

Parotid ductal stenosis after facial cosmetic surgery (2 case reports)

Jeong-Seok Choi, MD^a, Young-Mo Kim, MD^a, Jae-Yol Lim, MD^{b,*}

Abstract

Rationale: Facial cosmetic surgery sometimes causes complications involving surrounding tissues. In particular, parotid damage may cause fibrous tissue formation, ductal stenosis, and obstruct salivary flow. Affected patients usually complain of symptoms such as pain and swelling.

Patient concerns: The authors report 2 cases of obstructive parotitis, arising as a complication of facial cosmetic surgery that were treated successfully using sialendoscopic procedures.

Diagnosis: A diagnosis of parotid ductal stenosis was made based on medical history, clinical manifestations, imaging studies, and sialendoscopic findings for the 2 patients.

Interventions: The successful sialendoscopic procedures was given to the 2 patients.

Outcomes: The 2 patients have shown no recurrent symptoms during follow-up.

Lessons: Surgeons that perform facial cosmetic procedures should attain a thorough knowledge of the surgical anatomy of the parotid region and sialendoscopic procedure may be helpful for the management of obstructive parotitis due to complication of cosmetic surgery.

Abbreviation: SMAS = superficial muscular aponeurotic system.

Keywords: face-lift, facial cosmetic surgery, malarplasty, obstructive parotitis, sialendoscopy

1. Introduction

Obstructive parotitis is a common disease of the salivary gland and causes pain and swelling of the involved parotid gland after stimulation. This disease can be occasioned by sialolithiasis, ductal stenosis, infection, or injury.^[1] Parotid ductal injury sometimes can result as a complication of facial cosmetic surgery. Ductal damage may cause fibrous tissue formation, ductal stenosis, or obstruct salivary flow and lead to secondary ascending infection.^[2] We report 2 cases of obstructive parotitis arising after facial cosmetic surgery that were treated successfully using sialendoscopic procedures. Patients have provided informed consent for publication of the case.

Editor: N/A.

This research was supported by an Inha University Research Grant.

The authors have no potential conflict of interest to declare.

^aDepartment of Otorhinolaryngology-Head and Neck Surgery, Inha University School of Medicine, Incheon, ^bDepartment of Otorhinolaryngology, Gangnam Severance Hospital, Yonsei University College of Medicine, Seoul, Republic of Korea.

*Correspondence: Jae-Yol Lim, Department of Otorhinolaryngology-Head and Neck Surgery, Gangnam Severance Hospital, Yonsei University College of Medicine, 211, Eonju-ro, Gangnam-gu, Seoul 06273, Republic of Korea (e-mail: jyylimd@yuhs.ac).

Copyright © 2019 the Author(s). Published by Wolters Kluwer Health, Inc. This is an open access article distributed under the terms of the Creative Commons Attribution-Non Commercial-No Derivatives License 4.0 (CCBY-NC-ND), where it is permissible to download and share the work provided it is properly cited. The work cannot be changed in any way or used commercially without permission from the journal.

Medicine (2019) 98:15(e15015)

Received: 6 November 2018 / Received in final form: 14 February 2019 / Accepted: 6 March 2019

<http://dx.doi.org/10.1097/MD.00000000000015015>

2. Case reports

2.1. Case 1

A 51-year-old woman was first seen in our department of otorhinolaryngology with a chief complaint of transient episodes of left parotid swelling during the previous 4 months. The swellings were only moderately painful and seemed to be exacerbated by meals. Questioning indicated that cosmetic surgery (a face-lift) has been performed on both sides of her face 2 years previously. The left parotid gland and cheek were mildly swollen and some debris was discharged with saliva when the gland was squeezed. There was no cervical lymphadenopathy. Computed tomography showed distal focal ductal stenosis and a stone with proximal duct dilation and periductal wall thickening in the left parotid duct (Fig. 1A), but without evidence of parotid gland abnormality. Sialendoscopy (Karl Storz, Tuttlingen, Germany) was performed on the involved gland for evaluation and treatment of the ductal pathology. A 4 mm sized stone was discovered after passing the distal ductal stenotic lesion (Fig. 1B). Mechanical dilation and stone removal were conducted with a balloon catheter and forceps, but after stone removal, an unidentified blue colored foreign body was observed in the duct (Fig. 1C). Removal of this foreign body was not easy due to its cogwheel shaped surface, and a LASER was required to cut it in situ. After successfully removing the foreign material, it was found to be a thread penetrating the duct (Fig. 1D). A stent was inserted and removed 2 weeks after sialendoscopy. The patient showed no recurrent symptoms during follow-up.

2.2. Case 2

A 23-year-old woman visited our department of otorhinolaryngology due to left parotid swelling 2 months after zygomatic

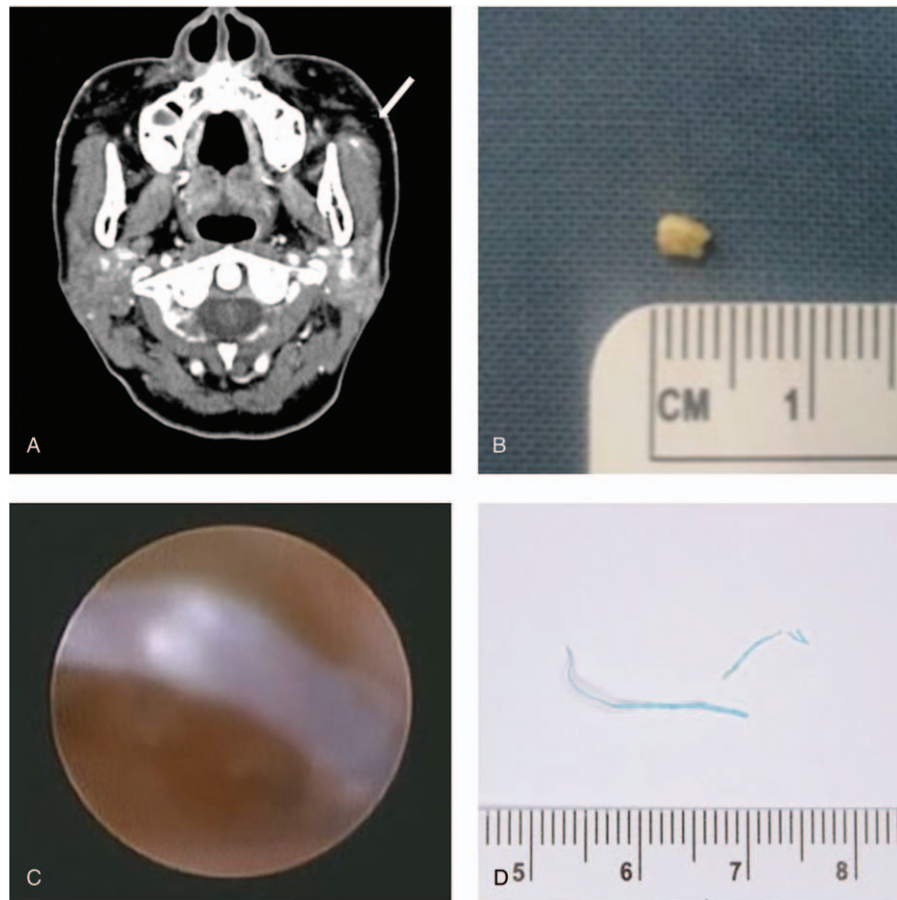


Figure 1. Computed tomographic and operative findings of case 1. (A) Axial enhanced neck computed tomograph showing a 0.4 cm sized stone in the superficial lobe of the left parotid gland with ductal dilatation (arrow), (B) 0.4 × 0.3 cm sized ductal stone removed by sialendoscopy, (C) Sialendoscopic finding showing the blue colored foreign body, which passed across the parotid ductal lumen, (D) The foreign body removed by sialendoscopy.

reduction surgery. Palpation indicated that the left parotid gland was slightly tender than normal. No associated lymphadenopathy was noted. Intraorally, mucosa was moist, but cloudy saliva was noted from the left duct orifice. Magnetic resonance sialography showed distal ductal obstruction and proximal ductal dilatation of the left parotid gland (Fig. 2A and B). Sialendoscopy was performed and severe ductal stricture of the opening site was observed. A guide wire was introduced through the stenotic portion and mechanical dilation and bougienage were conducted to widen the stenotic lumen (Fig. 2C). Marked dilatations of the proximal main duct and secondary and tertiary ducts were observed over the stenotic lesion (Fig. 2D). After sialendoscopic lavage with a continuous sterile saline perfusion, ductal debris was removed from the glands by massage, and steroid was instilled. A stent was inserted and removed 2 weeks later. However, during follow-up, she showed symptom recurrence, which was finally resolved by transoral ductal surgery involving transection of the stenotic duct and anastomosis of the proximal duct to oral mucosa (Fig. 2E and F).

3. Discussion

Chronic obstructive sialadenitis is mainly caused by sialolith, ductal stenosis, autoimmune disease, or radiation exposure, and the determination of its cause is crucial for adequate management. However, chronic obstructive sialadenitis can sometimes

result from parotid duct injury during facial surgery. Nowadays, facial cosmetic surgery is widely performed, and the surgical skills have evolved significantly due to better understanding of facial anatomy, but unfortunately, some practitioners tend to perform cosmetic procedures without adequate background knowledge of head and facial surgery. In particular, aggressive dissection of facial soft tissues, such as those of the superficial muscular aponeurotic system (SMAS) poses the risk of parotid gland injury. Furthermore, injury to parenchyme of the parotid gland or to the ductal system can lead to sialocele, parotid fistula, obstructive parotitis, and ductal stenosis.^[3] These postoperative complications have rarely been documented as side effects of facial cosmetic surgery, and the iatrogenic surgical traumatization of parotid glands is not attracting much attention.^[4]

Palpation of the parotid gland is not easy under normal conditions because most portion of parotid gland is wrapped around the ascending ramus of the mandible. It locates inferior and anterior to the external auditory canal, and its superficial portion extends anteriorly over the masseter muscle. Superior boundary of parotid gland is inferior border of zygoma. There is no natural plane between the parotid gland and overlying skin, and thus, the gland lies directly under the skin with variable amounts of subcutaneous fat. The parotid duct starts from the anterolateral edge of the parotid gland and curves around the anterior edge of the masseter muscle to enter the mouth (buccal mucosa of upper second molars).^[5] Safe and successful facial

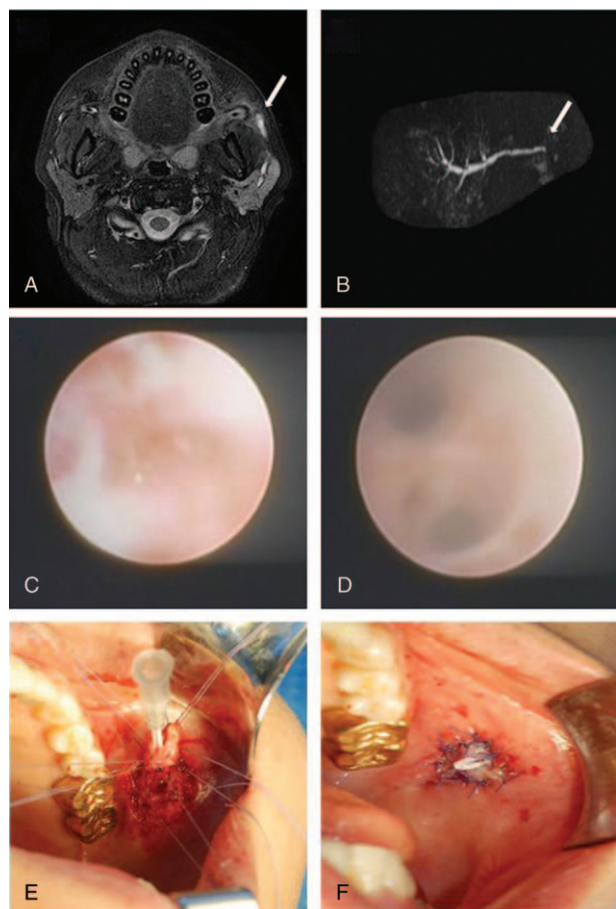


Figure 2. MR sialographic and sialendoscopic findings and operative procedure in case 2. (A) MR sialography axial T2 weighted image showing increased signal intensity and ductal dilatation (arrow) due to obstruction of the distal duct of the left parotid gland. (B) MR sialographic image showing dilation of proximal ducts, but which failed to visualize the main parotid duct (arrow). (C) Sialendoscopy revealed severe ductal stricture of the opening site, and (D) marked dilatations of the proximal main duct and the secondary and tertiary ducts after widening the stenotic portion. (E) Transoral ductal surgery was performed to transect the stenotic duct and anastomose the proximal duct to oral mucosa. (F) A catheter stent was inserted in the left Stensen duct, sutured, and maintained for 2 weeks. MR = magnetic resonance.

cosmetic surgery requires an appreciation of the anatomy of the face, such as, of SMAS and parotid gland sheath and ductal courses and openings in the oral cavity. Inadvertent dissections with parotid-masseteric fascia, periductal soft tissue, and buccal mucosa can cause trauma to any parotid gland. Surgeons should be acutely aware of facial morbidities associated with any surgical site and should explain these postoperative complications to the patients. Healing of a surgically induced ductal damage makes scar tissue formation and ductal stenosis. These lesion blocks salivary flow and leads to salivary stagnation. Furthermore, retained saliva has a high susceptibility to bacterial infection and causes sialodochitis and sialadenitis. Swelling of parotid gland can occur when gland inflammation is exacerbated by ductal obstruction due to inflammatory debris and scarring of the duct wall.

Obstructive parotitis in the first case is believed to have been caused by inappropriate stitching. The thread penetrated the parotid duct and acted as a foreign body in its lumen, which acted as a nidus for inflammation, stone formation, periductal fibrosis,

and ductal stenosis. This case supports the notion that some foreign bodies can cause parotid stone formation within ducts. We believe the cause of obstructive parotitis in our second case was inappropriate manipulation of soft tissue surrounding the parotid duct when approaching zygoma during surgery. Inept surgical skill and instrumentation could have caused parotid duct damage and consequent inflammation and stenosis formation.

Parotid duct stenosis can be a challenging clinical problem, which can lead to diffuse gland swelling, dilation of the duct, pain, discomfort, and recurrent infection.^[6,7] Conservative therapies, such as gland massage, antibiotics, and pain control are not usually effective because the saliva cannot go out through the stenotic lumen. Treatment options are parotidectomy and injection of botulinum toxin to suppress salivary flow.^[8] Other options include emerging techniques of sialendoscopy and ductal surgery, which together offer unique advantages for managing obstructive sialadenitis.^[9,10]

Nowadays, symptom amelioration may be achieved using a variety of new sialendoscopic techniques, such as stent insertion, balloon sialodochoplasty, forced manipulation with forceps and guide wire, and pressured saline irrigation. The basic aim of these procedures is to relieve the stricture by widening the duct lumen and promoting normal salivary flow. Elimination of the primary cause of salivary flow obstruction usually facilitates healing and the subsidence of obstructive symptomatology, and the gland may return to normal function after surgery. Furthermore, given sufficient salivary flow and duct flushing, further bacterial incursions are discouraged. Our 2 patients responded well to sialendoscopic and/or sialendoscopic assisted ductal procedures. In our opinion, in cases of severe ductal damage of the parotid gland, sialendoscopic assisted ductal surgery is a useful modality.

The main causes of salivary gland injury during facial cosmetic surgery are inadequate skills and scarce understanding of facial anatomy. We believe that surgeons that perform these procedures should attain a thorough knowledge of the surgical anatomy of the parotid region. It is recommended directing a patient to an otorhinolaryngologist skilled in sialendoscopy when parotid gland damage is suspected because sialendoscopy may be helpful for the management of obstructive parotitis.

Author contributions

Conceptualization: Jae-Yol Lim.

Data curation: Jeong-Seok Choi.

Formal analysis: Jeong-Seok Choi.

Investigation: Jeong-Seok Choi.

Methodology: Jae-Yol Lim.

Project administration: Young-Mo Kim.

Supervision: Young-Mo Kim.

Validation: Young-Mo Kim.

Visualization: Jeong-Seok Choi.

Writing – original draft: Jeong-Seok Choi.

Writing – review and editing: Jae-Yol Lim.

Jeong-Seok Choi orcid: 0000-0001-9669-2141.

References

- Ardekian L, Shamir D, Trabelsi M, et al. Chronic obstructive parotitis due to strictures of Stenson's duct – our treatment experience with sialoendoscopy. *J Oral Maxillofac Surg* 2010;68:83–7.
- Atienza G, López-Cedrún JL. Management of obstructive salivary disorders by sialendoscopy: a systematic review. *Br J Oral Maxillofac Surg* 2015;53:507–19.

- [3] Nahlieli O, Abramson A, Shacham R, et al. Endoscopic treatment of salivary gland injuries due to facial rejuvenation procedures. *Laryngoscope* 2008;118:763–7.
- [4] Baurmash HD. Obstructive parotitis after rhytidectomy. *J Oral Maxillofac Surg* 2004;62:1439.
- [5] Carlson GW. The salivary glands. Embryology, anatomy, and surgical applications. *Surg Clin North Am* 2000;80:261–73.
- [6] Koch M, Zenk J, Iro H. Algorithms for treatment of salivary gland obstructions. *Otolaryngol Clin North Am* 2009;42:1173–92.
- [7] Koch M, Iro H. Extended and treatment-oriented classification of parotid duct stenosis. *Laryngoscope* 2017;127:366–71.
- [8] Ryan WR, Chang JL, Eisele DW. Surgeon-performed ultrasound and transfacial sialoendoscopy for complete parotid duct stenosis. *Laryngoscope* 2014;124:418–20.
- [9] Kim YM, Choi JS, Hong SB, et al. Salivary gland function after sialendoscopy for treatment of chronic radioiodine-induced sialadenitis. *Head Neck* 2016;38:51–8.
- [10] Koch M, Iro H. Salivary duct stenosis: diagnosis and treatment. *Acta Otorhinolaryngol Ital* 2017;37:132–41.