[UCI]I804:11046-000000517142

Comparison of condylar position according to the amount of incisor retraction during orthodontic treatment : a cone beam computed tomography study

Sang Ah Cho

The Graduate School

Yonsei University

Department of Dentistry

Comparison of condylar position according to the amount of incisor retraction during orthodontic treatment : a cone beam computed tomography study

A Master's Thesis
Submitted to the Department of Dentistry
and the Graduate School of Yonsei University
in partial fulfillment of the requirements for the degree of
Master of Dental Science

Sang Ah Cho

June 2018

This certifies that the Master's thesis of
Sang Ah Cho is approved.

Yoon Jeong Choi

Thesis Supervisor : Yoon Jeong Choi

Sung Sang Jin

Sang Jin Sung

Bumyeon Koh

Bum Yeon Koh

The Graduate School
Yonsei University
June 2018

감사의 글

설렘을 안고 연세대학교 대학원에 지원 한 것이 엊그제 같은데, 감사의 글을 쓰다 보니 졸업이 머지않았다는 것이 실감납니다. 연구에 도움을 주신 많은 분께 이 글을 통해 감사의 말을 전하고자 합니다.

존경하는 최윤정 지도교수님 감사합니다. 부족하고 서투른 저에게 항상 올바른 방향을 제시해 주시고 지도해 주신 교수님 덕분에 저의 학위 논문이 완성 될 수 있었습니다.

마지막까지 세심하게 논문의 수정에 애써주시고 진심어린 조언을 아끼지 않으신 성상진 교수님, 바쁘신 와중에도 논문 심사를 맡아주셔서 감사합니다.

저의 멘토이자 롤모델인 고범연 선생님, 연구에 사용된 자료제공을 너그러이 허락해주셔서 감사합니다. 선생님의 격려와 도움 덕분에 제가 여기까지 올 수 있었습니다.

항상 제 선택과 결정을 믿고 응원해주는 사랑하는 남편 송광현씨 고맙습니다. 딸의 늦깎이 공부를 뒷바라지하느라 고생하신 부모님을 비롯하여 힘들 때마다 든든한 지원군이 되어준 우리 가족 모두에게 깊은 감사의 마음을 전합니다.

1년차가 대학원 일로 휴가를 쓸 때마다 흔쾌히 허락해준 서울아산병원 치과교정과 의국원 모두를 비롯하여 대학원 생활에 도움을 주신 모든 분들에게 다시 한번 진심으로 감사드립니다.

Table of contents

List of figures

List of tables

ABSTRACT

Comparison of condylar position according to the amount of incisor retraction during orthodontic treatment : a cone beam computed tomography study

Sang Ah Cho, D.D.S.

Department of Dentistry

The Graduate School, Yonsei University

(Directed by Prof. Yoon Jeong Choi, D.D.S., M.S.D., Ph.D.)

Since the temporomandibular joint (TMJ) is an important anatomical structure in orthodontic field, there have been a lot of studies to investigate the relationship between temporomandibular disorder (TMD) and orthodontic treatment. However, it is difficult to identify the direct relationship between TMD and orthodontic treatment, which still remains a controversial issue.

Most previous studies used TMJ tomograms that have limited accuracy because of superimposition and distortion. The development of computed tomography (CT) allows to obtain three-dimensional images of the condyle and joint spaces. The aim of this study is to evaluate changes in the condylar position during the orthodontic treatment using cone beam CT (CBCT). Sixty two patients who had visited a private clinic were divided into 3 groups (minimum, moderate, and maximum retraction groups) according to the amount of retraction of the maxillary incisor. Pre-treatment (T0) and post-treatment (T1) CBCT images were superimposed based on the anterior cranial base using OnDemand3D program. Four joint spaces (anterior, posterior, superior, and medial), condylar height, and ramus height were measured to evaluate the condyle position and compared between T0 and T1 using paired t-tests. In the minimum and moderate groups, there were no significant changes in the 4 joint spaces ($P > 0.05$), while in the maximum group the posterior joint space decreased by 0.2 mm during treatment ($P < 0.05$). However, the posterior joint space after treatment was still within a normal range. The condylar height and ramus height did not show statistically significant changes during treatment ($P > 0.05$). There was no significant relationship between condylar position and maxillary incisor retraction in the minimum and moderate retraction groups ($P > 0.05$).

The orthodontic treatment does not significantly affect the condylar position. Although excessive retraction of maxillary incisors can affect the condylar position, the amount of backward movement of condyle is in a physiologic range.

Keywords : TMJ, CBCT, joint space, condyle position, orthodontic treatment, incisor retraction, extraction

Comparison of condylar position according to the amount of incisor retraction during orthodontic treatment : a cone beam computed tomography study

Sang Ah Cho, D.D.S.

Department of Dentistry

The Graduate School, Yonsei University

(Directed by Prof. Yoon Jeong Choi, D.D.S., M.S.D., Ph.D.)

I. Introduction

Orthodontic treatment combined with premolar extraction was thought to cause a temporomandibular disorder (TMD). There have been studies to investigate the relationship between orthodontic treatment and TMD. However, etiology of TMD is still

incompletely understood. It is difficult to identify the direct relationship between orthodontic treatment and TMD because of its multifactorial nature, which remains a controversial issue.

There have been many reports that orthodontic treatment is not a risk factor of TMD. The orthodontic treatment was reported neither to cause TMD nor to increase risk of developing signs and symptoms of TMD.[1, 2] However, Farrar and McCarty[3] reported that posteriorly positioned condyle can cause the disk to slip off the condyle. Weinberg et al.[4] also reported that TMD occurs more frequently in the posteriorly positioned condyle and emphasized importance of the condyle position in the mandibular fossa.

Some studies suggested that during the orthodontic treatment with premolar extraction, the condyle moved backward as the anterior teeth were retracted.[5, 6] Paul et al.[7] also reported that there was a small but statistically significant posterior shift of the condyle even in non-extraction group.

However, there are limitations in previous studies that evaluated the condylar position using a two-dimensional (2D) tomogram and enrolled patients under 19 years of age, which means that changes related with growth could not be excluded. The temporomandibular joint (TMJ) is a small complex structure that is surrounded by temporal bone, mastoid process and articular eminence.[8] TMJ tomograms used in most previous studies have limited accuracy because of superimposition of the osseous structures and image distortion. Development of cone beam computed tomography (CBCT) allows to obtain three-dimensional (3D) images of the condyle and joint spaces

with relatively low radiation dose. In addition, 2D images such as lateral cephalograms and panoramic radiographs can be regenerated from the 3D CBCT images, which removes the necessity of additional radiation exposure. To our knowledge, there has been one report evaluating effects of orthodontic treatment on the condylar position using 3D images. Alhammadi et al.[9] reported that the condyle moved backward after orthodontic treatment accompanied by extraction of the maxillary premolars and the amount of the condylar movement was statistically significant. However, because there was no control group in the study there might be possibility that the posterior repositioning of the mandible resulted from a dual bite, which is commonly observed in skeletal Class II malocclusion.

Therefore, this study was conducted to verify the following null hypothesis: the condylar position does not change according to the amount of retraction of the maxillary anterior teeth during orthodontic treatment in adults. Patients were divided into minimum, moderate, and maximum retraction groups according to the amount of retraction of the maxillary incisor, and changes in 4 joint spaces (anterior, posterior, superior, and medial) during orthodontic treatment were compared among the three groups by measuring pre- and post-treatment CBCT images.

II. Materials and methods

1. Subjects

This retrospective study included minimum (n = 20, 6 men and 14 women), moderate (n = 22, 1 man and 21 women), and maximum (n = 20, 3 men and 17 women) retraction groups. From 1035 patients who had visited a private clinic from March 2012 to June 2017 and finished comprehensive orthodontic treatment, 128 patients were selected on the basis of the following inclusion and exclusion criteria. The inclusion criteria were age older than 19 and availability of CBCT images obtained before (T0) and after (T1) treatment. The exclusion criteria were a history of previous orthodontic treatment, presence of TMD, presence of systemic disease including rheumatoid arthritis, craniofacial deformity, and facial asymmetry (menton deviation > 4mm)[10]. Then, 66 patients were additionally excluded according to retraction of the maxillary central incisor (U1) during orthodontic treatment and orthodontic extraction scheme. Sixty-two consecutively treated patients were finally selected for the present study. Twenty patients who had underwent orthodontic treatment without extraction and showed less than 1 mm of U1 movement were assigned to a minimum-retraction (control) group (Figure 1). Forty-two patients treated with extraction of 4 premolars were divided into 2 groups according to the amount of retraction: moderate-retraction group (1 mm <U1 movement < 6 mm, Figure 2) and maximum-retraction group (U1 movement > 6 mm, Figure 3).[11] In the moderate-retraction group (n = 22), premolar extraction was performed to resolve

crowding and space deficiency, while it was performed to resolve protrusion in the maximum-retraction group (n = 20).

One orthodontist performed all treatments by using 0.018-inch slot pre-adjusted edgewise appliance (Roth prescription) with a wire sequence of 0.014-inch nickel-titanium, 0.016-inch nickel-titanium, 0.018 x 0.018-inch copper-NiTi, 0.016 x 0.022-inch copper-NiTi and 0.016 x 0.022-inch stainless steel.

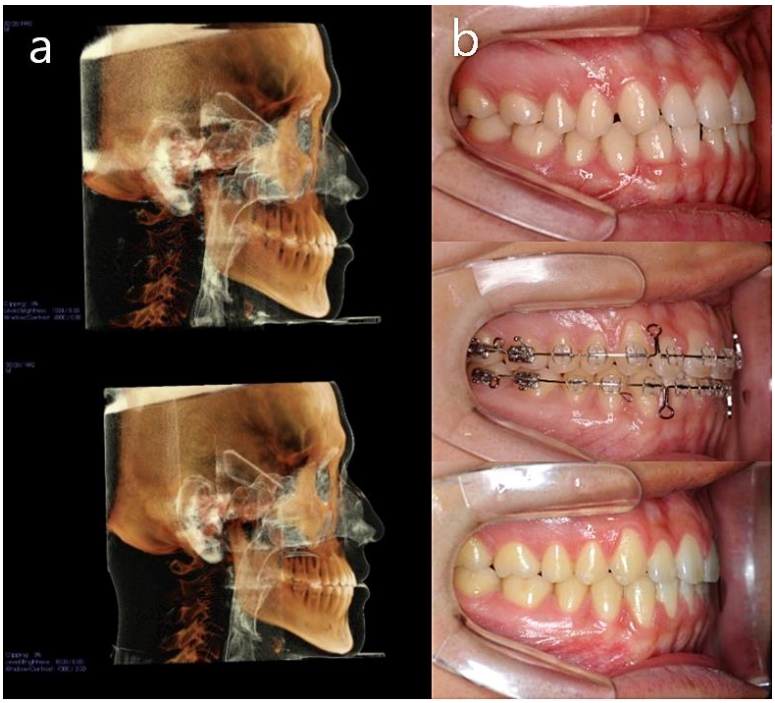

Figure 1. Minimum retraction group. The maxillary incisor moved within 1 mm. They had mild crowding or spaces before the treatment. a. Pre- and post-treatment CBCT b. Clinical photo images during the treatment

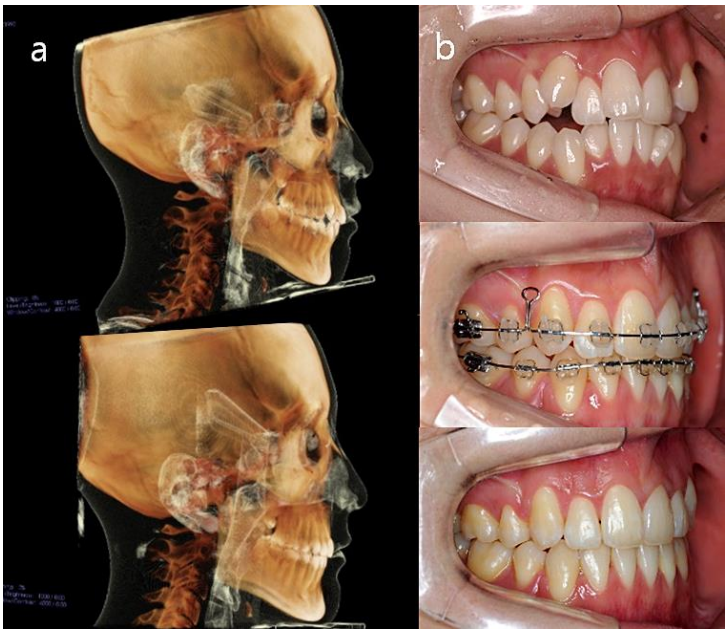

Figure 2. Moderate retraction group. Most of them had severe crowding at initial stage. a. Pre- and post-treatment CBCT b. Clinical photo images during the treatment

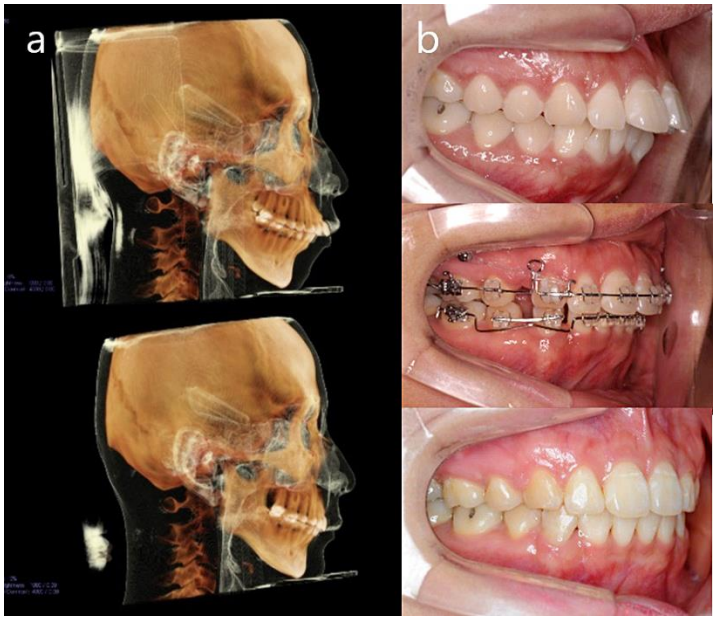

Figure 3. Maximum retraction group. Chief complaint of most patients in this group was protrusion. a. Pre- and post-treatment CBCT b. Clinical photo images during the treatment

2. Measurements

Before and after orthodontic treatment, CBCT scans were taken at 105 kV, 5.0 mA, scan time of 15s with a 0.2 mm voxel size (240 x 190 mm field of view) by Pax zenith CBCT machine (Vatech Co., Gyeonggi-do, Korea). Panoramic and cephalometric radiographs were generated from the CBCT images without additional radiation exposure.[12]

Patients were required to seat upright position with Frankfort plane parallel to the floor during image acquisition. The CBCT images were imported as DICOM files and reconstructed into 3D images with OnDemand3D software (CyberMed Inc., Seoul, Korea). Each CBCT scan was reoriented with three reference planes: Frankfort horizontal plane (FHP) passing through the left orbitale and both porions; the midsagittal plane (MSP) perpendicular to the FHP and passing through sella and nasion; and the coronal plane perpendicular to both FHP and MSP and passing through nasion. After reorientation of T0 images, T1 images were superimposed onto T0 images with reference of the anterior cranial base using automatic voxel-based superimposition, which made T0 and T1 images on the same coordination.[13] Nasion was set to (0, 0, 0) and 8 landmarks for the joint space measurements were digitized on each CBCT images (Table 1 and Figure 4). Landmarks include the most anterior, posterior, superior, and medial point of the condylar head and their corresponding fossa points to calculate the joint spaces. The joint space was measured for 4 regions (anterior, posterior, superior, and medial) to evaluate the condylar position. The anterior, posterior, and superior joint

spaces were measured on the sagittal section, and the medial joint space was measured on the coronal section (Figure 5).

To exclude possibility of changes in the condylar position because of condylar resorption during orthodontic treatment, condylar height, ramus height, and ramus inclination were included to measurements. To evaluate changes in skeletal and dental structures, the measurements included ANB, overjet, overbite, SN-MP, U1-SN, IMPA, ΔU1_H (amount of sagittal movement of the maxillary central incisor tip along the midsagittal plane), ΔL1_H (amount of sagittal movement of the mandibular central incisor tip along the midsagittal plane), ΔU6_H (amount of sagittal movement of the maxillary first molar mesiobuccal cusp), and ΔL6_H (amount of sagittal movement of the mandibular first molar mesiobuccal cusp). The joint spaces were measured on both right and left sides of the joint and the mean values were used for the present study.

Table 1. Definitions of landmarks and measurements.

Landmark		*Definition*
Anterior joint space	condylar point (AJSc)	The most anterior point of the condyle opposed to the shortest anterior condylar fossa distance
	fossa point (AJSf)	The most posterior point of the anterior wall of the mandibular fossa opposed to the shortest anterior condylar fossa distance
Posterior joint space	condylar point (PJSc)	The most posterior point of the condyle opposed to the shortest posterior condylar fossa distance
	fossa point (PJSf)	Most anterior point of the right posterior wall of the mandibular fossa opposed to the shortest posterior condylar fossa distance
Superior joint space	condylar point (SJSc)	The most superior point of the condylar head
	fossa point (SJSf)	The most superior and mid-point of the mandibular fossa
Medial joint space	condylar point (MJSc)	The most medial point of the condyle
	fossa point (MJSf)	The most lateral point of medial wall of mandibular fossa
Measurement		
Joint space	Anterior joint space	Distance between AJSc and AJSf
	Posterior joint space	Distance between PJSc and PJSf
	Superior joint space	Distance between SJSc and SJSf
	Medial joint space	Distance between MJSf and MJSc
	Condyle height	Distance between SJSc and the line passing through deepest point of mandibular notch and perpendicular to tangent posterior ramus line
	Ramus height	Distance between Go' (projection Go point on midsagittal plane) and Ar' (projection of Ar point on midsagittal plane)
	Ramus inclination	Angle between FH plane and ramus line (tangent to the posterior border of the ramus)

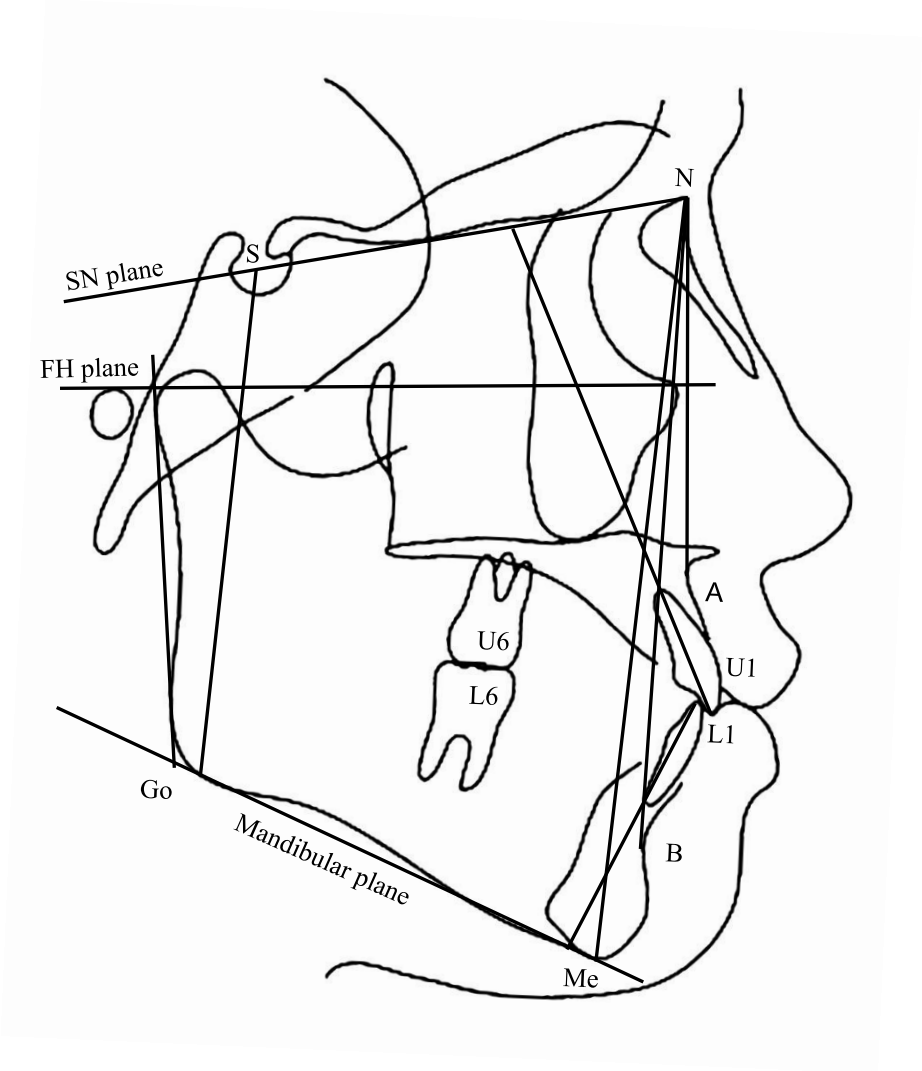

Figure 4. Landmarks and reference line ; Sella (S), Nasion (N), Gonion (Go), A point (A), B point (B), tip of maxillary central incisor (U1), tip of mandibular central incisor (L1), menton (Me), Mesiobuccal cusp tip of upper first molar (U6), Mesiobuccal cusp tip of lower first molar (L6).

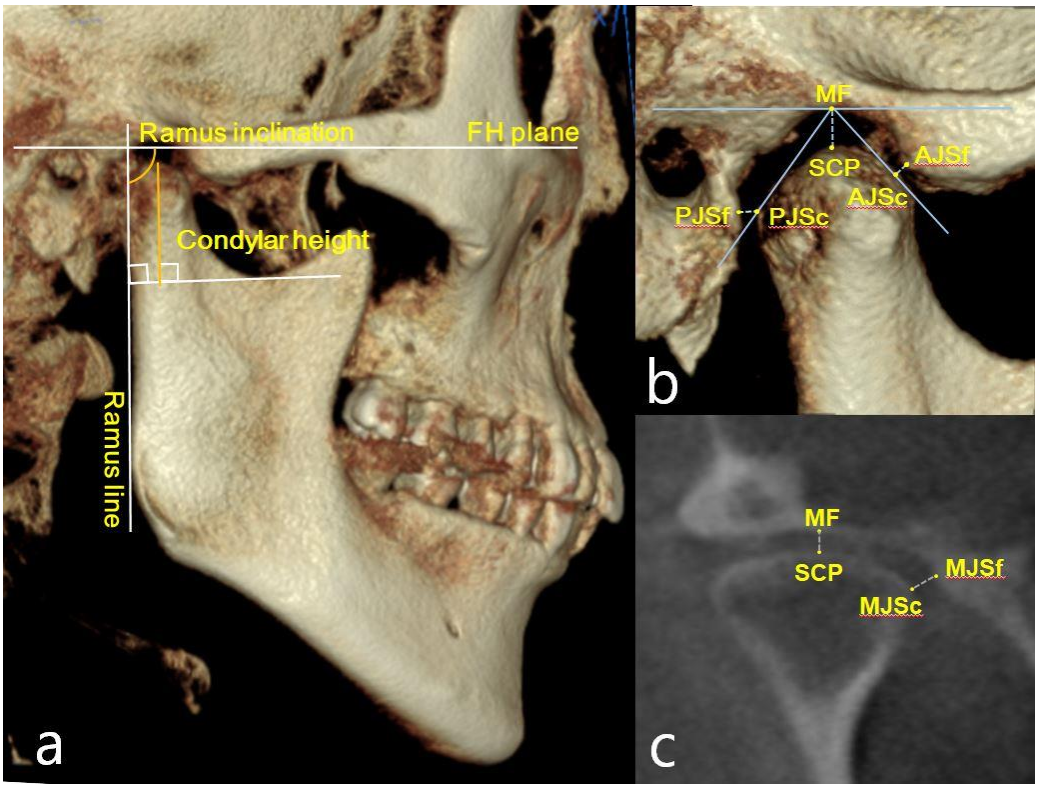

Figure 5. Joint spaces and condylar height and inclination.

a. Condylar height was measured to see the change of the condyle due to resorption during the orthodontic treatment. Ramus inclination was to see the rotational movement of the mandible during the orthodontic treatment.

b. Superior joint space(SJS), anterior joint space(AJS), posterior joint space(PSJ) were measured on sagittal section.

c. Mesial joint space(MJS) was measured on the coronal section.

3. Statistical analysis

Statistical analyses were performed using SPSS software 20.0 (IBM corp., Armonk, NY, USA). All CBCT scans were digitized by one observer. Five samples in each group were randomly selected and re-digitized two-weeks later to evaluate intra-observer reliability using intraclass correlation coefficient (ICC). Paired t-tests were conducted to evaluate differences between T0 and T1 in each group. To evaluate the differences of changes in the joint space among the 3 groups, one-way ANOVA or Kruskal-Walis test were conducted, and post-hoc tests were performed.

III. Results

All ICCs were over 0.91, except for the medial joint space (0.87) indicating good to excellent intra-observer reliability. Table 2 shows demographic features of the groups. Age was not statistically different among the three groups, while treatment duration of the minimum retraction group was significantly shorter than the other groups ($P < 0.05$).

Table 2. Demographic feature of subjects.

Variable	Minimum retraction (Control) n = 20	Moderate retraction n = 22	Maximum retraction n = 20	P value
Age (year)[§]	25.65 ± 4.88	25.41 ± 6.42	25.05 ± 4.87	0.759
Treatment duration (month)[§]	26.60 ± 5.78[a]	33.41 ± 5.54[b]	34.53 ± 5.86[b]	0.000***
ANB (°)	1.44 ± 2.02 [a]	1.77 ± 2.69 [a]	4.2 ± 2.56 [b]	0.001**
SN-MP (°)	32.44 ± 5.33 [a]	36.80 ± 6.91 [b]	39.70 ± 4.25 [b]	0.001**
U1-SN (°)	101.1 ± 6.69	105.2 ± 8.67	106.58 ± 5.71	0.074
IMPA (°)	95.76 ± 4.31	94.01 ± 7.78	98.80 ± 6.71	0.063
Overjet (mm)	2.79 ± 1.16[a]	2.87 ± 1.23[a]	5.34 ± 2.43[b]	0.000***
Overbite (mm)	2.77 ± 1.60	2.05 ± 1.83	3.06 ± 1.58	0.144
ΔU1_H (mm)[§]	0.11 ± 0.75[a]	3.70 ± 1.77[b]	8.02 ± 1.53[c]	0.000***

ANOVA was used to compare the three groups.

§ variables were compared by using Kruskal Wallis test and Mann-Whitney test for post hoc because the data did not show normal distribution.

The letters indicate the Bonferroni post hoc results, with the different letters representing statistically significant differences ($P < 0.05$). * $P < 0.05$, ** $P < 0.01$, *** $P < 0.001$.

The maxillary central incisors were retracted 0.16 ± 1.21 mm, 3.70 ± 1.77 mm and 8.02 ± 1.53 mm in the minimum, moderate and maximum retraction groups, respectively. There were no significant differences in the joint spaces between T0 and T1 in the minimum and moderate retraction groups (Table 3, $P > 0.05$). However, there were significant differences in the anterior and posterior joint spaces between T0 and T1 in the maximum retraction group ($P < 0.05$). The condylar height and ramus height did not show significant changes during the treatment in all the three groups ($P > 0.05$). Ramus inclination showed a significant decrease of 0.86° only in the minimum-retraction group ($P < 0.05$).

Changed in the anterior and posterior joint spaces during orthodontic treatment were significantly larger in the maximum-retraction group than in the other groups (Table 4, $P < 0.05$). Other measurements related the joint structure did not show significant differences among the three groups ($P > 0.05$), while changes in tooth inclination were significantly larger in the moderate and maximum retraction groups than in the minimum-retraction group ($P < 0.05$).

.

Table 3. Statistical comparisons of difference of values between T0 and T1 in each group.

	Minimum retraction (Control) n = 20			Moderate retraction n = 22			Maximum retraction n = 20		
	T0	T1	P	T0	T1	P	T0	T1	P
Anterior joint space (mm)	2.12 ± 0.71	2.10 ± 0.70	0.728	1.98 ± 0.44	2.01 ± 0.46	0.075	2.10 ± 0.84	2.27 ± 0.67	0.038*
Posterior joint space (mm)	2.34 ± 0.47	2.35 ± 0.57	0.905	2.03 ± 0.54	2.01 ± 0.56	0.159	2.30 ± 0.79	2.12 ± 0.78	0.023*
Superior joint space (mm)	2.87 ± 0.81	2.88 ± 0.75	0.920	2.57 ± 0.69	2.58 ± 0.69	0.180	2.38 ± 0.37	2.38 ± 0.37	0.955
Medial joint space (mm)	2.34 ± 0.75	2.37 ± 0.65	0.609	2.30 ± 0.79	2.30 ± 0.80	0.931	2.37 ± 0.67	2.35 ± 0.70	0.246
Condyle height (mm)	23.67 ± 2.53	23.58 ± 2.57	0.183	22.57 ± 2.67	22.59 ± 2.64	0.604	21.60 ± 3.07	21.64 ± 3.03	0.736
Ramus height	45.60 ± 4.37	45.60 ± 4.48	0.986	43.41 ± 5.11	43.39 ± 5.09	0.822	42.08 ± 5.14	42.09 ± 5.13	0.540
Ramus inclination (°)	91.44 ± 4.66	90.58 ± 4.79	0.003**	93.08 ± 4.30	92.97 ± 4.28	0.535	91.80 ± 4.06	91.37 ± 4.21	0.175
Overjet (mm)	2.79 ± 0.84	2.77 ± 1.60	0.551	2.87 ± 1.23	2.74 ± 0.76	0.631	5.34 ± 2.42	2.55 ± 0.51	0.000
Overbite (mm)	2.77 ±1.60	2.42 ± 0.76	0.310	2.05 ± 1.83	2.73 ± 1.43	0.067	3.06 ± 1.58	3.01 ± 1.00	0.901
U1_H (mm)	0.96 ± 6.08	1.11 ± 5.82	0.575	-3.26 ± 4.35	0.44 ± -0.39	0.000***	-5.85 ± 4.93	2.17 ± 4.37	0.000***
L1_H (mm)	3.81 ± 5.31	3.69 ± 5.68	0.664	-0.39 ± 4.68	3.18 ± 4.33	0.000***	-0.51 ± 4.56	4.71 ± 4.30	0.000***
U6_H (mm)	28.57 ± 5.03	28.66 ± 5.13	0.425	24.36 ± 3.80	22.17 ± 3.73	0.000***	24.16 ± 4.33	22.99 ± 3.89	0.000***
L6_H (mm)	28.14 ± 5.09	28.55 ± 5.21	0.034*	23.19 ± 4.08	21.62 ± 4.20	0.000***	24.75 ± 4.50	22.99 ± 4.17	0.000***

Paired t tests were performed to compare T0 and T1 for each group. Superior joint space, ramus height, U1_H in moderate retraction group and condylar height, U1_H in maximum retraction group were compared by using Wilcoxon signed rank test because the data did not show normal distribution. * P < 0.05, **P < 0.01, ***P < 0.001

Table 4. Statistical comparison of the difference of variables among three groups

variable	Minimum retraction n = 20	Moderate retraction n = 22	Maximum retraction n = 20	P value
ΔAnterior joint space (mm)	-0.02 ± 0.24 [a]	0.03 ± 0.08 [a]	0.17 ± 0.34 [b]	0.044*
ΔPosterior joint space (mm)	0.00 ± 0.28 [a]	-0.02 ± 0.07 [a]	-0.18 ± 0.33 [b]	0.041*
ΔSuperior joint space (mm)	0.00 ± 0.22	0.01 ± 0.05	0.00 ± 0.08	0.953
ΔMedial joint space (mm)	0.03 ± 0.24	0.00 ± 0.07	-0.02 ± 0.07	0.604
ΔCondyle height (mm) §	-0.09 ± 0.28	0.02 ± 0.13	0.04 ± 0.17	0.290
ΔRamus height (mm) §	-0.00 ± 0.37	-0.02 ± 0.17	0.02 ± 0.11	0.868
ΔRamus inclination (°) §	-0.86 ± 1.10	-0.11 ± 0.81	-0.44 ± 1.39	0.065
ΔANB (°)	0.23 ± 0.74	0.01 ± 0.74	0.03 ± 1.17	0.690
ΔU1-SN (°)	0.21 ± 6.04[a]	-7.53 ± 5.2[b]	-16.34 ± 5.05[c]	0.000***
ΔIMPA (°)	2.26 ± 4.93[a]	-5.30 ± 5.83[b]	-5.99 ± 6.96[b]	0.000***

One way ANOVA was used to compare the three groups.

§ Variables were compared by using Kruskal Wallis test and Mann-Whitney test for post hoc because the data did not show normal distribution.

The letters indicate the Bonferroni post hoc results, with the different letters representing statistically significant differences ($P < 0.05$).

* $P < 0.05$, ** $P < 0.01$, *** $P < 0.001$

IV. Discussion

The aim of this study is to evaluate changes in the condylar position using CBCT during orthodontic treatment. In the present study, condyle position was stable in the minimum and moderate retraction groups. This supports most of the previous studies which reported orthodontic treatment is not related to the condyle position. However, when the maxillary anterior teeth retracted over 6 mm (maximum retraction), there was 0.2 mm decrease of the posterior joint space, which was statistically significant, but clinically insignificant backward movement of the condyle (Figure 6). Therefore, premolar extrusion during orthodontic treatments may not directly affect to position of the condyle.

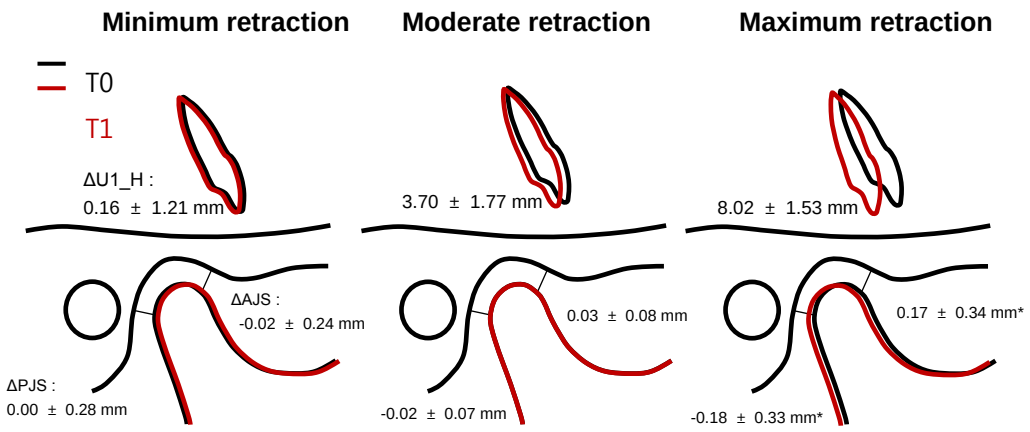

Figure 6. Schematic representation of condylar movement during the orthodontic treatment. Condyle moved backward significantly in the maximal-retraction group

With the development of maximum anchorage devices including miniscrew, absolute anchorage has become possible which has expanded the range of anterior retraction.[11, 14]

When the maxillary incisors retracted maximally, the mean of posterior condylar movement was 0.18 ± 0.33 mm. Of the total 20 out of the maximum retraction group, the condyle of 6 subjects moved more than the average value. Wyatt[15] stated that as the maxillary incisors moved backward, masticatory muscles attempt to retract the mandible when the patient closes the mouth to maximum intercuspation. This mandibular movement affects the backward movement and distal pressure of the condyle. Dalili et al[16] reported that mean posterior joint space in people with normal joint function (healthy joint) was 2.1 ± 0.7 mm. In this study, posterior joint space at T1 in maximum retraction group was 2.12 ± 0.78 mm, which is within a physiologically normal range and all the subjects were clinically asymptomatic after the orthodontic treatment. It seems not to be a problem clinically, but from an intra-articular biomechanical and biochemical aspect, decrease of the adequate distance between condyle and glenoid fossa. Then overloading can cause gradual reduction of lubrication function.[17] This can lead to temporomandibular dysfunction in a long-term prospective and in the case of the condyle pressing the retrodiscal tissue, patient can feel the pain. The risk of TMD is more than twice in retropositioned position of condyle than optimum position.[18, 19] Therefore, attention should be paid to excessive maxillary incisor retraction.

Additional regression analyses were done to evaluate the correlation between change in condyle position and ΔU1_H, ΔL1_H, Δoverjet, Δoverbite, treatment duration, ΔIMPA,

ΔSN-U1, and ΔANB. All variables except ΔL1-H did not exhibit statistically significant correlations with the condylar position ($P > 0.05$). Increase in the amount of retraction of lower incisors showed a significant correlation with decrease in posterior joint space ($r = -0.33$, $P < 0.01$). However, since ΔU1_H and ΔL1_H have a close positive correlation ($r = 0.81$), the maxillary incisor retraction may have an indirect influence on posterior movement of condyle.

There are several limitations of this study. Due to the ethical issues, it was difficult to obtain CBCT records from normal untreated subjects. Therefore, we couldn't compare the condyle position between untreated group and treated group. TMD is cited as commonly represented in Class II division 2 malocclusion, so that Alhammadi et al[9] observed condyle significantly moved posteriorly when upper premolar extracted in previous study. However, the only upper premolar extraction cases were not enough so that we couldn't compare together. Further study needs the long-term follow-up of the patients to examine the change of condylar position and onset of TMD.

V. Conclusion

In the minimum and moderate retraction group, there is no significant relationship between condylar position and the maxillary incisor retraction. In contrast, in the maximum retraction group, the condyle moved backward, although the amount of the condylar movement is 0.2 mm, which can be considered clinically insignificant. The posterior joint space after treatment in the maximum retraction group was 2.3 mm, which is in a physiologic range. As excessive retraction of the maxillary incisors can affect the condylar position, it is important to examine the signs and symptoms of the condyle carefully during orthodontic treatment.

Reference

1. McNamara JA, Jr., Seligman DA, Okeson JP. Occlusion, Orthodontic treatment, and temporomandibular disorders: a review. J Orofac Pain 1995;9(1):73-90.

2. Leite RA, Rodrigues JF, Sakima MT, Sakima T. Relationship between temporomandibular disorders and orthodontic treatment: a literature review. Dental Press J Orthod 2013;18(1):150-7.

3. WB F, William L, McCarty. A clinical outline of temporomandibular joint diagnosis and treatment. 7th edition ed. Montgomery, Alabama: Normandie Publications; 1983.

4. Weinberg LA. Role of condylar position in TMJ dysfunction-pain syndrome. J Prosthet Dent 1979;41(6):636-43.

5. Sadowsky C. The risk of orthodontic treatment for producing temporomandibular mandibular disorders: a literature overview. Am J Orthod Dentofacial Orthop 1992;101(1):79-83.

6. Terrance J, Spahl, John W, Witzig. The clinical management of basic maxillofacial orthopedic appliances. Littleton, MA: PSG Publishing; 1987.

7. Major P, Kamelchuk L, Nebbe B, Petrikowski G, Glover K. Condyle displacement associated with premolar extraction and nonextraction orthodontic treatment of Class I malocclusion. Am J Orthod Dentofacial Orthop 1997;112(4):435-40.

8. Fraga MR, Rodrigues AF, Ribeiro LC, Campos MJ, Vitral RW. Anteroposterior condylar position: a comparative study between subjects with normal occlusion and patients with Class I, Class II Division 1, and Class III malocclusions. Med Sci Monit 2013;19:903-7.

9. Alhammadi MS, Fayed MS, Labib A. Three-dimensional assessment of condylar position and joint spaces after maxillary first premolar extraction in skeletal Class II malocclusion. Orthod Craniofac Res 2017;20(2):71-78.

10. Ikeda M, Miyamoto JJ, Takada JI, Moriyama K. Association between 3-dimensional mandibular morphology and condylar movement in subjects with mandibular asymmetry. Am J Orthod Dentofacial Orthop 2017;151(2):324-34.

11. Kuroda S, Yamada K, Deguchi T, Kyung HM, Takano-Yamamoto T. Class II malocclusion treated with miniscrew anchorage: comparison with traditional orthodontic mechanics outcomes. Am J Orthod Dentofacial Orthop 2009;135(3):302-9.

12. Feragalli B, Rampado O, Abate C, et al. Cone beam computed tomography for dental and maxillofacial imaging: technique improvement and low-dose protocols. Radiol Med 2017;122(8):581-88.

13. Weissheimer A, Menezes LM, Koerich L, Pham J, Cevidanes LH. Fast three-dimensional superimposition of cone beam computed tomography for orthopaedics and orthognathic

surgery evaluation. Int J Oral Maxillofac Surg 2015;44(9):1188-96.

14. Liou EJ, Chang PM. Apical root resorption in orthodontic patients with en-masse maxillary anterior retraction and intrusion with miniscrews. Am J Orthod Dentofacial Orthop 2010;137(2):207-12.

15. Wyatt WE. Preventing adverse effects on the temporomandibular joint through orthodontic treatment. Int J Orthod 1988;26(3-4):10-2.

16. Dalili Z, Khaki N, Kia SJ, Salamat F. Assessing joint space and condylar position in the people with normal function of temporomandibular joint with cone-beam computed tomography. Dent Res J (Isfahan) 2012;9(5):607-12.

17. Nitzan DW. The process of lubrication impairment and its involvement in temporomandibular joint disc displacement: a theoretical concept. J Oral Maxillofac Surg 2001;59(1):36-45.

18. Williams BT. Role of condylar position in TMJ dysfunction-pain syndrome. J Prosthet Dent 1979;42(5):597.

19. Paknahad M, Shahidi S. Association between mandibular condylar position and clinical dysfunction index. J Craniomaxillofac Surg 2015;43(4):432-6.

ABSTRACT(IN KOREAN)

교정치료 전후 CBCT를 이용한 상악 전치 후방 이동량에 따른 하악 과두의 위치 비교

연세대학교 대학원 치의학과

조 상 아

(지도 교수 : 최 윤 정)

측두하악관절(TMJ)은 교정 영역에서도 중요한 해부학적 구조물로, 측두하악관절 질환(TMD)과 교정치료의 관계에 관하여 많은 연구가 진행되어 왔다. 그러나 TMD는 요인이 다양하여 TMD와 교정치료의 직접적인 관계를 증명하는 것이 어려우므로 아직까지 이 주제에 관하여 논란이 있다. 대부분의 선행 논문은 TMJ tomogram을 이용하여 연구하였으나, 이는 해부학적 구조물의 중첩과 이미지의 왜곡으로 인해 정확성에 한계가 있었다. 그러나 최근 computed tomography의 발달로 하악 과두와 관절공극을 삼차원 영상으로 획득할 수 있게 되었다.

본 연구의 목적은 CBCT를 이용하여 교정치료 전후 하악 과두의 위치 변화를 평가하는 것이다. 한 개인치과를 내원한 62명의 환자를 상악 전치의 후방 이동량에 따라 세 군으로 분류하였다(최소, 중간, 최대 견인군). OnDemand3D 프로그램을

이용하여 교정 치료 전(T0), 후(T1) CBCT를 중첩하였고 하악과두의 위치를 평가하기 위하여 네 개의 관절 공극(전방, 상방, 후방, 내측방)과 과두 높이, 하악지 높이를 계측하였고, 교정치료 전후 관절공극의 변화를 비교하였다. 최소-중간 견인군에서는 4개의 관절 공극 변화가 유의하지 않았지만($P > 0.05$), 최대 견인군에서는 교정 치료 후에 후방 관절 공극이 약 0.2 mm 감소하였다.($P < 0.05$) 그러나 치료 후 후방 관절 공극은 정상 범주 내에 있었다. 교정 치료 동안 과두 높이와 하악지 높이는 유의한 변화가 없었으며 상악 전치의 최소-중간 견인군에서는 과두 위치의 유의한 변화가 없었다.

교정치료는 과두 위치 변화에 유의한 영향을 미치지 않는다. 상악 전치를 과도하게 견인하였을 때 하악 과두가 후방으로 이동하나 그 양은 임상적으로 무시할만한 정도이다.

핵심이 되는 말 : 측두하악관절, CBCT, 관절공극, 하악 과두 위치, 교정치료, 전치 후방이동, 발치