[UCI]I804:11046-000000516231

Comparison of soft tissue changes between incisor tipping and translation in premolar extraction case

Won Kyeong Baik

Department of Dentistry
The Graduate School, Yonsei University

Comparison of soft tissue changes between incisor tipping and translation in premolar extraction case

Directed by Professor Kee-Joon Lee

The Master's Thesis
Submitted to the Department of Dentistry
and the Graduate School of Yonsei University
in partial fulfillment of the requirements for the degree of
Master of Dental Science

Won Kyeong Baik

June 2018

This certifies that the dissertation of

Won-Kyeong Baik is approved.

Thesis Supervisor : Kee-Joon Lee

Hyung-Seog Yu

Jung-Yul Cha

The Graduate School

Yonsei University

June 2018

감사의 글

부족한 제자를 이끌어 주시고 논문이 완성되기까지 따뜻한 배려와 함께 세심한 지도와 격려를 아끼지 않으신 이기준 지도 교수님께 진심으로 감사 드리며, 바쁘신 와중에도 귀중한 시간을 내주시어 관심과 조언을 보내주신 유형석 교수님, 차정열 교수님께 깊이 감사 드립니다. 또한 저에게 교정학을 공부할 수 있도록 기회를 주시고 많은 가르침을 주신 백형선 명예교수님, 황충주 교수님, 김경호 교수님, 정주령 교수님, 최윤정 교수님, 최성환 교수님께도 감사 드립니다.

논문 집필부터 의국 생활까지 많은 조언과 도움을 주신 권선미 선생님과, 수련 생활 동안 서로 힘이 되어주고 함께 동고동락한 의국 동기 박진호, 송병재, 이예슬, 천주희, 한서연 선생과 든든한 후배들 강성태, 김다소미, 안윤수, 정희규, 홍현기 선생에게도 이 자리를 빌려 감사의 마음을 전합니다.

마지막으로 지금의 저를 있게 해주시고 아낌없는 지원과 응원을 보내주시는 사랑하는 부모님께 깊이 감사 드리며, 부족한 형을 잘 따라주고 늘 도움을 아끼지 않는 하나뿐인 동생에게 고마움을 전합니다.

2018 년 6 월

저자 씀

TABLE OF CONTENTS

LEGENDS OF FIGURES

LEGENDS OF TABLES

Abstract

Comparison of soft tissue changes between incisor tipping and translation in premolar extraction case

Won Kyeong Baik

The Graduate School of Yonsei University

Department of Dentistry

(Directed by Professor Kee-Joon Lee)

The objective of this study was to compare the changes of soft tissues after extraction of 4 premolars followed by maximum retraction of anterior teeth, depending on the type of anterior teeth movement, tipping and translation.

The subjects of this retrospective study were selected from the patients who had undergone extraction of 4 premolars, followed by maximum retraction of anterior teeth. The subjects were then divided into two groups, based on the type of anterior

teeth retraction. Tipping group consisted of 27 patients and translation group consisted of 26 patients. Lateral cephalograms were taken before and after treatment, and the changes of hard and soft tissues were evaluated.

The root apex of the upper and lower incisors showed retractions of 0.33 mm and 0.26 mm, respectively, in tipping group, and 5.02 mm and 5.31 mm, respectively, in translation group; the differences between the two groups were significant ($p < 0.001$).

A point and B point moved posteriorly 0.61 mm and 1.98 mm, respectively in translation group, in contrast to almost no horizontal changes in tipping group ($p < 0.001$).

The soft tissue point A and soft tissue point B showed retractions of 0.61 mm and 1.25 mm, respectively, in tipping group, and 1.10 mm and 3.25 mm, respectively, in translation group; the differences between the two groups were significant ($p < 0.01$). The mentolabial sulcus angle increased 5.89° in tipping group, and decreased 8.13° in translation group; the differences between the two groups were significant ($p < 0.001$).

This result suggests that the type of anterior teeth retraction affects the changes of soft tissue profile. This study may provide the guidelines to orthodontists in deciding the type of tooth movement during anterior teeth retraction.

Key words: retraction of anterior teeth, tipping, translation, soft tissue changes

Comparison of soft tissue changes between incisor tipping and translation in premolar extraction case

Won Kyeong Baik

The Graduate School of Yonsei University

Department of Dentistry

(Directed by Professor Kee-Joon Lee)

I. Introduction

One of the most important goals of orthodontic treatment is the improvement of esthetics as well as achievement of ideal occlusal function. It is generally accepted that orthodontic tooth movement influences soft tissue profile, with particular interest in lip position (Hayashida, et al., 2011). In treatment planning, therefore, orthodontists should decide the type of tooth movement suited for the achievement of desirable soft tissue profile.

Retraction of anterior teeth following premolar extraction causes significant changes of anterior soft tissue profile. There are a number of previous studies that evaluated the relationship between the amount of retraction and soft tissue changes (Bravo, 1994; Kim, et al., 2017). Caplan et al. (Caplan and Shivapuja, 1997) reported that in adult bimaxillary protrusive patients, the ratios of maxillary anterior teeth retraction to upper lip retraction, and mandibular anterior teeth retraction to lower lip retraction were to be 1.75:1 and 1.2:1, respectively. However, some other studies have found that there was no definite correlation between changes in dentition and changes in soft tissue (Hershey, 1972; Talass, et al., 1987).

In last decades, the emergence of skeletal anchorage systems such as miniscrews made it possible to achieve significant amount of anterior teeth retraction (Kuroda, et al., 2009). Moreover, proper mechanics combined with miniscrews enabled the true bodily translations of the incisors (Kim, et al., 2014). However, most literatures which studied the changes after retraction of anterior teeth were only concerned to the amount of retraction, not the type of retraction such as tipping and translation.

The aim of this study was to compare the changes of hard and soft tissues after extraction of 4 premolars followed by maximum retraction of anterior teeth, depending on the type of anterior teeth movement, tipping and translation. Our hypothesis was that there would be no differences between the two groups in changes of hard and soft tissues which are close to the root apex of the upper and lower incisors.

II. Materials and methods

1. Subjects

The subjects for this retrospective study were selected from the patients who had undergone orthodontic treatment at the Department of Orthodontics, Yonsei University Dental hospital, Seoul, Korea. The inclusion criterias were as follows: (1) adult patients (over 17 years), (2) four premolars were extracted (one tooth per quadrant), (3) upper and lower incisor tips were retracted more than 5 mm, (4) less than 2° changes of mandibular plane angle (Sn-GoMe), (5) pre-treatment and post-treatment lateral cephalograms were present, (6) no severe dentofacial deformity. Among this sample, two groups were selected: Group 1 (controlled tipping group) with less than 1 mm retraction of upper and lower incisor root apex, and more than 10° decrease in upper and lower incisor axis (U1 to SN / IMPA), Group 2 (translation group) with more than 3 mm retraction of upper and lower incisor root apex, and less than 10˚ decrease in upper and lower incisor axis. Group 1 was comprised of 27 patients (6 males, 21 females; mean age at pre-treatment, 24.89 ± 7.36 years) and average treatment time was 27.44 ± 5.46 months. Group 2 was comprised of 26 patients (8 males, 18 females; mean age at pre-treatment, 23.92 ± 4.79 years) and average treatment time was 31.62 ± 9.33 months (Table 1).

All patients were treated with pre-adjusted 0.018-inch slot edgewise brackets in the Roth prescription (Tomy, Tokyo, Japan). After initial leveling & alignment, miniscrews were placed between maxillary and mandibular second premolars and first molars for anchorage reinforcement. Then 0.016 x 0.022 inch stainless steel rectangular archwires were placed. In translation group, additional 10° labial crown torque on the incisor area was added to archwires, if needed. Approximately 150g of retraction force was provided by placing elastic chains (Ormco, Glendora, CA, USA), and the chains were replaced every 4 weeks until space was closed.

Table 1. Demographic features of the subjects

	Tipping group (n=27)	Translation group (n=26)	P-value*
Sex	6 Males, 21 Females	8 Males, 18 Females	
Age (years)	24.89 ± 7.36	23.92 ± 4.79	.580
Treatment duration (months)	27.44 ± 5.46	31.62 ± 9.33	.051

* Independent *t*-tests were performed.

2. Methods and landmarks

Lateral cephalograms were taken using a Cranex 3+ (Soredex, Helsinki, Finland) with a centric occlusion in the natural head position before (T1) and after (T2) treatment. Cephalometric tracing was digitized with using V-ceph program (Osstem Inc., Seoul, Korea). The horizontal reference plane (HRP) was set on sella and oriented 7° below to the sella-nasion line. The vertical reference plane was set to the plane that passed the sella and perpendicular to the HRP. Center of resistance of the upper and lower incisors were estimated to one third of the distance from alveolar crest to root apex in a lateral cephalogram. Cephalometric landmarks, reference planes and measurements are shown in Figure 1, 2.

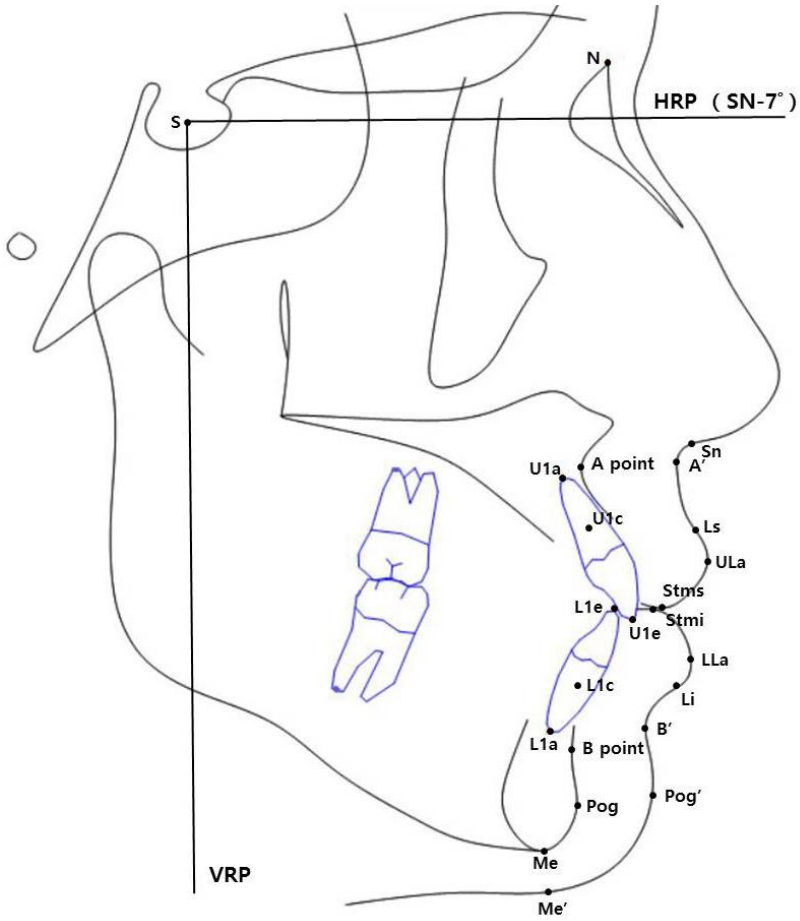

Figure 1. Cephalometric landmarks and reference planes. S, sella; N, nasion; A, A point; B, B point; Pog, pogonion; Me, menton; U1e, upper central incisor edge; U1c, center of resistance of the upper central incisor; U1a, root apex of the upper central incisor; L1e, lower central incisor edge; L1c, center of resistance of the lower central incisor; L1a, root apex of the lower central incisor; Sn, subnasale; A′, soft tissue point A; Ls, labrale superioris; ULa, the most anterior point of upper lip; Stms, stomion superioris; Stmi, stomion inferioris; LLa, the most anterior point of lower lip; Li, labrale inferioris; B′, soft tissue point B; Pog′, soft tissue pogonion; Me′, soft tissue menton; HRP, horizontal reference plane; VRP, vertical reference plane.

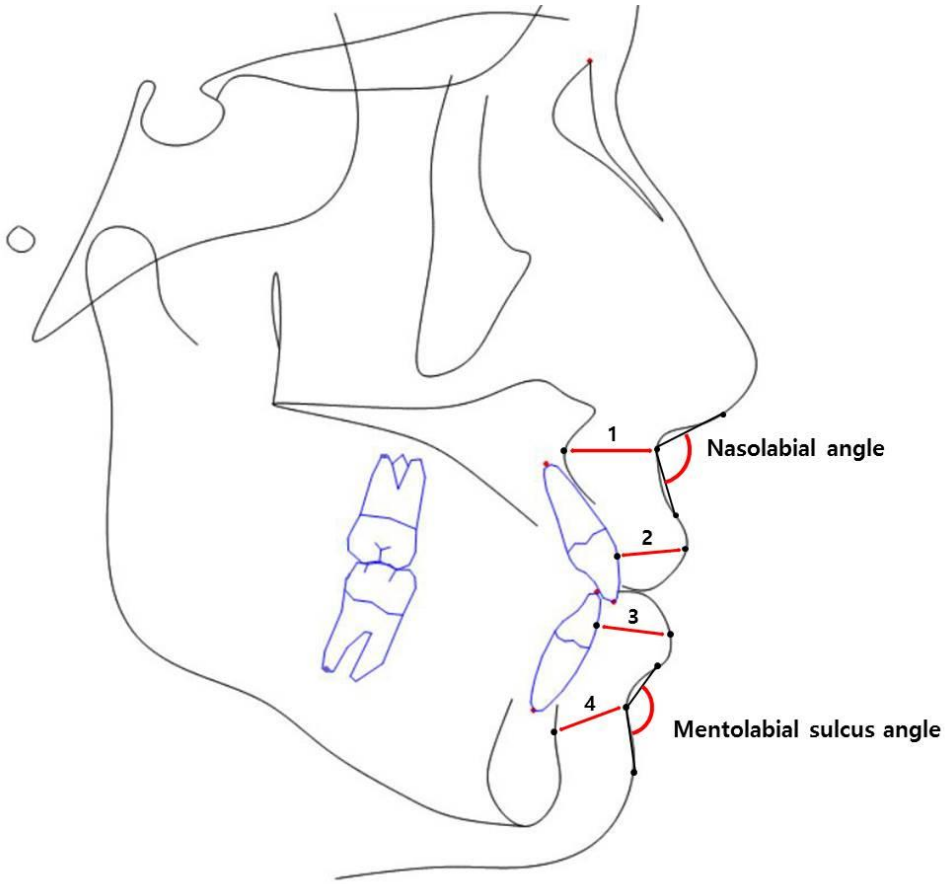

Figure 2. Additional cephalometric measurements. (1) basal upper lip thickness (distance between A point and soft tissue point A); (2) upper lip thickness (shortest distance between labial surface of upper central incisor and ULa); (3) lower lip thickness (shortest distance between labial surface of lower central incisor and LLa); (4) basal lower lip thickness (distance between B point and soft tissue point B).

3. Reliability

All lateral cephalometric tracing and measurements were performed by the same investigator. 1-week after the first tracing, ten samples were randomly selected and retraced. The intra-class correlation coefficient was greater than 0.93 except for the FMA, which was 0.87.

4. Statistical analysis

All statistical analyses were performed using IBM SPSS Statistics software for Windows, version 20.0 (SPSS Inc., Chicago, IL, USA). The Shapiro-Wilk test was used to confirm normality of the data distribution. The independent *t*-tests were used to compare the difference of variables in T1 and T2 and treatment changes (T1-T2) between the two groups. And Pearson's correlation coefficients were calculated to verify the association between lip profile changes and other variables.

III. Results

1. Comparison of pre-treatment cephalometric variables: between tipping and translation groups

No difference was found in pre-treatment skeletal variables between the tipping and translation groups (Table 2). However, there were significant differences in some pre-treatment dental variables. U1 to SN was 110.99° ± 6.17° in tipping group, and 104.79° ± 6.46° in translation group, and showed significant differences ($p < 0.01$). Interincisal angle was 107.89° ± 7.54° in tipping group, and 117.22° ± 7.51° in translation group, and showed significant differences ($p < 0.001$).

Table 2. Comparison of pre-treatment cephalometric variables between tipping and translation groups

Variable	Tipping group		Translation group		P Value
	Mean	SD	Mean	SD	
SNA (°)	81.42	3.49	81.25	3.38	.861
SNB (°)	77.46	3.55	77.21	4.02	.807
ANB difference (°)	3.95	2.19	4.04	2.34	.886
Wits (mm)	-0.86	3.00	-1.47	3.27	.480
SN-GoMe (°)	37.45	6.33	38.49	6.52	.560
FMA (°)	28.33	5.61	29.84	5.77	.338
Occlusal plane to GoMe (°)	18.18	4.44	17.81	4.05	.751
U1 to SN (°)	110.99	6.17	104.79	6.46	.001**
IMPA (°)	103.69	7.00	99.52	6.01	.024
Interincisal angle (°)	107.89	7.54	117.22	7.51	.000***
Nasolabial angle (°)	96.70	10.04	99.35	11.99	.385
Mentolabial sulcus angle (°)	134.40	11.31	135.95	13.99	.659

U1, upper central incisor

* $P < 0.05$; ** $P < 0.01$; *** $P < 0.001$

2. Comparison of the skeletal changes during the treatment

Comparing the skeletal changes during the treatment period between the two groups, there were significant differences in SNB ($p < 0.001$), ANB difference ($p < 0.001$), Wits ($p < 0.01$), VRP-A ($p < 0.001$), and VRP-B ($p < 0.001$) (Table 3). SNB increased 0.02° ± 0.31° in tipping group, and decreased 0.83° ± 0.63° in translation group. ANB increased 0.06° ± 0.37° in tipping group, and increased 0.81° ± 0.63° in translation group. Wits appraisal decreased 0.60° ± 1.56° in tipping group, and increased 1.06° ± 1.81° in translation group. A point and B point moved posteriorly 0.06 ± 0.37 mm and 0.05 ± 0.75 mm, respectively, in tipping group, and 0.61 ± 0.49 mm and 1.98 ± 1.18 mm, respectively, in translation group. Other skeletal changes did not show any significant differences between the two groups.

Table 3. Comparison of the skeletal changes during treatment period

	T1		T2		T1-T2		
	Tipping group	Translation group	Tipping group	Translation group	Tipping group	Translation group	
Skeletal variable	Mean(±SD)	Mean(±SD)	Mean(±SD)	Mean(±SD)	Mean(±SD)	Mean(±SD)	P value
SNA (°)	81.42(±3.49)	81.25(±3.38)	81.49(±3.51)	81.23(±3.48)	-0.08(±0.18)	0.02(±0.31)	.161
SNB (°)	77.46(±3.55)	77.21(±4.02)	77.48(±3.57)	76.38(±4.21)	-0.02(±0.35)	0.83(±0.63)	.000***
ANB difference (°)	3.95(±2.19)	4.04(±2.34)	4.01(±2.33)	4.85(±2.35)	-0.06(±0.37)	-0.81(±0.63)	.000***
Wits (mm)	-0.86(±3.00)	-1.47(±3.27)	-1.46(±3.27)	-0.42(±3.90)	0.60(±1.56)	-1.06(±1.81)	.001**
SN-GoMe (°)	37.45(±6.33)	38.49(±6.52)	37.34(±6.10)	38.47(±6.98)	0.11(±0.76)	0.02(±1.00)	.705
FMA (°)	28.33(±5.61)	29.84(±5.77)	28.25(±5.35)	29.85(±6.22)	0.08(±0.78)	-0.01(±1.04)	.716
Occlusal plane to GoMe (°)	18.18(±4.44)	17.81(±4.05)	17.22(±4.34)	17.07(±4.85)	0.96(±1.67)	0.74(±1.75)	.636
VRP-A (mm)	67.99(±4.04)	69.49(±6.37)	67.93(±4.06)	68.88(±6.26)	0.06(±0.37)	0.61(±0.49)	.000***
VRP-B (mm)	59.20(±7.19)	60.38(±9.66)	59.15(±7.23)	58.40(±9.71)	0.05(±0.75)	1.98(±1.18)	.000***
VRP-Pog (mm)	57.54(±8.35)	57.93(±10.96)	57.80(±8.60)	57.82(±11.24)	-0.26(±1.09)	0.11(±1.35)	.275
HRP-A (mm)	56.46(±3.53)	56.93(±4.33)	56.45(±3.52)	56.90(±4.19)	0.01(±0.33)	0.03(±0.55)	.865
HRP-B (mm)	100.86(±5.35)	100.54(±6.11)	100.49(±5.07)	99.58(±6.41)	0.38(±0.90)	0.96(±1.52)	.095
HRP-Pog (mm)	115.73(±6.79)	116.60(±6.97)	115.56(±6.50)	116.35(±7.37)	0.17(±1.01)	0.25(±1.07)	.791

T1, pre-treatment; T2, post-treatment; HRP, horizontal reference plane; VRP, vertical reference plane

* $p < 0.05$; ** $p < 0.01$; *** $p < 0.001$

3. Comparison of the dental changes during the treatment

Amounts of retraction of the upper and lower incisal edges were near 7 mm in both groups, and didn't show significant differences between the two groups (Table 4). However, in most of other dental variables, there were significant differences. U1 to SN and IMPA decreased 16.20 ± 3.64° and 18.21 ± 4.80°, respectively, in tipping group, and 3.42 ± 4.13° and 4.50 ± 3.23°, respectively, in translation group, which showed significant differences ($p < 0.001$).

Amounts of retraction of the root apex of the upper incisor and lower incisor were 0.33 ± 0.38 mm and 0.26 ± 0.45 mm, respectively, in tipping group, and 5.02 ± 1.32 mm and 5.31 ± 1.46 mm, respectively, in translation group, and showed significant differences ($p < 0.001$).

Vertical movement of the root apex of the upper and lower incisor also showed significant differences. The root apex of the upper incisor moved 1.18 ± 1.23 mm upward in tipping group, and -0.08 ± 1.35 mm downward in translation group ($p < 0.01$). The root apex of the lower incisor moved 0.54 ± 1.28 mm downward in tipping group, and 1.48 ± 1.62 mm upward in translation group ($p < 0.001$).

Table 4. Comparison of the dental changes during treatment period

	T1		T2		T1-T2		
	Tipping group	Translation group	Tipping group	Translation group	Tipping group	Translation group	
Dental variable	Mean(±SD)	Mean(±SD)	Mean(±SD)	Mean(±SD)	Mean(±SD)	Mean(±SD)	P value
U1 to SN (º)	110.99(±6,17)	104.79(±6.46)	94.79(±5.77)	101.37(±5.78)	16.20(±3.64)	3.42(±4.13)	.000***
IMPA (º)	103.69(±7.00)	99.52(±6.01)	85.48(±6.38)	95.03(±7.07)	18.21(±4.80)	4.50(±3.23)	.000***
Interincisal angle (º)	107.89(±7.54)	117.22(±7.51)	142.42(±7.17)	125.16(±8.17)	-34.53(±6.50)	-7.94(±5.11)	.000***
Overjet (mm)	3.74(±1.70)	3.46(±1.67)	3.85(±0.65)	3.70(±0.64)	-0.12(±1.58)	-0.25(±1.67)	.775
Overbite (mm)	0.80(±1.86)	1.28(±1.87)	2.51(±1.02)	2.39(±1.10)	-1.72(±1.65)	-1.11(±1.83)	.212
VRP-U1e (mm)	76.29(±5.67)	75.69(±8.20)	68.86(±5.95)	68.63(±7.77)	7.44(±1.66)	7.06(±1.45)	.390
VRP-U1c (mm)	68.62(±4.81)	69.33(±7.04)	65.86(±5.15)	63.60(±6.87)	2.76(±1.05)	5.73(±1.08)	.000***
VRP-U1a (mm)	64.16(±4.44)	65.70(±6.67)	63.83(±4.55)	60.68(±6.56)	0.33(±0.38)	5.02(±1.32)	.000***
VRP-L1e (mm)	72.33(±6.17)	72.65(±8.44)	65.63(±5.83)	65.62(±7.74)	6.71(±1.18)	7.03(±1.40)	.367
VRP-L1c (mm)	63.03(±6.38)	63.69(±9.12)	60.32(±6.56)	57.94(±8.59)	2.71(±0.88)	5.75(±1.37)	.000***
VRP-L1a (mm)	56.94(±6.87)	58.39(±9.66)	56.68(±7.00)	53.08(±9.21)	0.26(±0.45)	5.31(±1.46)	.000***
HRP-U1e (mm)	82.58(±4.90)	84.10(±5.74)	82.68(±4.62)	83.21(±5.58)	-0.10(±1.70)	0.89(±1.61)	.035*
HRP-U1c (mm)	67.26(±3.94)	67.73(±5.07)	66.65(±4.04)	67.38(±4.07)	0.61(±1.07)	0.36(±1.08)	.393
HRP-U1a (mm)	59.69(±3.66)	59.32(±4.56)	58.50(±3.60)	59.40(±4.53)	1.18(±1.23)	-0.08(±1.35)	.001**
HRP-L1e (mm)	81.48(±4.86)	82.01(±5.91)	79.34(±4.50)	79.97(±5.57)	2.14(±1.65)	2.04(±1.48)	.829
HRP-L1c (mm)	91.57(±4.69)	92.46(±5.84)	91.09(±4.52)	90.73(±5.87)	0.48(±1.14)	1.73(±1.37)	.001**
HRP-L1a (mm)	97.36(±4.90)	98.30(±5.97)	97.90(±4.77)	96.82(±6.01)	-0.54(±1.28)	1.48(±1.62)	.000***

T1, pre-treatment; T2, post-treatment; U1, upper central incisor; HRP, horizontal reference plane; VRP, vertical reference plane; U1e, upper central incisor edge; U1c, center of resistance of the upper central incisor; U1a, root apex of the upper central incisor; L1e, lower central incisor edge; L1c, center of resistance of the lower central incisor; L1a, root apex of the lower central incisor

* $p < 0.05$; ** $p < 0.01$; *** $p < 0.001$

4. Comparison of the soft tissue changes during the treatment

There were no significant differences in retraction amounts of Ls (labrale superioris), and ULa (most anterior point of upper lip) between the two groups. However, there were significant differences in retraction amounts of LLa (most anterior point of lower lip), and Li (labrale inferioris) ($p < 0.05$). LLa and Li were retracted 3.96 ± 1.27 mm and 2.81 ± 1.71 mm, respectively, in tipping group and 5.07 ± 2.34 mm and 4.04 ± 2.10 mm, respectively, in translation group.

Posterior movement of soft tissue point A and soft tissue point B were 0.61 ± 0.59 mm and 1.25 ± 1.90 mm, respectively, in tipping group, and 1.10 ± 0.70 mm and 3.25 ± 1.92 mm, respectively, in translation group, and both showed significant differences ($p < 0.01$).

There was significant difference in changes of nasolabial angle between two groups. In tipping group, mentolabial sulcus angle increased 5.89 ± 5.88°, whereas in translation group, mentolabial sulcus angle decreased 8.13 ± 6.32° ($p < 0.001$).

Table 5. Comparison of the soft tissue changes during treatment period

	T1		T2		T1-T2		
	Tipping group	Translation group	Tipping group	Translation group	Tipping group	Translation group	
Soft tissue variable	Mean(±SD)	Mean(±SD)	Mean(±SD)	Mean(±SD)	Mean(±SD)	Mean(±SD)	P value
VRP-Sn (mm)	83.08(±4.05)	83.58(±7.25)	82.83(±4.05)	83.20(±7.26)	0.25(±0.29)	0.39(±0.47)	.170
VRP-A' (mm)	81.76(±4.06)	82.65(±7.28)	81.15(±4.14)	81.54(±7.12)	0.61(±0.59)	1.10(±0.70)	.008**
VRP-Ls (mm)	85.82(±4.78)	86.21(±8.46)	83.23(±4.71)	83.30(±8.05)	2.59(±0.98)	2.92(±1.29)	.308
VRP-ULa (mm)	87.53(±4.78)	87.73(±8.46)	84.91(±4.95)	84.58(±8.06)	2.62(±1.27)	3.15(±1.42)	.157
VRP-Stms (mm)	80.54(±5.37)	80.48(±8.11)	75.29(±5.45)	75.11(±7.95)	5.25(±1.37)	5.37(±2.16)	.800
VRP-Stmi (mm)	79.25(±5.23)	79.46(±8.56)	73.46(±5.20)	73.10(±8.00)	5.79(±1.56)	6.37(±2.22)	.276
VRP-LLa (mm)	84.44(±5.46)	84.77(±9.48)	80.48(±5.60)	79.70(±8.39)	3.96(±1.27)	5.07(±2.34)	.036*
VRP-Li (mm)	79.32(±5.86)	79.39(±9.77)	76.51(±5.92)	75.35(±8.95)	2.81(±1.71)	4.04(±2.10)	.024*
VRP-B' (mm)	74.02(±6.25)	74.88(±9.35)	72.77(±6.42)	71.63(±9.36)	1.25(±1.46)	3.25(±1.92)	.000***
VRP-Pog' (mm)	69.75(±8.29)	70.03(±10.76)	70.07(±8.28)	69.98(±10.96)	-0.32(±0.92)	0.06(±1.32)	.232
HRP-Sn (mm)	54.53(±3.97)	54.99(±4.02)	54.65(±3.91)	54.96(±4.07)	-0.12(±0.51)	0.04(±0.73)	.369
HRP-A' (mm)	56.50(±3.93)	56.66(±4.21)	56.62(±3.84)	56.71(±4.03)	-0.11(±0.52)	-0.05(±0.45)	.659
HRP-Ls (mm)	68.26(±5.08)	68.53(±5.39)	69.09(±5.15)	69.84(±5.27)	-0.83(±1.16)	-1.31(±1.37)	.182
HRP-upper lip (mm)	74.83(±4.83)	74.64(±5.52)	74.68(±4.75)	75.10(±5.91)	0.15(±0.80)	-0.46(±1.14)	.028*
HRP-Stms (mm)	80.58(±4.99)	81.30(±5.81)	80.33(±4.56)	81.17(±5.60)	0.25(±1.50)	0.13(±1.12)	.733
HRP-Stmi (mm)	81.23(±4.73)	82.05(±5.62)	80.35(±4.42)	81.06(±5.41)	0.88(±1.54)	0.99(±1.11)	.764
HRP-lower lip (mm)	89.76(±5.63)	90.66(±6.68)	88.59(±4.88)	89.66(±6.55)	1.17(±2.33)	1.00(±1.42)	.759
HRP-Li (mm)	94.82(±4.73)	95.90(±7.11)	93.10(±4.57)	93.90(±6.91)	1.72(±1.96)	2.00(±1.56)	.567
HRP-B' (mm)	100.93(±5.72)	101.32(±7.88)	100.05(±5.44)	99.17(±8.54)	0.88(±1.48)	2.15(±2.12)	.015*
HRP-Pog' (mm)	115.74(±6.74)	116.87(±7.14)	115.91(±6.70)	116.48(±7.84)	-0.17(±1.08)	0.39(±1.54)	.133

T1, pre-treatment; T2, post-treatment; HRP, horizontal reference plane; VRP, vertical reference plane

* $p < 0.05$; ** $p < 0.01$; *** $p < 0.001$

Table 5. Continued

	T1		T2		T1-T2		
	Tipping group	Translation group	Tipping group	Translation group	Tipping group	Translation group	
Soft tissue variable	Mean(±SD)	Mean(±SD)	Mean(±SD)	Mean(±SD)	Mean(±SD)	Mean(±SD)	P value
Basal upper lip thickness (mm)	13.80(±1.49)	13.29(±2.03)	13.27(±1.57)	12.67(±2.12)	0.53(±0.55)	0.62(±0.56)	.548
Upper lip thickness (mm)	11.11(±1.98)	11.34(±2.34)	14.03(±2.08)	14.74(±2.84)	-2.91(±1.66)	-3.40(±1.42)	.253
Lower lip thickness (mm)	14.19(±2.29)	14.10(±2.28)	15.56(±1.69)	15.73(±2.36)	-1.37(±1.55)	-1.63(±1.89)	.576
Basal lower lip thickness (mm)	15.23(±2.41)	14.92(±2.10)	13.72(±1.77)	13.85(±2.22)	1.51(±1.63)	1.07(±1.66)	.339
Nasolabial angle (°)	96.70(±10.04)	99.35(±11.99)	105.89(±8.47)	106.67(±11.83)	-9.19(±4.61)	-7.31(±5.06)	.164
Mentolabial sulcus angle (°)	134.40(±11.31)	135.95(±13.99)	140.29(±11.56)	127.81(±13.50)	-5.89(±5.88)	8.13(±6.32)	.000***

T1, pre-treatment; T2, post-treatment; HRP, horizontal reference plane; VRP, vertical reference plane

* $p < 0.05$; ** $p < 0.01$; *** $p < 0.001$

5. Pearson's correlation coefficients between lip profile changes and other variables

The posterior movement of ULa was significantly positively correlated with the movement of U1e (r=0.30; $p<0.05$), and the movement of U1a (r=0.28; $p<0.05$). And the posterior movement of soft tissue point A showed strong positive correlation with the movement of A point (r=0.59; $p<0.001$), and the movement of U1a (r=0.47; $p<0.001$) (Table 6).

The posterior movement of LLa was significantly positively correlated with the movement of L1e (r=0.40; $p<0.01$), movement of L1a (r=0.39; $p<0.01$) and the movement of U1e (r=0.36; $p<0.01$). And the posterior movement of soft tissue point B showed strong positive correlation with the movement of B point (r=0.69; $p<0.001$), and the movement of L1a (r=0.57; $p<0.001$) (Table 6).

The posterior movement of ULa, LLa, soft tissue point A, soft tissue point B showed no significant correlation with the initial thickness of upper and lower lip, and the initial basal thickness of upper and lower lip (Table 7).

Table 6. Pearson's correlation coefficients between lip profile changes and other variables

Lip profile changes	Other variables		
VRP-A'	VRP-A 0.592***	VRP-U1a 0.474***	
VRP-ULa	VRP-U1e 0.302*	VRP-U1a 0.280*	
VRP-LLa	VRP-L1e 0.397**	VRP-L1a 0.387**	VRP-U1e 0.355**
VRP-B'	VRP-B 0.692***	VRP-L1a 0.571***	

VRP, vertical reference plane; ULa, the most anterior point of upper lip; LLa, the most anterior point of lower lip; U1e, upper central incisor edge; U1a, root apex of the upper central incisor; L1e, lower central incisor edge; L1a, root apex of the lower central incisor
* P < 0.05; ** P < 0.01; *** P < 0.001

Table 7. Pearson's correlation coefficients between lip profile changes and initial lip thickness

Lip profile changes	Lip thickness	
VRP-A'	Upper lip thickness 0.124	Basal upper lip thickness 0.005
VRP-ULa	Upper lip thickness 0.108	Basal upper lip thickness 0.091
VRP-LLa	Lower lip thickness 0.265	Basal lower lip thickness 0.194
VRP-B'	Lower lip thickness -0.075	Basal lower lip thickness 0.278

VRP, vertical reference plane; ULa, the most anterior point of upper lip; LLa, the most anterior point of lower lip
* P < 0.05; ** P < 0.01; *** P < 0.001

IV. Discussion

Many previous studies have been published, which examined the soft tissue changes, especially lips, after extraction of 4 premolars. However, most of them used conventional anchorage system rather than maximum anchorage like skeletal anchorage system (Bravo, 1994; Diels, et al., 1995). Although there were a few studies using maximum anchorage during anterior teeth retraction, they only focused on the amount of retraction, not the type of retraction (Hayashida, et al., 2011; Kim, et al., 2017). In this study, we evaluated the changes of hard and soft tissues depending on the type of anterior teeth retraction, controlled tipping and translation, after premolar extraction. With the relation to our hypothesis, there were significant differences in changes of hard and soft tissues between the two groups, especially at the region near to the root apex of the upper and lower incisors.

We included only the adult patients above 17-year-old age, to exclude the influence of the growth on soft tissue profile during treatment. And also we excluded the patients that the change of mandibular plane angle during treatment was more than 2 º to rule out the vertical influence. Vertical changes such as mandibular jaw rotation could affect the antero-posterior relationships (Lee and Kim, 2018), and this would make it hard to interpret the data. We used miniscrews as skeletal anchorage for maximum retraction of anterior teeth. And in translation group, we used arch wires

with additional 10° torque on the incisor area for true bodily translation of anterior teeth (Kim, et al., 2014).

In both groups, average retraction amounts of upper and lower incisor edge were near 7 mm with no significant differences. In tipping group, changes of U1 to SN and IMPA were 16.20° and 18.21°, respectively, and retraction amounts of root apex of upper and lower incisors were 0.33 mm and 0.26 mm, respectively, implying that controlled tipping occurred. In translation group, changes of U1 to SN and IMPA were 3.24° and 4.50°, respectively, and retraction amounts of root apex of upper and lower incisors were 5.02 mm and 5.31 mm, respectively, implying that the almost bodily translation of anterior teeth was achieved (Table 4). In previous studies which measured the movement of root apex of the incisors, retraction amounts of root apex of the upper and lower incisor were 1.20 mm and 1.10 mm, respectively (Sharma, 2010), and 2.59mm and 4.11 mm, respectively (Kim, et al., 2017). Compared to these previous studies, much more retraction of the root apex of the incisors occurred in the present study.

Horizontal changes of A point and B point during treatment showed significant differences between the two groups ($p < 0.001$). A point moved more posteriorly in translation group (0.61 mm) than tipping group (0.06 mm) and B point moved much more posteriorly in translation group (1.98 mm) than tipping group (0.05 mm), and this led to the decrease of SNB and increase of ANB and Wits appraisal in

translation group. This result assumed to be derived from much more posterior movement of root apex of upper and lower incisor, observed in translation group. This implies that A point and B point can be changed by the root movement of the upper and lower incisor. And this finding correspond to the previous study using CBCT, which found out that the B point could be remodeled during orthodontic treatment (Zhang, et al., 2015). However, the amount of posterior movement of B point was significantly larger than A point in spite of almost same retraction amounts of root apex of upper and lower incisor. One possible explanation for this different behavior of A point and B point is the difference of initial horizontal distance from root apex of upper incisor to A point and from root apex of lower incisor to B point. Initial horizontal distance, in terms of initial horizontal bone thickness, showed significant difference between A point and B point ($p < 0.001$). Horizontal bone thickness of A point to root apex of upper incisor was 3.79 ± 2.09 mm and B point to root apex of lower incisor was 1.99 ± 1.65 mm. Because of the small distance from the root apex of lower incisor to B point, remodeling of B point could have occurred much easier than A point.

There was significant difference in horizontal movement of soft tissue point A and soft tissue point B between the two groups ($p < 0.001$). Soft tissue point A and soft tissue point B moved more posteriorly in translation group (1.10 mm and 3.25 mm, respectively) than tipping group (0.61 mm and 1.25 mm, respectively) (Figure 3).

Since the retraction amount of upper and lower incisor edges were almost same in both groups, this behavior of soft tissue A point and soft tissue B point is likely to be the result of the more posterior movement of A point and B point in translation group.

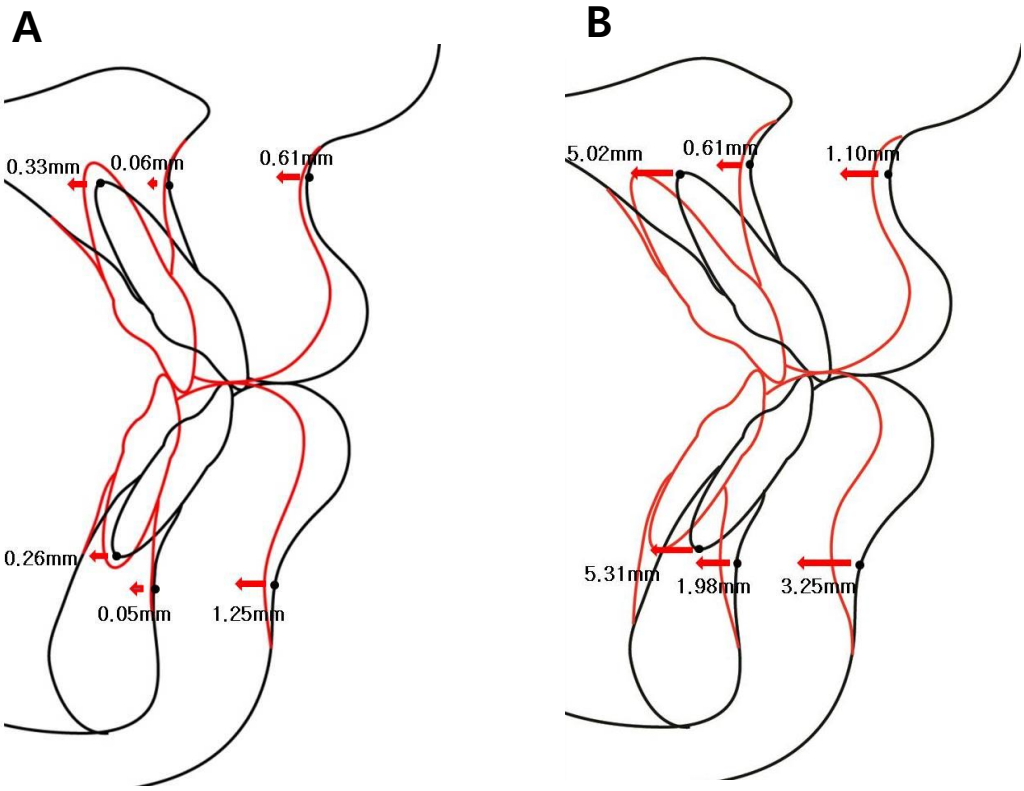

Figure 3. Comparison of treatment changes between the two groups. (A) Tipping group; (B) translation group

And this different movement of soft tissue B point between the two groups also led to the significant difference in the change of mentolabial sulcus angle. In tipping group, mentolabial sulcus angle increased 5.89º, and in contrast, in translation group, mentolabial sulcus angle decreased 8.13º, which was caused by the more posterior movement of soft tissue point B. Mentolabial sulcus and position of soft tissue point B are considered to be one of the most important factors in assessment of soft tissue profile because they affect the esthetic features of both lower lip and chin. Huang et al. (Huang and Li, 2015) reported that in the study of evaluation of post-treatment facial esthetics after extraction of four first premolars, both orthodontists and laypersons considered the relative position of soft tissue point B and mentolabial sulcus angle as the most significant factors affecting the facial esthetics. They resulted that the increase of mentolabial sulcus depth improved the evaluation of soft tissue esthetics, rather than flat sulcus. In this perspective, the translational anterior teeth retraction may lead to the more esthetic outcomes in some cases.

Posterior movement of ULa and LLa was mostly correlated with the horizontal movement of U1e and L1e, respectively. This finding is different from the previous study (Hayashida, et al., 2011) which resulted that horizontal movement of lower lip was mostly correlated with horizontal movement of the incisal edge of the upper incisor. This different outcome is thought to be the difference of initial overjet value in study sample which was 8.17 mm in the study by Hayashida et al., in contrast to 3.60 mm in the present study.

Posterior movement of soft tissue point A was highly correlated with the movement of A point, followed by the movement of U1a. And similarly, soft tissue point B was highly correlated with the movement of B point, followed by the movement of L1a. These findings suggest that we can intentionally retract the soft tissue point A and B by control the amount of root movement of the upper and lower incisors to induce the bone modeling of A point and B point.

There was no significant correlation between posterior movement of lips and initial lip thickness. Hayashida et el. reported that there was no correlation between upper lip changes and initial upper lip thickness, and there was weak correlation between lower lip changes and initial lower lip thickness. Whereas, Oliver reported that thicker upper lip had significantly less response to incisor retraction than thinner upper lip (Oliver, 1982). The reason why these results vary from one study to another might be that there are too many factors contributing to the lip profiles. Furthermore, since head posture or lip strain can affect lip thickness, these differences while taking the lateral cephalogram before and after treatment might have influenced the interpretation of data. Therefore, to verify the influence of lip thickness on lip profile changes, more refined studies are needed.

In treatment planning of the patients with the issues of soft tissue esthetics, first, we have to establish the specific soft tissue-based treatment goal. Since the esthetic standard is subjective, there should be a careful consultation with the patients to

meet their special needs. Once after the soft tissue goal is established, we have to determine the proper type of tooth movement to achieve this. Thereafter, finally we design the biomechanical force systems to accomplish the wanted type of tooth movement. This series of process is basically essential to every treatment planning. And this study might help predicting soft tissue changes after retraction of anterior teeth depending on the type of tooth movement.

There are a few limitations existing in this study, which should be considered when applying these findings. First, prediction of soft tissue changes after tooth movement varies considerably depending on age, gender, dentofacial morphology, and ethnicity (Brock, et al., 2005; Talass, et al., 1987; Yogosawa, 1990). Second, this study was designed retrospectively, and therefore temporal soft tissue changes within the patients such as body mass index (BMI) were not controlled (Dong, et al., 2012). In addition, since the retention period was not included, there might be some considerable changes after treatment. These points should be considered in further studies.

V. Conclusion

In this study, we compared the hard and soft tissue changes after 4 premolars extraction depending on the type of the anterior teeth retraction and the outcomes were as follows;

1. The root apex of the upper and lower incisors showed retractions of 0.33 mm and 0.26 mm, respectively, in tipping group, and 5.02 mm and 5.31 mm, respectively, in translation group; the differences between the two groups were significant ($p < 0.001$).

2. The A point and B point showed retractions of 0.06 mm and 0.05 mm, respectively, in tipping group, and 0.61 mm and 1.98 mm, respectively, in translation group; the differences between the two groups were significant ($p < 0.001$).

3. The soft tissue point A and soft tissue point B showed retractions of 0.61 mm and 1.25 mm, respectively, in tipping group, and 1.10 mm and 3.25 mm in translation group; the differences between the two groups were significant ($p < 0.01$).

4. The mentolabial sulcus angle increased 5.89° in tipping group, and decreased 8.13° in translation group; the differences between the two groups were significant ($p < 0.001$).

5. Retraction of soft tissue point A and B was correlated with the movement of A point and B point, respectively ($p < 0.001$), and the movement of the root apex of the upper and lower incisor, respectively ($p < 0.001$).

This result suggests that the type of anterior teeth retraction affects the changes of soft tissue profile. This study may provide the guidelines to orthodontists in deciding the type of tooth movement during anterior teeth retraction.

VI. References

Bravo LA: Soft tissue facial profile changes after orthodontic treatment with four premolars extracted. *Angle Orthod* 64(1): 31-42, 1994.

Brock RA, 2nd, Taylor RW, Buschang PH, Behrents RG: Ethnic differences in upper lip response to incisor retraction. *Am J Orthod Dentofacial Orthop* 127(6): 683-691; quiz 755, 2005.

Caplan MJ, Shivapuja PK: The effect of premolar extractions on the soft-tissue profile in adult African American females. *Angle Orthod* 67(2): 129-136, 1997.

Diels RM, Kalra V, DeLoach N, Jr., Powers M, Nelson SS: Changes in soft tissue profile of African-Americans following extraction treatment. *Angle Orthod* 65(4): 285-292, 1995.

Dong Y, Huang L, Feng Z, Bai S, Wu G, Zhao Y: Influence of sex and body mass index on facial soft tissue thickness measurements of the northern Chinese adult population. *Forensic Sci Int* 222(1-3): 396 e391-397, 2012.

Hayashida H, Ioi H, Nakata S, Takahashi I, Counts AL: Effects of retraction of anterior teeth and initial soft tissue variables on lip changes in Japanese adults. *Eur J Orthod* 33(4): 419-426, 2011.

Hershey HG: Incisor tooth retraction and subsequent profile change in postadolescent female patients. *Am J Orthod* 61(1): 45-54, 1972.

Huang YP, Li WR: Correlation between objective and subjective evaluation of profile in bimaxillary protrusion patients after orthodontic treatment. *Angle Orthod* 85(4): 690-698, 2015.

Kim K, Choi SH, Choi EH, Choi YJ, Hwang CJ, Cha JY: Unpredictability of soft tissue changes after camouflage treatment of Class Ⅱ division 1 malocclusion with maximum anterior retraction using miniscrews. *Angle Orthod* 87(2): 230-238, 2017.

Kim SJ, Kim JW, Choi TH, Lee KJ: Combined use of miniscrews and continuous arch for intrusive root movement of incisors in Class Ⅱ division 2 with gummy smile. *Angle Orthod* 84(5): 910-918, 2014.

Kuroda S, Yamada K, Deguchi T, Kyung HM, Takano-Yamamoto T: Class II malocclusion treated with miniscrew anchorage: comparison with traditional orthodontic mechanics outcomes. *Am J Orthod Dentofacial Orthop* 135(3): 302-309, 2009.

Lee KJ, Kim SJ: Advanced biomechanics for total arch movement and non-surgical treatment for hyperdivergent faces. *Semin Orthod*, 2018.

Oliver BM: The influence of lip thickness and strain on upper lip response to incisor retraction. *Am J Orthod* 82(2): 141-149, 1982.

Sharma JN: Skeletal and soft tissue point A and B changes following orthodontic treatment of Nepalese Class I bimaxillary protrusive patients. *Angle Orthod* 80(1): 91-96, 2010.

Talass MF, Talass L, Baker RC: Soft-tissue profile changes resulting from retraction of maxillary incisors. *Am J Orthod Dentofacial Orthop* 91(5): 385-394, 1987.

Yogosawa F: Predicting soft tissue profile changes concurrent with orthodontic treatment. *Angle Orthod* 60(3): 199-206, 1990.

Zhang S, Chen W, Ding S, Han H, Yu Z: Skelate changes induced by orthodontic in class II division 1 by CBCT: a long-term follow-up prospective study. *Int J Clin Exp Med* 8(7): 11312-11316, 2015.

국문요약

소구치 발치 증례에서 전치 경사이동과 치체이동이 연조직 안모에 미치는 영향

<지도교수: 이 기 준>

연세대학교 대학원 치의학과

백 원 경

본 연구에서는 네 개 소구치 발치 후 최대고정원을 이용하여 전치부를 후방견인할 시 경사이동 및 치체이동과 같은 치아 이동 유형에 따른 연조직의 변화양상을 비교하고자 하였다.

본 후향적 연구는 네 개 소구치를 발치하고 최대고정원을 이용하여 전치부를 후방견인한 환자들을 대상으로 하였다. 대상들은 전치부 후방견인시의 치아이동유형에 따라 두 군으로 나뉘었다. 경사이동군(tipping group)은 27명, 치체이동군(translation group)은 26명으로 구성되었다. 치료 전후에 촬영한 측모두부방사선사진을 이용하여 경조직 및 연조직의 변화를 평가하였다.

상악과 하악 전치의 치근단은 경사이동군에서 각각 0.33 mm, 0.26 mm 후방견인 되었고, 치체이동군에서는 각각 5.02 mm, 5.31 mm 후방견인 되었으며, 두 그룹간의 유의한 차이가 있었다($p<0.001$). B point는 경사이동군에서 0.05 mm 후방견인 되었고, 치체이동군에서는 1.98 mm 후방견인 되었으며, 두 그룹간 유의한 차이를 보였다($p<0.001$).

Soft tissue point A와 soft tissue point B는 경사이동군에서 각각 0.61 mm, 1.25 mm 후방견인 되었고, 치체이동군에서는 각각 1.10 mm, 3.25 mm 후방견인 되었으며, 두 그룹간 유의한 차이를 보였다($p<0.01$). Mentolabial sulcus angle은 경사이동군에서 5.89° 증가한 것에 반해, 치체이동군에서는 8.13° 감소하였고, 두 그룹간 유의한 차이를 보였다($p<0.001$).

본 연구결과를 통해 전치부의 후방견인 유형이 연조직 변화 양상에 영향을 미치는 것을 확인할 수 있었다. 본 연구는 전치부 후방견인시 교정의들이 치아이동유형을 결정하는데 참고가 될 수 있을 것이다.

핵심이 되는 말: 전치부 후방견인, 경사이동, 치체이동, 연조직 변화