Usefulness of false profile view for screening of ischiofemoral impingement

Dae kyung Kwak

Department of Medicine

The Graduate School, Yonsei University

Usefulness of false profile view for screening of ischiofemoral impingement

Directed by Professor Woo suk Lee

The Master's Thesis submitted
to the Department of Medicine,
the Graduate School of Yonsei University

Dae kyung Kwak

June 2018

This certifies that the Master's Thesis
of Dae kyung Kwak is approved.

[Signature]

Thesis Supervisor : Woo suk Lee

[Signature]

Thesis Committee Member#1 : Sungjun Kim

[Signature]

Thesis Committee Member#2 : Sang chul Lee

The Graduate School
Yonsei University

June 2018

ACKNOWLEDGEMENTS

My greatest debt is to Professor Woo Suk Lee. As my fellowship mentor, as a great surgeon, I'd like to record here my acknowledgement to him for his guiding, teaching and directing this study. Without him, I might not be here now.

I also want to express my deep gratitude to Professor Sung Jun Kim and Sang Chul Lee. They have always convinced me that my study has its own significance. And they gave a lot of advice and comment as a supervisor of this thesis. Additionally, I wish to thank Professor Je Hyun Yoo for giving generous support for writing this theis.

I am grateful to the Depart of medicine, The graduate school, Yonsei university for continuing my study.

Finally, I should like to express my appreciation to my parents who backed me up while I was working.

<TABLE OF CONTENTS>

ABSTRACT ····· 1

I. INTRODUCTION ····· 3
II. MATERIALS AND METHODS ····· 4
III. RESULTS ····· 8
IV. DISCUSSION ····· 13
V. CONCLUSION ····· 15

REFERENCES ····· 16
ABSTRACT (IN KOREAN) ····· 19

LIST OF FIGURES

Figure 1. Diagnosis by MRI ····· 7
Figure 2. Ischiofemoral space (IFS) ····· 8
Figure 3. ROC curve of each parameter ····· 11
Figure 4. Cut off value of IFS in false profile view ····· 12

LIST OF TABLES

Table 1. Patients characteristics of IFI and control group ····· 7
Table 2. IFS in false profile view and hip AP view ····· 10
Table 3. IFS and quadratus femoris space (QFS) in MRI ····· 10
Table 4. Correlated between MRI and measurement in hip AP X-ray ····· 12

ABSTRACT

Usefulness of false profile view
for screening of ischiofemoral impingement

Department of Medicine
The Graduate School, Yonsei University

(Directed by Professor Woo suk Lee)

Purpose: The ischiofemoral impingement is an easily overlooked disease due to its low incidence, which is mainly diagnosed by expensive magnetic resonance image (MRI). The purpose of this study was to evaluate the usefulness of false profile view as a screening test for ischifemoral impingement.

Materials and Methods: From June 2013 to July 2017, 58 patients diagnosed with ischiofemoral impingement were enrolled. 58 patients who matched age, gender and body mass index (BMI) in pairs using propensity score were included as control group. We measured the ischiofemoral space (IFS) between the lateral cortex of ischium and the medial cortex of lesser trochanter in weight bearing hip anteroposterior (AP) view and false profile view. IFS and quadratus femoris space (QFS) were also measured in MRI. The ROC AUC and cutoff point of the IFS were measured on false profile images, and the correlation between IFS and QFS was analyzed in IFS and MRI scans.

Results: In the false profile view and the hip AP view, the IFS was significantly decreased in the ischiofemoral impingement ($P < 0.01$). In the false profile view, ROC AUC (0.967) was higher than ROC AUC of IFS in hip AP view (0.841). Cutoff value for differential diagnosis of IFI in the false profile view was 10.3mm (sensitivity 88.2%, specificity 88.4%). IFS was correlated with IFS ($r=0.744$) QFS ($r=0.740$) in MRI and IFS ($r=0.621$) in hip AP view ($p<0.01$).

Conclusion: False profile view of the hip is considered to be useful for the screening of ischiofemoral impingement before the MRI.

Key words**:** Ischiofemoral impingement, false profile view, ischiofemoral space, quadratus femoris space

Usefulness of false profile view for screening of ischiofemoral impingement

Department of Medicine
The Graduate School, Yonsei University

(Directed by Professor Woo suk Lee)

Dae kyung Kwak

I. INTRODUCTION

Ischiofemoral impingement (IFI) is a rare clinical entity characterized by chronic groin, buttock or atypical hip pain[1]. It has since been considered a consequence of trauma or hip surgical procedures. However, IFI has recently been identified as a source of hip pain without iatrogenic consequence[2]. Although IFI is increasingly being discussed, it remains a poorly recognized problem because symptoms are often nonspecific[3]. Clinically, symptoms may be provoked with the ischiofemoral impingement test, which places the patient's limb in a combined position of extension, adduction and external rotation of the hip joint[4]. Despite its clinical use, symptoms may be confused with other hip and lumbar spine pathology, which may also coexist. Therefore, the diagnosis of IFI generally depends on both clinical and imaging study.

Torriani [5] first described in 2009, ischiofemoral space (IFS) – the shortest distance between the ischial tuberosity and the lesser trochanter and quadratus femoris space (QFS) - the shortest distance of the quadratus femoris muscle, as a parameter of ischiofemoral impingement on magnetic resonance image (MRI) axial cut image. Ischiofemoral impingement is a source of hip pain derived from impingement between the lesser trochanter and the ischium or from entrapment of the quadratus femoris muscle between the 2 structures[5,6]. MRI has been used for standard diagnostic tool of IFI. On the other hand, plain X-ray does not mean much[1,6]. We focus on the definition of the IFS, wondered how to look easily ischial tuberosity and lesser trochanter. Through this study, we wanted to know the usefulness of the false profile view of a screening test of IFI more convenient and easier way than MRI.

II. MATERIALS AND METHODS

This retrospective study received Institutional Review Board approval. We reviewed PACS images of patients who visited our clinic from June 2013 to July 2017 and selected patients who were diagnosed with IFI. The inclusion criteria were among the patients who visited our clinic with hip pain, available MRI image, false profile view and hip standing AP view. The diagnostic criteria for IFI patients were measured by IFS and QFS on T2-weighted axial fat-suppressed images on MRI images as described by Torriani (Fig 1)[5]. 13 mm or less of the IFS and 7 mm or less of the QFS were used as diagnostic criteria.

And no other abnormal finding on MRI images such as bursitis, edematous change and arthritis in hip joint was seen. Patients with previous history of hip surgery, fractures around the hip joint and patients with infectious diseases such as septic arthritis of hip joint were excluded. The final 58 IFI patients were enrolled and 58 patients who matched sex, age and body mass index (BMI) in pairs using propensity score matching system were included as a control group. There is no difference between two groups (Table 1). All patients were taking a hip standing AP view, a false profile view and MRI. Hip standing AP x-ray and MRI were taken with neutral rotation and teardrops of the pelvis should be symmetric as an optimal position. The false profile view was made with the patient in a standing position with the affected hip against the cassette and the pelvis rotated 65° in relation to the back wall stand. The foot on the same side as the affected hip should be positioned so that it is parallel to the cassette. The central beam is then centered on the femoral head, with a tube-to-film distance of approximately 40 in (102 cm)[7]. The mean age of IFI patients was 57.3 ± 13.1 years. and seven male patients fifty-one female patients, lesion site was 30 right and 28 left. In the control group, similar with patient group, mean age was 56.9 ± 17.0 years. Because propensity score matching system was used, male female ratio and lesion site were also same as patient group. IFS was measured in each patient by weight bearing hip standing AP image and false profile image (Fig 2). IFS and QFS were also measured in MRI T2-weighted axial fat-suppressed images. All measurements from X-ray and MRI was measured after random

assignment by two authors. The cutoff value of the IFS measured in the false profile view was calculated and the correlation coefficient (r) between the IFS value measured in the X-ray (hip standing AP view, false profile view), the IFS value measured and the QFS value in the MRI image was measured. The Youden J index, which was used to select the optimum cutoff points for each parameter, is a single statistic that summarizes the performance of a diagnostic test according to values ranging from 0 to 1 (1 indicates perfect test performance). The Youden index (J) was calculated with the following equation: J = sensitivity + specificity – 1. The r values were classified as follows: $0 \leq r < 0.25$, little or no relation; $0.25 \leq r < 0.5$, fair correlation; $0.5 \leq r < 0.75$, moderate to good correlation; and $0.75 \leq r$, very good to excellent correlation. The ROC AUC was measured as a measure of the discriminatory ability and a high AUC value as below can be considered to have a better discriminatory ability. Excellent discrimination, AUC ≥ 0.90; good discrimination, $0.80 \leq$ AUC < 0.90; fair discrimination, $0.70 \leq$ AUC < 0.80; and poor discrimination, AUC < 0.70. As statistical analysis, all data were analyzed SPSS version 23.0 statistical software (SPSS Inc., Chicago, IL, USA).

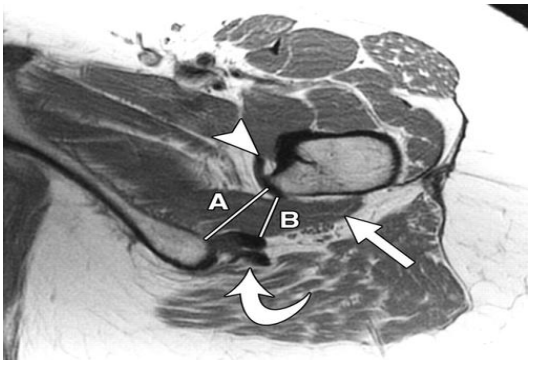

Fig 1. Diagnosis by magnetic resonance image [5]

Ischiofemoral space (IFS) and quadratus femoris space (QFS) on T2-weighted axial fat-suppressed images on magnetic resonance images as described by Torriani. Iliopsoas tendon (arrowhead), quadratus femoris muscle (straight arrow), and hamstring tendons (curved arrow)

A: Ischiofemoral space, B: Quadratus femoris space

Table 1. Patients characteristics of IFI and control group

	Study group (n=58)	Control group (n=58)	P-value
Age	57.3 ± 13.1	56.9 ± 17.0	0.421
Gender (male/female)	7/51	7/51	1.000
Body mass index (kg/m^2)	21.9 ± 3.7	22.5 ± 4.2	0.472
Lesion side (Right:Left)	30:28	30:28	1.000

Fig 2. Ischiofermoal space (IFS) on the hip AP and false profile view

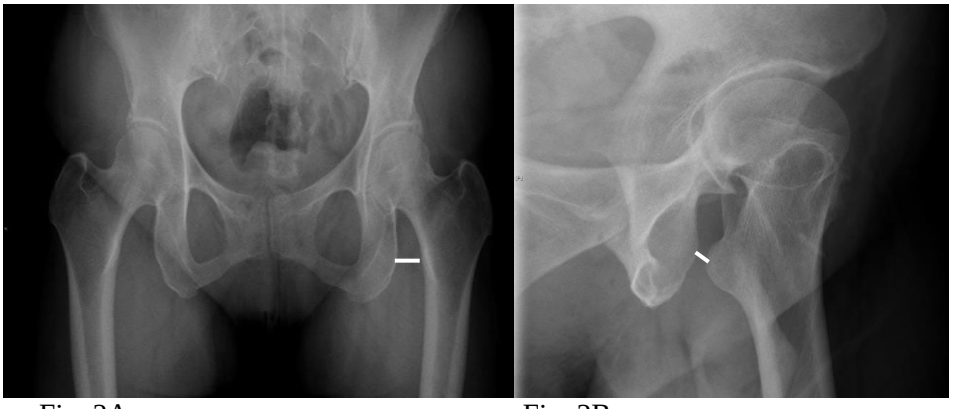

Fig. 2A Fig. 2B

The shortest distance between the lateral cortex of ischial tuberosity and medial cortex of the lesser trochanter

A. IFS on hip standing anteroposterior (AP) view, B. IFS on false profile view

III. RESULTS

Previous reports have suggested that bilateral IFIs occur at a rate of approximately 25% to 40%, in our study was 32.7(19/58) %[6,5]. In the IFI group, the IFS value measured in the false profile view was 7.07 ± 2.8 mm in the mean, the IFS value of control group was 17.1 ± 6.4 mm, ROC AUC value was 0.967 (Table 2). The IFS values measured in the hip AP view were 24.7 ± 6.7 mm in the IFI group and 34.5 ± 7.3 mm in the control group and the ROC AUC value was 0.841. In both the false profile view and the hip AP view, the IFS was significantly lower in the IFI patients compared to the control group ($P < 0.01$),

comparing the ROC AUC values, the hip AP view is 0.841 which is in the good discrimination category, but the ROC AUC value in the false profile view is 0.967 and can be used as an excellent parameter (excellent discrimination, AUC ≥ 0.90; good discrimination, 0.80 ≤ AUC < 0.90). IFS and QFS in MRI imaging were also shown similar results. In our study, IFS values were measured as mean 7.7 ± 2.7 mm and QFS 4.1 ± 2.4 mm in the IFI patients, IFS 18.4 ± 5.0 mm and QFS 13.4 ± 4.3 mm in the control group, respectively which were significantly lower than the P-value 0.01 (Table 3). The ROC AUC was also 0.994 and 0.984 for IFS and QFS, respectively, indicating that MRI was also excellent as a diagnostic tool for IFI. As you can see in the ROC curve (Fig 3), there is no doubt that MRI is the best diagnostic tool. And the false profile view is followed by MRI. The cutoff value of the IFS measured in the false profile view was 10.3mm (sensitivity 88.6%, specificity 88.4%) (Fig 4).

We also reaffirmed the usefulness of false profile view as the correlation between the IFS and QFS values measured by MRI known as the gold standard and the IFS values in the false profile view measured in this study and also compared with the hip AP view. As shown in Table 4, the correlation between the IFS values measured in the false profile view and the IFS and QFS measured by MRI was 0.74 and 0.74 which was superior to the correlation values of the hip AP view with IFS and QFS of 0.60 and 0.59 measured by MRI.

Table 2. Comparison of IFS between the false profile and hip AP view

	Study group (mm)	Control group (mm)	P - value	ROC AUC
IFS (false profile view)	7.6 ± 3.5	17.1 ± 6.4	<0.01	0.967
IFS (hip AP view)	24.7 ± 6.7	34.5 ± 7.3	<0.01	0.847

IFS: ischiofemoral space

Table 3. Mean value of IFS and QFS in MRI

	Study group (mm)	Control group (mm)	P - value	ROC AUC
IFS	7.7 ± 2.7	18.4 ± 5.0	<0.01	0.994
QFS	4.1 ± 2.4	13.4 ± 4.4	<0.01	0.984

IFS: ischiofemoral space, QFS: quadratus femoris space

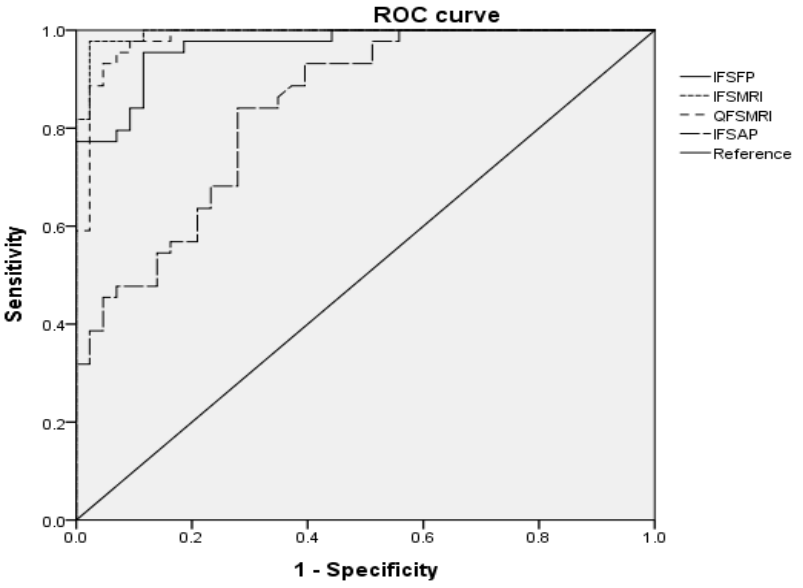

Fig 3. ROC curve of each parameter

Graph shows ROC curve of each parameter. IFSMRI and QFSMRI are almost same and largest AUC. Ischiofemoral space in hip anteroposterior (AP) view exhibits good discriminatory ability. (0.80 ≤ AUC < 0.90) But ischiofemoral space in false profile view has much better discriminatory ability.

Note: excellent discrimination, AUC ≥ 0.90; good discrimination, 0.80 ≤ AUC < 0.90; fair discrimination, 0.70 ≤ AUC < 0.80; and poor discrimination, AUC < 0.70.

IFSFP: Ischiofemoral space in false profile view, IFSMRI: Ischiofemoral space in MRI, QFSMRI: Quadratus femoris space in MRI, IFSAP: Ischiofemoral space in hip AP view

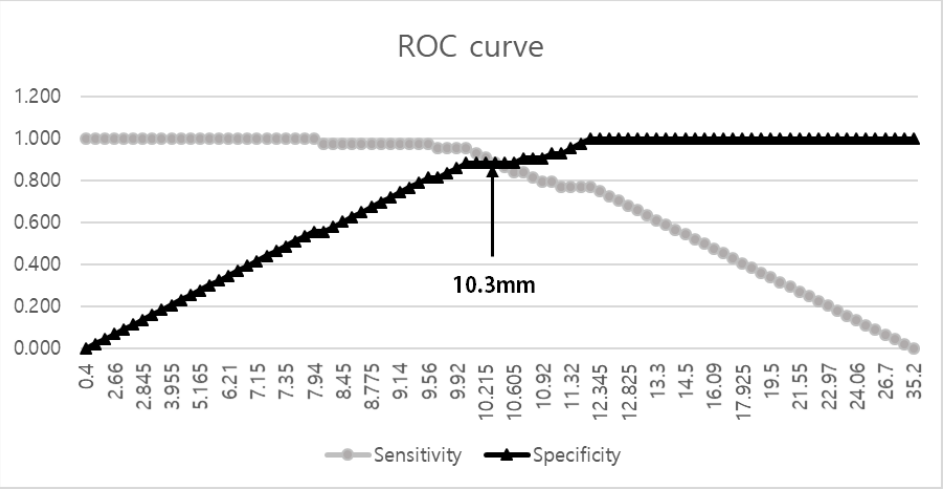

Fig 4. Cut off value of ischiofemoral space (IFS) in false profile view

Graph shows sensitivity and specificity values used to discriminate between ischiofemoral impingement patients and control group. Cut off value was 10.3 mm (sensitivity: 88.6 %, specificity: 88.4 %)

Table 4. Correlated between MRI and hip AP X-ray measurement

	IFS (FP view)	P-value	IFS (hip AP view)	P-value
IFS (MRI)	0.74	<0.01	0.60	<0.01
QFS (MRI)	0.74	<0.01	0.59	<0.01
IFS (hip AP view)	0.62	<0.01		

IFS: ischiofemoral space, QFS: quadratus femoris space, FP view: False profile view, hip AP view: hip anteroposterior view

IV. DISCUSSION

IFI is known to cause of hip pain and limit of motion due to narrowing of space between the ischial tuberosity and the lesser trochanter. The symptoms of IFI are not as easy to distinguish from those commonly seen in patients with nonspecific hip pain such as groin pain, hip pain, pain on sitting and locking in hip motion[1,6]. No specific clinical criteria for diagnosing IFI alone is currently established. However, up to now, based on the report of torriani et al, MRI has been used as a gold standard for diagnosis[5]. In the IFI patients, IFS and QFS are narrower than normal patients in MRI imaging also often accompanied by quadratus femoris muscle edema[1]. IFI may also be induced by pelvic morphology such as changes in osseous due to sclerosis or cystic change, femoral neck angle, ischial angle[8-10]. In addition, not only hip joint infection, but also myositis-like changes can induce impingement syndrome[11]. To exclude IFI that may be caused by external factors, we excluded patients who underwent surgical treatment such as total hip replacement, bipolar hemiarthroplasty, fractures around the hip joint and infection.

Since the prevalence of IFI is rare and not well known, there has been little research on diagnostic tools other than MRI. In a paper published by Park et al. in 2016, hip AP view was helpful for diagnosis[12]. Considering that the definition of IFI is a narrowing of the space between the lesser trochanter and the ischial tuberosity, radiography that can better observe the lesser

trochanter and ischial tuberosity may be more helpful. So, we used the false profile view for a screening tool in the diagnosis of IFI. According to a summarized article by Singer et al., IFS in patients with IFI ranged from 8.9 to 17.4mm, QFS from 6.14 to 12mm[13]. In our study, IFS was measured 7.7 ± 2.7mm in IFI patients and 4.1 ± 2.4 mm in QFS, which was statistically significantly lower in the IFI patient group than in the control group.

In this study, the IFS values between the IFI patients and the control groups measured using the false profile view were also significant ($p < 0.01$) between the two groups. The correlation between the values measured in the false profile view and the values measured in the MRI the coefficients also showed a significant correlation (Table 2, 4). Comparing the ROC AUC values, the values were higher in the false profile view than in the hip AP view (Table 1). IFI is known to be more common in women, in our study the female-to-male ratio was significantly higher (51:7), which is thought to be due to the anatomical difference between male and female pelvis. In our study, we used propensity score matching as a statistical method to compensate for such unbalanced gender and small patient number[14].

Treatment of IFI is mostly conservative treatment. Resting, physical therapy and non-steroidal anti-inflammatory drugs can be used. If Symptoms persist, CT or ultrasound-guided injection therapy and resection of the lesser trochanter may improve the symptoms[15-17]. Conservative treatment alone has improved symptoms in our patients.

Of course, there are many limitations in our study. Retrospective design and propensity score matching are complementary, but the small number of patients is the limiting point and the bias and error of the measurer should be taken into account. In addition, it is difficult to distinguish diseases such as iliopsoas tendinitis, hamstring injury and bursitis, which are similar to IFIs symptoms, when using only X-ray as a diagnostic tool. Also, there is the disadvantage that the cause of hip pain cannot be completely excluded from the case other than IFI even in the patients selected. However, there is nothing other than the MRI criteria for diagnosing IFI. It is the first study using false profile view and we can say that it has the strength of our research which compared the correlation with the hip AP view and correlated them with MRI in all patients.

V. CONCLUSION

Although there is no doubt that MRI is the tool of final diagnosis in the diagnosis of IFI, MRI is expensive and it is rather difficult to use MRI in all patients. The false profile view is relatively simple and can be measured at low cost. It may be useful as a screening tool for suspicion of IFI in patients with hip pain prior to MRI examination.

REFERENCES

1. Stafford GH, Villar RN. Ischiofemoral impingement. J Bone Joint Surg Br 2011;93:1300-2.
2. Patti JW, Ouellette H, Bredella MA, Torriani M. Impingement of lesser trochanter on ischium as a potential cause for hip pain. Skeletal Radiol 2008;37:939-41.
3. Hernando MF, Cerezal L, Perez-Carro L, Canga A, Gonzalez RP. Evaluation and management of ischiofemoral impingement: a pathophysiologic, radiologic, and therapeutic approach to a complex diagnosis. Skeletal Radiol 2016;45:771-87.
4. Hatem MA, Palmer IJ, Martin HD. Diagnosis and 2-year outcomes of endoscopic treatment for ischiofemoral impingement. Arthroscopy 2015;31:239-46.
5. Torriani M, Souto SC, Thomas BJ, Ouellette H, Bredella MA. Ischiofemoral impingement syndrome: an entity with hip pain and abnormalities of the quadratus femoris muscle. AJR Am J Roentgenol 2009;193:186-90.
6. Tosun O, Algin O, Yalcin N, Cay N, Ocakoglu G, Karaoglanoglu M. Ischiofemoral impingement: evaluation with new MRI parameters and assessment of their reliability. Skeletal Radiol 2012;41:575-87.
7. Clohisy JC, Carlisle JC, Beaule PE, Kim YJ, Trousdale RT, Sierra RJ, et al. A systematic approach to the plain radiographic evaluation of the young adult hip. J Bone Joint Surg Am 2008;90 Suppl 4:47-66.

8. Bredella MA, Azevedo DC, Oliveira AL, Simeone FJ, Chang CY, Stubbs AJ, et al. Pelvic morphology in ischiofemoral impingement. Skeletal Radiol 2015;44:249-53.

9. Schatteman J, Vanhoenacker FM, Somville J, Verstraete KL. Ischiofemoral Impingement Due to a Solitary Exostosis. JBR-BTR 2015;98:39-42.

10. Siebenrock KA, Steppacher SD, Haefeli PC, Schwab JM, Tannast M. Valgus hip with high antetorsion causes pain through posterior extraarticular FAI. Clin Orthop Relat Res 2013;471:3774-80.

11. Kwee RM, Ahlawat S, Fritz J. Magnetic Resonance Imaging Findings of Ischiofemoral Impingement in Patients With Inflammatory Myositis: An Observational Study. J Comput Assist Tomogr 2017;41:212-6.

12. Park S, Lee HY, Cuong PM, Won YY, Ji HM, Yoon SH, et al. Supine Versus Standing Radiographs for Detecting Ischiofemoral Impingement: A Propensity Score-Matched Analysis. AJR Am J Roentgenol 2016;206:1253-63.

13. Singer AD, Subhawong TK, Jose J, Tresley J, Clifford PD. Ischiofemoral impingement syndrome: a meta-analysis. Skeletal Radiol 2015;44:831-7.

14. Lee DK. An introduction to propensity score matching methods. Anesthesia and Pain Medicine 2016;11:130-48.

15. Howse EA, Mannava S, Tamam C, Martin HD, Bredella MA, Stubbs AJ. Ischiofemoral space decompression through posterolateral approach: cutting block technique. Arthrosc Tech 2014;3:e661-5.

16. Kim WJ, Shin HY, Koo GH, Park HG, Ha YC, Park YH. Ultrasound-guided Prolotherapy with Polydeoxyribonucleotide Sodium in Ischiofemoral Impingement Syndrome. Pain Pract 2014;14:649-55.

17. Jo S, O'Donnell JM. Endoscopic lesser trochanter resection for treatment of ischiofemoral impingement. J Hip Preserv Surg 2015;2:184-9.

ABSTRACT(IN KOREAN)

좌골대퇴충돌 증후군의 선별진단에서 false profile view 의 유용성

<지도교수 이 우 석>

연세대학교 대학원 의학과

곽 대 경

목적: 좌골대퇴충돌증후군은 발생빈도가 높지 않아 간과하기 쉬운 질환으로 고가의 자기공명영상을 통해 주로 진단되고 있다. 본 연구에서는 좌골대퇴충돌증후군의 선별진단을 위한 검사로 false profile 영상의 유용성을 알아보고자 하였다.

대상 및 방법: 2013년 6월부터 2017년 7월까지 좌골대퇴충돌증후군으로 진단받은 58예를 대상으로 하였고, propensity score matching을 이용하여 연령과 성별, 체질량 지수를 일치시킨 58예를 대조군으로 하였다. 체중부하 고관절 전후면 영상과 false profile 영상에서 좌골조면의 외측연과 소전자 내측연의 거리(ischiofemoral space; IFS)를 측정하였다. MRI 검사에서 IFS와 quadratus femoris space (QFS)를 측정하였다. false profile 영상에서 IFS의 ROC AUC과 결정점(cutoff point)을 측정하였고, 고관절 전후면 영상 IFS과 MRI 검사에

서 IFS 및 QFS과의 상관관계를 분석하였다.

결과: 고관절 false profile 영상과 전후면 영상에서 IFS는 좌골대퇴충돌증후군에서 의미있게 감소되어 있었으며($p<0.01$), false profile 영상에서 IFS의 ROC AUC(0.967)는 고관절 전후면 영상에서 IFS의 ROC AUC(0.841)보다 높았다. 좌골대퇴충돌증후군의 선별진단을 위한 false profile 영상에서 IFS의 결정점은 10.3 mm 이었다(민감도 88.2%. 특이도 88.4%). false profile 영상에서 IFS는 MRI 검사 IFS ($r=0.744$), MRI 검사 QFS ($r=0.740$), 고관절 전후면 영상 IFS ($r=0.621$)와 상관관계를 보였다($p<0.01$).

결론: 고관절 false profile 영상은 MRI 검사전에 좌골대퇴충돌증후군의 선별진단에 유용한 검사로 판단된다.

핵심되는 말 : 좌골대퇴충돌 증후군, false profile 영상, IFS, QFS, 선별 검사