

Retrograde Distal Superficial Femoral Artery Approach in the Supine Position for Chronic Superficial Femoral Artery Occlusion

Sanghoon Shin, MD, Seunghwan Kim, MD, Young-Guk Ko, MD,
Myeung-Ki Hong, MD, Yangsoo Jang, MD, and Donghoon Choi, MD

Division of Cardiology, Severance Cardiovascular Hospital, Yonsei University Health System, Yonsei University College of Medicine, Seoul, Korea

Subintimal angioplasty is an effective method for the treatment of long superficial femoral artery (SFA) occlusions. One of the major limiting factors for the success of this procedure is the failure to re-enter the true lumen. The recently introduced luminal re-entry devices provide a high technical success rate, but failures can occur. In such cases, a retrograde popliteal approach can serve as a potential backup option. However, the need to reposition the patient remains a drawback. Here, we report a case of an 81-year-old male with a long SFA occlusion treated using a retrograde distal SFA approach in the supine position after the initial failure of antegrade angioplasty. (**Korean Circ J 2014;44(3):184-188**)

KEY WORDS: Peripheral arterial disease; Femoral artery; Angioplasty.

Introduction

Subintimal angioplasty (SA) has been found to be an effective method for the treatment of long superficial femoral artery (SFA) occlusions.¹⁾ In this technique, a wire is advanced across the occlusion in the subintimal space, and then it re-enters the true vessel lumen distal to the occlusion. One of the major factors that limit the success of this procedure is the failure of the wire to re-enter the true lumen.²⁾ This issue is often related to the presence of severe calcification in the vessel wall. In this report, we present a case where an initially unsuccessful antegrade SA due to failure to re-enter the distal true lumen was rescued by using a retrograde subintimal approach through the distal SFA.

Received: October 11, 2012

Revision Received: December 12, 2012

Accepted: January 9, 2013

Correspondence: Donghoon Choi, MD, Division of Cardiology, Severance Cardiovascular Hospital, Yonsei University Health System, Yonsei University College of Medicine, 50-1 Yonsei-ro, Seodaemun-gu, Seoul 120-752, Korea

Tel: 82-2-2228-8449, Fax: 82-2-2227-7732

E-mail: cdhlyj@yuhs.ac

• The authors have no financial conflicts of interest.

This is an Open Access article distributed under the terms of the Creative Commons Attribution Non-Commercial License (<http://creativecommons.org/licenses/by-nc/3.0>) which permits unrestricted non-commercial use, distribution, and reproduction in any medium, provided the original work is properly cited.

Case

An 81-year-old male patient visited our hospital for right leg pain at rest (Fontaine class III). His comorbidities included hypertension, current smoking, and a previous non-ST elevation myocardial infarction in September 2010 which was treated with percutaneous coronary intervention and stent implantation in the right coronary artery. In addition, he also had chronic kidney disease because of long-standing hypertension and apical hypertrophic cardiomyopathy discovered on echocardiography. His left ventricular function was preserved (ejection fraction=64%), but there was a regional wall motion abnormality in the right coronary artery.

Angiogram performed via the left common femoral access showed an occlusion of about 25 cm of the right superficial femoral artery (SFA) with reconstitution of the distal SFA and popliteal artery (Fig. 1A and B). A 7 Fr Balkin sheath (Cook Inc., Bloomington, IN, USA) was inserted into the right external iliac artery, and an angled 0.035-inch hydrophilic guidewire (Radifocus; Terumo, Tokyo, Japan) through a 5 Fr catheter (Glidecath; Terumo, Tokyo, Japan) was used to create a subintimal dissection plane above the level of the occlusion. After successful formation of the subintimal dissection and wire loop, the wire was advanced through the subintimal space down to the distal occlusion site with the support of a Glide catheter. An attempt was then made to pass the wire into the distal true lumen. However, re-entry of the wire into the true lumen

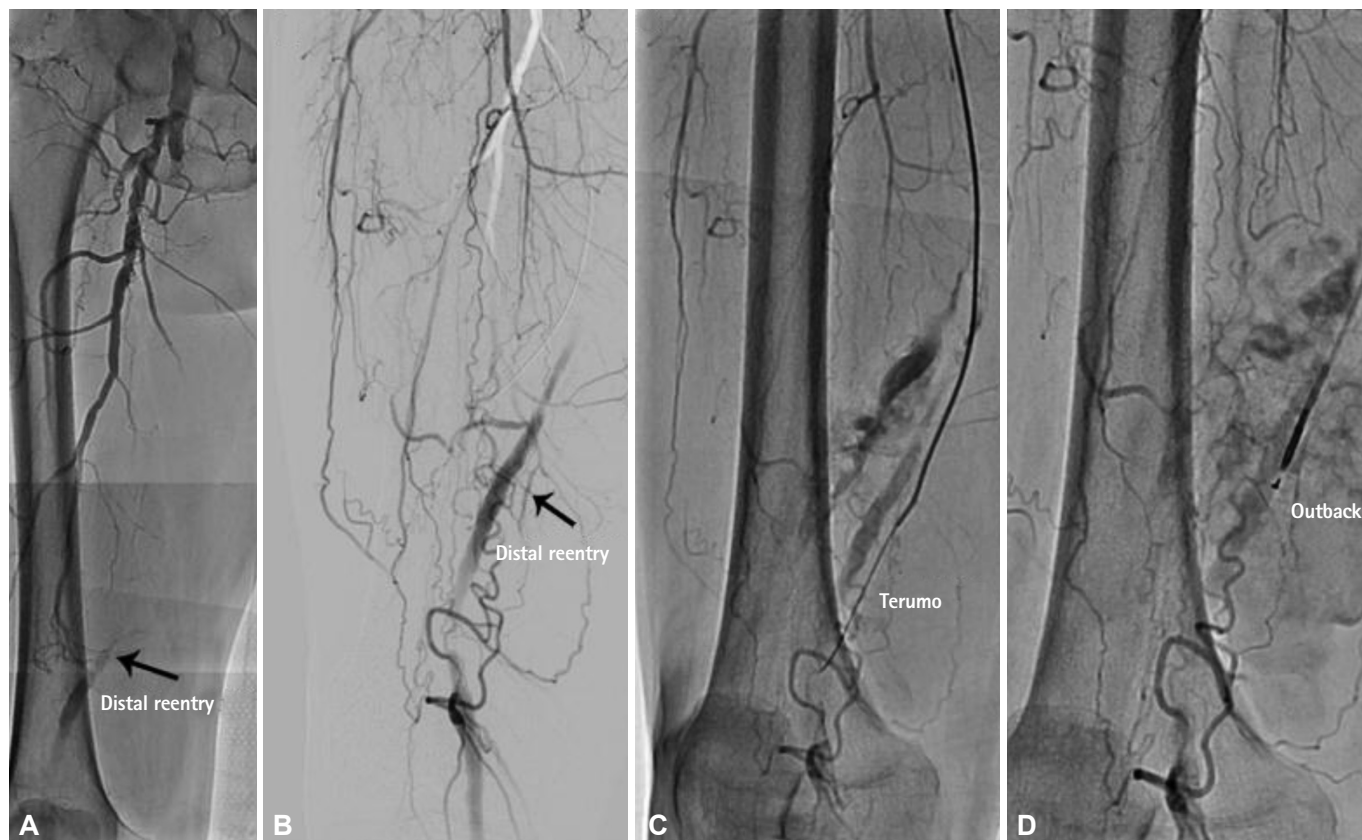

Fig. 1. A total occlusion of about 25 cm of the right superficial femoral artery with reconstitution of the distal superficial femoral artery (A and B) and failure to find the distal re-entry site with a hydrophilic wire (C) and re-entry catheter (D).

distal to the occlusion was not possible (Fig. 1C). Therefore, an Outback Re-Entry Catheter (LuMend, Inc., Redwood City, CA, USA) was used in an attempt to enter the true lumen, but this attempt failed (Fig. 1D).

Since the distal SFA was disease-free and normal in caliber, a retrograde approach through the distal SFA was planned as an alternative. For performing a retrograde approach through the distal SFA, a roadmap of the vessels was first obtained by injecting the contrast in an antegrade direction. The distal SFA was then punctured at the proximal part of the adductor canal with a 21-gauge micropuncture needle (Cook Inc., Bloomington, IN, USA) under roadmap fluoroscopic guidance. A 0.018-inch guide wire was advanced to the distal SFA following successful puncture, and an angiogram was performed through a 3 Fr dilator to confirm that the access to the SFA was achieved properly. A 5 Fr sheath was then inserted into the distal SFA (Fig. 2). An angled 0.035-inch hydrophilic wire with the support of the 5 Fr Glide catheter was advanced through the subintimal space in a retrograde fashion. The retrograde wire was successfully passed into the true lumen of the left common femoral artery, and then dilation with a 5.0×150 mm balloon was performed. The hydrophilic guide wire was successfully passed through the dissected channel in an antegrade fash-

ion, and two self-expanding nitinol stents (SMART 6×150 mm, SMART 7×120 mm; Cordis, Miami, FL, USA) were placed in the SFA, which yielded a satisfactory final result (Fig. 3). Following the procedure, complete hemostasis after insertion of the sheath into the distal SFA was achieved without the use of hemostatic devices other than elastic bandages and manual compression, and access site complications did not occur. The patient was discharged uneventfully three days after the procedure.

Discussion

Since the time Bolia first introduced subintimal angioplasty,³⁾ this technique has been an indispensable recanalization technique for chronic total occlusions in the SFA and has provided a high procedural success rate with acceptable long-term outcomes when combined with stenting.¹⁾ This technique involves intentional advancement of a wire across the occlusion in the subintimal space to ultimately exit into the true vessel lumen distal to the occlusion. However, its utility is limited by the inability to re-enter the true lumen from the subintimal space, which occurs in 13 to 26% of the cases. Distal re-entry devices, such as the intravascular ultrasound (IVUS)-guided CrossPoint TransAccess catheter (Trans-

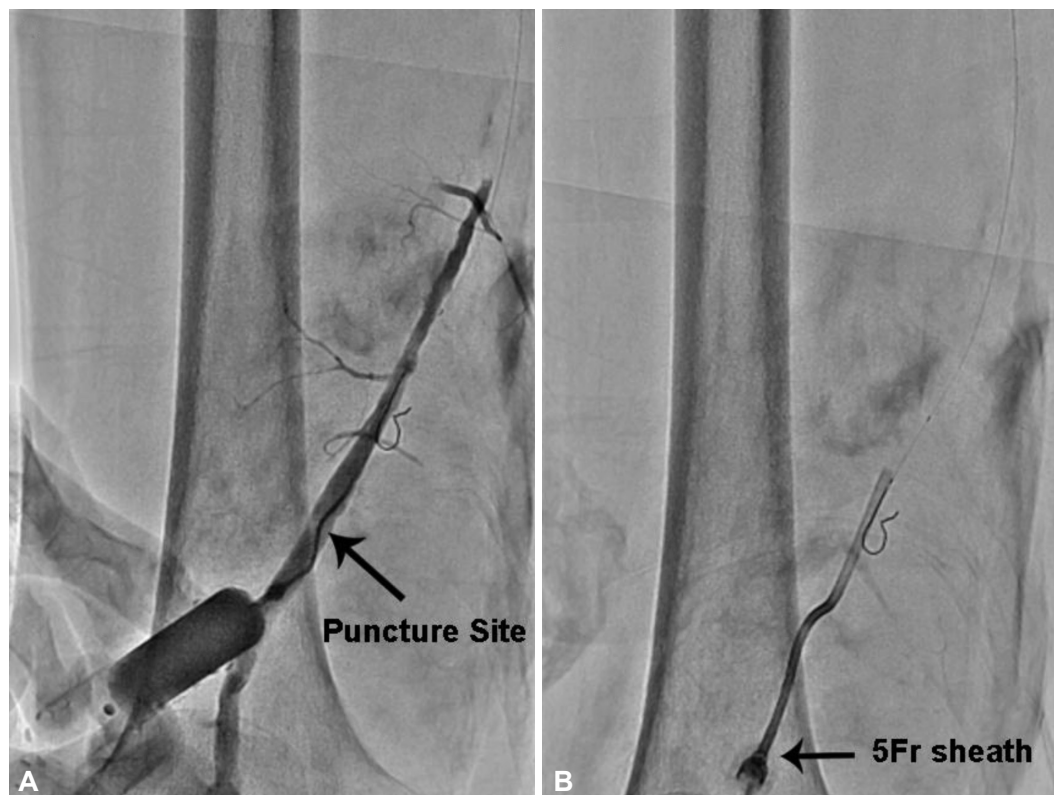


Fig. 2. The distal SFA is punctured at the proximal part of the adductor canal with a 21-gauge micropuncture needle under a roadmap fluoroscopic guidance, and an angiogram is performed through a 3 Fr dilator to confirm that the access to the SFA is achieved properly (A). Then, a 5 Fr sheath is inserted into the distal SFA (B).

Vascular, Menlo Park, CA, USA) or the Outback catheter (Perclose, CA, USA), were developed to overcome re-entry failure and they are being widely used.^{4,5)} However, utilizing these re-entry devices does not entirely preclude the possibility of failure to find the true lumen. In our case, we unsuccessfully attempted to re-enter the distal true lumen several times using a re-entry device.

Since Tønnesen et al.⁶⁾ first reported the utility of retrograde popliteal access in 1988, this approach has proved to be a useful alternative method for challenging SFA interventions.⁷⁻⁹⁾ However, the need for repositioning the patient during the procedure and the potential risk of complications, such as popliteal artery occlusion and arteriovenous fistula due to unintentional puncture of the popliteal vein, have impeded wider acceptance of the retrograde approach.⁸⁾ Furthermore, once the patient's position is changed to a prone position, the remaining procedures need to be performed via the popliteal access only. However, in our case, the distal SFA access allowed the patient to remain in the supine position throughout the procedure, thus enabling direct visualization of both arterial access points and maintenance of necessary sterile conditions at both sites.

Several authors have reported puncture site complication rates associated with the popliteal artery access between 2.5% and

5.2%.^{9,10)} The primary reason for the development of complications including arteriovenous fistula or gross hematoma is the proximity between the artery and the vein in the popliteal fossa.¹¹⁾ In addition, popliteal lesions are not a routine indication for stent therapy because popliteal stenting is assumed to be associated with a high risk of re-stenosis and fracture.¹²⁾

There are several advantages of a distal SFA access. First, distal SFA access does not require movement of the patient. Traditional retrograde popliteal access requires turning the patient from a supine to a prone position. This maneuver increases the patient anxiety and creates an uncomfortable situation, especially for patients who are obese or have impaired respiratory function. Some research groups developed a popliteal artery puncture technique performed by flexing and medially rotating the knee, which also causes discomfort to the patient. Second, the femoral vein is located lateral to the SFA in the proximal portion of the adductor canal, and therefore, distal SFA access is associated with a lower risk of puncturing the vein than popliteal access, and thus, the risk of arteriovenous fistula is reduced. Third, unlike the popliteal artery, a stent can be inserted into the SFA as long as the lesion does not involve the adductor canal. One of the disadvantages of a popliteal access is that if the puncture results in vascular occlusion

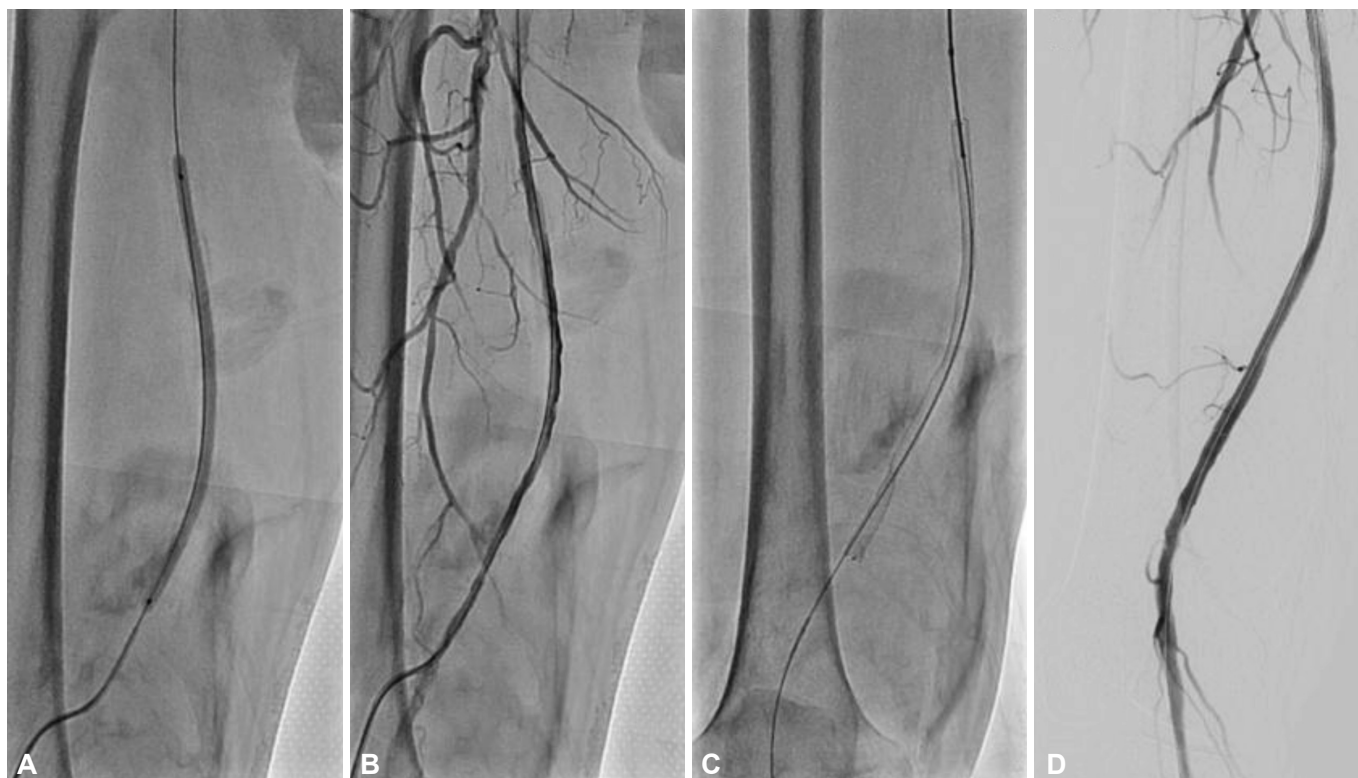

Fig. 3. After dilation with a 6.0×40 mm balloon (A), angiogram shows diffuse dissection of the superficial femoral artery (B). Two self-expanding nitinol stents are placed in the superficial femoral artery (C), which yields a satisfactory final result (D).

or dissection and worsens limb ischemia, the stent cannot be inserted, and only techniques such as long-duration ballooning can be used as alternatives. On the contrary, in case of distal SFA access, the stent may be inserted as far as the adductor canal even when the access site is dissected or occluded. Furthermore, although the procedure can only be performed in the retrograde direction once the patient is turned into the prone position, it can be performed in both ante- and retrograde directions if the patient is maintained in the supine position.

There are several limitations to this technique that need to be considered. First, it is technically harder to achieve a SFA access than popliteal access. The artery is located deep in the muscle, and therefore its pulsation cannot be readily felt. However, a roadmap fluoroscopic guidance assists in gaining access to the SFA. Second, the SFA cannot be directly compressed to achieve hemostasis, because the distal SFA is surrounded by muscles; and in our case, there were no leakages after the removal of the SFA sheath. This case demonstrates that a distal SFA approach in the supine position can serve as a convenient option for treating SFA occlusion in the setting of failed antegrade angioplasty.

References

1. Ko YG, Kim JS, Choi DH, Jang Y, Shim WH. Improved technical success

and midterm patency with subintimal angioplasty compared to intraluminal angioplasty in long femoropopliteal occlusions. *J Endovasc Ther* 2007;14:374-81.

2. Spinoso DJ, Leung DA, Harthun NL, et al. Simultaneous antegrade and retrograde access for subintimal recanalization of peripheral arterial occlusion. *J Vasc Interv Radiol* 2003;14:1449-54.
3. Bolia A. Percutaneous intentional extraluminal (subintimal) recanalization of crural arteries. *Eur J Radiol* 1998;28:199-204.
4. Hausegger KA, Georgieva B, Portugaller H, Tauss J, Stark G. The out-back catheter: a new device for true lumen re-entry after dissection during recanalization of arterial occlusions. *Cardiovasc Intervent Radiol* 2004;27:26-30.
5. Casserly IP, Sachar R, Bajzer C, Yadav JS. Utility of IVUS-guided trans-access catheter in the treatment of long chronic total occlusion of the superficial femoral artery. *Catheter Cardiovasc Interv* 2004;62:237-43.
6. Tønnesen KH, Sager P, Karle A, Henriksen L, Jørgensen B. Percutaneous transluminal angioplasty of the superficial femoral artery by retrograde catheterization via the popliteal artery. *Cardiovasc Intervent Radiol* 1988;11:127-31.
7. Zaitoun R, Iyer SS, Lewin RF, Dorros G. Percutaneous popliteal approach for angioplasty of superficial femoral artery occlusions. *Cathet Cardiovasc Diagn* 1990;21:154-8.
8. Heenan SD, Vinnicombe SJ, Buckenham TM, Belli AM. Percutaneous transluminal angioplasty by a retrograde subintimal transpopliteal approach. *Clin Radiol* 1994;49:824-7; discussion 827-8.

9. Yilmaz S, Sindel T, Ceken K, Alimoğlu E, Lüleci E. Subintimal recanalization of long superficial femoral artery occlusions through the retrograde popliteal approach. *Cardiovasc Intervent Radiol* 2001;24:154-60.
10. Noory E, Rastan A, Sixt S, et al. Arterial puncture closure using a clip device after transpopliteal retrograde approach for recanalization of the superficial femoral artery. *J Endovasc Ther* 2008;15:310-4.
11. Trigaux JP, Van Beers B, De Wispelaere JF. Anatomic relationship between the popliteal artery and vein: a guide to accurate angiographic puncture. *AJR Am J Roentgenol* 1991;157:1259-62.
12. Grimm J, Müller-Hülsbeck S, Jahnke T, Hilbert C, Brossmann J, Heller M. Randomized study to compare PTA alone versus PTA with Palmaz stent placement for femoropopliteal lesions. *J Vasc Interv Radiol* 2001;12:935-42.