

A Successfully Treated Case of Recurrent Focal Segmental Glomerulosclerosis (FSGS) with Plasmapheresis and High dose Methylprednisolone Pulse Therapy

저자	Her, Sun Mi ; Lee, Keum Hwa ; Shin, Jae Il
저널명	Childhood kidney diseases
발행기관	Korean Society of Pediatric Nephrology
NDSL URL	http://www.ndsl.kr/ndsl/search/detail/article/articleSearchResultDetail.do?cn=JAKO201732060821573
IP/ID	128.134.207.84
이용시간	2018/07/04 10:55:10

저작권 안내

- ① NDSL에서 제공하는 모든 저작물의 저작권은 원저작자에게 있으며, KISTI는 복제/배포/전송권을 확보하고 있습니다.
- ② NDSL에서 제공하는 콘텐츠를 상업적 및 기타 영리목적으로 복제/배포/전송할 경우 사전에 KISTI의 허락을 받아야 합니다.
- ③ NDSL에서 제공하는 콘텐츠를 보도, 비평, 교육, 연구 등을 위하여 정당한 범위 안에서 공정한 관행에 합치되게 인용할 수 있습니다.
- ④ NDSL에서 제공하는 콘텐츠를 무단 복제, 전송, 배포 기타 저작권법에 위반되는 방법으로 이용할 경우 저작권법 제136조에 따라 5년 이하의 징역 또는 5천만 원 이하의 벌금에 처해질 수 있습니다.

A Successfully Treated Case of Recurrent Focal Segmental Glomerulosclerosis (FSGS) with Plasmapheresis and High dose Methylprednisolone Pulse Therapy

Sun Mi Her, M.D.¹
Keum Hwa Lee, M.D.^{1,2,3}
Jae Il Shin, M.D., Ph.D.^{1,2,3}

Department of Pediatrics¹, Yonsei University College of Medicine, Seoul, Korea, Division of Pediatric Nephrology², Severance Children's Hospital, Seoul, Korea, Institute of Kidney Disease Research³, Yonsei University College of Medicine, Seoul, Korea

Corresponding author: Jae Il Shin, M.D., Ph.D.
Department of Pediatrics, Yonsei University College of Medicine, 50-1 Yonsei-ro, Seodaemun-gu, Seoul 03722, Korea
Tel: +82-2-2228-2050
Fax: +82-2-393-9118
E-mail: SHINJI@yuhs.ac

Received: 4 October 2017
Revised: 6 October 2017
Accepted: 7 October 2017

This is an open-access article distributed under the terms of the Creative Commons Attribution Non-Commercial License (<http://creativecommons.org/licenses/by-nc/4.0/>) which permits unrestricted non-commercial use, distribution, and reproduction in any medium, provided the original work is properly cited.

Copyright © 2017 The Korean Society of Pediatric Nephrology

Focal segmental glomerulosclerosis (FSGS) in children, which is a kind of nephrotic syndrome showing steroid resistance, usually progresses to a substantial number of end stage renal disease (ESRD). Although the pathogenesis of primary FSGS is unclear, several recent studies have reported that FSGS is associated with circulating immune factors such as soluble urokinase-type plasminogen activator receptor (suPAR) or anti-CD40 autoantibody. We report a successfully treated case of a 19-year-old female patient who experienced a recurrence of primary FSGS. After the diagnosis of FSGS, the patient progressed to ESRD and received a kidney transplantation (KT). Three days later, recurrence was suspected through proteinuria and hypoalbuminemia. She has been performed plasmapheresis and high dose methylprednisolone pulse therapy and shown remission status without increasing proteinuria for four years after KT. In conclusion, strong immunosuppressive therapy may be helpful for a good prognosis of recurrent FSGS, suppressing several immunologic circulating factors related disease pathogenesis.

Key words: Focal segmental glomerulosclerosis (FSGS), End stage renal disease (ESRD), Soluble urokinase-type plasminogen activator receptor (suPAR), Anti-CD40 autoantibody

Introduction

Idiopathic nephrotic syndrome is the most common glomerular disease in children. Also, congenital anomalies of the kidney and urinary tract are the most common cause of end-stage renal disease (ESRD) in children, followed by focal segmental glomerulosclerosis (FSGS) that is a kind of intractable glomerular disease¹. FSGS is one of the steroid resistant nephrotic syndromes and accounts for about 20% of children with nephrotic syndrome and about 50% of them progress to ESRD^{2,3}.

According to reports of the causes of FSGS, the main cause of primary FSGS is thought to be a podocyte injury by several circulating factors. The proposed caused of secondary FSGS are genetic, virus infections (e.g., human immunodeficiency virus type 1, parvovirus B19, simian virus 40, cytomegalovirus, Epstein-Barr virus), drugs (e.g., heroin, interferons alfa, beta, and gamma, lithium, pamidronate, sirolimus, calcineurin-inhibitor nephrotoxicity, anabolic steroids) and adaptive (reduced renal mass and renal hypertension)².

Steroid resistant FSGS in children usually gradually progresses to ESRD and needs to be received renal replacement therapies such as dialysis or kidney transplantation (KT). Even the patient has been performed KT recurrence rate is about 20-50%⁴.

Although the pathological mechanism of recurrent FSGS has not yet been elucidated, previous studies have reported that proteinuria occurs when injected into rats with serum from FSGS patients⁵. Recently, it has been reported that increased soluble urokinase-type plasminogen activator receptor (suPAR) affects the pathogenesis of kidney disease, especially FSGS⁶. In addition, there are studies that anti-CD40 autoantibody may be a potential circulating factor related to FSGS disease pathogenesis^{7,8}.

This report describes a case of successful treatment with plasmapheresis and high dose immunotherapy to strongly control immunologic circulating factors in recurrent FSGS patients after KT.

Case report

A 2-year-old female was diagnosed with nephrotic syndrome in February 2000 and had no family history. The patient was treated with deflazacort, but edema and proteinuria were repeatedly relapsed. Renal biopsy was performed in November 2000 for further evaluation of recurrence and minimal change disease was diagnosed. After that, methylprednisolone (MP) pulse therapy was performed and cyclosporine was added, but proteinuria, facial edema, hypoal-

buminemia did not be improved continuously. Therefore, a second renal biopsy was performed in October 2001 for evaluation and FSGS was finally diagnosed.

After FSGS diagnosis, 6 cycles of MP pulse therapy (30 mg/kg) and 6 cycles of cytozan pulse therapy (500 mg/BSA) were performed (from November 2001 to April 2002), and deflazacort and cyclosporine were maintained. However, relapses were repeated even though mycophenolate mofetil was added from September 2005 and eventually the disease progressed to ESRD. Eventually, at the age of 15, she received bilateral nephrectomy and living related donor KT in February 2013. The allograft functioned well immediately after reperfusion, but symptoms of nephrotic syndrome such as massive proteinuria exceeding 14 g/d, hypoalbuminemia (serum albumin 2.2 g/dL) and hypercholesterolemia (cholesterol 247 mg/dL) appeared on day 3 after KT. Three courses of plasmapheresis were tried at first, but they were ineffective. So the patient received a drug regimen with infusions of 20 mg/kg MP pulse therapy for 3 consecutive days every two weeks until 6 months after transplantation. After 6th infusion of pulse therapy, a graft function rapidly recovered and immediate reduction of serum creatinine and proteinuria was appeared. The patient achieved complete remission of proteinuria with stable renal function within 4 months of beginning of treatment. Four years after transplantation, no signs of FSGS recurrence are evident and graft function remains good (Fig. 1). Currently, the patient maintains taking immunosuppressants (tacrolimus, prednisolone, and mycophenolate) for preventing transplant rejection.

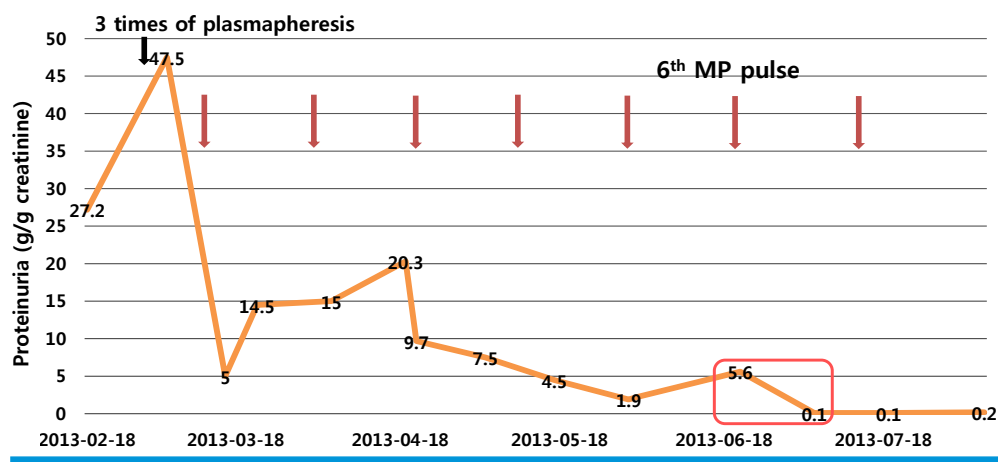


Fig. 1. Clinical course of treatment to the patient with recurrence of 3 days after receiving KT. FSGS, focal segmental glomerulosclerosis; KT, kidney transplantation; MP, methylprednisolone.

Discussion

The recurrence rate of primary FSGS after KT is relatively high, reported from 20 to 50% of patients⁴. It is known that two kinds of presentations can be came out after KT: an early recurrence and a late recurrence. Early recurrence can be frequently developed in about 10-18 days after KT, characterized by a nephrotic range of proteinuria with development of histological lesions of the new kidney⁹. In contrast, patients with a late recurrence shows massive proteinuria within several months or years after KT⁹. The graft survival is poor in children with recurrence of FSGS after KT because reported the median survival is only 5 months¹⁰. The risk of graft failure is higher in children with an early recurrence than a late one¹¹.

Despite the high incidence of recurrence and graft failure of FSGS after KT, however, the pathogenesis of recurrent FSGS is not well established from now on. In recent studies, several circulating factors have been suggested as a key role in the disease mechanism of FSGS^{7,12}. Several circulating factors which have been proposed are as follows: (1) suPAR and (2) anti-CD40 autoantibody.

SuPAR is released from the component of uPAR, which is the receptor of urokinase-type plasminogen activator (uPA) system¹³. In 2011, Wei et al. firstly reported that FSGS patients have two-thirds of elevated levels of suPAR and suggested that circulating suPAR could be a predictive value of FSGS recurrence in KT¹⁴. They hypothesized that suPAR enters the kidney glomerulus and activates $\beta 3$ integrin, which is the major anchoring proteins in glomerular basement membrane of podocyte¹⁴. Thus, podocyte dysfunction and effacement of membrane are developed resulting proteinuria¹⁴. There have been controversies, however, that suPAR levels can be increased not only in FSGS but also in other glomerular diseases or other systematic diseases such as paroxysmal nocturnal hemoglobinuria, infectious diseases including Human Immunodeficiency Virus (HIV)-1, tuberculosis sepsis, and malignancies^{13,15}. In addition, high-serum suPAR can show inverse correlation with estimated glomerular filtration rate (GFR)¹⁶.

Anti-CD40 autoantibody is also known as a circulating factor as an additional therapeutic target which cooperates with circulating suPAR with developing podocyte injury and proteinuria⁸. In animal models, injecting anti-CD40

autoantibody developed FSGS and some cases improved by manipulation of humoral response with plasmapheresis and rituximab^{17,18}. Besides, there is a report that recurred FSGS after KT was cured by plasmapheresis and rituximab¹⁹.

In our case, the patient showed massive proteinuria within three days after KT suggesting an early recurrence of FSGS. She has a high risk of graft failure, so we performed plasmapheresis and high-dose methylprednisolone protocol to reduce circulating factors. These treatment was effective because she shows maintainance of remission status without increasing proteinuria for three years after KT. This case suggests that the pathogenesis of recurrence can be related to immune mechanisms and serological dysregulation due to circulating factors. Also, high-dose methylprednisolone pulse therapy may have threshold dose of inducing remission. In other words, if immunesuppressants are not enough to suppress these relating circulating factors, the disease can relapse more often.

In conclusion, we should consider strong immunosuppressive therapy as soon as the patient with FSGS showing recurrence before proceeding to ESRD. The good response to the high-dose methylprednisolone combined plasma-pheresis may suggest the autoimmune nature of FSGS relating immunologic circulating factors.

Conflicts of interest

No potential conflict of interest relevant to this article was reported.

References

1. Harambat J, van Stralen KJ, Kim JJ, Tizard EJ. Epidemiology of chronic kidney disease in children. *Pediatr Nephrol* 2012;27:363-73.
2. D'Agati VD, Kaskel FJ, Falk RJ. Focal segmental glomerulosclerosis. *N Engl J Med* 2011;365:2398-411.
3. Naudet P. [Lipoid nephrosis in childhood]. *Rev Prat* 2003;53:2027-32.
4. Cochat P, Fargue S, Mestrallet G, Jungraithmayr T, Koch-Nogueira P, Ranchin B, et al. Disease recurrence in paediatric renal transplantation. *Pediatr Nephrol* 2009;24:2097-108.
5. Zimmerman SW. Increased urinary protein excretion in the rat

- produced by serum from a patient with recurrent focal glomerular sclerosis after renal transplantation. *Clin Nephrol* 1984;22:32-8.
6. Hayek SS, Sever S, Ko YA, Trachtman H, Awad M, Wadhvani S, et al. Soluble Urokinase Receptor and Chronic Kidney Disease. *N Engl J Med* 2015;373:1916-25.
 7. McCarthy ET, Sharma M, Savin VJ. Circulating permeability factors in idiopathic nephrotic syndrome and focal segmental glomerulosclerosis. *Clin J Am Soc Nephrol* 2010;5:2115-21.
 8. Delville M, Sigdel TK, Wei C, Li J, Hsieh SC, Fornoni A, et al. A circulating antibody panel for pretransplant prediction of FSGS recurrence after kidney transplantation. *Sci Transl Med* 2014;6:256ra136.
 9. Cochat P, Schell M, Ranchin B, Boueva A, Said MH. Management of recurrent nephrotic syndrome after kidney transplantation in children. *Clin Nephrol* 1996;46:17-20.
 10. Ehrlich JH, Rizzoni G, Brunner FP, Brynner H, Geerlings W, Fassbinder W, et al. Combined report on regular dialysis and transplantation of children in Europe, 1989. *Nephrol Dial Transplant* 1991;6 Suppl 1:37-47.
 11. Baum MA. Outcomes after renal transplantation for FSGS in children. *Pediatr Transplant* 2004;8:329-33.
 12. Reiser J, Nast CC, Alachkar N. Permeability factors in focal and segmental glomerulosclerosis. *Adv Chronic Kidney Dis* 2014;21:417-21.
 13. Thuno M, Macho B, Eugen-Olsen J. suPAR: the molecular crystal ball. *Dis Markers* 2009;27:157-72.
 14. Wei C, El Hindi S, Li J, Fornoni A, Goes N, Sageshima J, et al. Circulating urokinase receptor as a cause of focal segmental glomerulosclerosis. *Nat Med* 2011;17:952-60.
 15. Sever S, Trachtman H, Wei C, Reiser J. Is there clinical value in measuring suPAR levels in FSGS? *Clin J Am Soc Nephrol* 2013;8:1273-5.
 16. Harita Y, Ishizuka K, Tanego A, Sugawara N, Chikamoto H, Akioka Y, et al. Decreased glomerular filtration as the primary factor of elevated circulating suPAR levels in focal segmental glomerulosclerosis. *Pediatr Nephrol* 2014;29:1553-60.
 17. Fornoni A, Sageshima J, Wei C, Merscher-Gomez S, Aguillon-Prada R, Jauregui AN, et al. Rituximab targets podocytes in recurrent focal segmental glomerulosclerosis. *Sci Transl Med* 2011;3:85ra46.
 18. Assmann KJ, van Son JP, Dijkman HB, Mentzel S, Wetzels JF. Antibody-induced albuminuria and accelerated focal glomerulosclerosis in the Thy-1.1 transgenic mouse. *Kidney Int* 2002;62:116-26.
 19. Hristea D, Hadaya K, Marangon N, Buhler L, Villard J, Morel P, et al. Successful treatment of recurrent focal segmental glomerulosclerosis after kidney transplantation by plasmapheresis and rituximab. *Transpl Int* 2007;20:102-5.