Letter to the Editor
Diagnostic Genetics

Ann Lab Med 2017;37:359-361
https://doi.org/10.3343/alm.2017.37.4.359
ISSN 2234-3806 eISSN 2234-3814

ANNALS OF LABORATORY MEDICINE

Novel Mutation (c.8725T>C) in Two Siblings With Late-Onset *LAMA2*-Related Muscular Dystrophy

Min-Wook Kim, M.D.[1], Dae-Hyun Jang, M.D.[1], Jun Kang, M.D.[2], Seungok Lee, M.D.[3], Sun Young Joo, M.D.[4], Ja-Hyun Jang, M.D.[5,6], Eun-Hae Cho, M.D.[5], Young-Chul Choi, M.D.[7], and Jung Hwan Lee, M.D.[7]

Departments of Rehabilitation[1], Hospital Pathology[2], Laboratory Medicine[3], and Orthopaedic Surgery[4], Incheon St. Mary's Hospital, College of Medicine, The Catholic University of Korea, Seoul; Green Cross Genome[5], Yongin; Green Cross Laboratories[6], Yongin; Department of Neurology[7], Gangnam Severance Hospital, Yonsei University College of Medicine, Seoul, Korea

Dear Editor,

LAMA2-related muscular dystrophy can be classified into two clinical phenotypes: severe early-onset congenital muscular dystrophy and mild late-onset muscular dystrophy [1]. Several mild form muscular dystrophy cases have been diagnosed since Tan *et al* [2] reported the first case of late-onset *LAMA2*-related muscular dystrophy, thus expanding the spectrum of this disease [3-6]. Late-onset *LAMA2*-related muscular dystrophy presents clinically as limb girdle muscular dystrophy patterns and is associated with the partial expression of laminin α2 [6]. Here, we describe a novel missense mutation (c.8725T>C/p.Cys2909Arg) in the *LAMA2* in a patient diagnosed as having late-onset *LAMA2*-related muscular dystrophy. This study was approved by the institutional research review board of the Catholic University of Korea, Incheon St. Mary's Hospital. Written informed consent was obtained from the patient's parents after they had been briefed about the study.

The proband was a 4-yr-old girl who visited our clinic for evaluation because of a delay in motor milestone acquisition. Although there was no familial history of hereditary disorders, the patient's younger sister had similar proximal lower extremity weakness symptoms. The patient exhibited gross motor developmental delay, but no difficulties with fine motor functions, and her cognitive and speech skills corresponded with her age. Her serum creatine kinase concentration was 1,105 IU/L. Nerve conduction and needle electromyography studies did not reveal any definitive myopathy or peripheral neuropathy findings. Following the first visit, the patient was referred to the genetic clinic.

A gene panel test using next-generation sequencing for autosomal recessive limb girdle muscular dystrophy (30 genes: *ANO5, CAPN3, CAV3, DAG1, DES, DNAJB6, DYSF, FHL1, FKRP, FKTN, GAA, GMPPB, HNRPDL, ITGA7, LIMS2, LMNA, MYOT, PLEC, POMGNT1, POMT1, POMT2, SGCA, SGCB, SGCD, SGCG, TCAP, TNPO3, TRAPPC11, TRIM32,* and *TTN*), a multiplex ligation-dependent probe amplification test for Duchenne muscular dystrophy, and a dried blood spot test (lysosomal enzyme acid α-glucosidase activity assay) for Pompe disease were performed; all test results were normal. The patient was subjected to further genetic testing using next-generation sequencing analyzing 4,813 genes (approximately 62,000 exons) associated with several genetic diseases in humans [7]. Genomic DNA was extracted from the peripheral blood of the patient as well as her parents and sister. The genomic DNA was enriched by using the TruSight One Sequencing Panel (Illumina, Inc., San Diego, CA, USA) [7]. This panel provides comprehensive coverage of approximately 102 known protein-encoding genes involved in congenital my-

Received: October 24, 2016
Revision received: January 4, 2017
Accepted: March 13, 2017

Corresponding author: Dae-Hyun Jang
Department of Rehabilitation, Incheon St. Mary's Hospital, College of Medicine, The Catholic University of Korea, 56 Dongsu-ro, Bupyeong-gu, Incheon 21431, Korea
Tel: +82-32-280-5207, Fax: +82-32-280-5040
E-mail: dhjangmd@naver.com

opathy and muscular dystrophy.

We found compound heterozygous variations in the patient's *LAMA2*: a heterozygous nonsense variation in exon 49 (c.6955C >T/p.Arg2319*), previously reported as a pathogenic variation [8, 9], and a heterozygous missense variation in exon 62 (c.8725T >C/p.Cys2909Arg), which is a novel variation. The patient's parents were identified as heterozygous carriers for each variation, and the patient's sister had the same variations as the patient. Each variation was confirmed by conventional Sanger sequencing. One of the compound heterozygous variations present in the *LAMA2* of both siblings was a novel missense variation (c.8725T >C/p.Cys2909Arg). This variation has not been reported in control databases such as the 1,000 Genomes Project, Exome Variant Server, Exome Aggregation Consortium, and the dbSNP Database, and has been predicted to be deleterious by several *in silico* analysis tools. This nucleotide variation is relatively conserved (GERP 5.22, phyloP7 0.991). Genetic analysis of the parents confirmed transconfiguration of the missense variant with the

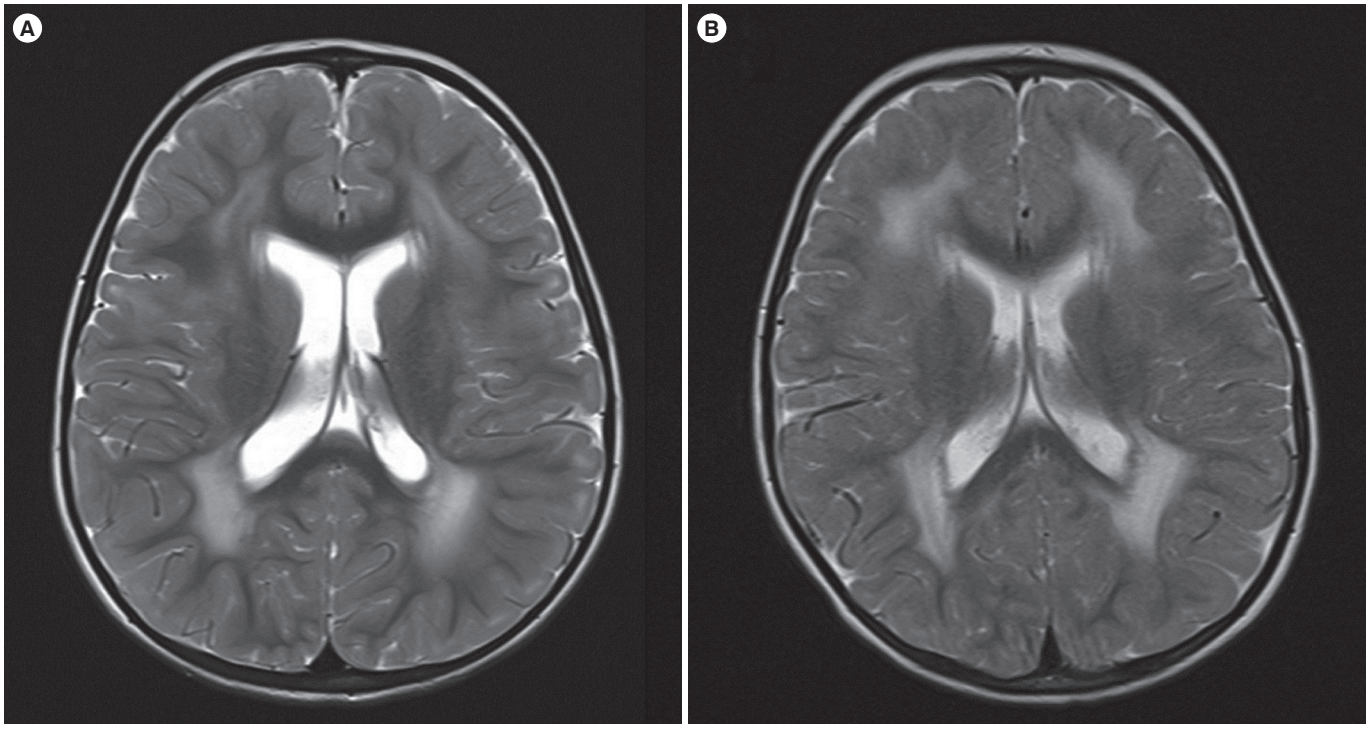

Fig. 1. Axial T2-weighted magnetic resonance images (A, the proband; B, the proband's sister) showing diffuse high signal intensity in the bilateral periventricular and subcortical white matter.

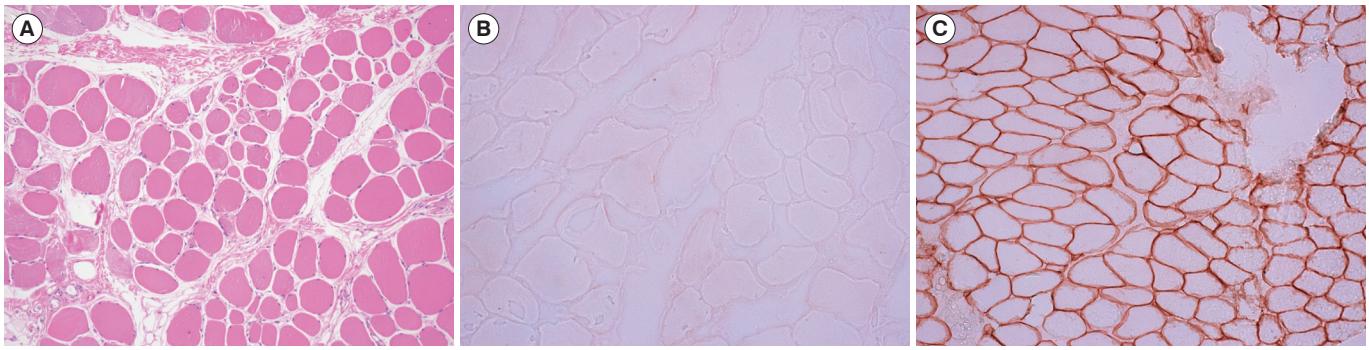

Fig. 2. Histologic examination of a muscle biopsy sample. (A) Hematoxylin and eosin (H-E) staining showing mild muscle fiber size variations, a few necrotic and regenerative muscle fibers, and endomysial edema (H-E stain, ×100). Immunohistochemical staining with the anti-laminin α2 antibody detected by 3,3′-diaminobenzidine (×200) showing decreased staining in the proband (B) compared with an age-matched normal control subject (C).

known pathogenic variant (c.6955C>T/p.Arg2319*).

Brain magnetic resonance images (MRI) of the patient and her sister revealed diffuse symmetric high signal unmyelinated changes (Fig. 1). A biopsy of the patient's left vastus lateralis muscle showed muscular dystrophic patterns. Immunohistochemical staining was performed by using antibodies against the following proteins: the C-terminus of dystrophin, the rod domain of dystrophin, the N-terminus of dystrophin, α-sarcoglycan, β-sarcoglycan, γ-sarcoglycan, δ-sarcoglycan, dysferlin, α-dystroglycan, caveolin-3, and laminin α2 (whole laminin α2). The laminin α2 staining in the patient was reduced compared with an age-matched normal control subject, whereas the staining of the other antibodies was non-specific (Fig. 2).

The proband and her sister showed similar clinical features, and the MRI findings of the two siblings and immunohistochemical findings of the proband were compatible with *LAMA2*-related muscular dystrophy. The evidence presented above and the cosegregation of the variants in the affected sister, suggest that this missense variant is the pathogenic element, based on the American College of Medical Genetics and Genomics guidelines regarding the interpretation of sequence variations [10].

In conclusion, we present a patient diagnosed as having late-onset *LAMA2*-related muscular dystrophy as a result of mutations in *LAMA2* (including a novel mutation: c.8725T>C/p.Cys2909Arg) identified by next-generation sequencing. We suggest that this novel missense mutation (c.8725T>C/p.Cys2909Arg) is the pathogenic mechanism underlying the genotype-phenotype correlation and annotation process.

Authors' Disclosures of Potential Conflicts of Interest

No potential conflicts of interest relevant to this article were reported.

Acknowledgments

This research was supported by a Translational R&D Project grant through the Clinical Research Laboratory, Incheon St. Mary's Hospital.

REFERENCES

1. Quijano-Roy S, Sparks SE, Rutkowski A. *LAMA2*-related muscular dystrophy. In: Pagon RA, Adam MP, et al. eds. GeneReviews. Seattle, WA: University of Washington, Seattle, 1993-2017.
2. Tan E, Topaloglu H, Sewry C, Zorlu Y, Naom I, Erdem S, et al. Late onset muscular dystrophy with cerebral white matter changes due to partial merosin deficiency. Neuromuscul Disord 1997;7:85-9.
3. Chan SH, Foley AR, Phadke R, Mathew AA, Pitt M, Sewry C, et al. Limb girdle muscular dystrophy due to LAMA2 mutations: diagnostic difficulties due to associated peripheral neuropathy. Neuromuscul Disord 2014;24:677-83.
4. Ding J, Zhao D, Du R, Zhang Y, Yang H, Liu J, et al. Clinical and molecular genetic analysis of a family with late-onset LAMA2-related muscular dystrophy. Brain Dev 2016;38:242-9.
5. Jones KJ, Morgan G, Johnston H, Tobias V, Ouvrier RA, Wilkinson I, et al. The expanding phenotype of laminin alpha2 chain (merosin) abnormalities: case series and review. J Med Genet 2001;38:649-57.
6. Rajakulendran S, Parton M, Holton JL, Hanna MG. Clinical and pathological heterogeneity in late-onset partial merosin deficiency. Muscle Nerve 2011;44:590-3.
7. Jang MA, Lee T, Lee J, Cho EH, Ki CS. Identification of a novel de novo variant in the PAX3 gene in Waardenburg Syndrome by diagnostic exome sequencing: the first molecular diagnosis in Korea. Ann Lab Med 2015;35:362-5.
8. Hayashi YK, Tezak Z, Momoi T, Nonaka I, Garcia CA, Hoffman EP, et al. Massive muscle cell degeneration in the early stage of merosin-deficient congenital muscular dystrophy. Neuromuscul Disord 2001;11:350-9.
9. Pegoraro E, Marks H, Garcia CA, Crawford T, Mancias P, Connolly AM, et al. Laminin alpha2 muscular dystrophy: genotype/phenotype studies of 22 patients. Neurology 1998;51:101-10.
10. Richards S, Aziz N, Bale S, Bick D, Das S, Gastier-Foster J, et al. Standards and guidelines for the interpretation of sequence variants: a joint consensus recommendation of the American College of Medical Genetics and Genomics and the Association for Molecular Pathology. Genet Med 2015;17:405-24.