

# Human Sting of *Cephalonomia gallicola* (Hymenoptera: Bethylidae) in Korea

In-Yong Lee<sup>1</sup>, Chang-Seob Shin<sup>2</sup>, Seobo Sim<sup>3</sup>, Jung-Won Park<sup>4</sup>, Tai-Soon Yong<sup>1,\*</sup>

<sup>1</sup>Department of Environmental Medical Biology and Institute of Tropical Medicine, Yonsei University College of Medicine, Seoul 120-752, Korea; <sup>2</sup>Gangnam Clean Pest Control, Seoul 135-862, Korea; <sup>3</sup>Department of Environmental and Tropical Medicine, School of Medicine, Konkuk University, Chungju 380-701, Korea; <sup>4</sup>Department of Internal Medicine, Yonsei University College of Medicine, Seoul 120-752, Korea

**Abstract:** Hymenoptera stings can cause serious injury to humans. We report the clinical findings of 6 cases of Hymenoptera stings. All patients developed painful erythematous papules at the sting sites and had a past history of parasitoid wasp sting. This is the first clinical report of the parasitoid wasp, *Cephalonomia gallicola*, causing human stings in Korea.

**Key words:** *Cephalonomia gallicola*, human sting, Hymenoptera, parasitoid wasp, Korea

## INTRODUCTION

Hymenoptera are one of the medically most important insects. The stings of Hymenoptera, including Apoidea (bees), Vespoidea (wasps, hornets, and yellow jackets), and Formicidae (poneromorph ants), account for the majority of severe allergic reactions to insects [1]. Many of the Hymenoptera are parasitoids. The Bethylidae is a family of Hymenoptera that consist of approximately 82 genera and 2,200 species worldwide have evolved to exploit coleopteran and lepidopteran larvae and pupae, and are often found in cryptic locales such as soil, leaf litter, wood, stems, and seeds.

*Cephalonomia gallicola* (Bethylidae) is a gregarious external parasitoid of the larvae and pupae of the cigarette beetle, *Lasioderma serricorne* (Coleoptera: Anobiidae), which is an injurious pest to stored dried products, other animals and vegetable materials [2]. The Bethylidae is one of the most powerful epizoic parasitoid wasps and contains anesthetic compounds, which cause painful irritation at the site of the sting. Human stings by Bethylidae, a parasitic wasp, have been reported in Europe and North America [3], Japan [4], and New Zealand [5]. In such cases, *Cephalonomia*, *Goniozus*, and *Sclerodermus* species were involved. Those species should be considered as a cause

of allergic responses in patients living in houses with visual evidence of parasitoid wasp infestation. To date, there have been no clinical reported investigations on parasitoid wasp stings in Korea. We describe here the clinical findings of 6 cases of *C. gallicola* sting detected in 2013.

## CASE RECORD

The patients (Table 1) visited the Arthropods of Medical Importance Resource Bank, and were referred to Yonsei University Severance Hospital (Seoul, Korea) because of multiple insect sting markings.

Case 1 was a 39-year-old female with severe pain at the sting sites and had erythematous papules over her hand (Fig. 1). She had no significant abnormalities of the cardiovascular, respiratory, nervous, or gastrointestinal systems. She observed insects in the bedroom of her home and suspected that they were the cause of her complaints. She brought in an insect that had been caught in her bedroom. On examination, the insect was identified to be a female *C. gallicola* (Figs. 2, 3). Casts of *C. gallicola* were found in the food storage room of her home (Fig. 4).

Case 2 was a 35-year-old male with generalized sting marks over his right arm. He was treated with oral antibiotics, oral antihistamines, and topical corticosteroid cream by a physician at private clinic, resulting in an improvement of local symptoms. He did not have any significant problems immediately after being stung, except for local swelling and itching at the sting sites. He also brought in an insect that had been caught in the living room of his home. On examination, the

•Received 6 March 2014, revised 20 August 2014, accepted 31 August 2014.

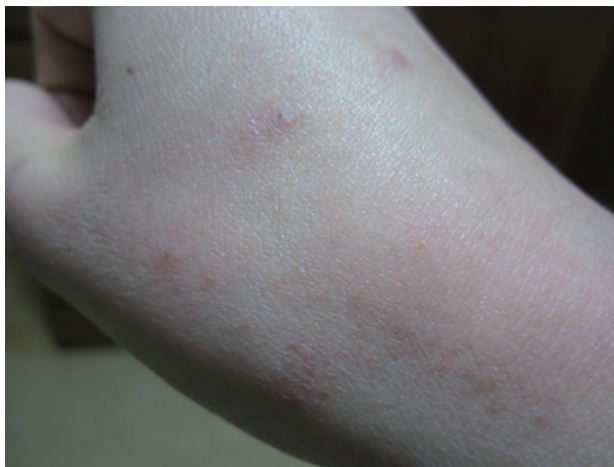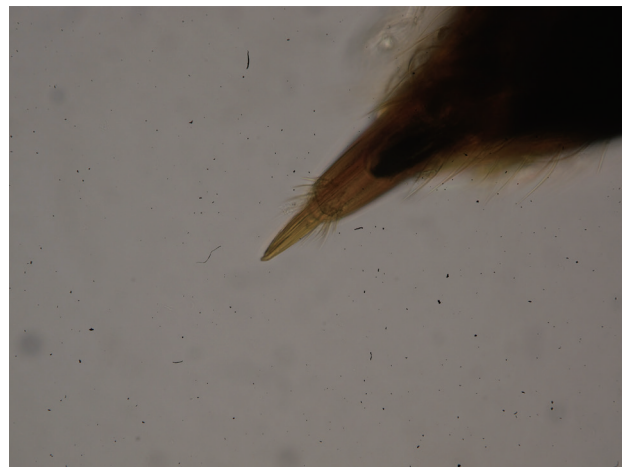
\*Corresponding author (tsyong212@yuhs.ac)

© 2014, Korean Society for Parasitology and Tropical Medicine

This is an Open Access article distributed under the terms of the Creative Commons Attribution Non-Commercial License (<http://creativecommons.org/licenses/by-nc/3.0>) which permits unrestricted non-commercial use, distribution, and reproduction in any medium, provided the original work is properly cited.

**Table 1.** Summary of the clinical finding of 6 cases of *Cephalonomia gallicola* sting in 2013

Patient no.	Time of observation	Sex	Age (year)	Location	No. of lesions	Residence	House type	Sites of sting	Collection of wasps
1	May 10	F	39	hand	7	Sanggye, Seoul	apartment	bedroom	3
2	May 27	M	35	arm	4	Galmal, Gangwon	private	living room	2
3	June 13	F	42	abdomen	3	Gahoe, Seoul	private	living room	1
4	June 29	M	31	leg	3	Seongnam, Gyeonggi	apartment	living room	5
5	July 6	M	51	abdomen	5	Yeonhui, Seoul	apartment	bedroom	2
6	August 3	M	3	arm/leg	3	Ansan, Gyeonggi	private	bedroom	3

**Fig. 1.** Erythematous papules with central punctums on the hand of a patient, caused by *Cephalonomia gallicola*.**Fig. 3.** Apical abdominal segment with a needle-like stinger ( $\times 400$ ).**Fig. 2.** A female of *Cephalonomia gallicola*, whole body. Scale bar=0.5 mm.**Fig. 4.** Cast of *Cephalonomia gallicola*.

insect was identified to be a female *C. gallicola*.

Case 3 was a 42-year-old female with severe pain at the sting sites and erythematous papules over her abdomen. She had no significant abnormalities in any other organ. She brought in an insect that had been caught in the bedroom of her home. On examination, the insect was also identified to be a

female *C. gallicola*.

Case 4 was a 31-year-old female with severe pain at the sting sites and erythematous papules over her left leg. She also brought an insect that had been caught in her bedroom. On examination, the insect was identified to be a female *C. gallicola*.

Case 5 was a 51-year-old male with swelling and itching at

the sting sites and generalized sting marks over his abdomen. He also brought in insects from his bedroom. On examination, the insects were identified to be female *C. gallicola*. His lesions disappeared 1 week after the discovery of the insects without medical treatment of antihistamines or corticosteroids.

Case 6 was a 3-year-old male with signs of redness, swelling, and pain at the sting sites. His father suspected the presence of insects in the boy's bedroom. Three captured specimens were submitted to us for identification and were all found to be female *C. gallicola*. He was treated with topical corticosteroid cream resulting in the subsidence of local symptoms.

Measurements of 16 *C. gallicola* females were obtained from observing the specimens with a microscope equipped with a micrometer. *C. gallicola* while monomorphic, do vary slightly in length and are approximately 1.98 mm to 2.59 mm long (average 2.23 mm) (Table 1). Body usually rounded and brown entirely. Antennae well developed and 12 segmented. Thorax with pronotum bell-shaped. Abdominal segments well developed and postabdomen with a diminutive sting (Figs. 2, 3).

Antihistamines and/or corticosteroids were given to all patients and the signs and symptoms in all patients improved within 2 weeks. Disinfestation of the patients' houses was performed using treatment with commercial insecticide (0.5% permethrin) in all rooms of the house, keeping it sealed. Three days after the insecticide treatment, an investigation was performed to confirm the elimination of insects from the house, and no parasitoid wasp, *C. gallicola*, has been found to date.

## DISCUSSION

Hymenoptera sting is a major clinical problem. Hymenoptera venoms contain many pharmacologically active constituents, including histamine, serotonin, acetylcholine, dopamine, noradrenaline, melittin hyaluronidase, apamin, and phospholipase [1]. The typical human sting reactions include headache, giddiness, nausea, pain at the sting sites, shortness of breath, and anaphylactic responses.

The parasitoid wasp, *C. gallicola*, has a diminutive stinger and stings if it is irritated. Stings from *C. gallicola* causes medical problem. In our case, *C. gallicola* sting was associated with indoor activities. Probably, the females were searching for larval forms of Coleoptera in household. The stings were inflicted on the hands, arms, legs, and abdomen. In case of skin lesions, exhibited redness, swelling, and pain at the sting sites, with the development of pruritic erythematous papules, similar to oth-

er arthropod bites and stings. *C. gallicola* wasp most frequently sting humans during the spring (May) and summer (June-August), though the pattern depends on parasitoid wasp activity in nature.

The parasitoid wasp fauna of Korea, *C. gallicola* [2], *Sclerodermus harmandi* [6], and 5 species of *Goniozus*, including *G. koreanus*, *G. mesolevis*, *G. akitsushimanus*, *G. yoshikawai*, and *G. maurus* [7], have been documented. *Goniozus* and *S. harmandi* are found mainly in the outdoor environment, while *C. gallicola* is found indoors. *C. gallicola* coexist with *Pachycondyla chinensis* in the indoor environment in Korea. *C. gallicola* are very similar to *P. chinensis* morphologically and the 2 are very difficult to distinguish. *C. gallicola* is a wasp and *P. chinensis* is an ant. *P. chinensis* was reported to be the only ant sting in the home environment. These stinging ants included a total of 12 species in 6 genera of the poneromorph group in Korea [8]. Anaphylactic reactions were occasionally induced by *P. chinensis* [9-11]. An ant sting can cause a wide range of allergic responses in sensitized individuals. The sensitization rate to *P. chinensis* was found to be 23.0% in residents living in an endemic area, and 2.1% of the residents were reported to have a history of systemic allergic reactions to the ant in Korea [11].

The characteristic morphology of the skin lesion and history are very important in making the diagnosis of Hymenoptera sting. Skin lesions can be similar to various types of dermatitis and other skin pathologies. Diagnosis should be based on the history and physical findings of Hymenoptera sting. The skin lesions caused by *C. gallicola*, an etiologic diagnosis may be difficult. Confirming the diagnosis of a *C. gallicola*, sting is sometimes difficult to be suspected unless to obtain a detailed explanation of the home environment.

The clinical diagnosis of *C. gallicola* sting should take into accounts the many potential reactions to the insect's bite/sting. Further investigations are necessary to examine the possibility of cross sensitization between allergic disorders caused by *C. gallicola* and *P. chinensis*.

To the best of our knowledge, this is the first clinical findings report of human stings by the parasitoid wasp, *C. gallicola*, in Korea.

## ACKNOWLEDGMENTS

This study was supported in part by the National Research Foundation of Korea (NRF-2012M3A9B8021806). We thank Prof. Seunghwan Lee, Division of Entomology, Seoul National

University, Korea for his kind assistance in the identification of specimens.

### CONFLICT OF INTEREST

We have no conflict of interest related to this study.

### REFERENCES

1. Fitzgerald KT, Flood AA. Hymenoptera stings. *Clin Tech Small Anim Pract* 2006; 21: 194-204.
2. Lim J, Oh M, Lee J, Lee S. *Cephalonomia gallicola* (Hymenoptera: Bethylidae), new to Korea, an ectoparasitoid of the cigarette beetle, *Lasioderma serricorne* (Coleoptera: Anobiidae). *J Asia-Pacific Entomol* 2007; 10: 335-338.
3. Papini PA. A case of stings in humans caused by *Sclerodermus* sp. in Italy. *J Venom Anim Toxins Incl Trop Dis* 2014; 20: 11.
4. Oda T, Mori A, Fujita K, Monkada L, Tachikawa T, Tanaka S. A case of the sting of a parasitic wasp, *Sclerodermus* sp. (Hymenoptera: Bethylidae). *Trop Med (Nagasaki, Japan)* 1981; 23: 213-216.
5. Harris AC. The effects on a human of the sting of *Goniozus antipodum* (Hymenoptera: Bethylidae). *New Zealand Entomol* 1996; 19: 49.
6. Hong JI, Koh SH, Chung YJ, Shin SC, Kim GH, Choi KS. Biological characteristics of *Sclerodermus harmandi* (Hymenoptera: Bethylidae) parasitized on cerambycid. *Korean J Appl Entomol* 47: 133-139 (in Korean).
7. Lim J, Lee S. Review of *Goniozus* Förster, 1856 (Hymenoptera: Bethylidae) of Korea, with descriptions of two new species. *Zootaxa* 2012; 3414: 43-57.
8. Lyu D. Taxonomic study on the poneromorph subfamilies group (Hymenoptera: Formicidae) in Korea. *Korean J Appl Entomol* 2008; 47: 315-331.
9. Yun YY, Ko SH, Park JW, Hong CS. Anaphylaxis to venom of the *Parchycondyla* species ant. *J Allergy Clin Immunol* 1999; 104: 879-882.
10. Kim SS, Park HS, Kim HY, Lee SK, Nahm DH. Anaphylaxis caused by the new ant, *Parchycondyla chinensis*: demonstration of specific IgE and IgE-binding components. *J Allergy Clin Immunol* 2001; 107: 1095-1099.
11. Cho YS, Lee YM, Lee CK, Yoo B, Park HS, Moon HB. Prevalence of *Parchycondyla chinensis* venom allergy in an ant-infested area in Korea. *J Allergy Clin Immunol* 2002; 110: 54-57.