Kor J Oral Maxillofac Pathol 2013;37(6):323-326

# 임플란트 식립부의 백반증에서 편평세포암종으로 이생된 1예 보고

양동현[1)], 차인호[2)], 김진[1)*]

연세대학교 치과대학 구강병리학교실, 구강종양연구소[1)], 연세대학교 치과대학 구강악안면외과학교실[2)]

〈Abstract〉

## Malignant Transformation of Oral Leukoplakia into Oral Squamous Cell Carcinoma in the Vicinity of Osseointegrated Dental Implants

*Dong Hyun Yang[1)], In Ho Cha[2)], Jin Kim[1)*]*

*Department of Oral Pathology, Oral Cancer Research Institute[1)],*
*Department of Oral and maxillofacial Surgery[2)], College of Dentistry, Yonsei University*

Development of squamous cell carcinoma around dental implants is an uncommon clinical manifestation with only a few cases described in the literature. Recently, we observed primary squamous cell carcinoma that developed from leukoplakia around dental implants. We report this case to emphasize the importance of careful oral examination, for implant surgery has to be preceded by thorough evaluation of oral mucosal conditions.

*Key words* : Squamous cell carcinoma, Dental implant

## Ⅰ. INTRODUCTION

Since the Branemark osseointegrated implant system was developed, it has become a very useful and reliable practice for many dentists to replace lost teeth with dental implants. Some authors even regard implant treatment as the gold standard in dental rehabilitation[1)]. However, as the use of dental implants increases, more cases of adverse side effects including the occurrence of oral squamous cell carcinoma (SCC) have been reported[2,3)]. Here, we report a case of primary SCC around dental implants and discuss the potential role of osseointegrated dental implant in SCC development.

## Ⅱ. CASE REPORT

A 48-year-old Korean male was referred to Yonsei University Dental Hospital for the evaluation and treatment of a whitish lesion on the left maxillary gingiva 4 years ago. Intraoral examination revealed an ill-defined whitish patch lesion around the left maxillary first and second molars, which was not removed by gauze cleaning or finger rubbing (Fig. 1A). Panoramic radiographic image showed severe vertical alveolar bone loss around the left maxillary second molar (Fig. 1B). After the extraction of left maxillary second molar due to severe alveolar bone loss, incisional

* Correspondence: Professor Jin Kim, Department of Oral Pathology, Oral Cancer Research Institute
Yonsei University College of Dentistry, 50 Yonsei-ro, Seodaemun-gu, Seoul, 120-752, South Korea,
Tel: +82-2-2228-3031, Fax: +82-2-392-2959, E-mail: jink@yuhs.ac

* Acknowledgements: This study was supported by Professor Research Grant from Yonsei University College of Dentistry (6-2013-0081). The authors would also like to extend sincere thanks to Doo Young Lee for his thorough review of this manuscript.

Received: Oct 10, 2013; Revised: Oct 14, 2013; Accepted: Oct 21, 2013

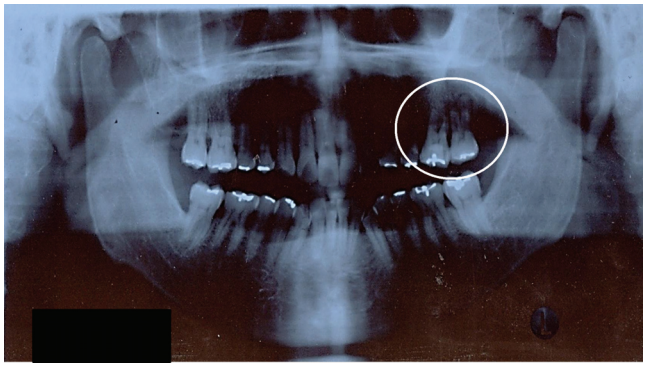

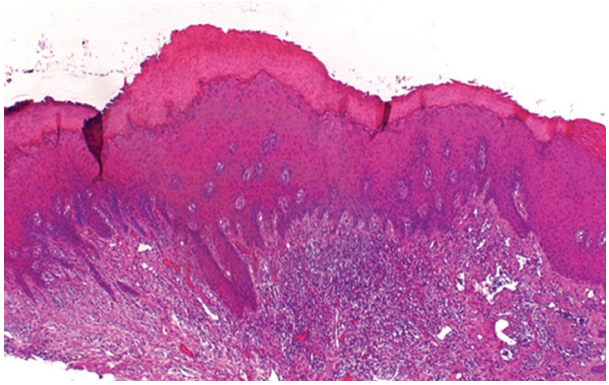

**Fig. 1A.** Clinical photo taken prior to implant installation shows whitish patch lesion on #26, 27 which could not be removed by gauze cleaning or finger rubbing.

**Fig. 1B.** Panoramic radiograpy reveals severe vertical alveolar bone loss on #26, 27.

**Fig. 1C.** Histologic examination reveals hyperkeratosis and epithelial hyperplasia (hematoxylin-eosin, original magnification x40).

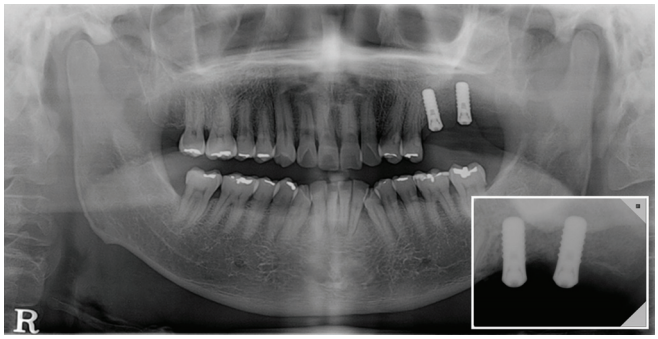


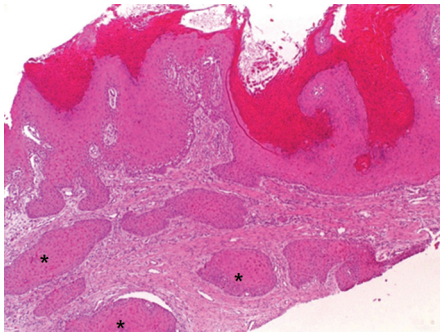

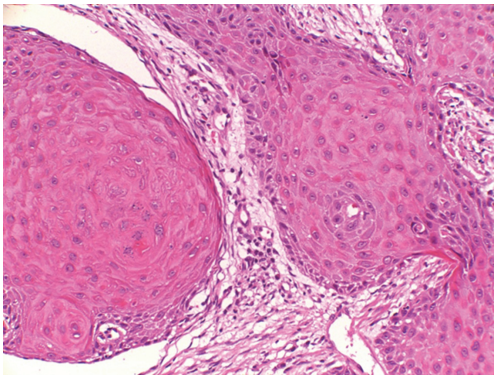

**Fig. 2A.** Clinical photo shows relatively ill-defined whitish lesion with slight bleeding tendency around the implants.

**Fig. 2B.** Panoramic and periapical (inserted image) radiography reveals crestal bone loss around #26, 27 implants.

**Fig. 2C.** Histologic examination reveals islands of malignant squamous epithelium* invading into the underlying connective tissue (hematoxylin-eosin, original magnification ×40)

**Fig. 2D.** Histologic examination reveals malignant squamous carcinoma cell nets showing prominent nucleoli (hematoxylin-eosin, original magnification x200)

biopsy of the adjacent mucosa was performed. At microscopic examination, biopsy specimen revealed marked hyperkeratosis with epithelial hyperplasia, and this histologic finding was clinically compatible with leukoplakia (Fig. 1C). Four years later, the patient had dental implants installed on the left maxillary first and second molar regions at a personal dental clinic. One month after the implant installation, he visited our hospital for the evaluation of whitish lesion around the dental implants. Upon oral examination, an irregularly shaped whitish lesion with several ulcerative reddish foci was found in the vicinity of the implant installation sites (Fig. 2A). Radiographic image showed crestal bone loss around the dental implants, mimicking peri-implantitis (Fig. 2B). Incisional biopsy was performed, and the lesion was confirmed histologically as invasive SCC (Fig. 2C,D). Left partial maxillectomy was subsequently performed, and there has been no evidence of recurrence in a 6-year follow-up.

## Ⅲ. DISCUSSION

Leukoplakia is defined by the World Health Oraganization (WHO) as "a whitish patch or plaque that cannot be characterized clinically or pathologically as any other disease". The term is strictly a clinical one and does not imply a specific histopathological tissue alteration[4]. Even so, leukoplakia is typically considered to be a premalignant lesion with a frequency of malignant transformation between 17% and 35%[5]. If a premalignant lesion is present in the vicinity of an implant installation site, mechanical trauma inflicted by the implantin stallation can facilitate malignant transformation by triggering dysplastic changes. *Block et al.* reported that a 72-year-old male who had leukoplakia around the implant insertion site at the time of implant installation developed SCC 5 months later, similar to our case[2]. *Schache et al.* suggested that osseointegrated implants may facilitate the spread of mucosal SCC into cancellous bone through the implant-bone interface[3]. Therefore, clinicians should perform thorough oral examination before dental implant installation to warn patients with premalignant or malignant lesions against the possible side effects of undergoing implant surgery. If patients already have premalignant or suspected lesions around dental implants, periodic follow-ups and adequate biopsies will have to be performed to prevent further progression. Moreover, an alternative treatment option should be considered as a substitute for the implant surgery.

## Ⅳ. REFERENCES


1. Moshref M, Jamilian A, Lotfi A, et al: Oral squamous cell carcinoma associated with a dental implant - a case report and literature review. J C Exp Dent 2011;166-168.
2. Block MS, Scheufler E: Squamous cell carcinoma appearing as peri-implant bone loss: a case report. J Oral Maxillofac Surg 2001;59:1349-1352.
3. Schache A, Thavaraj S, Kalavrezos N: Osseointegrated implants: a potential route of entry for squamous cell carcinoma of the mandible. Br J Oral Maxillofac Surg 2008;46:397-399.
4. Neville BW, Damm DD, Allen CM, et al: Oral and maxillofacial pathology. 3rd ed. Philadelphia: Saunders, 2009:388.
5. Liu W, Wu L, Shen XM, et al: Expression patterns of cancer stem cell markers ALDH1 and CD133 correlate with a high risk of malignant transformation of oral leukoplakia. Int J Cancer 2013;132:868-874.