



## Original Article

# Nonvisible tumors on multiparametric magnetic resonance imaging does not predict low-risk prostate cancer

Seung Hwan Lee <sup>1</sup>, Kyo Chul Koo <sup>2</sup>, Dong Hoon Lee <sup>3</sup>, Byung Ha Chung <sup>2,\*</sup>

<sup>1</sup> Department of Urology, Severance Hospital, Yonsei University College of Medicine, Seoul, South Korea

<sup>2</sup> Department of Urology, Gangnam Severance Hospital, Yonsei University Health System, Seoul, South Korea

<sup>3</sup> Department of Urology, Busan National University College of Medicine, Busan, South Korea

## ARTICLE INFO

## Article history:

Received 10 August 2015

Received in revised form

20 September 2015

Accepted 24 September 2015

Available online 8 October 2015

## Keywords:

Active surveillance

Low risk

Magnetic resonance imaging

Prostate cancer

## ABSTRACT

**Purpose:** To determine whether multiparametric MRI could help predict the diagnosis of low-risk prostate cancer (PCA).

**Methods:** We retrospectively analyzed consecutive 623 patients with PCA who underwent multiparametric MRI before radical prostatectomy (RP). High-resolution T1- and T2-weighted, diffusion-weighted, and dynamic precontrast and postcontrast image sequences were obtained for each patient. Of the 623 patients, 177 (28.4%) exhibited non visible tumors on MRI of clinical stage T1c. The imaging results were compared with the pathological findings with respect to both stage and Gleason scores (GS).

**Results:** Of the 177 prostatectomy patients with non visible tumors on MRI, pathological findings resulted in the upgrading of 49 (27.7%) patients to a sum of GS 7 or more. 101 (57.1%) patients exhibited tumor volumes greater than 0.5cc. The biochemical recurrence rate was significantly higher in the pathological upgraded group compared with the nonupgraded group after a mean follow-up time of 29 months. In the multiple logistic analysis, non visible tumor on MRI was not a significant predictor of low-risk PCA.

**Conclusions:** Even though cancer foci were not visualized by postbiopsy MRI, the pathological tumor volumes and extent of GS upgrading were relatively high. Therefore, nonvisible tumors by multiparametric MRI do not appear to be predictive of low-risk PCA.

Copyright © 2015 Asian Pacific Prostate Society, Published by Elsevier. All rights reserved.

## 1. Introduction

The detection of low-risk prostate cancer (PCA) has increased as cancer screening programs and detection mechanisms have improved.<sup>1</sup> Since the number of patients diagnosed with low-risk PCA has increased in recent times, the ability to precisely localize tumor foci within the prostate has become an important goal. Accurately identifying the positions of PCA tumors would increase staging accuracy, improve patient selection for active surveillance (AS), and facilitate treatment planning.<sup>2</sup>

A growing body of evidence indicates that AS is the most suitable approach for a select group of men with low-risk PCA.<sup>3</sup> However, pretreatment diagnosis of low-risk PCA is often

difficult since PCA is a multifocal, heterogeneous disease.<sup>4</sup> Moreover, the current criteria used to define low-risk PCA cannot reliably determine whether AS is the best treatment option for each patient. Some studies have reported that even low-risk PCA may demonstrate disease upgrading or upstaging.<sup>5,6</sup> Even known indicators of the severity of PCA, such as prostate-specific antigen (PSA) kinetics or initial biopsy results at the time of PCA diagnosis, do not reliably predict adverse pathology when men are monitored by AS.<sup>7</sup> Therefore, imaging techniques have played an increasingly important role in the management of localized PCA. However, no imaging modality presently available is able to measure the actual cancer volume.<sup>8</sup> Moreover, no current criteria for AS reliably includes clinical staging based on the imaging modality. Therefore, the aim of the present study was to determine whether multiparametric magnetic resonance imaging (MRI) could help predict the diagnosis of low-risk PCA. Focusing on nonvisible tumors on multiparametric MRI of clinical stage T1c, we assessed the clinicopathological relationships between the biopsy and pathological results.

\* Corresponding author. Department of Urology, Yonsei University College of Medicine, Gangnam Severance Hospital, 712 Eonju-ro, Gangnam-gu, Seoul, South Korea.

E-mail address: [chung646@yuhs.ac](mailto:chung646@yuhs.ac) (BH Chung).

## 2. Materials and methods

We retrospectively analyzed 623 consecutive patients with PCA who underwent multiparametric MRI before radical prostatectomy (RP) at our institution. Patients who had undergone prostate biopsy at another institution, hormone therapy, or radiation therapy before the RP were excluded from the study.

All patients underwent a transrectal, ultrasound-guided 12-core needle biopsy. In all patients, the serum PSA level was obtained before digital rectal examination and transrectal ultrasonography. Clinical staging was performed according to the TNM staging system, and the ellipsoid formula was used to derive the prostate volume via transrectal ultrasonography.

For all clinical staging protocols, all patients underwent imaging using a 3.0T MRI system (Intera Achieva 3.0T, Phillips Medical System, Best, The Netherlands) equipped with a phased array coil (6-channel) before RP. All patients also underwent diffusion weighted-MRI, in addition to the routine prostate MRI protocol used at our institution. Two b values (0 and 1,000) were used, and diffusion restriction was quantified using ADC mapping. T2-weighted images were acquired in three orthogonal planes (axial, sagittal, and coronal). Dynamic contrast-enhanced MRI was also performed. All images were retrospectively reviewed by two experienced urologists who were blinded to biopsy results and who conducted a consensus review of the MRI of all patients.

Of the 623 patients included in the analysis, 177 (28.4%) had a nonvisible tumor on MRI of clinical stage T1c. The imaging results were then compared with the pathological findings with respect to stage and Gleason score (GS). All biopsy and RP specimens were reviewed by a single genitourinary pathologist, and all biopsy cores were individually labeled. For each biopsy protocol, the number of cores containing tumor tissue, the total length of tissue sampled, the total length of the cancer detected, and the GS were determined. Transverse whole-mount step section specimens were obtained at 3–4mm intervals on a parallel plane, and the genitourinary pathologist followed a standardized processing and reporting protocol.<sup>9</sup> Tumor volume (cc) was evaluated by visual estimation. Tumor area was measured in the x and y diameters, and the tumor area was then multiplied by the tumor depth, as determined by the presence of the tumor in subsequent sections and the thicknesses of those sections. The total sum of all tumor foci corresponded to the estimated tumor volume. To achieve objective interpretation, another reviewer integrated the radiology and pathology results.

Clinicopathologic outcomes were compared using the Chi-square test and independent *t* test for categorical and continuous variables, respectively. Low-risk PCA was defined as an organ-confined, postoperative GS 6 tumor with a volume less than 0.5 cm<sup>3</sup>. For AS, the criteria outlined in the Prostate Cancer Research International: Active Surveillance protocol were used. The inclusion criteria for Prostate Cancer Research International: Active Surveillance include: a biopsy GS ≤ 6, a PSA level ≤ 10 ng/mL, a PSA density ≤ 0.2 ng/mL/cm<sup>3</sup>, and no more than two positive cores. However, only patients with tumors of clinical stage T1c were included for AS in this study. Multivariate logistic regression analysis was then performed to identify predictors of low-risk PCA. All statistical tests were two-tailed and were performed using SPSS version 20.0 software (SPSS Inc., Chicago, IL, USA). A *P* value < 0.05 was considered statistically significant.

## 3. Results

The patient ages in this study ranged from 48 years to 74 years (mean ± standard deviation, 63.3 ± 6.2 years), and the serum PSA levels at diagnosis ranged from 3.2 ng/mL to 21.7 ng/mL (mean ± standard deviation, 6.0 ± 1.9 ng/mL). The median

biopsy GS was 6 (range, 3–9). The mean interval between the transrectal ultrasound-guided biopsy and the postbiopsy MRI was 22.0 ± 1.3 days (range, 2–32 days). In all patients, RP was performed within 52 days (range, 6–52 days; median 21 days) after MR imaging.

The pathological findings of the 177 patients with nonvisible tumors on MRI (clinical stage T1c) before RP are shown in Table 1. These pathological findings resulted in the upgrading of 49 (27.9%) patients to a sum of GS 7 or more. One hundred and one (57.1%) patients exhibited a tumor volume greater than 0.5 cc. The numbers of patients with tumors of pathological stage T2 and T3 or above were 126 (71.0%) and 51 (29.0%), respectively.

The clinicopathological findings in the pathological upgraded group (*N* = 49) and the pathological nonupgraded group (*N* = 128) are compared in Table 2. Both the average level of PSA and the average PSA density were significantly different between the two groups (*P* < 0.01). Interestingly, the average number of cores involved and the maximum core diameters were significantly higher in the pathological upgraded group compared with the pathological nonupgraded group, even though the average GS at biopsy were not significantly different between the two groups (*P* = 0.02 and *P* < 0.01, respectively). Furthermore, the biochemical recurrence rate (BCR) was significantly higher after the follow-up period (mean, 29 months) in the pathological upgraded group compared with the nonupgraded group (*P* < 0.01; Table 2).

Of the 39 patients with tumors of clinical stage T1c who met the criteria for AS, seven patients (17.9%) showed pathological GS upgrading, and three patients (7.7%) were classified as pathological stage T3 or above. However, of the 138 patients with tumors of clinical stage T1c who did not meet the criteria for AS, 42 patients (30.4%) showed pathological GS upgrading, and 48 patients (34.8%) were classified as pathological stage T3 or above. Candidates who did not meet the criteria for AS and who exhibited nonvisible tumors on MRI had significantly higher incidences of pathological upgrading and upstaging compared with candidates who meet the criteria for AS with nonvisible tumors on MRI (*P* < 0.01 and *P* = 0.02, respectively). Of the entire study cohort, nonvisible tumors on MRI were detected in 177 patients (28.4%), whereas 446 patients (71.6%) had visible tumors (Fig. 1). No significant differences in the extent of pathological GS upgrading, staging classifications, or BCR rates were observed between the two groups.

Using multivariate logistic regression analysis to predict the development of low-risk PCA, both PSA level and PSA density were significantly associated with an increased likelihood for developing low-risk PCA. However, tumor visibility on the preoperative MRI scan did not exhibit this association (Table 3).

**Table 1**  
Pathological findings from analyses of radical prostatectomy specimens from patients preoperatively classified as clinical stage T1c.

Findings	No. of patients (%)
Total no. of patients	177
Pathological Gleason score	
Upgraded	49 (27.9)
Downgraded	26 (14.7)
Identical	102 (57.6)
Stage	
T2a	53 (29.9)
T2b	51 (28.7)
T2c	22 (12.4)
≥T3	51 (29.0)
Positive surgical margin	62 (35.5)
Tumor volume (cc)	
0–0.5	76 (42.9)
>0.5	101 (57.1)

**Table 2**

Comparison of Clinicopathological Findings Between the Pathological Upgraded Group and the Nonupgraded Group from Analyses of Radical Prostatectomy Specimens from Patients Preoperatively Classified as Clinical Stage T1c.

	Pathological upgrading	No pathological upgrading	P
No.	49	128	
Age (y)	63.6 (49–71)	63.1 (48–74)	0.45
Interval from biopsy to MRI (d)	21.8 (2–25)	22.1 (2–29)	0.32
DRE-positive finding (N)	6 (12.2)	13 (10.1)	0.09
PSA (ng/mL)	6.5 (3.5–19.3)	5.1 (3.2–21.7)	<0.01
PSA density	0.20 (0.07–0.67)	0.15 (0.10–0.45)	<0.01
Prostate volume (cc)	30.2 (16.4–64.5)	33.7 (14.8–71.3)	0.13
Biopsy findings			
Gleason score	5.9 ± 0.7	5.8 ± 0.4	0.24
No. of involved cores	2.1 ± 3.3	1.6 ± 1.9	0.02
Maximal tumor diameter (mm)	19.2 ± 2.8	11.8 ± 1.7	<0.01
Final stage			<0.01
≤T2	7 (14.3)	119 (92.9)	
≥T3	42 (85.7)	9 (7.1)	
Positive surgical margin	44 (89.8)	18 (10.2)	<0.01
Tumor volume (cc)			<0.01
≤0.5	13 (26.5)	88 (68.8)	
>0.5	36 (73.5)	40 (31.2)	
BCR (N)	11 (22.4)	6 (4.7)	<0.01

Data are presented as n (%), mean (range), or mean ± standard deviation.

BCR, biochemical recurrence; DRE, digital rectal examination; MRI, magnetic resonance imaging; PSA, prostate-specific antigen.

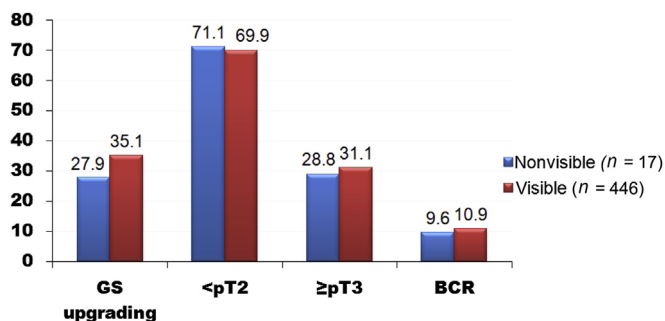
#### 4. Discussion

Since the widespread use of PSA testing has dramatically increased the number of low-risk PCA cases identified, more precise clinical staging would allow the most appropriate candidates to proceed with AS. However, since clinical staging is still imperfect, patients with PCA who choose AS also take a calculated risk. Several lines of evidence indicate that a significant proportion of patients who are suitable for AS, at least according to the most commonly adopted criteria, have unfavorable PCA characteristics discovered if they undergo RP.<sup>10,11</sup> Klotz et al<sup>12</sup> recently demonstrated that up to 50% of all patients who are treated after an initial period of observation develop BCR; this finding questions the ability of AS to maintain the window of curability in patients who have low-risk PCA characteristics at diagnosis.<sup>12</sup> Conti et al<sup>13</sup> reported that 28% of all men who met the AS criteria also had GS upgrading, 21% experienced extracapsular extension, and 11% had seminal vesicle invasion at RP. To ensure that AS is used appropriately, providers must more accurately predict the likelihood of progression in patients. In the context of accurate clinical staging, MRI is playing an increasingly important role in the selection of suitable candidates for AS.

In the present study, we collected data on nonvisible tumors on MRI foci in both AS candidates and also in patients who were not chosen for AS. Of all the patients found to have nonvisible tumors

on MRI, 78% were not eligible for AS. We had hypothesized that men with nonvisible tumors on MRI at the time of staging would have more favorable pathologic features compared with men in whom MRI-visible tumors were observed. Interestingly, however, pathologic parameters such as GS upgrading, staging upgrading, and BCR did not significantly differ between the MRI-visible versus the nonvisible tumor on MRI groups (Fig. 1). Guzzo et al<sup>14</sup> reported that a small but significant percentage of men who are thought to have low-risk, low-volume PCA at the time of clinical staging by MRI are actually understaged and are more appropriate candidates for immediate intervention. These results call into question the clinical usefulness of MRI, especially in the context of evaluating the characteristics of low-volume tumors. Roethke et al<sup>15</sup> reported that MRI was unable to detect tumors with diameters and volumes smaller than 10 mm and 0.4 cm<sup>3</sup>, respectively. Moreover, MRI has been shown to be unsuitable for visualizing tumor foci with a maximum size of 0.3 cm; importantly, 3% of all tumors are sized between 0.3 cm and 0.5 cm, whereas 13% are sized between 1 cm and 0.5 cm. Volume-dependent detection has been shown to have a detection rate of 4% for tumors less than 0.5 mL in volume; this rate increased to 89% for tumors 2 mL or more in volume. Rosenkrantz et al<sup>16</sup> observed biological differences between tumors that were detected by MRI and tumors that were missed by MRI. Desmoplastic stroma was present in all detected tumors, and the overall detection of solid tumor growth had an odds ratio of 17.8. This result highlights the importance of the formation of a discrete nodule of continuous tumor growth to enable MRI detection. Given these findings, the inability to visualize a known tumor by MRI may indicate the lack of a distinct nodule of malignant glands encompassed by the tumor.<sup>16</sup>

In our study, of the 177 patients with nonvisible tumors on MRI, 76 (42.9%) exhibited a tumor volume greater than 0.5 cc in the final pathology examination. Several factors might contribute to the low detection rate of tumors of relatively high volumes. First, central gland and transitional gland tumors are considered more difficult to detect with MRI and would likely not have been observed. Transitional zone tumors have also been shown to be difficult to distinguish from benign hyperplasia nodules, even though their specific T2w image features have been recently described.<sup>17</sup> Furthermore, the role of dynamic contrast-enhanced MRI in the diagnosis of central gland tumors is limited. Padhani et al<sup>18</sup>



**Fig. 1.** Comparison of pathological findings between nonvisible tumor versus visible tumor on magnetic resonance image. BCR, biochemical recurrence; GS, Gleason score.

**Table 3**  
Significant Predictors of Low-risk Prostate Cancer According to Multiple Logistic Regression Analysis.

Variable	Odds ratio (95% CI)	P
Age (y)	1.031 (0.843–3.117)	0.483
PSA	1.384 (1.103–2.011)	0.027
PSA density	1.294 (1.083–1.847)	0.031
Biopsy Gleason score		
Gleason score ≤ 6	Reference	
Gleason score > 6	0.818 (0.467–1.319)	0.095
% positive cores in the biopsy	0.955 (0.816–1.420)	0.305
No. of positive cores	0.913 (0.658–1.275)	0.123
MRI findings		
Nonvisible tumor	Reference	
Visible tumor	0.895 (0.315–1.388)	0.092

CI, confidence interval; MRI, magnetic resonance imaging; PSA, prostate-specific antigen.

described a complete overlap in the enhancement characteristics between cancer and *benign prostatic hyperplasia*; this high degree of similarity between the two was explained by the increased microvessel density in *benign prostatic hyperplasia*, which is similar to that in cancer. Secondly, we did not exclude any cases based on the delay between the biopsy and the MRI scan; thus, postbiopsy hemorrhage may have influenced tumor detection in some cases. However, as shown in Table 2, the interval from biopsy to MRI in our study was relatively short compared with other studies.<sup>19,20</sup> No consensus has yet been reached regarding the optimal timing of MRI for acute staging. In our previous report,<sup>21</sup> a significant negative correlation between the amount of postbiopsy hemorrhage and the time from the biopsy to the MRI scan was observed, even though no significant differences in cancer localization were observed between the MRI data and the final pathology data. Qayyum et al<sup>19</sup> suggested that MRI and MR spectroscopic imaging should be conducted at least 8 weeks postbiopsy since hemorrhaging was found to be decreased by that time. However, hemorrhages do not actually appear to interfere with the ability of MRI to detect tumor characteristics since no significant difference was observed in the interval from biopsy to MRI between the pathological upgraded and nonupgraded groups. Future studies are needed to clarify the precise effects of postbiopsy hemorrhage on the accuracy of MRI-based diagnostic approaches.

Most previous studies have included AS patients who underwent MRI.<sup>14,22,23</sup> Guzzo et al<sup>14</sup> reported that the extent of tumor visibility on the T2W-MRI scans was not predictive of the pathologic features of RP specimens, and that T2W-MRI scans could not provide additional useful information for candidates undergoing AS. Moreover, Ploussard et al<sup>24</sup> showed that standard MRI was not a useful marker to improve the selection for AS when an extended 21-core biopsy scheme was used. D'Amico et al<sup>25</sup> found that preoperative endorectal MRI imparted prognostic information that was only incrementally important compared with standard clinical factors such as stage, GS, and PSA level; however, this study only included patients with intermediate to high-risk disease. However, prostate MRI has been shown to have a significant value for the identification of extracapsular extension and seminal vesicle invasion.<sup>26,27</sup> These benefits were primarily detected in patients with intermediate or high risk PCA.<sup>28</sup> Rais-Bahrami et al<sup>29</sup> found that multiparametric MRI more accurately detected and characterized tumors in patients with disease of GS 7 or higher. The 2013 NCCN guideline recommends pelvic computed tomography or MRI scanning if T3 or T4 disease is present, or if T1 or T2 disease is present and a nomogram indicates that the chance of lymph node involvement is greater than 20%; however, staging studies may not be cost-effective until the chance of lymph node involvement reaches 45%.<sup>30</sup> From these results, the role of prostate MRI in the detection of low-risk PCA is not

yet clear. To elevate the accuracy of staging low-risk PCA, additional MR techniques, such as MR spectroscopy, will likely be necessary.

The present study did have several limitations. Firstly, our study had a retrospective design and a relatively small sample size. Moreover, our study may have been subject to some degree of selection bias since only patients who underwent RP were enrolled. In addition, our data were collected at a single institution; thus, our study is also subject to the limitations and biases of any analysis based on treatment outcomes from a single center. Secondly, as we previously mentioned, the length of time from the biopsy to the MRI scan was not factored into our study analysis. This may have affected our results since hemorrhages are more likely to interfere with MRI detection in patients with shorter intervals from biopsy to MRI. However, our multiparametric MRI protocol including pre-contrast T1WI can overcome this limitation because areas of hemorrhage will also be characteristically hyper-intense on T1WI.

Even though cancer foci were not visualized with postbiopsy MRI, pathological tumor volumes and the extent of GS upgrading were relatively high in our study. Therefore, nonvisible tumors on multiparametric MRI do not appear to predict the development of low-risk PCA.

### Conflicts of interest

All authors have no conflict of interest to declare.

### References

- Yin M, Bastacky S, Chandran U, Becich MJ, Dhir R. Prevalence of incidental prostate cancer in the general population: a study of healthy organ donors. *J Urol.* 2008;179:892–5. discussion 895.
- Rouvière O, Papillard M, Girouin N, Boutier R, Rabilloud M, Riche B, et al. Is it possible to model the risk of malignancy of focal abnormalities found at prostate multiparametric MRI? *Eur Radiol.* 2012;22:1149–57.
- Klotz L. Active surveillance with selective delayed intervention for favorable risk prostate cancer. *Urol Oncol.* 2006;24:46–50.
- Carter HB, Epstein JI. Prediction of significant cancer in men with stage T1c adenocarcinoma of the prostate. *World J Urol.* 1997;15:359–63.
- Pepe P, Candiano G, Fraggetta F, Galia A, Grasso G, Aragona F. Is transition zone sampling at repeated saturation prostate biopsy still useful? *Urol Int.* 2010;85:324–7.
- Thong AE, Shikanov S, Katz MH, Gofrit ON, Eggner S, Zagaja GP, et al. A single microfocus (5% or less) of Gleason 6 prostate cancer at biopsy—can we predict adverse pathological outcomes? *J Urol.* 2008;180:2436–40.
- Ross AE, Loeb S, Landis P. Prostate-specific antigen kinetics during follow-up are an unreliable trigger for intervention in a prostate cancer surveillance program. *J Clin Oncol.* 2010;28:2810–6.
- Haider MA, van der Kwast TH, Tanguay J, Evans AJ, Hashmi AT, Lockwood G, et al. Combined T2-weighted and diffusion-weighted MRI for localization of prostate cancer. *AJR Am J Roentgenol.* 2007;189:323–8.
- McNeal JE, Redwine EA, Freiha FS, Stamey TA. Zonal distribution of prostatic adenocarcinoma. Correlation with histologic pattern and direction of spread. *Am J Surg Pathol.* 1988;12:897–906.
- Suardi N, Capitanio U, Chun FK, Graefen M, Perrotte P, Schlomm T, et al. Currently used criteria for active surveillance in men with low-risk prostate cancer: an analysis of pathologic features. *Cancer.* 2008;113:2068–72.
- Ploussard G, Xylinas E, Salomon L, Allory Y, Vordos D, Hoznek A, et al. The role of biopsy core number in selecting prostate cancer patients for active surveillance. *Eur Urol.* 2009;56:891–8.
- Klotz L, Zhang L, Lam A, Nam R, Mamedov A, Loblaw A. Clinical results of long-term follow-up of a large, active surveillance cohort with localized prostate cancer. *J Clin Oncol.* 2010;28:126–31.
- Conti SL, Dall'era M, Fradet V, Cowan JE, Simko J, Carroll PR. Pathological outcomes of candidates for active surveillance of prostate cancer. *J Urol.* 2009;181:1628–33. discussion 1633–4.
- Guzzo TJ, Resnick MJ, Canter DJ, Bivalacqua TJ, Rosen MA, Bergey MR, et al. Endorectal T2-weighted MRI does not differentiate between favorable and adverse pathologic features in men with prostate cancer who would qualify for active surveillance. *Urol Oncol.* 2012;30:301–5.
- Roethke MC, Lichy MP, Jurgschat L, Hennenlotter J, Vogel U, Schilling D, et al. Tumorsize dependent detection rate of endorectal MRI of prostate cancer—a histopathologic correlation with whole-mount sections in 70 patients with prostate cancer. *Eur J Radiol.* 2011;79:189–95.
- Rosenkrantz AB, Mendrinós S, Babb JS, Taneja SS. Prostate cancer foci detected on multiparametric magnetic resonance imaging are histologically distinct from those not detected. *J Urol.* 2012;187:2032–8.



17. Oto A, Kayhan A, Jiang Y, Tretiakova M, Yang C, Antic T, et al. Prostate cancer: differentiation of central gland cancer from benign prostatic hyperplasia by using diffusion-weighted and dynamic contrast-enhanced MR imaging. *Radiology*. 2010;257:715–23.
18. Padhani AR, Gapinski CJ, Macvicar DA, Parker GJ, Suckling J, Revell PB, et al. Dynamic contrast enhanced MRI of prostate cancer: correlation with morphology and tumour stage, histological grade and PSA. *Clin Radiol*. 2000;55:99–109.
19. Qayyum A, Coakley FV, Lu Y, Olpin JD, Wu L, Yeh BM, et al. Organ-confined prostate cancer: effect of prior transrectal biopsy on endorectal MRI and MR spectroscopic imaging. *AJR Am J Roentgenol*. 2004;183:1079–83.
20. Ikonen S, Kivisaari L, Vehmas T, Tervahartiala P, Salo JO, Taari K, et al. Optimal timing of post-biopsy MR imaging of the prostate. *Acta Radiol*. 2001;42:70–3.
21. Park KK, Lee SH, Lim BJ, Kim JH, Chung BH. The effects of the period between biopsy and diffusion-weighted magnetic resonance imaging on cancer staging in localized prostate cancer. *BJU Int*. 2010;106:1148–51.
22. Margel D, Yap SA, Lawrentschuk N, Klotz L, Haider M, Hersey K, et al. Impact of multiparametric endorectal coil prostate magnetic resonance imaging on disease reclassification among active surveillance candidates: a prospective cohort study. *J Urol*. 2012;187:1247–52.
23. Lee DH, Koo KC, Lee SH, Rha KH, Choi YD, Hong SJ, et al. Tumor lesion diameter on diffusion weighted magnetic resonance imaging could help predict insignificant prostate cancer in patients eligible for active surveillance: preliminary analysis. *J Urol*. 2013;190:1213–7.
24. Ploussard G, Xylinas E, Durand X, Ouzaid I, Allory Y, Bouanane M, et al. Magnetic resonance imaging does not improve the prediction of misclassification of prostate cancer patients eligible for active surveillance when the most stringent selection criteria are based on the saturation biopsy scheme. *BJU Int*. 2011;108:513–7.
25. D'Amico AV, Whittington R, Malkowicz B, Schnall M, Schultz D, Cote K, et al. Endorectal magnetic resonance imaging as a predictor of biochemical outcome after radical prostatectomy in men with clinically localized prostate cancer. *J Urol*. 2000;164:759–63.
26. Mullerad M, Hricak H, Kuroiwa K, Pucar D, Chen HN, Kattan MW, et al. Comparison of endorectal magnetic resonance imaging, guided prostate biopsy and digital rectal examination in the preoperative anatomical localization of prostate cancer. *J Urol*. 2005;174:2158–63.
27. Akin O, Sala E, Moskowitz CS, Kuroiwa K, Ishill NM, Pucar D, et al. Transition zone prostate cancers: features, detection, localization, and staging at endorectal MR imaging. *Radiology*. 2006;239:784–92.
28. Wang L, Hricak H, Kattan MW, Chen HN, Scardino PT, Kuroiwa K. Prediction of organ-confined prostate cancer: incremental value of MR imaging and MR spectroscopic imaging to staging nomograms. *Radiology*. 2006;238:597–603.
29. Rais-Bahrami S, Siddiqui MM, Turkbey B, Stamatakis L, Logan J, Hoang AN, et al. Utility of multiparametric magnetic resonance imaging suspicion levels for detecting prostate cancer. *J Urol*. 2013;190:1721–7.
30. Wolf Jr JS, Cher M, Dall'era M, Presti Jr JC, Hricak H, Carroll PR. The use and accuracy of cross-sectional imaging and fine needle aspiration cytology for detection of pelvic lymph node metastases before radical prostatectomy. *J Urol*. 1995;153:993–9.