

# Long-Term Results of Gamma Knife Radiosurgery for Intracranial Meningioma

Chang Ki Jang, Hyun Ho Jung, Jong Hee Chang, Jin Woo Chang, Yong Gou Park, Won Seok Chang

Department of Neurosurgery, Yonsei Gamma Knife Center, Yonsei University College of Medicine, Seoul, Korea

**Background** The predominant treatment modality for meningioma is surgical resection. However, gamma knife radiosurgery is also an important treatment modality for meningioma that is small or cannot be completely removed because of its location. In this study, we evaluated the effectiveness and long-term results of radiosurgical treatment for meningioma in our institution.

**Methods** We studied 628 patients (130 men and 498 women) who underwent gamma knife radiosurgery for intracranial meningioma, which is radiologically diagnosed, from Jan 2008 to Nov 2012. We included patients with single lesion meningioma, and followed up after 6 months with imaging, and then at 24 months with a clinical examination. Patients with high-grade meningioma or multiple meningiomas were excluded. We analyzed each of the factors associated with progression free survival. The median patient's age was 56.8 years. Maximal dosage was 27.8 Gy and marginal dosage was 13.9 Gy.

**Results** The overall tumor control rate was 95%. Twenty-eight patients (4.4%) showed evidence of tumor recurrence. Ninety-eight patients (15%) developed peritumoral edema (PTE) after gamma-knife surgery; two of them (2%) underwent surgical resections due to PTE. Nine patients had craniotomy and tumor removal after gamma knife surgery.

**Conclusion** Gamma knife surgery for intracranial meningioma has proven to be a safe and effective treatment tool with successful long-term outcomes. Gamma knife radiosurgery can be especially effective in cases of remnant meningioma after surgical resection or where PTE is not present.

**Key Words** Meningioma; Radiosurgery; Stereotactic.

**Received** July 20, 2015  
**Revised** September 3, 2015  
**Accepted** October 8, 2015

## Correspondence

Won Seok Chang  
Department of Neurosurgery, Yonsei  
Gamma Knife Center, Yonsei University  
College of Medicine, 50-1 Yonsei-ro,  
Seodaemun-gu, Seoul 03722, Korea  
**Tel:** +82-2-2228-2176  
**Fax:** +82-2-393-9979  
**E-mail:** changws0716@yuhs.ac

## INTRODUCTION

Intracranial meningioma makes up 15–20% of primary brain tumors and is the most common primary adult brain tumor [1]. The predominant treatment of intracranial meningioma is surgical resection [2,3].

However, tumor recurrence or progression can be a significant problem after surgery because of the involvement of adjacent cranial nerves or major intracranial arteries. Treatment of small-size tumors with surgical removal can have complications and may be contentious. In such cases, gamma knife surgery is a feasible alternative treatment modality [4,5]. Thus,

it has become an important management tool for patients with intracranial meningioma.

At 5 years after gamma knife surgery, tumor control rates of 90–100% are reported for intracranial meningioma [6-9]. However, reports on long-term outcomes for meningioma are limited because of its pathologic characteristics; it is most often benign and so patients do not follow-up at out-patient departments.

We reviewed clinical outcomes in 628 consecutive patients with meningioma.

## MATERIALS AND METHODS

### Patients

We studied 628 patients who underwent gamma knife radiosurgery for intracranial incidental meningioma from Jan 2008 to Nov 2012 at the Yonsei University College of Medicine.

This is an Open Access article distributed under the terms of the Creative Commons Attribution Non-Commercial License (<http://creativecommons.org/licenses/by-nc/3.0>) which permits unrestricted non-commercial use, distribution, and reproduction in any medium, provided the original work is properly cited.

Copyright © 2015 The Korean Brain Tumor Society, The Korean Society for Neuro-Oncology, and The Korean Society for Pediatric Neuro-Oncology

We included patients with single lesion meningioma and followed up after 6 months with imaging, and then at 24 months with a clinical examination. The median patient age at the time of gamma knife treatment was 56.8 years (28–83 years). Of the 628 patients, 130 (20%) were male, and 498 (80%) were female. In cases in which surgery was not performed and histological diagnosis was not obtained, the diagnosis was confirmed by computed tomography (CT) or magnetic resonance imaging (MRI). Clinical follow-up was conducted between 1 to 79 months after gamma knife surgery (median 37 months). Prior resections were performed in 131 patients (20.8%). Institutional Review Board (IRB) approval was obtained from the severance hospital Yonsei University health system (IRB approval number 4-2015-0604).

**Gamma knife technique**

Tumor locations are listed in Table 1. T1-weighted images with gadobutrol (Gd, Gadovist; Bayer Schering Pharma AG, Leverkusen, Germany) enhancement and T2-weighted images (repetition time 25, field of view 250 mm, matrix: 256×256 mm). Gamma knife surgery was performed using Leksell Gamma Knife type C or Perfexion (Elekta Instrument AB, Stockholm, Sweden).

Patients underwent gamma knife surgery after application of local anesthesia for stereotactic head frame. After frame application, MRI was conducted in the axial plane. Conformal and selective dose plans were created, always using multiple isocenters. Dose selection was based on individual factors that included age, prior exposure to radiation therapy, tumor volume, tumor location, and neurological status by using the GammaPlan treatment planning software. The median marginal and maximal dose delivered to the tumor was 13.9 Gy (range, 9 to 19 Gy) and 27.8 Gy (range, 20 to 36 Gy), respectively.

Serial imaging follow-ups were performed using MRI to examine changes in tumor volume, peritumoral edema (PTE), and hydrocephalus; CT was performed when the MRI results

**Table 1.** Demographics for the 628 patients who underwent gamma knife surgery

Factor	Total: 628
Gender	
Male	130
Female	498
Age	Mean (yr) 56.8±11.3
Location	
Supratentorial	179
Middle cranial fossa	143
Cerebellopontine angle	100
Parasagittal	97
Falx	72
Infratentorial convexity	31
Intraventricular	6

were in contraindication.

Data was analyzed using the chi-square, Fisher exact, and Kruskal-Wallis tests. Multivariate analysis was carried out using the Cox proportional hazards regression analysis.

The Statistical Package for the Social Sciences version 20.0.0 (IBM, Armonk, NY, USA) was used for all statistical analyses.

Long-term tumor control and radiation-related complication rates were determined using the Kaplan-Meier method. Univariate testing was performed using log rank test.

**RESULTS**

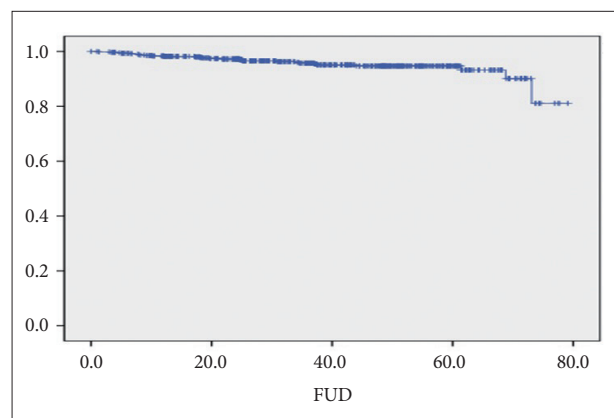
Clinical follow-up data was available in 628 patients (130 men and 498 women). Histopathological diagnoses was not confirmed in 300 cases and Grade I meningioma was detected in 128 cases. The overall tumor control rate was 95%. Twenty-eight patients (4%) showed evidence of tumor recurrence. Ninety-eight patients (15%) developed PTE after gamma-knife surgery. Of these, 76 patients were treated with medicines, and 31 of them fully recovered after this treatment. Two patients (2%) had surgical resection for PTE.

Overall, the median progression free survival (PFS) time was 75 months, and the overall 5-year PFS (5YR PFS) was 94.7% (Fig. 1).

The median PFS for patients older and younger than 65 years was 69 and 70.9 months, respectively. The 5YR PFS for patients older and younger than 65 years was 69.0% and 70.9%, respectively (*p*-value=0.986) (Table 2).

In men, the median PFS was 69.1 months, while it was 76.1 months for women (*p*-value=0.065). The median PFS for patients with and without PTE was 85.3 and 96.5 months, respectively. The 5YR PFS of patients with and without PTE was 69.0% and 76.0%, respectively (*p*-value=0.000) (Table 2).

Gamma Knife radiosurgery was the primary treatment for 497 patients (79.2%), while 131 patients (20.8%) had previous-



**Fig. 1.** Overall survival. FUD, follow-up duration (months).

ly undergone open surgery. The mean period to gamma knife surgery after open surgery was 40 months (range, 0 to 227 months). Nine patients underwent craniotomy and tumor removal after gamma knife surgery (Table 2).

The medial PFS was 77.4 months for patients for whom the primary treatment was gamma knife surgery and 62.3 months for those who had previously undergone open surgery. The corresponding values for 5YR PFS were 97.9% and 81.8%. The only factors showing tendency for survival in the multivariate analysis was PTE (Table 3).

## DISCUSSION

Over the last two decades, gamma knife surgery has become an alternative component in multimodal management of primary and surgically removed intracranial meningioma. It has been applied frequently in patients in whom the meningioma is located in challenging location, for solitary, small tumors or for patients showing recurrence after incomplete resections [10]. It has been demonstrated to be effective for controlling tumor growth.

Most previous studies reporting gamma knife surgery for intracranial meningioma had follow-up periods of fewer than 5 years [7,11-13]. Only few studies have provided long-term

**Table 2.** Five-year progression free survival (5YR PFS) and medial progression free survival (mPFS) of patients with asymptomatic intracranial meningioma

	5YR PFS (%)	mPFS (mo)	p-value
Age			0.986
65>	96.5	69.0	
65≤	94.4	70.9	
Gender			0.065
Male		69.1	
Female		76.1	
PTE			<0.001
Yes	85.3	69.0	
No	96.5	76.0	
Surgery			0.017
Previous done	81.8	62.3	
No	97.9	77.4	

PTE, peritumoral edema

**Table 3.** Multivariate analysis

	p-value	95% CI	
Age over 65	0.238	0.711	1.089
Gender	0.086	0.661	1.028
Max dose (Gy)	0.499	0.701	1.189
Marginal dose (Gy)	0.112	0.909	2.500
PTE	0.079	0.619	1.027
Location	0.676	0.785	1.308

CI, confidence interval; PTE, peritumoral edema

follow-up analysis.

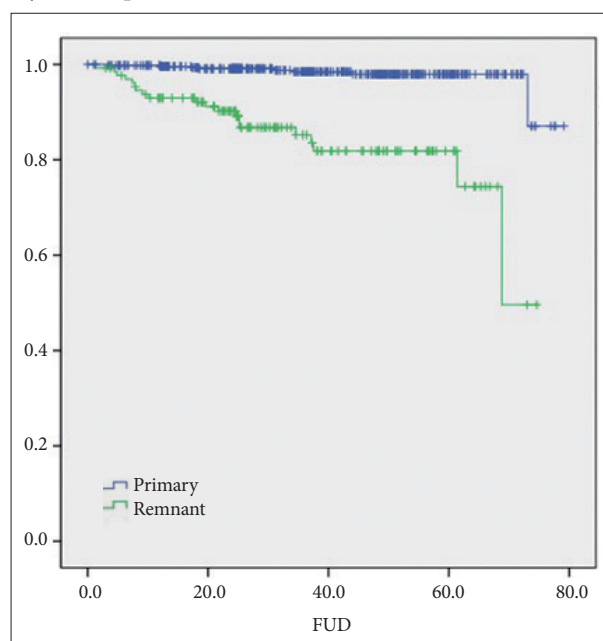
In these few studies, the overall tumor control rates were ~86–100% with minimal complications to vital structures [14,15].

Kondziolka et al. [16] reported patient outcomes at up to 10 years after radiosurgery and found a tumor control rate of 95%. In a study in which adjacent or new tumor growth away from the primary target was considered as treatment failure, the tumor control rate dropped to 89% at 10 years [17]. In the Mayo clinic study of larger (>10 mL) benign meningiomas, Bledsoe et al. [18] reported a tumor control rate of 99% at 7 years and a neurological complication rate of 44% in supratentorial tumors and 18% in skull-base tumors. Further, Han et al. [19] reported outcomes after gamma knife surgery for 63 skull-based meningiomas treated with a mean marginal isodose of 12.7 Gy. The overall tumor control rate was 90%, with follow-up period ranging from 12 to 60 months.

In our study, the overall tumor control rate was 95%. Twenty-eight patients (4%) showed evidence of tumor recurrence.

Couldwell et al. [20] analyzed patterns for failure after gamma knife surgery for benign meningiomas and reported a higher likelihood of failure in cavernous sinus meningiomas. In a recent study, tumor progression after gamma knife surgery was high in patients treated with incomplete coverage, with cavernous sinus or with meningiomatosis, despite benign tumor histology.

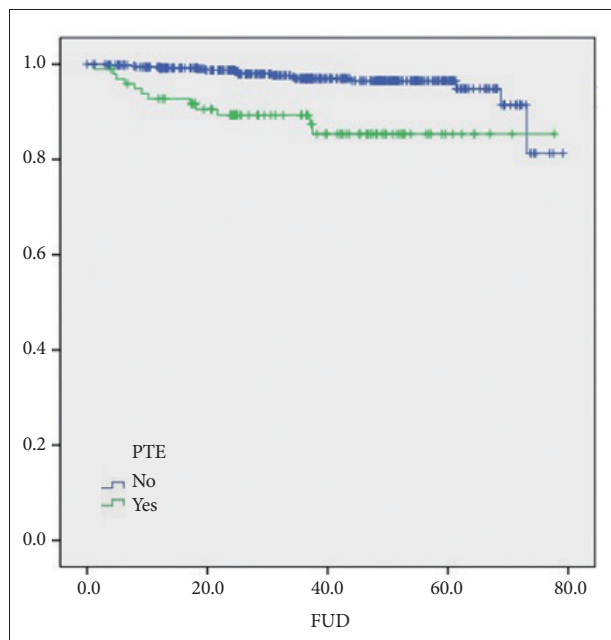
Relatively fewer recurrences have been reported for patients with meningiomas who received higher marginal doses (>14 Gy) in comparison with those who received lower doses (10–



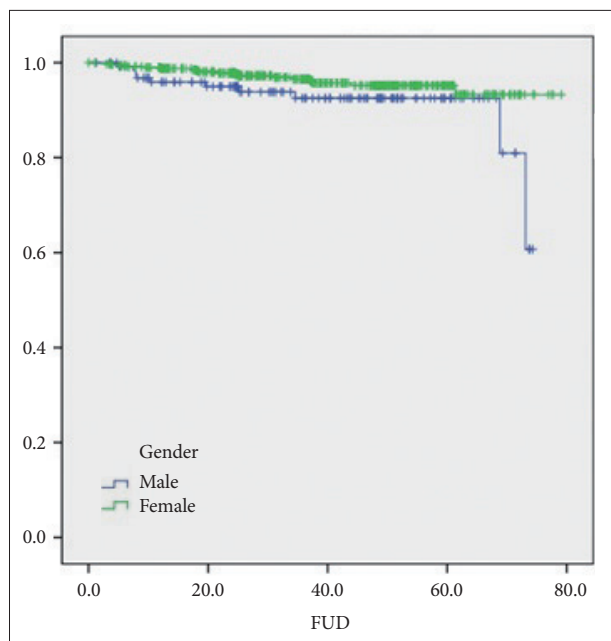
**Fig. 2.** Influence of primary surgery or post-surgery remnant lesion radiation on progression free survival. FUD, follow-up duration (months).

12 Gy) [14].

Various factors may influence the long-term outcomes and likelihood of complications. Kondziolka et al. [16] reported prior radiation therapy ( $p < 0.0001$ ) and high-grade tumors ( $p < 0.0001$ ) as factors associated with a worse PFS. Age, sex, tumor volume, and margin dose were not associated with PFS. DiBiase et al. [11] reported that male patients and patients with tumor size greater than 10 cc were more likely to have a worse prognosis. The reason for female patients having a



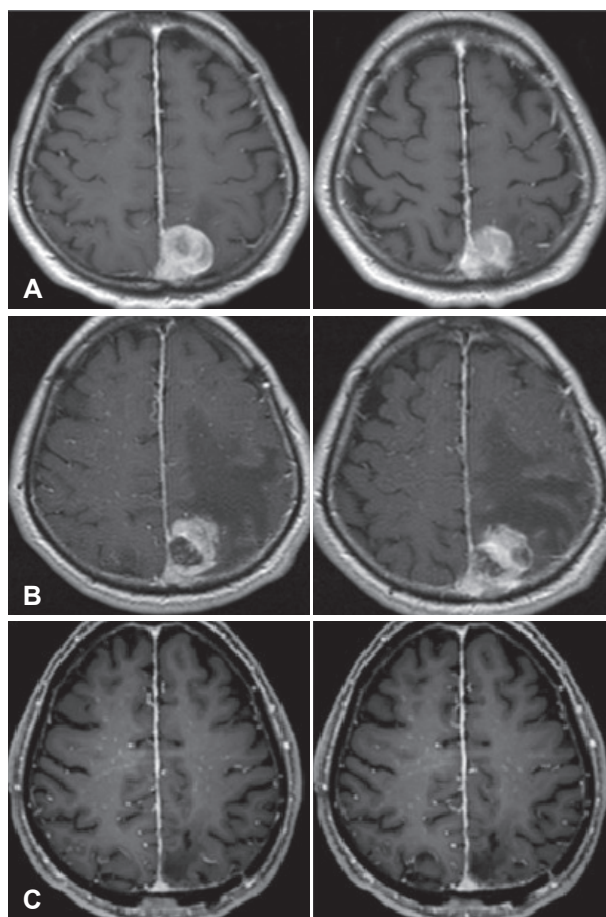
**Fig. 3.** Influence of peritumoral edema on progression free survival. FUD, follow-up duration (months).



**Fig. 4.** Influence of gender on progression free survival. FUD, follow-up duration (months).

higher tumor control rate is unknown, but one hypothesis is related to the presence of hormone receptors in meningiomas. Sexual hormone assays of meningiomas exhibit the presence of estrogen, progesterone, and androgen receptors [21]. Further, patients treated with less conformal plans to cover the dural tail have been reported to have better outcomes. Previous studies demonstrate the need to adequately cover the dural tail in patients treated with gamma knife surgery for benign intracranial meningiomas. Additionally, previous surgery to treat a lesion larger than 10 cc was found to be a significant factor affecting the likelihood of tumor control [11]. Radiation-related complications were associated with tumor location (convexity/falx) and large tumor volume [22].

In our study, previous surgery (Fig. 2) and presence of PTE (Fig. 3) were identified as factors influencing PFS. So we recommend that primary surgery was needed before perform-



**Fig. 5.** Magnetic resonance images of a representative case. A 62-year-old man received gamma knife surgery for parasagittal meningioma with invasion of superior sagittal sinus. A: Axial T1-weighted magnetic resonance (MR) image obtained in Dec 2006 showing homogeneous enhancing round mass with invasion of superior sagittal sinus. B: Axial T1-weighted MR image from Aug 2009 (post gamma knife surgery 32 months) showing increased heterogeneous enhancing round mass with aggravated peritumoral edema. C: Axial T1-weighted MR image from Sep 2009 (post-operation) showing no remnant lesion.



ing gamma knife surgery if there is PTE. Male patients tended to have poorer PFS than female patients (Fig. 4), although this finding did not reach statistical significance. Further, older patients ( $\geq 65$ ) showed similar long-term tumor control rates compared to younger patients ( $< 65$ ). This provides evidence that gamma knife surgery for meningioma is plausible even for elderly patients. The only factor that showed tendency on multivariate analysis was PTE. In this report, patients without PTE had a significantly higher 5YR PFS than those with PTE (96.5% vs. 85.3%,  $p$ -value $<0.001$ ), and this remained tendency on multivariate analysis (Table 3).

Our study does have some limitations. It was retrospective and involved cases that were not confirmed by histopathology. Specifically, for 500 cases, histological confirmation was not obtained. Of the 128 cases that were histopathologically confirmed, 100 were of World Health Organization (WHO) grade I, 25 were of WHO grade II, and 3 were of WHO grade III.

A small percentage of meningiomas appear to have malignant potential [23,24]. According to the literature on meningioma, diverse behaviors of the tumors are described. One of our patients, a 62-year-old man, received gamma knife surgery for a parasagittal meningioma with invasion of the superior sagittal sinus (Fig. 5A). After 32 months, follow-up with MRI revealed increasing tumor size with PTE (Fig. 5B). We performed total resection of that lesion, which had atypical pathology for meningioma (WHO grade III) (Fig. 5C).

According to our results, gamma knife surgery for intracranial meningioma is safe and effective with successful long-term outcomes. It can be a highly effective treatment modality particularly in cases of remnant meningioma after surgical resection as well as in cases without PTE.

#### Conflicts of Interest

The authors have no financial conflicts of interest.

#### Acknowledgments

This work was supported by The Yonsei University Future-leading Research Initiative (Yonsei Challenge) of 2014 (2014-22-0150) and Basic Science Research Program through the National Research Foundation of Korea (NRF) funded by the Ministry of Science, ICT and Future Planning (2015R1C1A1A02036851).

#### REFERENCES

- Claus EB, Bondy ML, Schildkraut JM, Wiemels JL, Wrensch M, Black PM. Epidemiology of intracranial meningioma. *Neurosurgery* 2005; 57:1088-95; discussion 1088-95.
- Sanna M, Bacciu A, Falcioni M, Taibah A, Piazza P. Surgical management of jugular foramen meningiomas: a series of 13 cases and review of the literature. *Laryngoscope* 2007;117:1710-9.
- Voss NF, Vronionis FD, Heilman CB, Robertson JH. Meningiomas of the cerebellopontine angle. *Surg Neurol* 2000;53:439-46; discussion 446-7.
- Lee JY, Niranjan A, McInerney J, Kondziolka D, Flickinger JC, Lunsford LD. Stereotactic radiosurgery providing long-term tumor control of cavernous sinus meningiomas. *J Neurosurg* 2002;97:65-72.
- Pollock BE, Stafford SL. Results of stereotactic radiosurgery for patients with imaging defined cavernous sinus meningiomas. *Int J Radiat Oncol Biol Phys* 2005;62:1427-31.
- Kreil W, Luggin J, Fuchs I, Weigl V, Eustacchio S, Papaefthymiou G. Long term experience of gamma knife radiosurgery for benign skull base meningiomas. *J Neurol Neurosurg Psychiatry* 2005;76:1425-30.
- Nicolato A, Foroni R, Alessandrini F, Bricolo A, Gerosa M. Radiosurgical treatment of cavernous sinus meningiomas: experience with 122 treated patients. *Neurosurgery* 2002;51:1153-9; discussion 1159-61.
- Starke RM, Nguyen JH, Rainey J, et al. Gamma Knife surgery of meningiomas located in the posterior fossa: factors predictive of outcome and remission. *J Neurosurg* 2011;114:1399-409.
- Subach BR, Lunsford LD, Kondziolka D, Maitz AH, Flickinger JC. Management of petroclival meningiomas by stereotactic radiosurgery. *Neurosurgery* 1998;42:437-43; discussion 443-5.
- Iwai Y, Yamanaka K, Ikeda H. Gamma Knife radiosurgery for skull base meningioma: long-term results of low-dose treatment. *J Neurosurg* 2008;109:804-10.
- DiBiase SJ, Kwok Y, Yovino S, et al. Factors predicting local tumor control after gamma knife stereotactic radiosurgery for benign intracranial meningiomas. *Int J Radiat Oncol Biol Phys* 2004;60:1515-9.
- Pendl G, Schröttner O, Eustacchio S, Ganz JC, Feichtinger K. Cavernous sinus meningiomas--what is the strategy: upfront or adjuvant gamma knife surgery? *Stereotact Funct Neurosurg* 1998;70 Suppl 1:33-40.
- Nicolato A, Foroni R, Pellegrino M, et al. Gamma knife radiosurgery in meningiomas of the posterior fossa. Experience with 62 treated lesions. *Minim Invasive Neurosurg* 2001;44:211-7.
- Shin M, Kurita H, Sasaki T, et al. Analysis of treatment outcome after stereotactic radiosurgery for cavernous sinus meningiomas. *J Neurosurg* 2001;95:435-9.
- Roche PH, Pellet W, Fuentes S, Thomassin JM, Régis J. Gamma knife radiosurgical management of petroclival meningiomas results and indications. *Acta Neurochir (Wien)* 2003;145:883-8; discussion 888.
- Kondziolka D, Patel AD, Kano H, Flickinger JC, Lunsford LD. Long-term Outcomes After Gamma Knife Radiosurgery for Meningiomas. *Am J Clin Oncol* 2014 Apr 21. [Epub]
- Flickinger JC, Kondziolka D, Maitz AH, Lunsford LD. Gamma knife radiosurgery of imaging-diagnosed intracranial meningioma. *Int J Radiat Oncol Biol Phys* 2003;56:801-6.
- Bledsoe JM, Link MJ, Stafford SL, Park PJ, Pollock BE. Radiosurgery for large-volume ( $> 10$  cm<sup>3</sup>) benign meningiomas. *J Neurosurg* 2010;112:951-6.
- Han JH, Kim DG, Chung HT, et al. Gamma knife radiosurgery for skull base meningiomas: long-term radiologic and clinical outcome. *Int J Radiat Oncol Biol Phys* 2008;72:1324-32.
- Couldwell WT, Cole CD, Al-Mefty O. Patterns of skull base meningioma progression after failed radiosurgery. *J Neurosurg* 2007;106:30-5.
- Goodwin JW, Crowley J, Eyre HJ, Stafford B, Jaecle KA, Townsend JJ. A phase II evaluation of tamoxifen in unresectable or refractory meningiomas: a Southwest Oncology Group study. *J Neurooncol* 1993; 15:75-7.
- Pollock BE, Stafford SL, Link MJ, Garces YI, Foote RL. Single-fraction radiosurgery for presumed intracranial meningiomas: efficacy and complications from a 22-year experience. *Int J Radiat Oncol Biol Phys* 2012;83:1414-8.
- Jääskeläinen J, Haltia M, Servo A. Atypical and anaplastic meningiomas: radiology, surgery, radiotherapy, and outcome. *Surg Neurol* 1986; 25:233-42.
- Modha A, Gutin PH. Diagnosis and treatment of atypical and anaplastic meningiomas: a review. *Neurosurgery* 2005;57:538-50; discussion 538-50.