



## Voxel-based lesion symptom mapping analysis of depressive mood in patients with isolated cerebellar stroke: A pilot study☆☆☆



Na Young Kim, MD<sup>a</sup>, Sang Chul Lee, MD, PhD<sup>a</sup>, Ji-Cheol Shin, MD, PhD<sup>a</sup>,  
Ji Eun Park, MD<sup>b</sup>, Yong Wook Kim, MD, PhD<sup>a,\*</sup>

<sup>a</sup> Department and Research Institute of Rehabilitation Medicine, Yonsei University College of Medicine, Seoul, Republic of Korea

<sup>b</sup> Department of Radiology, Research Institute of Radiology, University of Ulsan College of Medicine, Asan Medical Center, Seoul, Republic of Korea

### ARTICLE INFO

#### Article history:

Received 11 July 2016

Received in revised form 7 November 2016

Accepted 11 November 2016

Available online 12 November 2016

#### Keyword:

Cerebellum

Stroke

Depression

Brain mapping

### ABSTRACT

Post-stroke depression (PSD) is the most common neuropsychological sequela of stroke and occurs in approximately one-third of all stroke survivors. However, there are no well-established predictors of PSD. Depression in stroke patients is correlated with unfavorable outcomes. Meta-analyses of the relationship between PSD and lesion location have yielded contradictory results and have not adequately addressed the impact of cerebellar lesions. Furthermore, other brain regions associated with depression in patients with cerebellar stroke remain a matter of debate. For these reasons, this cross-sectional study investigated the relationship between PSD and lesion location in patients with isolated cerebellar stroke.

Twenty-four patients in the subacute rehabilitative period following a first-ever isolated cerebellar stroke were enrolled in the study. Depressive mood was evaluated using the Geriatric Depression Scale. Regions of interest were drawn manually on T1-weighted magnetic resonance images using MRicron software, and data were normalized to a standard brain template in order to examine the neural correlates of depression using voxel-based lesion-symptom mapping analysis.

Voxel-wise subtraction and  $\chi$  (Ayerbe et al., 2014) analyses indicated that damage to the left posterior cerebellar hemisphere was associated with depression. Significant correlations were also found between the severity of depressive symptoms and lesions in lobules VI, VIIb, VIII, Crus I, and Crus II of the left cerebellar hemisphere ( $P_{\text{corrected}} = 0.045$ ). Our results suggest that damage to the left posterior cerebellum is associated with increased depressive mood severity in patients with isolated cerebellar stroke.

© 2016 The Authors. Published by Elsevier Inc. This is an open access article under the CC BY-NC-ND license (<http://creativecommons.org/licenses/by-nc-nd/4.0/>).

### 1. Introduction

Post-stroke depression (PSD) has been reported to affect >30% of patients with stroke survivors (Hackett and Pickles, 2014). PSD can occur during the early or late phase after stroke and shows a high recurrence rate but a relatively short duration (Ayerbe et al., 2014). The influence of PSD on recovery from stroke is clinically significant, as it leads to increased functional dependence (Herrmann et al., 1998), poorer rehabilitation outcomes (Gillen et al., 2001), increased mortality, and lower quality of life (Ayerbe et al., 2013a). Moreover, recovery from PSD

does not reduce the long-term risk of negative outcomes (Ayerbe et al., 2013b).

During the past few decades, a large number of studies have investigated the relationship between PSD development and stroke location. Several studies have suggested that left hemispheric stroke is related to the development of PSD, (Robinson et al., 1983; Robinson et al., 1984; Parikh et al., 1987) whereas MacHale et al. found a statistically significant association between PSD and right hemispheric lesion (MacHale et al., 1998). However, recent meta-analyses have failed to detect robust relationships between PSD and lesion location, (Carson et al., 2000; Hadidi et al., 2009; Wei et al., 2015) and thus this relationship remains inconclusive. Furthermore, most previous studies have focused on lesions to the cerebral hemispheres, and the potential role of the cerebellum in the development of PSD has been underexplored.

Since the definition of cerebellar cognitive affective syndrome by Schmahmann and Sherman (Schmahmann and Sherman, 1998), there has been growing concern regarding the role of the cerebellum in the control of emotional processing. Several studies have reported decreased cerebellar volume associated with mood disorders (Peng et al., 2011; DelBello et al., 1999; Escalona et al., 1993). Blood flow

*Abbreviations:* GDS, Geriatric Depression Scale; MBI, modified Barthel index; MMSE, Mini-Mental State Examination; MNI, Montreal Neurological Institute; MRI, magnetic resonance imaging; PSD, post-stroke depression; ROI, regions of interest; SD, standard deviation; VLSM, voxel-based lesion-symptom mapping.

☆ Conflicts of interest: The authors have no conflicts of interest to declare

☆☆ Source of funding: This research did not receive any specific grant from funding agencies in the public, commercial, or not-for-profit sectors.

\* Corresponding author at: Department of Rehabilitation Medicine, Yonsei University College of Medicine, 50-1 Yonsei-ro Seodaemun-gu, Seoul, 120-752, Republic of Korea.

E-mail address: [ywkim1@yuhs.ac](mailto:ywkim1@yuhs.ac) (Y.W. Kim).

abnormalities (Videbech et al., 2002; Dolan et al., 1992) and disrupted regional homogeneity in the cerebellum have been observed in subjects with major depressive disorder (Liu et al., 2010; Guo et al., 2011). Cerebellar stroke has also been associated with post-stroke emotional incontinence (Kim and Choi-Kwon, 2000). However, few studies have been conducted on the relationship between PSD and stroke-induced cerebellar lesions. Thus, the aim of the current study was to investigate the association between PSD and lesion location in patients with isolated cerebellar stroke using brain voxel-based lesion-symptom mapping (VLSM) analysis.

## 2. Methods

### 2.1. Subjects

From February 2005 to December 2014, we consecutively included 154 adult patients with cerebellar stroke from a tertiary inpatient rehabilitation hospital. Stroke diagnoses were made by clinicians who treated the patients at the time of admission, based on neurological examination and history of present illness. Diagnoses were confirmed by computed tomography or magnetic resonance imaging (MRI) findings during the acute period.

On MRI, we differentiated focal lesions in the supratentorial region, in respect to their signal intensities on T1-, T2- weighted and fluid attenuated inversion-recovery images, as well as their size, shape, symmetry and location (Longstreth et al., 1998). Hyperintense punctate lesions only on T2 images or lesions smaller than 3 mm were not regarded as evidences of cerebrovascular accidents, to exclude small unidentified bright objects (Kertesz et al., 1988) and enlarged perivascular spaces (Heier et al., 1989). Patients with evidence of old ischemic or hemorrhagic supratentorial lesions on imaging, but no previous diagnosis of stroke, were excluded from the study.

The inclusion criteria were as follows: 1) first-ever stroke restricted to the cerebellum, 2) age 18 years or older, 3) elapsed time of 3 months or less after stroke onset, 4) no history of neurological or psychiatric disorders, 5) no disorders of consciousness (vegetative or minimally conscious state, as defined by the JFK Coma Recovery Scale (Giacino et al., 2004)) and 6) no severe cognitive deficit (Mini-Mental Status Examination (MMSE) scores  $\geq 15$  points). Fifteen patients refused to proceed with the study. Twenty-four patients were enrolled in the study (Fig. 1).

The patients included 15 men and 9 women with a mean age of 55.04 years (standard deviation [SD], 17.79 years; range, 19–81 years). The mean elapsed time since stroke onset was 1.42 months (SD, 0.78 months; range, 0–3 months). All subjects or their family members gave informed consent, and all procedures were performed with the approval of Institutional Review Board for Clinical Studies of Yonsei University College of Medicine, Seoul, Korea.

### 2.2. Evaluation of cognitive function, depression, and functional status

Cognitive function was assessed using the MMSE, since Salter et al. reported increased sensitivity and specificity of the Geriatric Depression Scale (GDS) in patients with MMSE scores of 15 and higher (Salter et al., 2007). Patients with MMSE scores  $< 15$  were excluded from further assessment.

Patients were interviewed for depressive symptoms. A patient was considered depressed if he or she fulfilled the criteria of mood disorder due to stroke with major depression-like episode or minor depression (research criteria), as defined by the Diagnostic and Statistical Manual of Mental Disorders, fourth edition, text revision (DSM-IV-TR) (Unutzer et al., 2002), and had a GDS score  $> 16$  points (Kim et al., 2008). We used GDS to quantify the severity of depressive symptoms. GDS is comprised of 30 questions with yes/no responses, and is a highly reliable and valid test for depression screening (Stiles and McGarrah, 1998). Both MMSE and GDS were administered by a psychologist, who was unaware of the lesion location and detailed neurologic findings.

Performance on activities of daily living was measured with the modified Barthel index (MBI) (Shah et al., 1989). MBI scores range from 0 to 100; a lower score is associated with greater physical dependence.

### 2.3. Brain MR imaging acquisition

MRI was performed using a Philips 3T scanner (Intra Achieva, Philips Healthcare, Amsterdam, Netherlands). Brain MRI scans included high-resolution, 3-dimensional T1-weighted (axial plane, matrix =  $224 \times 256$ , field of view = 220 mm, voxel size =  $0.875 \times 0.875 \times 1.0$  mm<sup>3</sup>, echo time = 4.6 ms, repetition time = 9.9 ms, flip angle = 8, 160 slices), T2-weighted (axial plane, matrix =  $448 \times 358$ , field of view = 230 mm, voxel size =  $0.449 \times 0.449 \times 3.0$  mm<sup>3</sup>, echo time = 80 ms, repetition time = 4553 ms, 48 slices), and fluid attenuation inversion recovery scans (axial plane, matrix =  $352 \times 249$ , field of view = 230 mm, voxel size =  $0.449 \times 0.449 \times 7.0$  mm<sup>3</sup>, echo time = 125 ms, repetition time = 11,000 ms, 20 slices).

### 2.4. Statistical analyses of demographic and clinical data

Demographic and clinical data were analyzed using SPSS Statistics software, Version 20.0 (IBM, Armonk, NY, USA). In subgroup analyses, the  $\chi^2$  (Ayerbe et al., 2014) test and Fisher's exact test were used to analyze the effects of categorical variables (sex and stroke etiology). The Mann-Whitney *U* test was used to analyze the effects of continuous variables (age, lesion volume, time since stroke, and MMSE and MBI scores).

To assess possible confounding factors, correlations among age, lesion volume, and MBI and GDS scores were evaluated using Spearman's rank correlation coefficient. *P* values  $< 0.05$  were considered significant.

### 2.5. Lesion mapping and analysis

Lesions were manually drawn by a radiologist, who was blinded to all clinical information, on T1-weighted template MRI slices using MRlcron software (<http://www.mricron.com>; University of South Carolina, Columbia, SC, USA), and saved as regions of interest (ROI). Multiple images were compared to confirm lesion location and extent. The drawn lesions were inspected by a skilled neuroradiologist. Each ROI was registered, resampled to a voxel size of  $2 \times 2 \times 2$  mm<sup>3</sup>, and normalized to a standard brain template using Statistical Parametric Mapping 12 software (<http://www.fil.ion.ucl.ac.uk/spm/>; Wellcome Department of Cognitive Neurology, London, UK).

Two types of analysis were conducted on the normalized lesions of our patients. First, we performed a group comparison study to recognize the lesions associated with PSD. Patients were classified into non-depressive ( $n = 16$ ) and depressive groups ( $n = 8$ ). The overlay map of ROIs for each group was created, and ROI data of the non-depressive group were subtracted from those of the depressive group. To avoid potential problems associated with subtraction analysis, we also performed a direct statistical comparison of lesions between depressive and non-depressive patient groups using voxel-by-voxel  $\chi^2$  (Ayerbe et al., 2014) analyses for each voxel that was damaged in at least 1 patient (Rorden and Karnath, 2004). Statistical significance was defined as  $P < 0.01$ .

Second, a VLSM approach was applied to identify correlations between lesions and the severity of depressive symptoms using the VLSM 2.55 toolbox (<http://neuroling.arizona.edu/resources.html>; University of Arizona, Tucson, AZ, USA) for MATLAB (MathWorks, Natick, MA, USA) (Bates et al., 2003). A *t*-statistic for each voxel was calculated to compare the severity of depression in patients with and without a lesion in that voxel. Cluster size and the permutation method were used to correct multiple comparisons (Wilson et al., 2015). Only voxels that were lesioned in at least 10% of all patients were included in the analysis. Data were permuted 1000 times with a *t*-map threshold of

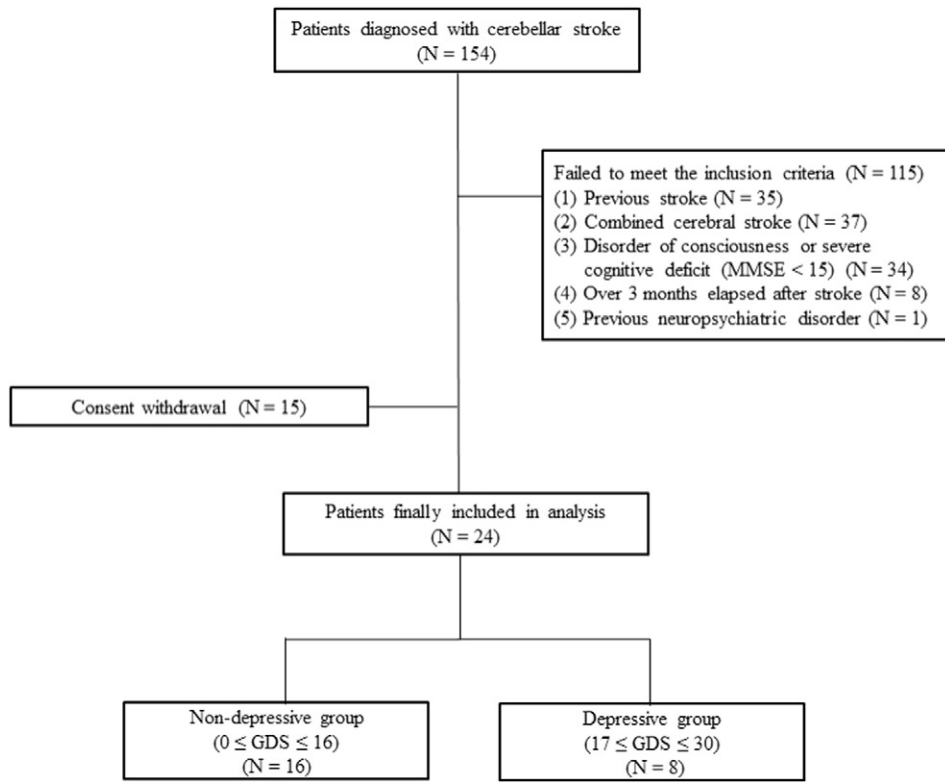


Fig. 1. Flow chart showing patient selection according to inclusion/exclusion criteria.

voxel-wise  $P < 0.01$ . The maximal cluster size was noted, and corrected  $P$  values for each cluster were obtained with reference to the null distribution of the largest cluster sizes from the permuted data sets. Statistical significance was determined as  $P < 0.05$ .

### 3. Results

#### 3.1. Demographic and clinical characteristics

Based on DSM-IV-TR criteria and GDS scores, we classified 8 subjects into the depressive group and 16 subjects into the non-depressive group. There were no statistically significant differences between two groups in age, gender, etiology of stroke, duration since stroke onset, lesion volume, MBI and MMSE scores ( $P > 0.05$  for all; Table 1). To check signal-to-noise ratio, we calculated the ratio of mean and standard

deviation of the white matter signal intensity in T1 MRI of each patient. The median values were 7.28 (interquartile range, 6.80 to 8.09) in all patients, 6.88 (interquartile range, 6.42 to 7.60) in depressive group, and 7.30 (interquartile range, 7.05 to 8.18) in non-depressive group. No significant difference was found between depressive and non-depressive groups ( $P = 0.214$ ).

The severity of functional impairment measured by MBI was statistically correlated with depressive symptom severity (Spearman's  $\rho = -0.412$ ,  $P = 0.045$ ; Fig. 2).

Table 1  
Demographic and clinical characteristics of patients with isolated cerebellar stroke.

	DG	NDG	<i>P</i> value
Age	61 (16.5)	57.5 (40)	0.787
Gender			
Male	5 (62.5)	10 (62.5)	
Female	3 (37.5)	6 (37.5)	1.000
Type of stroke			0.388
Hemorrhage	2 (25.0)	8 (50.0)	
Ischemia	6 (75.0)	8 (50.0)	
Onset duration (days)	52.5 (42.5)	39.0 (41.0)	0.326
Lesion volume (cc)	13.58 (21.27)	36.21 (39.69)	0.238
MMSE	26 (7.5)	25.5 (7.5)	0.787
MBI	33.5 (22.5)	45.5 (51.75)	0.350
GDS	21.5 (3.75)	10 (5.75)	<0.001*

Values are presented as median (interquartile range) or number(%).

MMSE = Mini Mental State Examination (0–30).

GDS = Geriatric Depression Scale (0–30).

MBI = modified Barthel Index.

DG: Depressive group, NDG: Non-depressive group.

\*  $p < 0.001$ .

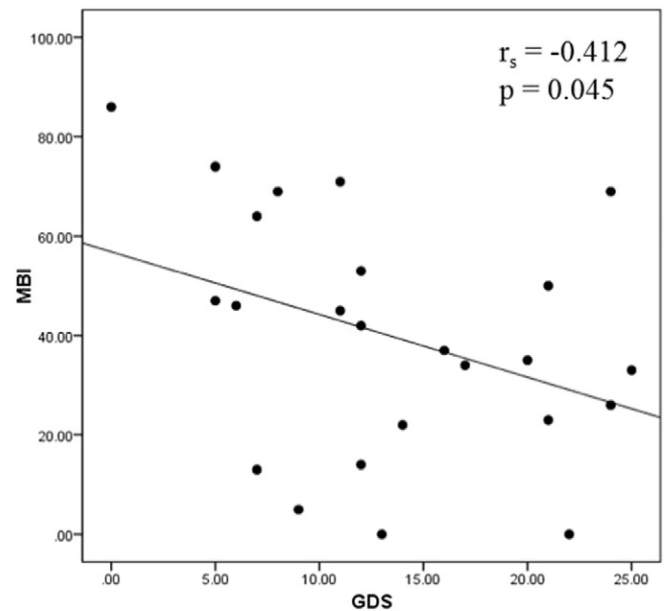
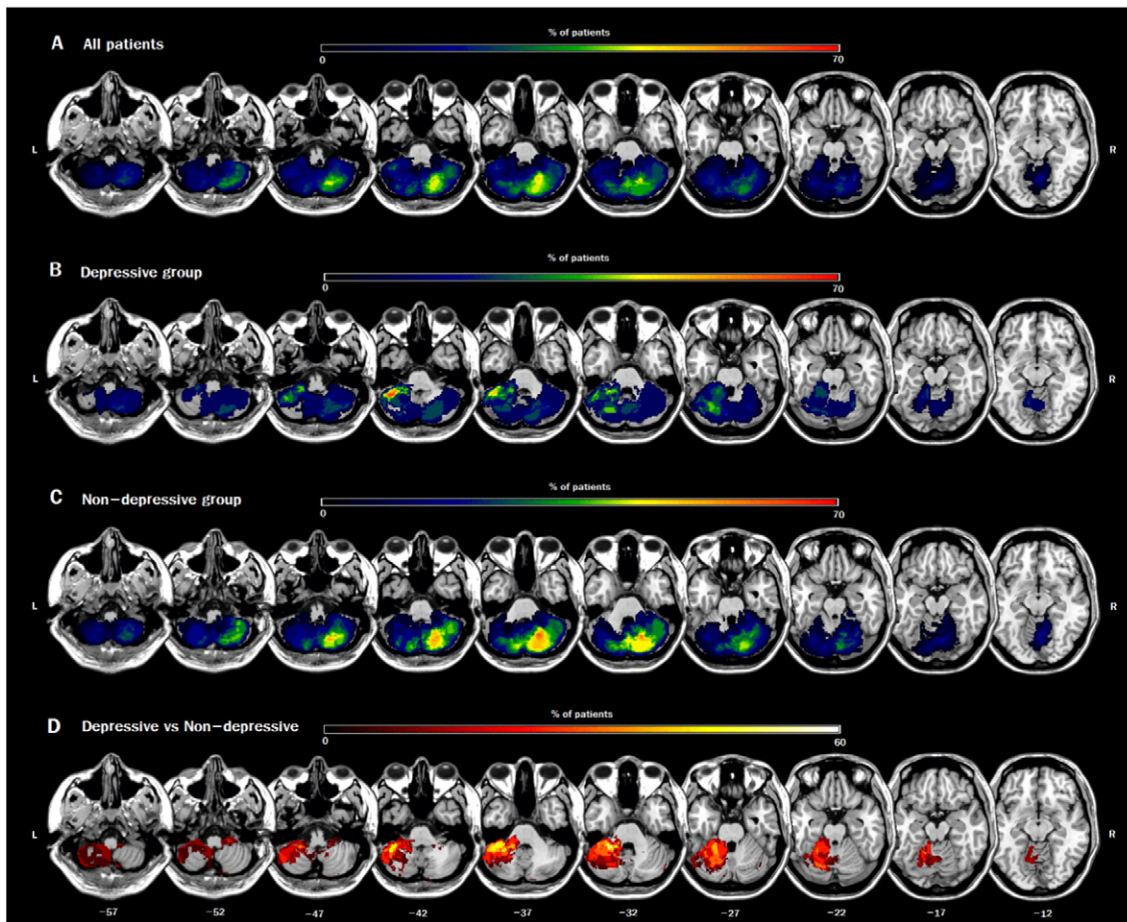


Fig. 2. Correlation between the severity of depression (score of geriatric depression scale) and the score of modified Barthel index.



**Fig. 3.** Overlay lesion plots for (A) all 24 patients included in our study, (B) a subgroup of 8 patients with depressive symptoms, and (C) a subgroup of 16 patients without depressive symptoms. Color bars indicate the degree of lesion overlap; black indicates <5% overlap, red indicates >70% overlap. (D) Subtraction plot showing superimposed lesions of the depressive group minus those of the non-depressive group. Color bar indicates regions with more frequent damage in the depressive group compared to the non-depressive group. Numbers indicate Montreal Neurological Institute (MNI) z-coordinates. L = left; R = right.

However, neither age nor lesion volume was significantly correlated with the severity of depressive symptom.

### 3.2. Subgroup analysis

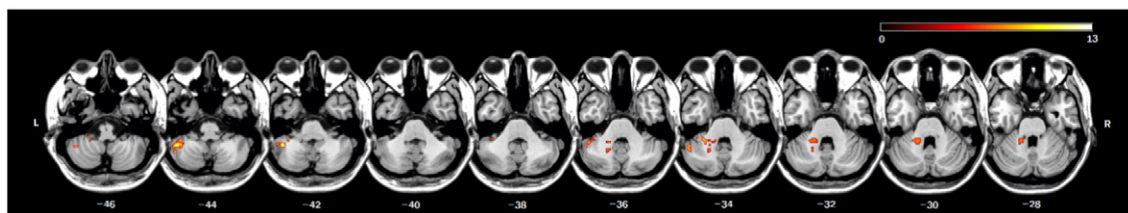
The overall distribution of cerebellar damage among all patients included the whole cerebellum (Fig. 3A). In the depressive group, the maximum lesion overlap ( $n = 5$  out of 8 lesions) was observed in lobules VIIIb, VIII, Crus I, and Crus II of the left cerebellar hemisphere, whereas lesions in lobule VIII of the right hemisphere were observed mainly in non-depressive patients ( $n = 10$  out of 16 lesions, Fig. 3B, C). Subtraction analysis showed that lobules VI, VIIb, VIII, Crus I, and Crus II of the left cerebellar hemisphere were damaged at least 50% more frequently in the depressive group than in the non-depressive group (Fig. 3D).

Fig. 4 shows all voxels with statistically significant differences between groups, as identified by a  $\chi^2$  (Ayerbe et al., 2014) analysis.

The most distinct cluster of significant voxels was located in the inferior posterior lobe of the left cerebellar hemisphere, involving lobules VIIb, VIII, Crus I, and Crus II (Table 2).

### 3.3. VLSM analysis

Because lower scores on the MBI showed a significant correlation with the severity of depressive symptoms, as measured by the GDS, MBI score was included as a covariate to control for possible effects of functional impairment on depressive symptoms. Correlates of depression showed significant involvement of the posterior lobe of the left cerebellar hemisphere, including lobules VI, VIIb, VIII, Crus I, and Crus II (Fig. 5, Table 3;  $P_{corrected} = 0.045$ ).



**Fig. 4.** Anatomical correlates of post-stroke depressive symptoms obtained by a voxel-wise comparison of lesions in patients with or without depressive symptoms. Only voxels significant at  $P < 0.01$  are shown. Color bar indicates  $\chi^2$  (Ayerbe et al., 2014) values. Numbers indicate MNI z-coordinates. L = left; R = right.

**Table 2**  
Significant regions associated with prevalence of PSD.

Peak ROI	Peak $\chi$ (Ayerbe et al., 2014): MNI coordinate			Peak ( $\chi$ (Ayerbe et al., 2014))	Volume (voxels)	Composition
	x	y	z			
L Crus II	−46	−48	−44	12.46	41	46% L Crus II; 39% L VII; 12% L Crus I
L Crus I	−38	−40	−38	9.42	15	53% L Crus I
L IV	−16	−44	−36	9.42	53	15% L IV; 8% L VI

Minimum 5 voxels in acquired space. L, Left.

#### 4. Discussion

To the best of our knowledge, this is the first lesion-symptom mapping analysis study to investigate the depression in patients with isolated cerebellar stroke. As novel finding, our study was able to identify cerebellar lesion associated with the development of depression in isolated cerebellar stroke. The posterior lobe of the left cerebellum was identified as a key region from our subtraction analysis, which was confirmed by non-parametric voxel-by-voxel analysis. In the VLSM analysis, we were able to confirm that the posterior lobe of the left cerebellar hemisphere, particularly in the lobules VIIb, VIII, Crus I, and Crus II, is associated with the severity of PSD in the isolated cerebellar stroke.

In our study, one-third of all included subjects showed depressive mood, consistent with the prevalence of PSD described in a previous study (Hackett and Pickles, 2014). While female gender, severe functional impairment, and large lesion size were reported as risk factors for PSD in previous studies, (Poynter et al., 2009; Schwartz et al., 1993) only the level of functional status was significantly correlated with PSD in our study. Thus, although a causal relationship between PSD and functional disability has yet to be described, these two factors may interact with one another.

The elapsed time between stroke onset and evaluation of depression is an important confounding factor of the relationship between PSD and lesion location, as lesions to depression-related brain regions and other risk factors may vary over time following stroke onset (Bhogal et al., 2004; Provinciali and Coccia, 2002). However, since our study included subjects within 3 months after stroke onset at a single rehabilitation hospital, we were able to control for other external factors that may have affected the development and severity of depressive symptoms.

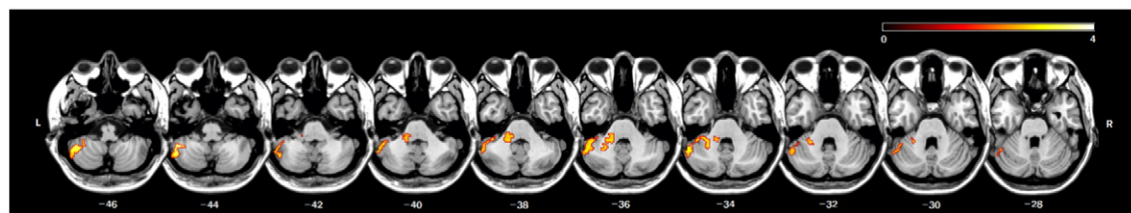
The cerebellum is known to be involved in motor coordination and learning (Thach et al., 1992; Bastian, 2006) as well as perceptual, cognitive, and emotional processings (Schmahmann, 2004; Ito, 2008). The role of the cerebellum in emotional control is neuroanatomically based on connections between the cerebellum and non-motor cortical and subcortical areas, which have been documented by functional neuroimaging studies (Schmahmann, 2000). Papez proposed that the cerebellum shares bidirectional connections with a large portion of the limbic lobe and the associated subcortical nuclei, as well as the amygdaloid complex, septal nuclei, and various hypothalamic and thalamic nuclei, which are all regions of interest in the field of psychiatry by virtue of

their involvement in emotional processing (Papez, 1995). Although several studies on PSD have been conducted, studies regarding the putative role of the cerebellum in PSD have been strikingly scarce and mainly limited to clinical research.

Previous anatomical and functional neuroimaging studies have shown connections between the posterior cerebellar lobes, particularly lobules VI, Crus I and II, and VIIb, and the prefrontal cortex as a part of neural networks for emotional processing (Buckner et al., 2011; Habas et al., 2009). Altered functional connectivity within a prefronto-cerebellar circuit has been found in patients with major depressive disorder, (Ma et al., 2013) demonstrating that disruption of this circuit may lead to disturbances in emotional control. Our results support this hypothesis. Cerebello-cerebral diaschisis, a phenomenon that represents the cortical dysfunction secondary to the primary lesion in cerebellum, (Rousseaux and Steinling, 1992) is thought to be the most likely explanation. Remote deactivation from damage to the fiber tracts of the cerebro-cerebellar loop could occur in hyperacute phase after stroke (Sobesky et al., 2005). Frontal hypoperfusion and its association with neuropsychological dysfunction were revealed in the subacute phase after cerebellar lesion (Baillieux et al., 2010). The further study is needed to investigate the relevance of diaschisis to PSD.

In this study, the damage to left cerebellar hemisphere was significantly correlated with PSD, which may propose the laterality of depression-related cerebellar function. Functional asymmetry of the cerebellum has been suggested in the diverse cognitive and emotional domains (Hu et al., 2008). Spatially distinct patterns of cerebellar activity in response to various emotional stimuli has been observed (Baumann and Mattingley, 2012). It could result from crossed connections within cerebro-cerebellar circuits; for instance, activation of the right cerebellum by language tasks is associated with activation of the left cerebral hemisphere (Wang et al., 2013). Hemispheric specialization in emotional processing has been researched for centuries, numerous studies support that the right cerebral hemisphere is specialized for perception and expression of emotions (Demaree et al., 2005). Our findings could be interpreted in this context.

Accumulating evidence suggests that the cerebellum is not only involved in the relay of information between cortical and subcortical regions, but also plays a role in the modulation of neural processes for cognitive function (Stoodley, 2012). Also, the cerebellum participates in error-monitoring and reward-related processes that are critical for successful emotional adaptation to changing environmental conditions



**Fig. 5.** Voxel-based lesion-symptom maps showing lesioned areas significantly associated with depressive symptom severity after controlling for functional dependency ( $P < 0.05$ , corrected for multiple comparisons). Color bar represents t values. Numbers indicate MNI z-coordinates. L = left; R = right.

**Table 3**  
Significant regions associated with severity of PSD.

Peak ROI	Peak t: MNI coordinate			Peak (t)	Volume (voxels)	Composition
	x	y	z			
L Crus II	-46	-48	-44	3.82	491	37% L Crus I; 17% L Crus II; 11% L VIII; 6% L VI; 4% L VII

L, Left.

(Schutter, 2016). For that reason, the damage to cerebellum may impair the precise modulation of information processing and lead to inappropriate responses to various circumstances. This desynchronization of information could contribute to various symptoms of depression, such as loss of energy, cognitive inefficiency, and social withdrawal (Schutter, 2016).

We also found that damage to lobule VIII of the left cerebellar hemisphere was correlated with PSD in patients with isolated cerebellar stroke. Although lobule VIII is known to compose sensorimotor networks, previous studies have shown that this region also plays a role in emotional processing (Baumann and Mattingley, 2012; Schraa-Tam et al., 2012). In an investigation of neural activity patterns associated with primary emotions, Baumann and Mattingley found that happiness was associated with activation of lobule VIII, an activity pattern that did not overlap with that of any other emotion (Baumann and Mattingley, 2012). A study by Schraa-Tam et al. showed activation of lobule VIII of the left cerebellar hemisphere when subjects viewed negative emotional faces (Schraa-Tam et al., 2012). Further studies of cerebro-cerebellar networks including lobule VIII will be necessary.

Several limitations of this study should be considered. First, a small number of patients were enrolled, and lesions were not evenly distributed. Second, we did not consider microstructural abnormalities, such as white matter hyperintensities in the supratentorial region, although recent studies suggest that these factors may contribute to the development of depression (Wang et al., 2014). Further studies should be performed to obtain more in-depth data on pathologic changes in the supratentorial region. Third, measurement error might occur over time. To obtain constant results, we used the same scanner and acquisition protocol. In addition, we checked the statistical difference in signal-to-noise ratio between the two groups. Nevertheless, we cannot entirely rule out potential effect of the time of scan. Forth, we analyzed only anatomical correlations, which may not fully explain functional disturbances. Future studies should investigate neural correlates of depression in isolated cerebellar stroke patients using functional neuroimaging. Fifth, although we controlled for several factors that could have affected depressive symptoms, based on the findings of previous studies, we cannot exclude the possibility of influences by other confounding factors. Sixth, only one scale was used to evaluate symptom severity of depression. Finally, as a cross-sectional study, this study cannot address prognosis or long-term effect of cerebellar lesion.

## 5. Conclusion

Our results suggest that damage to the posterolateral regions of the left cerebellum, especially lobule Crus II, is related to the occurrence and severity of PSD in patients with isolated cerebellar stroke.

## References

Ayerbe, L., Ayis, S., Wolfe, C.D., Rudd, A.G., 2013a. Natural history, predictors and outcomes of depression after stroke: systematic review and meta-analysis. *Br. J. Psychiatry* 202 (1), 14–21.

Ayerbe, L., Ayis, S., Crichton, S., Wolfe, C.D., Rudd, A.G., 2013b. The natural history of depression up to 15 years after stroke: the South London stroke register. *Stroke* 44 (4), 1105–1110.

Ayerbe, L., Ayis, S., Crichton, S., Wolfe, C.D., Rudd, A.G., 2014. The long-term outcomes of depression up to 10 years after stroke; the South London stroke register. *J. Neurol. Neurosurg. Psychiatry* 85 (5), 514–521.

Baillieux, H., De Smet, H.J., Dobbelaire, A., Paquier, P.F., De Deyn, P.P., Mariën, P., 2010. Cognitive and affective disturbances following focal cerebellar damage in adults: a neuropsychological and SPECT study. *Cortex* 46 (7), 869–879.

Bastian, A.J., 2006. Learning to predict the future: the cerebellum adapts feedforward movement control. *Curr. Opin. Neurobiol.* 16 (6), 645–649.

Bates, E., Wilson, S.M., Saygin, A.P., et al., 2003. Voxel-based lesion-symptom mapping. *Nat. Neurosci.* 6 (5), 448–450.

Baumann, O., Mattingley, J.B., 2012. Functional topography of primary emotion processing in the human cerebellum. *NeuroImage* 61 (4), 805–811.

Bhogal, S.K., Teasell, R., Foley, N., Speechley, M., 2004. Lesion location and poststroke depression: systematic review of the methodological limitations in the literature. *Stroke* 35 (3), 794–802.

Buckner, R.L., Krienen, F.M., Castellanos, A., Diaz, J.C., Yeo, B.T., 2011. The organization of the human cerebellum estimated by intrinsic functional connectivity. *J. Neurophysiol.* 106 (5), 2322–2345.

Carson, A.J., MacHale, S., Allen, K., et al., 2000. Depression after stroke and lesion location: a systematic review. *Lancet* 356 (9224), 122–126.

DelBello, M.P., Strakowski, S.M., Zimmerman, M.E., Hawkins, J.M., Sax, K.W., 1999. MRI analysis of the cerebellum in bipolar disorder: a pilot study. *Neuropsychopharmacology* 21 (1), 63–68.

Demaree, H.A., Everhart, D.E., Youngstrom, E.A., Harrison, D.W., 2005. Brain lateralization of emotional processing: historical roots and a future incorporating “dominance”. *Behav. Cogn. Neurosci. Rev.* 4 (1), 3–20.

Dolan, R.J., Bench, C.J., Brown, R.G., Scott, L.C., Friston, K.J., Frackowiak, R.S., 1992. Regional cerebral blood flow abnormalities in depressed patients with cognitive impairment. *J. Neurol. Neurosurg. Psychiatry* 55 (9), 768–773.

Escalona, P.R., Early, B., McDonald, W.M., et al., 1993. Reduction of cerebellar volume in major depression: a controlled MRI study. *Depression* 1 (3), 156–158.

Giacino, J.T., Kalmar, K., Whyte, J., 2004. The JFK coma recovery scale-revised: measurement characteristics and diagnostic utility. *Arch. Phys. Med. Rehabil.* 85 (12), 2020–2029.

Gillen, R., Tennen, H., McKee, T.E., Gernert-Dott, P., Affleck, G., 2001. Depressive symptoms and history of depression predict rehabilitation efficiency in stroke patients. *Arch. Phys. Med. Rehabil.* 82 (12), 1645–1649.

Guo, W.B., Sun, X.L., Liu, L., et al., 2011. Disrupted regional homogeneity in treatment-resistant depression: a resting-state fMRI study. *Prog. Neuro-Psychopharmacol. Biol. Psychiatry* 35 (5), 1297–1302.

Habas, C., Kamdar, N., Nguyen, D., et al., 2009. Distinct cerebellar contributions to intrinsic connectivity networks. *J. Neurosci.* 29 (26), 8586–8594.

Hackett, M.L., Pickles, K., 2014. Part I: frequency of depression after stroke: an updated systematic review and meta-analysis of observational studies. *Int. J. Stroke* 9 (8), 1017–1025.

Hadidi, N., Treat-Jacobson, D.J., Lindquist, R., 2009. Poststroke depression and functional outcome: a critical review of literature. *Heart Lung* 38 (2), 151–162.

Heier, L.A., Bauer, C.J., Schwartz, L., Zimmerman, R.D., Morgello, S., Deck, M.D., 1989. Large Virchow-Robin spaces: MR-clinical correlation. *AJNR Am. J. Neuroradiol.* 10 (5), 929–936.

Herrmann, N., Black, S.E., Lawrence, J., Szekely, C., Szalai, J.P., 1998. The Sunnybrook stroke study: a prospective study of depressive symptoms and functional outcome. *Stroke* 29 (3), 618–624.

Hu, D., Shen, H., Zhou, Z., 2008. Functional asymmetry in the cerebellum: a brief review. *Cerebellum* 7 (3), 304–313.

Ito, M., 2008. Control of mental activities by internal models in the cerebellum. *Nat. Rev. Neurosci.* 9 (4), 304–313.

Kertesz, A., Black, S.E., Tokar, G., Benke, T., Carr, T., Nicholson, L., 1988. Periventricular and subcortical hyperintensities on magnetic resonance imaging. 'Rims, caps, and unidentified bright objects'. *Arch. Neurol.* 45 (4), 404–408.

Kim, J.S., Choi-Kwon, S., 2000. Poststroke depression and emotional incontinence: correlation with lesion location. *Neurology* 54 (9), 1805–1810.

Kim, J.Y., Park, J.H., Lee, J.J., et al., 2008. Standardization of the Korean version of the geriatric depression scale: reliability, validity, and factor structure. *Psychiatry Investig.* 5 (4), 232–238.

Liu, Z., Xu, C., Xu, Y., et al., 2010. Decreased regional homogeneity in insula and cerebellum: a resting-state fMRI study in patients with major depression and subjects at high risk for major depression. *Psychiatry Res.* 182 (3), 211–215.

Longstreth Jr., W.T., Bernick, C., Manolio, T.A., Bryan, N., Jungreis, C.A., Price, T.R., 1998. Lacunar infarcts defined by magnetic resonance imaging of 3660 elderly people: the cardiovascular health study. *Arch. Neurol.* 55 (9), 1217–1225.

Ma, Q., Zeng, L.L., Shen, H., Liu, L., Hu, D., 2013. Altered cerebellar-cerebral resting-state functional connectivity reliably identifies major depressive disorder. *Brain Res.* 1495, 86–94.

MacHale, S.M., O'Rourke, S.J., Wardlaw, J.M., Dennis, M.S., 1998. Depression and its relation to lesion location after stroke. *J. Neurol. Neurosurg. Psychiatry* 64 (3), 371–374.

Papez, J.W., 1995. A proposed mechanism of emotion. 1937. *J. Neuropsychiatr. Clin. Neurosci.* 7 (1), 103–112.

Parikh, R.M., Lipsey, J.R., Robinson, R.G., Price, T.R., 1987. Two-year longitudinal study of post-stroke mood disorders: dynamic changes in correlates of depression at one and two years. *Stroke* 18 (3), 579–584.

Peng, J., Liu, J., Nie, B., et al., 2011. Cerebral and cerebellar gray matter reduction in first-episode patients with major depressive disorder: a voxel-based morphometry study. *Eur. J. Radiol.* 80 (2), 395–399.

Poynter, B., Shuman, M., Diaz-Granados, N., Kapral, M., Grace, S.L., Stewart, D.E., 2009. Sex differences in the prevalence of post-stroke depression: a systematic review. *Psychosomatics* 50 (6), 563–569.

Provinciali, L., Cocchia, M., 2002. Post-stroke and vascular depression: a critical review. *Neurol. Sci.* 22 (6), 417–428.

- Robinson, R.G., Kubos, K.L., Starr, L.B., Rao, K., Price, T.R., 1983. Mood changes in stroke patients: relationship to lesion location. *Compr. Psychiatry* 24 (6), 555–566.
- Robinson, R.G., Kubos, K.L., Starr, L.B., Rao, K., Price, T.R., 1984. Mood disorders in stroke patients. Importance of location of lesion. *Brain* 107 (Pt 1), 81–93.
- Rorden, C., Karnath, H.O., 2004. Using human brain lesions to infer function: a relic from a past era in the fMRI age? *Nat. Rev. Neurosci.* 5 (10), 813–819.
- Rousseaux, M., Steinling, M., 1992. Crossed hemispheric diaschisis in unilateral cerebellar lesions. *Stroke* 23 (4), 511–514.
- Salter, K., Bhogal, S.K., Foley, N., Jutai, J., Teasell, R., 2007. The assessment of poststroke depression. *Top. Stroke Rehabil.* 14 (3), 1–24.
- Schmahmann, J.D., 2000. The role of the cerebellum in affect and psychosis. *J. Neurolinguistics* 13 (2), 189–214.
- Schmahmann, J.D., 2004. Disorders of the cerebellum: ataxia, dysmetria of thought, and the cerebellar cognitive affective syndrome. *J. Neuropsychiatr. Clin. Neurosci.* 16 (3), 367–378.
- Schmahmann, J.D., Sherman, J.C., 1998. The cerebellar cognitive affective syndrome. *Brain* 121 (Pt 4), 561–579.
- Schraa-Tam, C.K., Rietdijk, W.J., Verbeke, W.J., et al., 2012. fMRI activities in the emotional cerebellum: a preference for negative stimuli and goal-directed behavior. *Cerebellum* 11 (1), 233–245.
- Shutter, D.J., 2016. A cerebellar framework for predictive coding and homeostatic regulation in depressive disorder. *Cerebellum* 15 (1), 30–33.
- Schwartz, J.A., Speed, N.M., Brunberg, J.A., Brewer, T.L., Brown, M., Greden, J.F., 1993. Depression in stroke rehabilitation. *Biol. Psychiatry* 33 (10), 694–699.
- Shah, S., Vanclay, F., Cooper, B., 1989. Improving the sensitivity of the Barthel index for stroke rehabilitation. *J. Clin. Epidemiol.* 42 (8), 703–709.
- Sobesky, J., Thiel, A., Ghaemi, M., et al., 2005. Crossed cerebellar diaschisis in acute human stroke: a PET study of serial changes and response to supratentorial reperfusion. *J. Cereb. Blood Flow Metab.* 25 (12), 1685–1691.
- Stiles, P.G., McGarrah, J.F., 1998. The geriatric depression scale: a comprehensive review. *Journal of Clinical Geropsychology.*
- Stoodley, C.J., 2012. The cerebellum and cognition: evidence from functional imaging studies. *Cerebellum* 11 (2), 352–365.
- Thach, W.T., Goodkin, H.P., Keating, J.G., 1992. The cerebellum and the adaptive coordination of movement. *Annu. Rev. Neurosci.* 15, 403–442.
- Unutzer, J., Katon, W., Callahan, C.M., et al., 2002. Collaborative care management of late-life depression in the primary care setting: a randomized controlled trial. *JAMA* 288 (22), 2836–2845.
- Videbech, P., Ravnkilde, B., Pedersen, T.H., et al., 2002. The Danish PET/depression project: clinical symptoms and cerebral blood flow. A regions-of-interest analysis. *Acta Psychiatr. Scand.* 106 (1), 35–44.
- Wang, D., Buckner, R.L., Liu, H., 2013. Cerebellar asymmetry and its relation to cerebral asymmetry estimated by intrinsic functional connectivity. *J. Neurophysiol.* 109 (1), 46–57.
- Wang, L., Leonards, C.O., Sterzer, P., Ebinger, M., 2014. White matter lesions and depression: a systematic review and meta-analysis. *J. Psychiatr. Res.* 56, 56–64.
- Wei, N., Yong, W., Li, X., et al., 2015. Post-stroke depression and lesion location: a systematic review. *J. Neurol.* 262 (1), 81–90.
- Wilson, S.M., Lam, D., Babiak, M.C., et al., 2015. Transient aphasias after left hemisphere resective surgery. *J. Neurosurg.* 123 (3), 581–593.