Dental Materials Journal 2017; 36(1): 41–47

Biological efficacy of two mineral trioxide aggregate (MTA)-based materials in a canine model of pulpotomy

Myeongyeon LEE[1]*, Chung-Min KANG[1]*, Je Seon SONG[1,2], Yooseok SHIN[2,3], Seunghye KIM[4], Seong-Oh KIM[1,2] and Hyung-Jun CHOI[1,2]

[1] *Department of Pediatric Dentistry, College of Dentistry, Yonsei University, Seoul, Republic of Korea, 50 Yonseiro, Seodamun-Gu, Seoul, 120-752, Korea*
[2] *Oral Science Research Center, College of Dentistry, Yonsei University, Seoul, Republic of Korea, 50 Yonseiro, Seodamun-Gu, Seoul, 120-752, Korea*
[3] *Department of Conservative Dentistry, College of Dentistry, Yonsei University, Seoul, Republic of Korea, 50 Yonseiro, Seodamun-Gu, Seoul, 120-752, Korea*
[4] *Department of Pediatric Dentistry, Institute of Oral Health Science, Ajou University School of Medicine, Suwon, Republic of Korea, 164, World cup-ro, Yeongtong-gu, Suwon-si, Gyeonggi-do, Korea*
Corresponding author, Hyung-Jun CHOI; E-mail: choihj88@yuhs.ac

The aim of this study was to compare the biocompatibility of Endocem Zr® and ProRoot MTA® by histopathologic analysis in a canine model of pulpotomy. This study utilized 39 teeth of two beagle dogs. The exposed pulp tissues were treated by pulpotomy using ProRoot MTA (n=19) or Endocem Zr (n=20). After 8 weeks, the teeth were extracted and processed with hematoxylin-eosin staining for histologic evaluation. Most of the specimens in both groups developed a calcific barrier at the pulp amputation site and formed an odontoblast layer. However, some of the Endocem Zr specimens showed less calcific barrier formation with a greater inflammatory response and less odontoblast layer formation when compared with the ProRoot MTA specimens. ProRoot MTA and Endocem Zr specimens developed a calcific barrier; however, ProRoot MTA was more biocompatible than Endocem Zr.

Keywords: Endocem Zr, Mineral trioxide aggregate, ProRoot MTA, Pulpotomy

INTRODUCTION

In recent years, there have been considerable developments in vital pulp therapy following introduction of mineral trioxide aggregate (MTA). The purpose of vital pulp therapy is to maintain pulp viability and function. In cases of mechanical or traumatic pulp exposure, vital pulp therapies, including direct pulp capping, partial pulpotomy, and full pulpotomy, are recommended, especially when immature permanent teeth are involved[1-3].

Pulpotomy is a common procedure for maintaining pulp viability[2]. It is performed on primary molar teeth with extensive dental caries but without clinical or radiologic evidence of pulp degeneration, and on permanent teeth with traumatic pulp exposure requiring apexogenesis[1,2]. For pulpotomy to be successful, the dressing material should ideally be bactericidal, harmless to the pulp and surrounding structures, and effective for healing the radicular pulp. Additionally, it should not interfere with physiologic root resorption[4].

To satisfy the above conditions, calcium hydroxide (CH) has traditionally been the material of choice for a pulpotomy procedure involving an immature permanent tooth[5]. CH has antibacterial properties due to its high pH and can stimulate mineralization[6]. However, despite the widespread use of CH in vital therapy for permanent teeth, MTA is increasingly recommended nowadays as a substitute for CH because of its low solubility and ability to form a strong calcific barrier[3].

MTA was approved for use in endodontic treatment by the US Food and Drug Administration in 1998, and ProRoot MTA® (Dentsply, Tulsa Dental Products, Tulsa, OK, USA) was the first commercial MTA product introduced in the dental market. There have been several reports on the good biocompatibility and favorable physicochemical properties of MTA[7,8], and the product has been associated with favorable outcomes in vital pulp therapy[2,3].

However, there are some limitations associated with clinical application of MTA. Some authors have reported that ProRoot MTA causes tooth discoloration, has a long setting time, and is difficult to handle[9]. Therefore, much effort has been made to modify the chemical composition of MTA-based materials used in pulp therapy.

Endocem Zr® (Maruchi, Wonju, Korea) is a newly developed MTA-based material, the composition of which is shown in Table 1. According to previous research, tooth discoloration can be reduced by replacement of the radiopacifier[10], so the radiopacifier in Endocem Zr has been changed from bismuth oxide to zirconium oxide. Endocem Zr® has a relatively shorter final setting time (4±0.5 min) than ProRoot MTA®

*Authors who contributed equally to this work.
Color figures can be viewed in the online issue, which is available at J-STAGE.

Received Apr 18, 2016: Accepted Aug 5, 2016
doi:10.4012/dmj.2016-121 JOI JST.JSTAGE/dmj/2016-121

Table 1 Compositions of ProRoot MTA® and Endocem Zr®

Material	Manufacturer	Composition	Content (wt%)
ProRoot MTA®	Densply, Tulsa, OK	Calcium oxide (CaO)	44.2
		Silicon dioxide (SiO_2)	21.2
		Bismuth oxide (Bi_2O_3)	16.1
		Aluminium oxide (Al_2O_3)	1.9
		Magnesium oxide (MgO)	1.4
		Sulphur trioxide (SO_3)	0.6
		Ferrous oxide (FeO)	0.4
Endocem Zr®	MARUCHI, Wonju, Korea	Calcium oxide (CaO)	27–37
		Silicon dioxide (SiO_2)	7–11
		Aluminium oxide (Al_2O_3)	3–5
		Magnesium oxide (MgO)	1.7–2.5
		Ferrous oxide (Fe_2O_3)	1.3–2.3
		Zirconium oxide (ZrO_2)	43–46

(261±21 min)[11]. However, Chung *et al.,* performed an *in vitro* study of the cytotoxicity of these materials and reported that Endocem Zr was more cytotoxic and associated with lower expression of vascular endothelial growth factor and angiogenin[12]. However, further *in vivo* study is needed to evaluate the biocompatibility of this new material. The aim of this study was to compare the response of dental pulp to Endocem Zr with that to ProRoot MTA by histopathologic analysis in a dog model of pulpotomy.

MATERIALS AND METHODS

Animal model

Thirty-nine teeth in two beagle dogs (age 18–24 months) were used in this study. Incisors, canines, and first and second premolars of the maxilla and mandible were selected. All animal procedures conformed to the Institutional Animal Care and Use Committee, Yonsei Medical Center, Seoul, Korea (certification #2013-0317-4).

The teeth were divided into two groups on the basis of the pulp capping materials used in the cervical pulpotomy procedure as follows: Endocem Zr (n=20) and ProRoot MTA (control group, n=19).The teeth were equally distributed among the groups according to tooth type, except one congenitally missing mandibular incisor in the ProRoot MTA group. Table 1 shows the composition of these materials.

Surgical protocol

The surgical procedures were performed in a sterile operating room. General anesthesia was induced by intravascular injection of Zoletil® (5 mg/kg; Virbac Korea, Seoul, Korea) and xylazine (0.2 mg/kg; Rompun®, Bayer Korea, Seoul, Korea) and inhaled isoflurane (Gerolan®, Choongwae Pharmaceutical, Seoul, Korea). To prevent infection, a subcutaneous injection of enfloxacin (5 mg/kg) was given just before and after treatment, and intraoral amoxicillin clavulanate (12.5 mg/kg) was administered for 5–7 days postoperatively.

Pulpotomy procedure

Local anesthetic was delivered using lidocaine (2% lidocaine hydrochloride with epinephrine 1:100,000; Kwangmyung Pharmaceutical, Seoul, Korea). The pulp was mechanically exposed *via* occlusal cavities using a high speed carbide bur No. 330 (H7 314 008, Brasseler, Germany) with water spray. After coronal accessment, the coronal portion of pulp was removed at the level of the cementoenamel junction. Bleeding was controlled by application of a sterile cotton pellet with light pressure and irrigation with sterile saline. The remaining pulp was covered with the experimental material, and cotton pellets moistened with saline were used to adapt MTA onto the pulp wound area. The cavities were restored with conventional glass-ionomer cement (Ketac-Molar, ESPE Platz, Seefeld, Germany). The animals were euthanized 8 weeks after the procedure.

Histologic analysis

The teeth were extracted with forceps and the apical third of each root was removed with a high-speed bur. The specimens were fixed in 10% buffered formalin (Sigma-Aldrich, St Louis, MO, USA) for 48 h, demineralized in ethylenediaminetetraacetic acid (pH 7.4; Fisher Scientific, TX, USA) for 6 weeks, and then embedded in paraffin. For each specimen, 3-μm serial sections were made in the buccolingual direction and stained with hematoxylin-eosin. We made 2 slides for each tooth, each containing 4 histosections. The specimens were observed with a BX40 optical microscope (Olympus Optical, Tokyo, Japan), and imaged using an Infinity 2.0 CCD digital camera (Lumenera, Ottawa, ON, Canada) and InnerView 2.0 image analyzer software (Innerview, Seongnam-Si, Gyeonggi-do, Korea).

The sections were examined by five investigators (YS, JK, HL, JH and ML) blinded to the groups. One histosection for each tooth was selected by agreement

of the investigators. Histopathologic analysis included calcific barrier formation (continuity, morphological aspects, and thickness), extent of the inflammatory reaction (chronic or acute, number of cells, and extension of the reaction), hyperemia, and formation of an odontoblast layer. All findings were scored 1 to 4 using a modified version of the scoring system devised by Nowicka *et al.*[13] (Table 2). The final score was determined by agreement of more than three observers.

Table 2 Scores used during histological analysis of calcific barriers and dental pulp

Scores	Calcific barrier continuity
1	Complete dentin bridge formation
2	Partial/incomplete dentin bridge formation extending to more than one-half of the exposure site but not completely closing the exposure site
3	Initial dentin bridge formation extending to not more than one-half of the exposure site
4	No dentin bridge formation
Scores	**Calcific barrier morphology**
1	Dentin or dentin associated with irregular hard tissue
2	Only irregular hard tissue deposition
3	Only a thin layer of hard tissue deposition
4	No hard tissue deposition
Scores	**Tubules in calcific barrier**
1	No tubules present
2	Mild (tubules present in less than 30% of calcific barrier)
3	Moderate to severe (tubules present in more than 30% of calcific barrier)
4	No hard tissue deposition
Scores	**Inflammation intensity**
1	Absent or very few inflammatory cells
2	Mild (an average of <10 inflammatory cells)
3	Moderate (an average of 10–25 inflammatory cells)
4	Severe (an average >25 inflammatory cells)
Scores	**Inflammation extensity**
1	Absent
2	Mild (inflammatory cells next to dentin bridge or area of pulp exposure only)
3	Moderate (inflammatory cells observed in one-third or more of the coronal pulp or in the midpulp)
4	Severe (all of the coronal pulp is infiltrated or necrotic)
Scores	**Inflammation type**
1	No inflammation
2	Chronic inflammation
3	Acute and chronic inflammation
4	Acute inflammation
Scores	**Dental pulp congestion**
1	No congestion
2	Mild (enlarged blood vessels next to dentin bridge or area of pulp exposure only)
3	Moderate (enlarged blood vessels observed in one-third or more of the coronal pulp or in the midpulp)
4	Severe (all of the coronal pulp is infiltrated with blood cells)
Scores	**Odontoblastic cell layer**
1	Palisade pattern of cells
2	Presence of odontoblast cells and odontoblast-like cells
3	Presence of odontoblast-like cells only
4	Absent

Statistical analysis

Statistical analysis of the collected data was performed using SPSS version 20 software (SPSS, Chicago, IL, USA). Independent *t*-tests were used to identify the group differences for these scores. Statistical significance was set at $p<0.05$.

RESULTS

Histopathologic evaluation was performed for 18 ProRoot MTA and 14 Endocem Zr specimens. One specimen from the ProRoot MTA group and 6 from the Endocem Zr group were excluded because of failure during teeth extraction or histopathologic processing. One specimen from each group was excluded from the evaluation of inflammation and the odontoblast layer due to pulpal

Table 3 Score percentages for calcific barriers

Groups	Calcific barrier continuity (%)				Calcific barrier morphology (%)			
	1	2	3	4	1	2	3	4
ProRoot MTA® [a]	77.78 (14/18)*	16.67 (3/18)	5.56 (1/18)	—	33.33 (6/18)	61.11 (11/18)	5.56 (1/18)	—
Endocem Zr® [a]	57.14 (8/14)	28.57 (4/14)	7.14 (1/14)	7.14 (1/14)	14.29 (2/14)	64.29 (9/14)	14.29 (2/14)	7.14 (1/14)

[a]Groups with same letters are not significantly different ($p>0.05$)

Table 3 Continued

Groups	Tubules in calcific barrier (%)			
	1	2	3	4
ProRoot MTA® [a]	16.67 (3/18)	55.56 (10/18)	27.78 (5/18)	—
Endocem Zr® [b]	—	50.00 (7/14)	42.86 (6/14)	7.14 (1/14)

*(number of teeth receiving the score/total number of teeth evaluated)
[a, b] Groups with different letters are significantly different ($p<0.05$).

Table 4 Score percentages for inflammatory responses

Groups	Inflammation intensity (%)				Inflammation extensity (%)			
	1	2	3	4	1	2	3	4
ProRoot MTA® [a]	41.18 (7/17)*	41.18 (7/17)	11.76 (2/17)	5.88 (1/17)	47.06 (8/17)	41.18 (7/17)	11.76 (2/17)	—
Endocem Zr® [a]	30.77 (4/13)	46.15 (6/13)	23.08 (3/13)	—	30.77 (4/13)	53.85 (7/13)	15.39 (2/13)	—

[a] Groups with same letters are not significantly different ($p>0.05$)

Table 4 Continued

Groups	Inflammation type (%)				Dental pulp congestion (%)			
	1	2	3	4	1	2	3	4
ProRoot MTA® [a]	47.06 (8/17)	52.94 (9/17)	—	—	23.53 (4/17)	52.94 (9/17)	23.53 (4/17)	—
Endocem Zr® [a]	30.77 (4/13)	69.23 (9/11)	—	—	23.08 (3/13)	61.54 (8/13)	15.39 (2/13)	—

*(number of teeth receiving the score/total number of teeth evaluated)
[a]Groups with same letters are not significantly different ($p>0.05$)

Table 5 Score prcentages for the odontoblastic cell layer

Groups	Odontoblastic cell layer (%)			
	1	2	3	4
ProRoot MTA® [a]	23.53 (4/17)*	52.94 (9/17)	17.65 (3/17)	5.88 (1/17)
Endocem Zr® [a]	15.38 (2/13)	30.77 (4/13)	46.15 (6/13)	7.69 (1/13)

*(number of teeth receiving the score/total number of teeth evaluated)
[a] Groups with same letters are not significantly different (p>0.05)

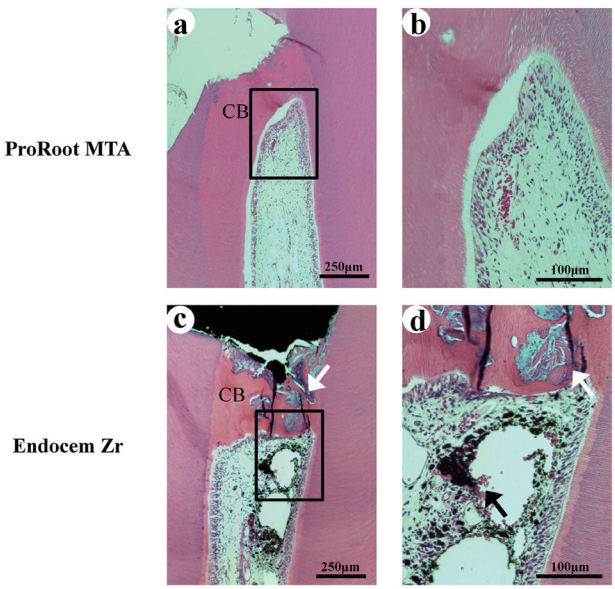

Fig. 1 Formation of the CB in the ProRoot MTA® and Endocem Zr® groups after 8 weeks.
(a, b) show features associated with ProRoot MTA and (c, d) show features associated with Endocem Zr (a, c: scale bar=250 µm, b, d: scale bar=100 µm). The tubular defects and irregular calcific barrier margin are shown in the Endocem Zr specimen (d). Black arrows indicate the presence of inflammatory cells and white arrows indicate the presence of a tubular defect in the CB (hematoxylin eosin staining, 40×magnification). Abbreviation: CB, calcific barrier.
The scores of calcification barrier continuity, morphology and tubular defects for (a) and (c) were 1, 1, 1 and 1, 2, 3, respectively. In terms of dental pulp inflammation, the scores of intensity, extensity, type, and congestion for (a) and (c) were 1, 1, 1, 2 and 2, 2, 2, 2, respectively. The scores for the odontoblastic cell layer of figure (a) and (c) were 1 and 2.

tissue amputation. Tables 3–5 show the percentages of scores for each material. In general, ProRoot MTA had better scores than Endocem Zr (Fig. 1).

Calcific barrier formation
The percentages of scores given for calcific barrier formation using each material are shown in Table 3. In total, 77.68% of ProRoot MTA and 57.14% of Endocem Zr specimens formed a calcific barrier that completely obliterated the pulp amputation site. Notably, formation of hard tissue was not observed in one Endocem Zr specimen. In terms of tubular defects in the calcific barrier, ProRoot MTA more scores of 1 and 2 than Endocem Zr; this difference was statistically significant different.

Pulp reaction
In total, 47.06% of ProRoot MTA and 30.77% of Endocem Zr specimens were found to be free of inflammation. Mild dental pulp congestion was observed in both groups, with the majority of specimens having a score of 2 (Table 4); there was no statistically significant difference between the ProRoot MTA and Endocem Zr groups in this regard.

Odontoblastic cell layer
In the ProRoot MTA group, 23.53% of specimens had a score of 1 (indicating a palisading odontoblast pattern) and 53.95% had a score of 2 (indicating the presence of odontoblasts and odontoblast-like cells). Although, there was no statistically significant difference between the ProRoot MTA and Endocem Zr groups, the Endocem Zr group displayed a distinct tendency compared with the ProRoot MTA group. The majority of specimens in the Endocem Zr group had scores of 2 (30.77%) or 3 (46.15%) (Table 5).

DISCUSSION

The aim of this study was to evaluate the biological efficacy of Endocem Zr using a dog model of pulpotomy. ProRoot MTA was used as a positive control. Both materials induced formation of a complete calcific barrier at the pulp amputation site with controlled inflammation of the pulp tissue. However, the ProRoot MTA specimens showed better calcific barrier morphology and fewer tubular defects than their Endocem Zr counterparts.

Endocem Zr is a pozzolan-based, white-colored

MTA material developed to overcome the long setting time and tooth discoloration found with conventional MTA. Endocem® was the previously introduced pozzolan-based MTA material, and has been reported to have biocompatibility and mineralization potential comparable with that of ProRoot MTA[11,14]. However, in spite of the decreased setting time of Endocem, use of MTA for vital pulp therapy involving the anterior teeth is limited by its propensity to cause tooth discoloration[15]. Bismuth oxide, which is used as a radiopacifier in MTA cement, interacts with the collagen in dentin, so could be the cause of tooth discoloration[16]. Therefore, the radiopacifier was replaced with zirconium oxide in the Endocem Zr formulation. Some authors have reported on the propensity for discoloration[10], biocompatibility[12], and physicochemical properties[17,18] of Endocem Zr, but clinical use of this new material needs to be supported by *in vivo* research.

To evaluate the response of the dental pulp to each material, we used a modified version of the scoring system devised by Nowicka *et al.*[13]. This scoring system includes evaluation of the calcific barrier, inflammation of the dental pulp, dental pulp congestion, and formation of an odontoblast layer. We considered formation of a calcific barrier to be a beneficial pulp reaction after a pulpotomy procedure. However, formation of a calcific barrier could be interpreted either as a healing process or as a reaction to irritation[19,20]. Further, the dental pulp tissue could come into contact with the coronal aspects of the calcific barrier *via* tubular defects therein[21]. Therefore, we included criteria for evaluation of the dental pulp, *i.e.*, inflammation, congestion, and patterns of odontoblast-like cells.

Although both materials showed the ability to form a calcific barrier, the ProRoot MTA specimens developed a better barrier in terms of quality and quantity. MTA produces calcium ions *via* a hydration procedure[22]. Calcium ions stimulate the dental pulp cells at the amputation site to synthesize fibronectin in a dose dependent manner[23]. Fibronectin plays a role in the differentiation of odontoblast-like cells and formation of the hard tissue barrier[24]. According to one *in vitro* study, the calcium ion concentration in Endocem Zr is less than that in ProRoot MTA[17]. An increased concentration of extracellular calcium induces the biological response of dental pulp cells and contributes to formation of the calcific barrier[23]. Therefore, the low extracellular calcium ion concentration achieved using Endocem Zr could explain the deficient calcific barrier formation found when this material is used.

The major component of Endocem Zr is zirconium oxide, which substitutes for bismuth oxide to reduce tooth discoloration. Zirconium oxide is a radiopacifier with the characteristics of biocompatibility[25] and radiopacity[26] and an ability to accelerate hydration[27]. In a previous study of radiopacifier replacement in Portland cement, zirconium oxide was reported not to participate in the hydration reaction[28] and not to affect its physical properties[29]. However, the atomic number of zirconium is half that of bismuth, so the proportion of zirconium oxide in Endocem Zr needs to be higher than the proportion of bismuth oxide in ProRoot MTA to show a similar degree of radiopacity[26]. According to the manufacturer's specifications, 43–46 wt% of Endocem Zr consists of zirconium oxide (Table 1) and this has been shown to have adequate radiopacity. However, a decreased amount of calcium silicate in cement indicates possible shortcomings in terms of calcium ion release[18,30]. Calcium ion release from Portland cement has been reported to decrease on addition of a radiopacifying agent[28,30]. This could be a reason for the lower extracellular calcium ion concentration and calcific barrier formation found with Endocem Zr.

Sealing ability is another reason for the less favorable histologic result achieved using Endocem Zr. Coronal microbial leakage could cause reinfection of the pulp cavity[31], so the sealing ability of the capping material is essential for the clinical success of vital pulp therapy. It appears that MTA provides good sealing ability and marginal adaptation[32]. It has been reported that Endocem, the earlier pozzolan-based MTA material, has sealing ability comparable with that of ProRoot MTA[11]. In contrast, Endocem Zr was found to have less favorable sealing ability than other MTA-based materials in a dye penetration study[18]. However, the results of dye penetration studies do not necessarily reflect bacterial invasion[33], and there are no reports on the mechanical properties of Endocem Zr. Thus, further studies are needed to evaluate the physicochemical properties of Endocem Zr.

In terms of biocompatibility, the only study published to date on cell viability with Endocem Zr reported initial transient cytotoxicity in the fresh mixed state and lower levels of angiogenic factors, such as vascular endothelial growth factor, angiogenin, and basic fibroblast growth factor-2 than ProRoot MTA[12,14]. Endocem is reported to be associated with less cell viability than ProRoot MTA and Angelus MTA®, especially in the fresh mixed state[14]. Chung *et al.* considered the higher concentration of aluminum in pozzolan-based cement to be a cause of the initial transient cytotoxicity associated with this material[12]. In spite of the initial transient cytotoxicity of Endocem Zr, the inflammatory response and dental pulp congestion scores were comparable with those of ProRoot MTA.

In the present study, ProRoot MTA achieved a better histologic result than Endocem Zr, especially in terms of formation of a calcific barrier. However, Endocem Zr has the advantages of a shorter setting time and not causing tooth discoloration Moreover, previous clinical studies have shown that the histologic findings for vital pulp therapy do not always coincide with clinical signs and symptoms[34,35]. Therefore, further clinical studies using human teeth may be required for evaluation of the biological efficacy of this material.

CONCLUSION

This *in vivo* study compared ProRoot MTA and Endocem Zr with regard to the dental pulp response after a

pulpotomy procedure. Endocem Zr showed inferiority, especially in formation of a calcific barrier. However, the inflammatory response of dental pulp tissue was similar with both materials.

ACKNOWLEDGMENTS

This study was supported by the Yonsei University College of Dentistry Fund (6-2014-0083). The authors deny any conflicts of interest related to this study.

REFERENCES

1) Cohenca N, Paranjpe A, Berg J. Vital pulp therapy. Dent Clin North Am 2013; 57: 59-73.
2) Fuks AB. Vital pulp therapy with new materials for primary teeth: new directions and treatment perspectives. J Endod 2008; 34: S18-S24.
3) Witherspoon DE. Vital pulp therapy with new materials: new directions and treatment perspectives —permanent teeth. J Endod 2008; 34: S25-S28.
4) Sonmez D, Sari S, Çetinbaş T. A Comparison of four pulpotomy techniques in primary molars: a long-term follow-up. J Endod 2008; 34: 950-955.
5) Farhad A, Mohammadi Z. Calcium hydroxide: a review. Int Dent J 2005; 55: 293-301.
6) Foreman PC, Barnes IE. A review of calcium hydroxide. Int Endod J 1990; 23: 283-297.
7) Camilleri J, Pitt Ford T. Mineral trioxide aggregate: a review of the constituents and biological properties of the material. Int Endod J 2006; 39: 747-754.
8) Rao A, Rao A, Shenoy R. Mineral trioxide aggregate —a review. J Clin Pediatr Dent 2009; 34: 1-8.
9) Islam I, Chng HK, Yap AUJ. Comparison of the physical and mechanical properties of MTA and Portland cement. J Endod 2006; 32: 193-197.
10) Kang SH, Shin YS, Lee HS, Kim SO, Shin Y, Jung IY, Song JS. Color changes of teeth after treatment with various mineral trioxide aggregate–based materials: an ex vivo study. J Endod 2015; 41: 737-741.
11) Choi Y, Park SJ, Lee SH, Hwang YC, Yu MK, Min KS. Biological effects and washout resistance of a newly developed fast-setting pozzolan cement. J Endod 2013; 39: 467-472.
12) Chung C, Kim E, Song M, Park JW, Shin SJ. Effects of two fast-setting calcium-silicate cements on cell viability and angiogenic factor release in human pulp-derived cells. Odontology 2016; 104: 143-151.
13) Nowicka A, Lipski M, Parafiniuk M, Sporniak-Tutak K, Lichota D, Kosierkiewicz A, Kaczmarek W, Buczkowska-Radlińska J. Response of human dental pulp capped with biodentine and mineral trioxide aggregate. J Endod 2013; 39: 743-747.
14) Song M, Yoon TS, Kim SY, Kim E. Cytotoxicity of newly developed pozzolan cement and other root-end filling materials on human periodontal ligament cell. Restor Dent Endod 2014; 39: 39-44.
15) Yun DA, Park SJ, Lee SR, Min KS. Tooth discoloration induced by calcium-silicate-based pulp-capping materials. Eur J Dent 2015; 9: 165-170.
16) Marciano MA, Costa RM, Camilleri J, Mondelli RFL, Guimarães BM, Duarte MAH. Assessment of color stability of white mineral trioxide aggregate angelus and bismuth oxide in contact with tooth structure. J Endod 2014; 40: 1235-1240.
17) Han L, Kodama S, Okiji T. Evaluation of calcium-releasing and apatite-forming abilities of fast-setting calcium silicate-based endodontic materials. Int Endod J 2015; 48: 124-130.
18) Lee KS, Kim JS, Lee DY, Kim RJY, Shin JH. In vitro microleakage of six different dental materials as intraorifice barriers in endodontically treated teeth. Dent Mater J 2015; 34: 425-431.
19) Al-Hezaimi K, Salameh Z, Al-Fouzan K, Al Rejaie M, Tay FR. Histomorphometric and micro-computed tomography analysis of pulpal response to three different pulp capping materials. J Endod 2011; 37: 507-512.
20) Schröder U. Effects of calcium hydroxide-containing pulp-capping agents on pulp cell migration, proliferation, and differentiation. J Dent Res 1985; 64: 541-548.
21) Goldberg F, Massone EJ, Spielberg C. Evaluation of the dentinal bridge after pulpotomy andcalcium hydroxide dressing. J Endod 1984; 10: 318-320.
22) Camilleri J. Characterization of hydration products of mineral trioxide aggregate. Int Endod J 2008; 41: 408-417.
23) Mizuno M, Banzai Y. Calcium ion release from calcium hydroxide stimulated fibronectin gene expression in dental pulp cells and the differentiation of dental pulp cells to mineralized tissue forming cells by fibronectin. Int Endod J 2008; 41: 933-938.
24) Yoshiba K, Yoshiba N, Nakamura H, Iwaku M, Ozawa H. Immunolocalization of fibronectin during reparative dentinogenesis in human teeth after pulp capping with calcium hydroxide. J Dent Res 1996; 75: 1590-1597.
25) Dion I, Bordenave L, Lefebvre F, Bareille R, Baquey C, Monties JR, Havlik P. Physico-chemistry and cytotoxicity of ceramics. J Mater Sci Mater Med 1994; 5: 18-24.
26) Húngaro Duarte MA, de Oliveira El Kadre GDa, Vivan RR, Guerreiro Tanomaru JM, Filho MT, de Moraes IG. Radiopacity of Portland cement associated with different radiopacifying agents. J Endod 2009; 35: 737-740.
27) Li Q, Deacon AD, Coleman NJ. The impact of zirconium oxide nanoparticles on the hydration chemistry and biocompatibility of white Portland cement. Dent Mater J 2013; 32: 808-815.
28) Camilleri J, Cutajar A, Mallia B. Hydration characteristics of zirconium oxide replaced Portland cement for use as a root-end filling material. Dent Mater 2011; 27: 845-854.
29) Cutajar A, Mallia B, Abela S, Camilleri J. Replacement of radiopacifier in mineral trioxide aggregate; characterization and determination of physical properties. Dent Mater 2011; 27: 879-891.
30) Hungaro Duarte MA, Minotti PG, Rodrigues CT, Zapata RO, Bramante CM, Filho MT, Vivan RR, Gomes de Moraes I, Bombarda de Andrade F. Effect of different radiopacifying agents on the physicochemical properties of white Portland cement and white mineral trioxide aggregate. J Endod 2012; 38: 394-397.
31) Madison S, Wilcox LR. An evaluation of coronal microleakage in endodontically treated teeth. Part III. In vivo study. J Endod 1988; 14: 455-458.
32) Torabinejad M, Parirokh M. Mineral trioxide aggregate: a comprehensive literature review —Part II: Leakage and biocompatibility investigations. J Endod 2010; 36: 190-202.
33) Barthel C, Moshonov J, Shuping G, Orstavik D. Bacterial leakage versus dye leakage in obturated root canals. Int Endod J 1999; 32: 370-375.
34) Iwamoto CE, Adachi E, Pameijer CH, Barnes D, Romberg EE, Jefferies S. Clinical and histological evaluation of white ProRoot MTA in direct pulp capping. Am J Dent 2006; 19: 85-90.
35) Caicedo R, Abbott P, Alongi D, Alarcon M. Clinical, radiographic and histological analysis of the effects of mineral trioxide aggregate used in direct pulp capping and pulpotomies of primary teeth. Aust Dent J 2006; 51: 297-305.