

Caruncle excision to treat epiphora caused by caruncle swelling in patients with active Graves' ophthalmopathy: case series

Yoon Jin Kong¹, Sang Youn Han², Jin Sook Yoon³, Sun Young Jang¹

¹Department of Ophthalmology, Soonchunhyang University Bucheon Hospital, Soonchunhyang University College of Medicine, Bucheon 14584, Korea

²Department of Ophthalmology, Kim's Eye Hospital, Myung-Gok Eye Research Institute, Konyang University College of Medicine, Seoul 07301, Korea

³Department of Ophthalmology, Severance Hospital, Institute of Vision Research, Yonsei University College of Medicine, Seoul 03722, Korea

Correspondence to: Sun Young Jang. Department of Ophthalmology, Soonchunhyang University Bucheon Hospital, Soonchunhyang University College of Medicine, Bucheon 14584, Korea. ysyat01@naver.com

Received: 2015-11-10 Accepted: 2016-05-03

DOI:10.18240/ijo.2016.11.25

Kong YJ, Han SY, Yoon JS, Jang SY. Caruncle excision to treat epiphora caused by caruncle swelling in patients with active Graves' ophthalmopathy: case series. *Int J Ophthalmol* 2016;9(11):1691-1693

Dear Editor,

I am Yoon Jin Kong from the Department of Ophthalmology, Soonchunhyang University Bucheon Hospital, Bucheon, Korea. Herein, we describe a series of three patients with active Graves' ophthalmopathy (GO) who presented with epiphora caused by swollen caruncles whose symptoms improved after surgical excision of the caruncles. Caruncle swelling is common in patients with active GO^[1]. Acute nonspecific inflammation induces infiltration of hydrophilic hyaluronic acid and cellular debris into the caruncular tissue, which can be used to assess disease activity^[1-2]. The swollen caruncle may impair fluid flow from the lacrimal gland to the punctum, triggering epiphora, although the nasolacrimal system is normal^[3-4].

All the cases were conducted in accordance with the Declaration of Helsinki. All patients underwent an ophthalmic examination, including slit-lamp assessment, Schirmer's test, tear breakup time (TBUT), tear meniscus height (TMH), fluorescein dye disappearance test (FDDT) and the nasolacrimal duct irrigation test. In all subjects, we found swollen caruncle and adjacent redundant conjunctiva, which protrude over the lower eyelid margin and block the

entrance of the punctum. We performed excision of caruncle using similar pattern reported by Mombaerts and Colla^[4]. The amount of caruncle that had to be resected was judged after topical anesthesia. After insertion of an eye speculum, a vertical ellipse of caruncular tissue, including the adjacent plical semilunaris, was excised en bloc using scissors. The excision was ended in a tail-like excision of redundant conjunctiva in the lower fornix (Figure 1). The conjunctiva were closed with interrupted Vicryl 8-0 sutures.

CASE 1

A 64-year-old female presented with epiphora more than 6mo in duration. She had been treated with oral steroids after a diagnosis of active GO. Both eyelids were swollen and red. On slit-lamp examination, caruncle swelling, conjunctival chemosis, and hyperemia were evident in both eyes, but neither cornea had a specific lesion. Schirmer's test and the TBUT were normal. No lid lag or retraction was evident. The Hertel exophthalmometry measurements were 17 mm for both eyes. Both upper and lower puncta were intact and the nasolacrimal duct irrigation test was positive. The TMH was 1.5 mm in both eyes. The FDDT revealed 3+ in both eyes based on the classification of Zappia and Milder^[5]. The swollen caruncle causing obstruction of the lower punctum was excised. The epiphora symptoms resolved 1mo later even though the clinical activity scores (CAS) was still 4; the TMH was 0.5 mm, and the FDDT was 1+ in both eyes. At the 1-year final follow-up, no recurrence of caruncle swelling or epiphora was observed (Figure 2A, 2B), and the CAS was 2.

CASE 2

A 49-year-old male presented with epiphora. He had undergone orbital decompression due to compressive optic neuropathy which was nonresponsive to glucocorticoids. The Hertel exophthalmometry measurements were decreasing from 24 mm to 18 mm in both eyes after decompression. Epiphora was present both before and after decompression. Both eyelids were swollen and red. On slit-lamp examination, caruncle swelling and scleral vessel engorgement were observed. Neither cornea had a specific lesion. No lid lag or retraction was evident. Schirmer's test and the TBUT were normal. Both upper and lower puncta were intact and the nasolacrimal duct irrigation test was positive. The TMH was 2.0 mm in both eyes. The FDDT




Figure 1 Schematic drawing of the amount of excision of caruncular tissue (outlined by dashed line) in the caruncle excision procedure.

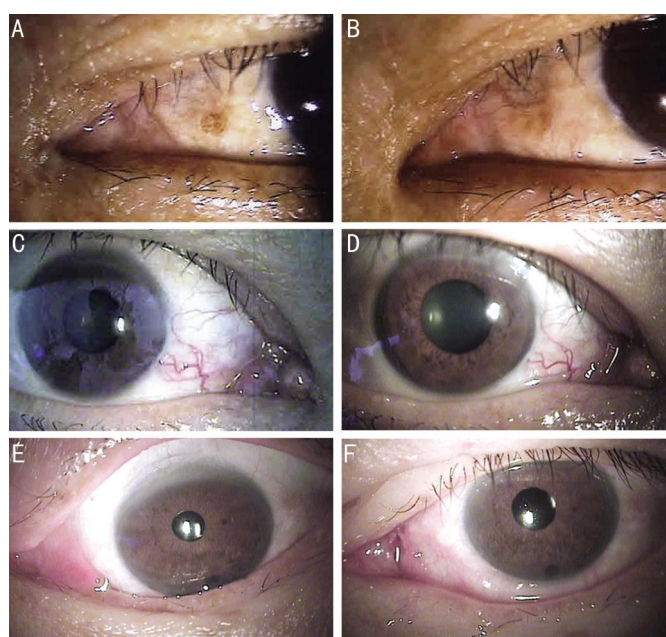

Figure 2 Slit-lamp examination of three patients A: Slit-lamp examination of patient 1 showing a swollen caruncle in her left eye; B: One month after caruncle excision, no recurrence of caruncle swelling was observed; C: Slit-lamp examination of patient 2 showing swollen caruncles in right eye; D: One year after the caruncle excision, no recurrence of caruncle swelling was observed; E: Slit-lamp examination of patient 3 showing a swollen caruncle in the left eye; F: Slit-lamp examination immediately after caruncle excision.

was 4+ in both eyes. We excised the swollen caruncle of both eyes. The symptoms improved by 1mo after surgery; the TMH was 1.0 mm and the FDDT was 1+ in both eyes. At the final 1-year follow-up, no recurrence of caruncle swelling or epiphora was observed (Figure 2C, 2D), and the CAS was 4.

CASE 3

A 65-year-old female presented with epiphora of the left eye more than 1y in duration. Both eyelids were swollen and red. On slit-lamp examination, caruncle swelling and punctate epithelial erosions were observed in both eyes, being most

severe in the left eye. Schirmer's test result was 5 mm, and the TBUT was 3s for both eyes. No lid lag or retraction was observed. The Hertel exophthalmometry measurements were 13 mm in the right eye and 15 mm in the left eye. The patient was diagnosed with active GO, and intravenous and oral glucocorticoid therapy was started. Artificial tears were given to treat the dry eye and corneal lesions. However, the epiphora did not improve. Both upper and lower puncta were intact and the nasolacrimal duct irrigation test was positive. The TMH was 0.5 mm in the right eye and 1.5 mm in the left eye. The FDDT was 1+ in the right eye and 4+ in the left eye. We excised the swollen caruncle of the left eye. The symptoms resolved by 1mo after surgery; the TMH was 0.5 mm and the FDDT was 1+ in the left eye. At the 6-month final follow-up, no recurrence of caruncle swelling or epiphora was observed (Figure 2E, 2F) and the CAS was 3.

DISCUSSION

Epiphora in patients with GO may be caused by excess reflexive tearing attributable to dry eye, induced by corneal exposure caused by eyelid retraction, proptosis, and decreased tear secretion [6-8]. However, two patients in this study did not exhibit corneal exposure, and both Schirmer's test and TBUT were normal. One patient exhibited corneal erosions and abnormal Schirmer's test and TBUT, so she was prescribed artificial tears to treat corneal irritation, but her epiphora symptoms did not improve. All patients had intact puncta and passed the nasolacrimal duct irrigation test, but the TMH was elevated. In all cases, we determined that the swollen caruncles occluded puncta entrance and were causing the epiphora. After excision of caruncle, the subjective symptoms of all patients were resolved and the FDDT showed improvement.

GO is a self-limiting disease, and a "wait and see" strategy is appropriate for most patients with mild symptoms. When the disease is severe, immunosuppressive treatments such as intravenous and/or oral glucocorticoids are required [9]. Patients with sight-threatening corneal breakdown or compressive optic neuropathy who are nonresponsive to glucocorticoids may require surgery such as orbital decompression [10-12]. However, rehabilitative surgery may be considered if the orbitopathy has been inactive for at least 6mo, and no further changes in exophthalmos, lid aperture, and extraocular muscle function are evident [12-13].

In the present study, three patients presented with epiphora possibly caused by swollen caruncles, a sign of active GO. Epiphora may interfere with daily activities by causing blurred vision, discharges, and/or a persistent crying appearance [14]. Simple surgical excision of the swollen caruncles dramatically improved symptoms and normalized the TMH in all three patients. Moreover, no recurrence was evident at the final follow-ups.

This study reported preliminary results, but we believe that a larger clinical study will confirm our conclusions. Furthermore, data such as the TMH assessed by anterior segment optical coherence tomography or pre- and postsurgical photographs of the closed eye may provide valuable clinical information to more objectively assess the effectiveness of the present surgical technique.

To our knowledge, this is the first report to describe the effectiveness of surgical excision of swollen caruncles in patients with active GO. The operation is simple and no severe complications were observed. We propose that caruncle excision should be considered for patients with active GO who present with epiphora.

ACKNOWLEDGEMENTS

Foundation: Supported by the Soonchunhyang University Research Fund (No.20160003).

Conflicts of Interest: Kong YJ, None; Han SY, None; Yoon JS, None; Jang SY, None.

REFERENCES

- 1 Mourits MP, Koornneef L, Wiersinga WM, Prummel MF, Berghout A, van der Gaag R. Clinical criteria for the assessment of disease activity in Graves' ophthalmopathy: a novel approach. *Br J Ophthalmol* 1989;73(8): 639-644.
- 2 Mourits MP, Prummel MF, Wiersinga WM, Koornneef L. Clinical activity score as a guide in the management of patients with Graves' ophthalmopathy. *Clin Endocrinol (Oxf)* 1997;47(1):9-14.
- 3 Cheema MM, Meyer DR. Epiphora secondary to punctal apposition in the setting of Graves' orbitopathy. *Ophthalm Plast Reconstr Surg* 1995;11(2): 122-124.
- 4 Mombaerts I, Colla B. Partial lacrimal carunclectomy: a simple procedure for epiphora. *Ophthalmology* 2001;108(4):793-797.
- 5 Zappia RJ, Milder B. Lacrimal drainage function. 2. The fluorescein dye disappearance test. *Am J Ophthalmol* 1972;74(1):160-162.
- 6 Bruscolini A, Abbouda A, Locuratolo N, Restivo L, Trimboli P, Romanelli F. Dry Eye Syndrome in Non-Exophthalmic Graves' Disease. *Semin Ophthalmol* 2014;24:24.
- 7 Xu N, Huang D, Yang H, Lai Z, Luo Q. Ocular surface characteristics and impression cytology in patients with active versus inactive thyroid eye disease. *Eye Sci* 2012;27(2):64-68.
- 8 Sizmaz S, Altan-Yaycioglu R, Bakiner OS, Bozkirli E, Coban-Karatas M, Ulas B. Assessment of tear meniscus with optical coherence tomography in thyroid-associated ophthalmopathy. *Curr Eye Res* 2014;39(4):323-328.
- 9 Bhatti MT, Dutton JJ. Thyroid eye disease: therapy in the active phase. *J Neuroophthalmol* 2014;34(2):186-197.
- 10 Soares-Welch CV, Fatourechi V, Bartley GB, Beatty CW, Gorman CA, Bahn RS, Bergstralh EJ, Schleck CD, Garrity JA. Optic neuropathy of Graves disease: results of transantral orbital decompression and long-term follow-up in 215 patients. *Am J Ophthalmol* 2003;136(3):433-441.
- 11 Wakelkamp IM, Baldeschi L, Saeed P, Mourits MP, Prummel MF, Wiersinga WM. Surgical or medical decompression as a first-line treatment of optic neuropathy in Graves' ophthalmopathy? A randomized controlled trial. *Clin Endocrinol* 2005;63(3):323-328.
- 12 Bartalena L, Baldeschi L, Dickinson AJ, Eckstein A, Kendall-Taylor P, Marcocci C, Mourits MP, Perros P, Boboridis K, Boschi A, Curro N, Daumerie C, Kahaly GJ, Krassas G, Lane CM, Lazarus JH, Marino M, Nardi M, Neoh C, Orgiazzi J, Pearce S, Pinchera A, Pitz S, Salvi M, Sivelli P, Stahl M, von Arx G, Wiersinga WM. Consensus statement of the European group on Graves' orbitopathy (EUGOGO) on management of Graves' orbitopathy. *Thyroid* 2008;18(3):333-346.
- 13 Baldeschi L, Wakelkamp IM, Lindeboom R, Prummel MF, Wiersinga WM. Early versus late orbital decompression in Graves' orbitopathy: a retrospective study in 125 patients. *Ophthalmology* 2006;113(5): 874-878.
- 14 Fayers T, Laverde T, Tay E, Olver JM. Lacrimal surgery success after external dacryocystorhinostomy: functional and anatomical results using strict outcome criteria. *Ophthalm Plast Reconstr Surg* 2009;25(6):472-475.