

Left Atrial Decompression by Percutaneous Left Atrial Venting Cannula Insertion during Venoarterial Extracorporeal Membrane Oxygenation Support

Ha Eun Kim, M.D.¹, Jo Won Jung, M.D.², Yu Rim Shin, M.D.¹, Han Ki Park, M.D.¹,
Young Hwan Park, M.D.¹, Hong Ju Shin, M.D.^{1,3}

Patients with venoarterial extracorporeal membrane oxygenation (ECMO) frequently suffer from pulmonary edema due to left ventricular dysfunction that accompanies left heart dilatation, which is caused by left atrial hypertension. The problem can be resolved by left atrium (LA) decompression. We performed a successful percutaneous LA decompression with an atrial septostomy and placement of an LA venting cannula in a 38-month-old child treated with venoarterial ECMO for acute myocarditis.

Key words: 1. Myocarditis
2. Extracorporeal membrane oxygenation
3. Extracorporeal circulation

CASE REPORT

A problem that has frequently emerged as a critical issue in patients with venoarterial (VA) extracorporeal membranous oxygenation (ECMO) is a dilatation of the left heart due to volume overload of the left ventricle [1]. This can lead to left atrial (LA) hypertension and cause pulmonary edema. This serious problem can be resolved with LA decompression. Conventionally, a venting cannula is placed in the left atrium via the right upper pulmonary vein or the LA auricle with a sternotomy or a lateral thoracotomy. However, these approaches are risky because of significant complications such as bleeding and scarring. Thus, we decided to perform a percutaneous decompressive procedure. The procedure chosen for

percutaneous left heart decompression varies from insertion of the LA venting cannula to placement of an atrial septal stent. Recent reports showed that there was no significant difference between these procedures [2]. Here, we describe a successful percutaneous balloon atrial septostomy and an LA venting cannula insertion during VA ECMO in a patient with severe acute myocarditis.

A 38-month-old, 11.7 kg boy was admitted for fever, upper respiratory infection symptoms, and respiratory difficulty. He had suffered from intraventricular hemorrhage and intracranial hemorrhage caused by neonatal asphyxia, and he had been kept on antiepileptic medication due to infantile spasm. His condition rapidly declined shortly after admission. The patient was transferred to the intensive care unit with very poor he-

¹Division of Cardiovascular Surgery, Department of Thoracic and Cardiovascular Surgery and ²Division of Pediatric Cardiology, Congenital Heart Disease Center, Severance Cardiovascular Hospital, Yonsei University College of Medicine, ³Department of Thoracic and Cardiovascular Surgery, Chungbuk National University Hospital, Chungbuk National University College of Medicine

Received: July 28, 2015, Revised: November 16, 2015, Accepted: November 16, 2015, Published online: June 5, 2016

Corresponding author: Hong Ju Shin, Department of Thoracic and Cardiovascular Surgery, Chungbuk National University Hospital, Chungbuk National University College of Medicine, 776 1(il)sunhwan-ro, Heungdeok-gu, Cheongju 28644, Korea
(Tel) 82-43-269-8440 (Fax) 82-43-269-6069 (E-mail) babymedi@naver.com

© The Korean Society for Thoracic and Cardiovascular Surgery. 2016. All right reserved.

© This is an open access article distributed under the terms of the Creative Commons Attribution Non-Commercial License (<http://creativecommons.org/licenses/by-nc/4.0>) which permits unrestricted non-commercial use, distribution, and reproduction in any medium, provided the original work is properly cited.

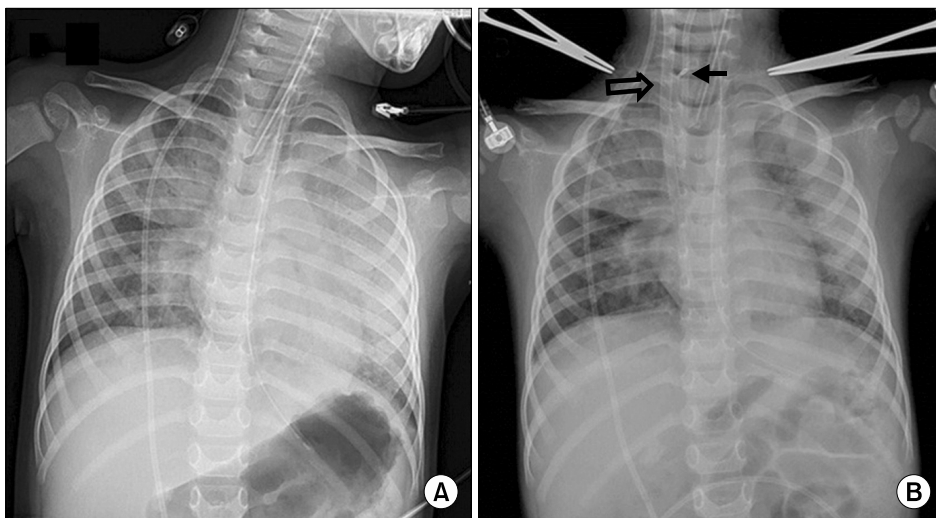


Fig. 1. (A) Preoperative chest X-ray shows cardiomegaly with haziness in the left lung. (B) Chest X-ray showing extracorporeal membrane oxygenation support via the right neck vessel. Arterial cannula (black arrow); venous cannula (open arrow).

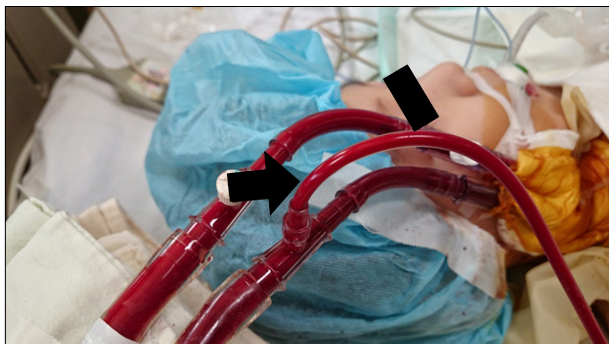


Fig. 2. Left atrial venting cannula (black arrow) connected to a venous cannula, which shows a brighter color than venous blood.

modynamics and subsequent supraventricular tachycardia (heart rate $>200/\text{min}$), which did not respond to intravenous amiodarone or adenosine. Despite conventional therapy including inotropes, his condition continued to deteriorate with tachycardia. Echocardiography revealed a marked decrease of 20% in the ejection fraction, and we therefore decided to support him with VA ECMO.

Arterial cannulation was performed via the right carotid artery with an 8 Fr percutaneous arterial cannula (RMI; Edwards Lifesciences, Irvine, CA, USA), and a 14 Fr percutaneous venous cannula (RMI, Edwards Lifesciences) was placed in the right internal jugular vein. ECMO flow was initially 1,300 mL/min and was maintained between 700 to 800 mL/min. After ECMO insertion, the patient's vital signs stabilized and his chest X-ray improved (Fig. 1). However, he began to pro-

duce a large amount of frothy, bloody endotracheal secretions and his pulse pressure disappeared twelve hours later. Follow-up echocardiography revealed marked left heart distention and a left ventricular ejection fraction lower than 10%. Therefore, fourteen hours after ECMO insertion, the patient was taken to the cardiac catheter laboratory for an atrial balloon septostomy and LA venting cannula insertion. The procedure was accomplished with a percutaneous approach through the right femoral vein without complications and an 8.5 Fr LA venting cannula (Mullins sheath; Cook Inc., Somerset, NJ, USA) was placed successfully. This LA venting cannula was then connected to the ECMO venous line (Fig. 2). After placement of the LA venting cannula, the pulse pressure appeared again, with a 15 mmHg gap between the systolic and diastolic pressure. His follow-up chest X-ray improved (Fig. 3A), and endotracheal suction became creamy and watery. Four days later, we observed recovery of left ventricular function and improvement of the chest X-ray (Fig. 3B). These improved parameters allowed successful ECMO weaning. The total ECMO running time was 63 hours. The patient was transferred to a general ward 10 days after ECMO weaning. Follow-up echocardiography showed improved LV systolic function and an ejection fraction of 65%.

DISCUSSION

Since its introduction as a major support for severe respira-

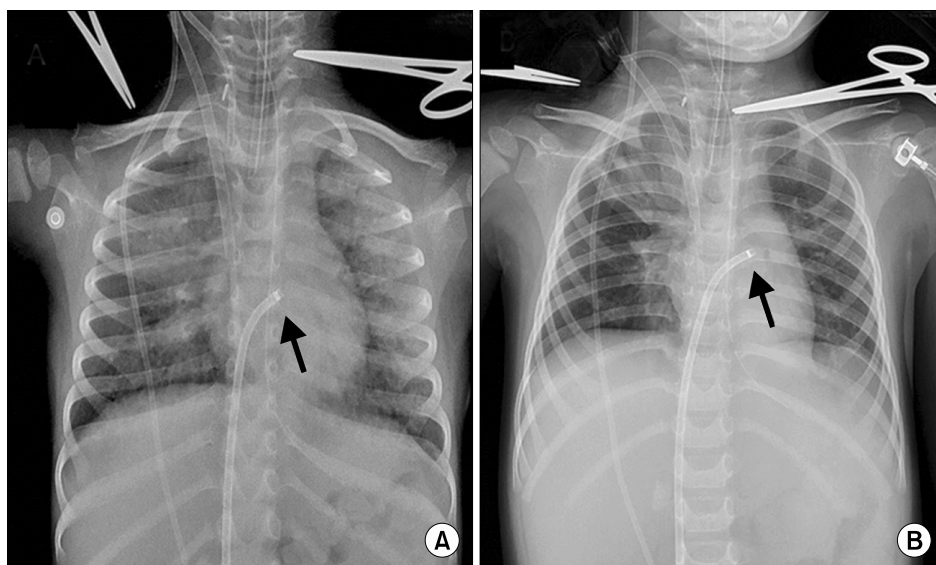


Fig. 3. (A) Chest X-ray showing improvement of pulmonary edema just after left atrial venting cannulation (black arrow). (B) Chest X-ray just before weaning of extracorporeal membrane oxygenation (black arrow).

tory distress, ECMO has become a well-established therapy in pediatric patients, particularly those with severe but reversible neonatal respiratory failure, cardiac failure, or cardiorespiratory failure. In particular, VA ECMO has been used in pediatric patients with cardiac dysfunction, such as myocarditis, cardiac arrest, and cardiomyopathy [3].

Left heart distension during VA ECMO may develop, leading to progressive left heart deterioration, pulmonary edema, and impairment of myocardial oxygenation [4]. Despite its clinical importance, the management of left heart decompression in a patient with ECMO is rarely discussed. Only sporadic case reports and a few articles have shown the efficacy of LA decompression on functional recovery of the left heart [5-7]. Conventionally, LA decompression is achieved by insertion of an LA venting cannula via sternotomy or thoracotomy. However, sternotomy or thoracotomy themselves are risky and have several complications, such as bleeding and significant scarring. Therefore, we chose a percutaneous approach to LA decompression.

LA decompression with a percutaneous cardiac catheterization-based technique including septostomy using a blade or radiofrequency ablation, balloon dilatation, and LA venting cannula insertion has been effective [2,4-6,8]. Several institutions with LA vents have identified technical issues related to management of the indwelling catheters, such as kinking, poor flow, movement of the catheter with required

patient care, and ongoing concern for thrombosis. Therefore, a recent study showed a shift in preference from LA vent insertion to balloon dilation alone [2]. However, balloon atrial septostomy alone is not always successful because of varying degrees of atrial septal thickness [9]. We believe that using an LA venting cannula after balloon dilation offers several advantages over balloon dilatation alone. First, the placement of an LA venting cannula potentially allows for controlled decompression of the left heart by adjusting flow rates on the ECMO circuit or clamping the cannula [5]. Second, this procedure minimizes the risk of transeptal communication closure. Third, the size of the cannula can be tailored to each patient, so this procedure can be adjusted for use in smaller patients.

For patients with left heart dysfunction causing pulmonary edema during VA ECMO, percutaneous balloon atrial septostomy with LA venting cannula insertion is a treatment option that carries a low risk of other complications such as bleeding.

CONFLICT OF INTEREST

No potential conflict of interest relevant to this article was reported.

REFERENCES

1. Kotani Y, Chetan D, Rodrigues W, et al. *Left atrial decom-*

- pression during venoarterial extracorporeal membrane oxygenation for left ventricular failure in children: current strategy and clinical outcomes.* *Artif Organs* 2013;37:29-36.
2. Eastaugh LJ, Thiagarajan RR, Darst JR, McElhinney DB, Lock JE, Marshall AC. *Percutaneous left atrial decompression in patients supported with extracorporeal membrane oxygenation for cardiac disease.* *Pediatr Crit Care Med* 2015;16:59-65.
 3. Thourani VH, Kirshbom PM, Kanter KR, et al. *Venoarterial extracorporeal membrane oxygenation (VA-ECMO) in pediatric cardiac support.* *Ann Thorac Surg* 2006;82:138-44.
 4. Ward KE, Tuggle DW, Gessouroun MR, Overholt ED, Mantor PC. *Transseptal decompression of the left heart during ECMO for severe myocarditis.* *Ann Thorac Surg* 1995;59:749-51.
 5. Hlavacek AM, Atz AM, Bradley SM, Bandisode VM. *Left atrial decompression by percutaneous cannula placement while on extracorporeal membrane oxygenation.* *J Thorac Cardiovasc Surg* 2005;130:595-6.
 6. Cheung MM, Goldman AP, Shekerdeman LS, Brown KL, Cohen GA, Redington AN. *Percutaneous left ventricular "vent" insertion for left heart decompression during extracorporeal membrane oxygenation.* *Pediatr Crit Care Med* 2003;4:447-9.
 7. Fouilloux V, Lebrun L, Mace L, Kreitmann B. *Extracorporeal membranous oxygenation and left atrial decompression: a fast and minimally invasive approach.* *Ann Thorac Surg* 2011;91:1996-7.
 8. Seib PM, Faulkner SC, Erickson CC, et al. *Blade and balloon atrial septostomy for left heart decompression in patients with severe ventricular dysfunction on extracorporeal membrane oxygenation.* *Catheter Cardiovasc Interv* 1999;46:179-86.
 9. Thanopoulos BD, Georgakopoulos D, Tsaousis GS, Simeunovic S. *Percutaneous balloon dilatation of the atrial septum: immediate and midterm results.* *Heart* 1996;76:502-6.