

## ORIGINAL ARTICLE

# Targeted exome sequencing resolves allelic and the genetic heterogeneity in the genetic diagnosis of nephronophthisis-related ciliopathy

Hee Gyung Kang<sup>1,12</sup>, Hyun Kyung Lee<sup>1,12</sup>, Yo Han Ahn<sup>1</sup>, Je-Gun Joung<sup>2</sup>, Jaeyong Nam<sup>2</sup>, Nayoung KD Kim<sup>2</sup>, Jung Min Ko<sup>1</sup>, Min Hyun Cho<sup>3</sup>, Jae Il Shin<sup>4</sup>, Joon Kim<sup>5</sup>, Hye Won Park<sup>6</sup>, Young Seo Park<sup>7</sup>, Il-Soo Ha<sup>1</sup>, Woo Yeong Chung<sup>8</sup>, Dae-Yeol Lee<sup>9</sup>, Su Young Kim<sup>10</sup>, Woong Yang Park<sup>2,11</sup> and Hae Il Cheong<sup>1</sup>

Nephronophthisis-related ciliopathy (NPHP-RC) is a common genetic cause of end-stage renal failure during childhood and adolescence and exhibits an autosomal recessive pattern of inheritance. Genetic diagnosis is quite limited owing to genetic heterogeneity in NPHP-RC. We designed a novel approach involving the step-wise screening of Sanger sequencing and targeted exome sequencing for the genetic diagnosis of 55 patients with NPHP-RC. First, five NPHP-RC genes were analyzed by Sanger sequencing in phenotypically classified patients. Known pathogenic mutations were identified in 12 patients (21.8%); homozygous deletions of *NPHP1* in 4 juvenile nephronophthisis patients, *IQCB1/NPHP5* mutations in 3 Senior-Løken syndrome patients, a *CEP290/NPHP6* mutation in 1 Joubert syndrome patient, and *TMEM67/MKS3* mutations in 4 Joubert syndrome patients with liver involvement. In the remaining undiagnosed patients, we applied targeted exome sequencing of 34 ciliopathy-related genes to detect known pathogenic mutations in 7 (16.3%) of 43 patients. Another 18 likely damaging heterozygous variants were identified in 13 NPHP-RC genes in 18 patients. In this study, we report a variety of pathogenic and candidate mutations identified in 55 patients with NPHP-RC in Korea using a step-wise application of two genetic tests. These results support the clinical utility of targeted exome sequencing to resolve the issue of allelic and genetic heterogeneity in NPHP-RC. *Experimental & Molecular Medicine* (2016) 48, e251; doi:10.1038/emm.2016.63; published online 5 August 2016

## INTRODUCTION

Nephronophthisis (NPHP) should be included in the differential diagnosis of children or adolescents presenting with chronic renal failure (CRF) of unknown etiology, because NPHP is the most common (accounting for ~3%) monogenic autosomal recessive cause of CRF in this age group.<sup>1–3</sup> NPHP is clinically characterized by anemia and growth retardation due to impaired renal function as well as polyuria/nocturia and polydipsia due to decreased renal concentrating ability.

Urinalysis often appears normal,<sup>4</sup> and blood pressure is typically not high. Commonly, ultrasonography reveals normal-sized or relatively small kidneys that are distinctive from autosomal recessive or autosomal dominant polycystic kidney disease (ARPKD or ADPKD)<sup>5</sup> and lack corticomedullary differentiation. NPHP is often accompanied by defects in other organs and tissues, for example, the retina, cerebellum and liver, such as in Joubert syndrome, Senior-Løken syndrome and Meckel-Gruber syndrome (MKS). A collective

<sup>1</sup>Department of Pediatrics, Seoul National University Children's Hospital, Seoul, Republic of Korea; <sup>2</sup>Samsung Genome Institute, Samsung Medical Center, Seoul, Republic of Korea; <sup>3</sup>Department of Pediatrics, Kyungpook National University School of Medicine, Daegu, Republic of Korea; <sup>4</sup>Department of Pediatrics, Yonsei University College of Medicine, Seoul, Republic of Korea; <sup>5</sup>Graduate School of Medical Science and Engineering, Korea Advanced Institute of Science and Technology, Daejeon, Republic of Korea; <sup>6</sup>Department of Pediatrics, Seoul National University Bundang Hospital, Seongnam, Republic of Korea; <sup>7</sup>Department of Pediatrics, Asian Medical Center, University of Ulsan College of Medicine, Seoul, Republic of Korea; <sup>8</sup>Department of Pediatrics, College of Medicine, Inje University, Busan Paik Hospital, Busan, Republic of Korea; <sup>9</sup>Department of Pediatrics, College of Medicine, Chonbuk National University, Jeonju, Republic of Korea; <sup>10</sup>Department of Pediatrics, Pusan National University Children's Hospital, Pusan, Republic of Korea and <sup>11</sup>Department of Molecular Cell Biology, Sungkyunkwan University School of Medicine, Suwon, Republic of Korea

<sup>12</sup>These authors contributed equally to this work.

Correspondence: Professor W-Y Park, Samsung Genome Institute, Samsung Medical Center, Seoul 135-710, Republic of Korea.

E-mail: woonyang@skku.edu

or Professor HI Cheong, Department of Pediatrics, Seoul National University Children's Hospital, Seoul 110-744, Republic of Korea.

E-mail: cheonghi@snu.ac.kr

Received 13 September 2015; revised 29 February 2016; accepted 11 March 2016

term, NPHP-related ciliopathy (NPHP-RC), is used to describe this group of diseases, because most of the causative genes in these disorders encode proteins that have a role in the cilium.<sup>6–8</sup>

A genetic diagnosis is required for a definitive diagnosis of NPHP-RC, because the clinical features of patients with NPHP-RC are rather non-specific, and their symptoms overlap significantly.<sup>8</sup> The most common genetic cause of NPHP is a large deletion of *NPHP1*,<sup>9–11</sup> which is noted in >20% of patients with NPHP, whereas other genes contribute less than 2–3%.<sup>7</sup> Sanger sequencing of commonly mutated NPHP genes detects mutations in less than one-third of patients.<sup>8</sup> In addition, the number of NPHP-RC-related genes has been rapidly increasing, with 20 genes having NPHP as part of their gene name at the time of writing, especially after the introduction of next-generation sequencing (NGS) techniques.<sup>12–14</sup> Therefore, the genetic diagnosis of NPHP-RC based on an ‘educated guess at the best candidate gene’ is now changing to adopting high-throughput genome analysis techniques. Through NGS screening of known and candidate genes, a genetic diagnosis can be obtained efficiently in more patients, and novel causative genes can be identified. However, this technology is still evolving, and it is relatively costly and requires advanced bioinformatics support for handling large quantities of data. Therefore, the combination of both traditional Sanger sequencing and NGS might be more practical in obtaining a genetic diagnosis of NPHP-RC or other genetically heterogeneous groups of disorders.

We report here the use of a stratified two-step procedure of Sanger sequencing of selected genes followed by targeted exome sequencing of 34 disease-related genes, which led to a genetic diagnosis for 19 (34.5%) of our cohort of 55 Korean patients with NPHP-RC clinical diagnoses.

## MATERIALS AND METHODS

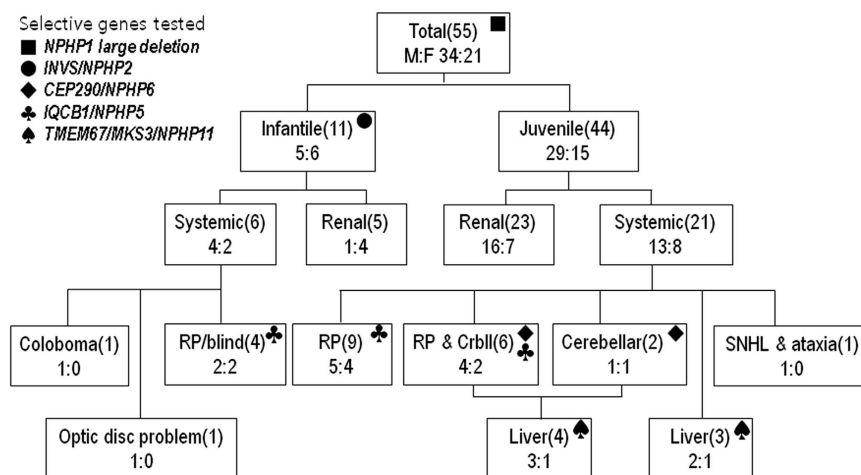
### Study population

This study was approved by the independent review board of Seoul National University Hospital (H-0812-002-264), and only those patients who provided written informed consent were screened and included in this study. Patients who were clinically diagnosed with NPHP were included.<sup>15</sup> Presentation with incidentally identified CRF in the first three decades of life without evidence of previous renal damage was typical. Other causes of CRF were excluded by past medical history and imaging of the urinary tract in the majority of the cases. Patients with a clinical diagnosis of ADPKD were excluded. One patient (J-86) was included owing to typical findings of Joubert syndrome (cerebellar vermis aplasia, Leber congenital amaurosis and mental retardation) without renal involvement. We performed fundus examinations and abdominal sonography to evaluate the intra-abdominal organs. Renal ultrasonographic findings of increased echogenicity (normal or slightly decreased size for age) and cortico-medullary differentiation loss were considered to be typical for NPHP-RC.<sup>5</sup> For those individuals with developmental delay and neurological problems, we requested brain imaging. For some patients ( $n=15$ ), renal pathology was also obtained, which exhibited typical findings of chronic tubular interstitial disease. This study adheres to the Declaration of Helsinki.

The patients were classified according to their age at the time of end-stage renal disease as infantile when younger than 5 years old ( $n=11$ ) and juvenile when older ( $n=44$ ). Combinations of NPHP with cerebellar vermis hypoplasia or aplasia were designated as Joubert syndrome ( $n=8$ ). Retinal involvement with retinitis pigmentosa (RP) or Leber’s congenital amaurosis was designated as Senior–Løken syndrome ( $n=13$ ), and those patients with multiple problems without cerebellar hypo/aplasia were designated as MKS-like ( $n=3$ ).

### Sanger sequencing

The most probable candidate genes were selected for Sanger sequencing based on known mutation frequencies and specific clinical phenotypes (Figure 1). Peripheral blood mononuclear cells were collected from the patients, and genomic DNA was obtained using a



**Figure 1** Strategy for Sanger sequencing. All of the patients were screened for complete deletions of *NPHP1*, which is the most common mutation in NPHP. Among those without complete *NPHP1* deletion, infant NPHP patients were tested for *INVS/NPHP2* mutations. *IQCB1/NPHP5*, *CEP290/NPHP6*, and *TMEM67/MKS3/NPHP11* were tested according to the phenotypes of the patients. CrblI, cerebellar; F, female; M, male; NPHP, nephronophthisis; RP, retinitis pigmentosa; SNHL, sensory neural hearing loss.

QIA amp DNA Blood Mini Kit (Qiagen, Hilden, Germany). All of the patients ( $n=55$ ) were screened for large deletions of *NPHP1*, which is the most common mutation in NPHP, by amplifying each of the exons using PCR; a failure of amplification was considered to be a total homozygous deletion of the *NPHP1* gene.<sup>10,16</sup> Among those patients without large deletions of *NPHP1*, infantile NPHP patients were tested for *INVS/NPHP2* mutations ( $n=11$ ).<sup>17</sup> The selection of genes according to phenotype was as follows: *IQCB1/NPHP5* for RP ( $n=19$ );<sup>18</sup> *CEP290/NPHP6* for Joubert syndrome ( $n=8$ );<sup>19</sup> and *TMEM67/MKS3* for hepatic fibrosis ( $n=7$ ).<sup>20,21</sup>

### Targeted exome sequencing

We designed customized targeted exome capture using a SeqCap EZ kit (Roche NimbleGen, Madison, WI, USA) for 34 genes related to NPHP-RC, Bardet-Biedl syndrome and ARPKD (Supplementary Table S1). After capturing the target sequences, the DNA libraries were amplified and sequenced using Illumina HiSeq2000 (Illumina, San Diego, CA, USA).

### Alignment, coverage calculation and variant detection

Reads were aligned to the UCSC hg19 reference genome using BWA-0.6.1 with default settings<sup>22</sup> for single-nucleotide variation (SNV)/insertion and deletion (indel) detection, and duplicate reads were removed. Variants were identified using Unified Genotyper in GATK-1.3.<sup>23</sup> A Perl script and Annovar were used to annotate variants and search the known SNPs and indels from dbSNP v135 and the 1000 Genomes project data (drafted February 2012). Coverage and depth were calculated using the GATK DepthOfCoverage analysis. The significance of variants was assessed *in silico* using MutationTaster, PolyPhen-2, SIFT and FATHMM. Those variants predicted to be disease causing or not tolerated by two or more programs were considered to be pathogenic mutations.<sup>24–27</sup> Conservation scores (Phylo-P) for each mutated nucleotide were also considered.<sup>28</sup> Prediction of alternative splicing by intronic variation was performed using NetGene2 (<http://www.cbs.dtu.dk/services/NetGene2/>), Ex-skip (<http://ex-skip.img.cas.cz/>), and BDGP acceptor site prediction ([http://www.fruitfly.org/seq\\_tools/other.html](http://www.fruitfly.org/seq_tools/other.html)).

Variant calls were obtained using the following filter parameter: minimum base quality of 17 (the default value for the GATK Unified Genotyper). A minimum variant count of 10 was applied for potential truncating mutations (nonsense, frameshift and obligatory splice-site mutations), and non-synonymous missense variants were filtered by a minimum count of 3. Synonymous variants and common dbSNP (v135) variants with a population allele frequency >1% were excluded.

All of the candidate mutations were validated by Sanger sequencing. When available, we verified their co-segregation in the family (J-61 and J-50).

## RESULTS

### Clinical features of NPHP-RC patients

We recruited 55 unrelated Korean patients with a clinical diagnosis of NPHP (M:F=34:21) who were referred to our laboratory for genetic diagnosis (Supplementary Table S1). The mean age of the patients at end-stage renal disease was  $9.0 \pm 5.1$  years old (median, 8.3 years; range, 0.6–17.9 years). Renal histology from 15 patients exhibited typical findings of tubulointerstitial nephropathy. Nineteen patients (34%) had eye involvement of RP or Leber's congenital amaurosis, eight

patients (14.5%) had a molar tooth sign in the brainstem on brain imaging and seven patients (12.7%) exhibited hepatic fibrosis. Eight patients (14.5%) had siblings with similar symptoms; however, none of their parents had CRF.

### First step: Sanger sequencing for genetic diagnosis

As a first step in the stratified approach to determine a genetic diagnosis of NPHP, we selected and screened the patients by Sanger sequencing for candidate genes (Figure 1). A homozygous deletion of *NPHP1* was detected in four patients (7.3% (confidence interval (CI, 95%) 0.4–14.2%), and 17% of patients exhibited juvenile isolated NPHP without other organ involvement ( $n=23$ ); Table 1, in bold). Three (15.8%) of 19 NPHP patients with RP or Leber's congenital amaurosis (Senior-Løken syndrome, marked with ♣ in Figure 1) carried a common pathogenic homozygous mutation (c.1522\_1523dupGA, p.Ala509Lysfs\*3) in the *IQCB1/NPHP5* genes.<sup>29</sup> In screening NPHP patients with cerebellar vermis hypotrophy/atrophy involvement ( $n=8$ , marked with ♦ in Figure 1), one familial case of Joubert syndrome had a compound heterozygous mutation in *CEP290/NPHP6*, a known pathogenic c.1666delA, p.Ile556Phefs\*17,<sup>30</sup> and an SNV (c.6011-12T>A) that is predicted to cause alternative splicing.<sup>31</sup> Four of seven NPHP patients with hepatic fibrosis (marked with ♣ in Figure 1) carried compound heterozygous mutations in *TMEM67/MKS3/JBSTS6*, a frameshift, truncating mutation and an SNV.<sup>32–34</sup> All four of these patients had Joubert syndrome and congenital hepatic fibrosis compatible with COACH (cerebellar vermis hypoplasia/aplasia, oligophrenia, congenital ataxia, ocular coloboma and hepatic fibrosis) syndrome.<sup>35</sup> In total, Sanger sequencing detected genetic aberrations in 12 patients (21.8%) with a clinical diagnosis of NPHP-RC.

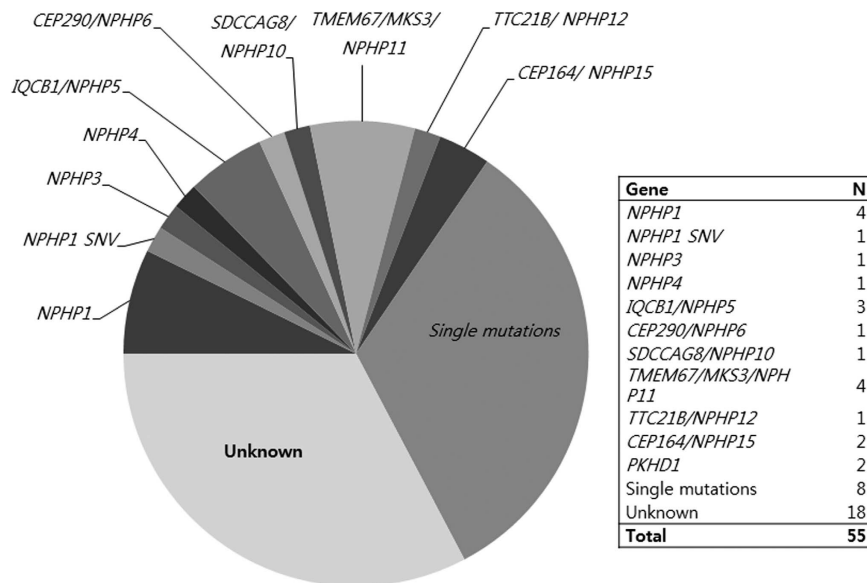
### Second step: Targeted exome sequencing in patients with NPHP-RC

Targeted exome sequencing of 34 NPHP-RC-related genes was applied in 43 patients in whom a genetic diagnosis was not obtained by our first step of Sanger sequencing. We obtained an average 21.8 Mb of mapped data per individual for ~166 kb of targeting and flanking regions (Supplementary Table S2). The mean read depth was  $131 \pm 55$  and 95.4% of the captured target exons exhibited >10-fold coverage. Most likely azpathogenic mutations of various types were identified in 7 of 43 cases (16%) in six genes, including *NPHP1*, *NPHP3*, *NPHP4*, *SDCCAG8/NPHP10*, *TTC21B/NPHP12* and *PKHD1* (Figure 2). In three cases (K-8, J-84, K-9, Table 2), a heterozygous known pathogenic mutation in *BBS4* was identified that could not explain the genetic pathogenesis but might explain a mild phenotype resembling BBS, as previously reported.<sup>36,37</sup> Heterozygous potentially damaging mutations/ variations in at least one of the target NPHP-RC genes were identified in additional 15 patients, including one truncating mutation of *NPHP3* in two patients with isolated juvenile NPHP. In the remaining 18 patients, no significant variations of the target genes were identified. In total, we identified most

**Table 1 Pathogenic mutations found in Korean NPHP-RC patients by Sanger sequencing and targeted exome sequencing**

Patient	ESRD (yrs)	Extra-renal manifestations	Gene	Nucleotide change	Amino acid change	1000 genomes	Phylo-P	Mutation Taster	Poly-phen2	SIFT	FATHMM	Ref.
K-1	8.1	RD	<i>NPHP1</i>	Total deletion (Hom)	-	-	-	-	-	-	-	8-10
J-57	13.0	RD, nystagmus										
J-104	14.0	RD										
J-92	CKD	Myopia										
O-508	17.9	Congenital cataract	<i>IQCB1/NPHP5</i>	<b>c.1522_1523 dupGA (Hom)</b>	p.Ala509Lysfs*3	-	-	-	-	-	-	28
K-2	11.0	RD, LCA, nystagmus										
K-3	10.8	RD, LCA										
J-86	NA	LCA, cataract, CVA, MR	<i>CEP290/NPHP6</i>	<b>c.1666delA</b>	p.Ile556Phefs*17	-	-	-	-	-	-	29
K-4	11.8	Apraxia, MR, CVA, Caroli, choledochoal cyst	<i>TMEM67/MKS3/NPHP11</i>	<b>c.6012-12A&gt;T</b> <b>c.725A&gt;G</b> <b>c.2758delT</b>	alt. splicing p.Asn242Ser p.Tyr920Thrfs*40	-	-	DC	DC	DC	DC	30
J-63	6.0	OMA, ONA, CVA, MR, HF, choledochoal cyst		<b>c.274G&gt;A</b> <b>c.579_580delAG</b>	p.Gly92Arg p. Gly195Ilefs*13	-	-	DC	DC	DC	DC	31
J-55	6.8	RD, CVA, MR, CP, HF		<b>c.274G&gt;A</b> <b>c.1353delA</b>	p.Gly92Arg p.Glu452Lysfs*4	-	-	DC	DC	DC	DC	32
J-61	14.4	ONA, RD, CVP, MR, HF, choledochoal cyst		<b>c.1353delA</b> <b>c.2096T&gt;C</b>	p.Glu452Lysfs*4 p.Leu699Ser	-	-	DC	DC	DC	DC	31
J-39	12.7	RD, nystagmus	<i>NPHP1</i>	Total deletion c.609_610insC	p.Arg204Glnfs*8	-	-	DC	DC	DC	DC	8-10
J-4	16.7	Elliptocytosis	<i>NPHP3</i>	c.1597G>C c.3757C>G	p.Gly533Arg p.Leu1253Val	-	-	DC	DC	DC	DC	46
K-5	2.5	ONA	<i>NPHP4</i>	c.2260G>A (Hom)	p.Gly754Arg	-	-	DC	DC	DC	DC	
J-50	14	Amblyopia, strabismus, LCA	<i>SDCCAG8/NPHP10</i>	c.845_848delITTTG c.1300delA	p.Cys283fs*1 p.Asn434Ilefs*28	-	-	DC	DC	DC	DC	
J-10	15.6	None	<i>TTC21B/NPHP12</i>	c.379G>A	p.Ala127Thr	-	-	DC	DC	DC	DC	
K-7	12.9	ONA	<i>PKHD1</i>	c.2572C>T c.1690C>T c.1756T>G	p.Arg858* p.Arg564* p.Phe586Val	-	-	DC	DC	DC	DC	47
O-463	CKD	Caroli disease		c.2507T>C c.11611T>C	p.Val836Ala p.Trp3871Arg	-	-	DC	DC	DC	DC	48

Abbreviations: CP, cerebellar palsy; CVA, cerebellar vermis aplasia; CVP, cerebellar vermis hypoplasia; D, damaging; DC, disease causing; DD, developmental delay; ESRD, end-stage renal disease; Het, heterozygous mutation; HF, hepatic fibrosis; Hom, homozygous mutation; LCA, leber congenital amaurosis; MR, mental retardation; NA, not applicable; NT, not tolerated; NPHP-RC, Nephronophthisis-related ciliopathy; OMA, oculomotor apraxia; ONA, optic nerve anomaly; PD, probably damaging; PoD, possibly damaging; RD, retinal dystrophy; T, tolerated; SNV, single-nucleotide variation; yrs, years.  
For novel mutations, the significance was assessed *in silico* using MutationTaster, PolyPhen-2, SIFT and FATHMM, in addition to conservation score Phylo-P. For known mutations, references were noted.



**Figure 2** Results of genetic diagnosis for NPHP-RC. One-third ( $n=19$ ; 34.5%) of the patients with clinical diagnoses of NPHP-RC obtained a genetic diagnosis by two-step genetic diagnosis using Sanger sequencing ( $n=12$ , 21.8%) and targeted exome sequencing ( $n=7$ ; 12.7%). Four patients with homozygous total deletion of *NPHP1*, three with *IQCB1/NPHP5*, one with *CEP290/NPHP6*, and four with *TMEM67/MKS3/NPH11* were detected using Sanger sequencing. Mutations of other genes were detected using targeted exome sequencing. In addition, heterozygous mutations in NPHP-RC genes were detected in 13 patients (23.6%). NPHP-RC, nephronophthisis-related ciliopathy.

likely pathogenic mutations in nine NPHP-RC-related genes in 19 (34.5%) of 55 Asian NPHP-RC patients using a two-step genetic diagnosis (Figure 2), where the frequency of homozygous deletion of *NPHP1* is relatively low (7.3%, CI 0.4–14.2).

## DISCUSSION

The genetic causes of several Mendelian diseases, such as NPHP-RC, RP, and non-syndromic hearing loss, are heterogeneous. For these diseases, providing a precise diagnosis is often difficult until pathogenic mutations are identified. In the present study, we obtained a genetic diagnosis in one-third of patients with a clinical diagnosis of NPHP-RC with a two-step genetic diagnosis using Sanger sequencing followed by high-throughput mutation analysis using NGS after a custom DNA-capture procedure. For two patients (K-7 and O-463), mutation analysis led to correction of their diagnoses from NPHP to ARPKD. Patients with ARPKD may have normal-sized kidneys and therefore may be misdiagnosed with NPHP, as shown here. In addition, additional heterozygous mutations were identified in candidate genes from NGS (data not shown), implying that further study of the respective genes or other closely related genes would enhance the efficacy of genetic diagnosis of NPHP-RC. For the definitive genetic diagnosis of NPHP-RC patients, extensive analysis of trio or family studies of NPHP-RC will be followed to understand the penetrance of genetic alterations and recurrence in additional patients. Systemic functional studies on the variant proteins will also be required to understand the effects of genetic alterations.

Traditionally, genetic diagnosis has been obtained by Sanger sequencing of the best candidate genes based on disease phenotype and frequency. The same approach was applied

for our NPHP-RC patients as our first step, and 22% of the patients were given genetic diagnosis with a fair genotype–phenotype correlation. All three patients with congenital blindness due to Leber’s congenital amaurosis were shown to have an identical homozygous indel mutation in *IQCB1/NPHP5* (5.5% (CI 0–11.5%) of the total population), suggesting a founder effect. Four patients with Joubert syndrome, RP, hepatic fibrosis and developmental delay were found to have *TMEM67/MKS3/JBSTS6* mutations (7.3% (CI 0.4–11.5%) of the total population). These four patients had a similar appearance to each other, with rectangular faces, square jaws, and amiable natures despite mental retardation. Another interesting finding at this step was that the proportion of *NPHP1* mutations in these patients was relatively lower than reported.<sup>7,8,12</sup> It is not clear whether this difference reflects ethnic characteristics of the study populations or is simply derived from a selection bias of this study given the small number of participants. Nonetheless, a majority of the patients were not given a definitive diagnosis, similar to that reported in the literature.<sup>7,8,12,38</sup> Those with an atypical phenotype would have been misclassified in this step, and their causative genes would not have been assessed. Therefore, we introduced NGS technology as our second step.

For better cost-effectiveness, we chose targeted exome sequencing (TES) instead of whole-genome sequencing or whole-exome sequencing. TES for disease-related genes with high read depth enables multiplex screening of candidate genes.<sup>38</sup> In addition to a well-defined set of known NPHP-RC genes known at the time of study design, we included an extended set of cilia-related genes in our TES (Supplementary Table S2), including ARPKD and genes of interest to the

Table 2 Probably pathogenic variants in NPHP-RC patients

Patient	ESRD (yrs)	Extra-renal manifestations	Gene	Nucleotide change	Amino acid change	1000 genomes	Phylo-P	Mutation Taster	Mutation phen2	SIFT	FATHMM	Ref.
J-6	9.9		<i>NPHP1</i>	c.2029G>C	p.Glu677Gln	-	3.269	DC	PD	D	T	
J-12	1.9		<i>INVS/NPHP2</i>	c.721A>T	p.Thr241Ser	-	5.055	DC	PD	D	T	
HNF-38	16.7		<i>NPHP3</i>	c.2852G>A	p.Arg951Gln	-	4.573	DC	PD	T	D	
J-46	3.1			c.424C>T	p.Arg142*		5.688	DC				
J-83	8.4			c.424C>T	p.Arg142*		5.688	DC				
J-35	7.4		<i>CEP290/NPHP6</i>	c.5237G>A	p.Arg1746Gln	0.0032	3.28	DC	PoD	T	T	
J-79	CKD		<i>GLIS2/NPHP7</i>	c.53G>A	p.Arg18Gln	-	3.183	DC	PD	D	T	50
J-14	0.6		<i>AHI1/JBTS3</i>	c.3257A>G	p.Glu1086Gly							51
K-8	3.2	ONA,ADHD, AR	<i>BBS4</i>	c.1548_1549del	p.516_517del							35
J-84	5.5	LCA, MR, HF		c.1414A>G	p.Met472Val							35
K-9	5.2			c.1414A>G	p.Met472Val		35					
J-59	11.8	strabismus, CVA, DD, Sz	<i>MKKS/BBS6</i>	c.416G>A	p.Arg139Gln	0.0018	1.875	DC	PD	T	T	
K-10	3	RD, HF	<i>ARL13B/JBTS8</i>	c.259A>G	p.Ile87Val	0.0018	4.762	DC	PD	T	T	
K-11	CKD	Cholechochal cyst, HF, Caroli	<i>CC2D2A/JBTS9/</i>	c.4202C>G	p.Thr1401Ser	0.0041	5.88	DC	PD	T	T	
K-12	CKD		<i>MKS6</i>	c.4238G>A	p.Cys1413Tyr	0.0014	5.725	DC	PD	T	T	
J-60	1.2	OMA, ONA, CVA, DD, HF, chole- dochal cyst	<i>TRIM32/BBS11</i>	c.467T>C	p.Leu156Pro	-	4.635	DC	PD	D	T	
J-102	6.5	LCA, MR, brain atrophy, Caroli disease	<i>C5orf42/JBTS17</i>	c.8539G>A	p.Asp2847Asn	-	3.608	DC	PD	T	T	
K-6	12.0	RD	<i>PKHD1</i>	c.9629C>G	p.Ser3210Cys	0.0037	2.488	DC	PD	T	D	

Abbreviations: AR, aortic regurgitation; ADHD, attention deficit and hyperactivity disorder; CVA, cerebellar vermis aplasia; D, damaging; DC, disease causing; DD, developmental delay; ESRD, end-stage renal disease; HA, hemolytic anemia; HF, hepatic fibrosis; MR, mental retardation; NA, not applicable; NPHP-RC, nephronophthisis-related ciliopathy; NT, not tolerated; OMA, oculomotor apraxia; ONA, optic nerve anomaly; PD, probably damaging; PoD, possibly damaging; RD, retinal dystrophy; SNV, single-nucleotide variation; Sz, seizure; T, tolerated; yrs, years.

authors. Among the variants detected in our second step of genetic diagnosis, only those that might explain the phenotype were selected as the most likely pathogenic mutations ( $n = 13$ , Table 2); four known pathogenic mutations, five frameshift or truncating mutations and four missense mutations were predicted to be damaging. The possibility of large deletions or duplications was also considered, and total deletion of one *NPHP1* allele was detected in one patient (J-39) in whom the other *NPHP1* allele exhibited a heterozygous frame shift mutation. Other than this case (J-39), no genetic diagnosis was made involving the five genes selected for our first step. Given that those with known genetic defects were excluded at this second step, the efficiency of TES could not be assessed. Overall, this second step of genetic diagnosis mapped genetic aberrations in known NPHP-RC genes or *PKHD1* in 16% (7 of 43) of the patients. Our results reflect a similar mutation-detection rate to that reported by Halbritter *et al.*<sup>38</sup>, where a molecular diagnosis was obtained in 12% of patients using high-throughput mutation screening of 13 NPHP genes in a large population of NPHP-RC patients.

This study has several shortcomings. The number of the patients is small compared with previous reports,<sup>38,39</sup> and segregation analysis was not available in the majority of the cases due to the inability to obtain a sample from the parents. In addition, functional studies of 'most likely pathogenic' novel mutations have not been performed to date. In addition, given that the coverage of TES of this study was not perfect (Supplementary Table S3), a second mutation might not be sequenced, thus warranting Sanger sequencing of the respective genes with single candidate variants. Unfortunately, further analysis was not possible in this study because those with single variants were lost to follow-up. Above all, the set of genes used for TES reflects our knowledge at the time of study design; therefore, newly discovered genes, such as *ZNF423*,<sup>40</sup> *WDR19*,<sup>41</sup> *ANKS6*,<sup>42</sup> *IFT172*,<sup>43</sup> *CEP83* (ref. 44) and *DCDC2*,<sup>45</sup> were not included. On the basis of this study, we are currently developing our next set of TES by incorporating the recent discovery of NPHP-RC. Improvements in NSG technology are expected to increase the rate of genetic diagnosis.

Although the number of patients of this study was not sufficiently large to determine the distribution of genetic aberration types and loci, this finding helps to delineate the characteristics of Korean or Asian NPHP, which enables a more efficient genetic diagnosis of NPHP-RC in this population. On the basis of this study, we are currently assessing the genetic aberrations of our NPHP-RC patients as follows. Gel electrophoresis of PCR products of *NPHP1* is performed as the first step (step 1), and then one or two particular mutations or genes are analyzed if the patient has distinctive extra-renal findings, such as congenital blindness with c.1523\_1524insGA of *IQCB1/NPHP5* or COACH syndrome with a *TMEM67/MKS3/JBTS6* mutation (step 2). If genetic diagnosis is not obtained with these first two steps, then the TES steps in (step 3) might be replaced by whole-exome sequencing or whole-genome sequencing in the near future. With expanding collective knowledge and rapidly evolving technology, both

steps 2 and 3 are expected to simultaneously become more diverse and more precise, thus yielding a better genetic diagnosis of NPHP-RC.

## CONFLICT OF INTEREST

The authors declare no conflict of interest.

## ACKNOWLEDGEMENTS

This study was supported by a grant (HI12C0014) from the Korea Healthcare Technology R&D Project, Ministry for Health and Welfare, Republic of Korea.

- 1 Steele BT, Lirenman DS, Beattie CW. Nephronophthisis. *Am J Med* 1980; **68**: 531–538.
- 2 Avner ED, Harmon WE, Niaudet P, Yoshikawa N, Emma F, Goldstein SL. *Pediatric nephrology*. Springer: Heidelberg, Germany, 2016.
- 3 Hamiwka LA, Midgley JP, Wade AW, Martz KL, Grisaru S. Outcomes of kidney transplantation in children with nephronophthisis: an analysis of the North American Pediatric Renal Trials and Collaborative Studies (NAPRTCS) Registry. *Pediatr Transplant* 2008; **12**: 878–882.
- 4 Hirano D, Fujinaga S, Ohtomo Y, Nishizaki N, Hara S, Murakami H *et al*. Nephronophthisis cannot be detected by urinary screening program. *Clin Pediatr (Phila)* 2012; **52**: 759–761.
- 5 Blowey DL, Querfeld U, Geary D, Warady BA, Alon U. Ultrasound findings in juvenile nephronophthisis. *Pediatr Nephrol* 1996; **10**: 22–24.
- 6 Hildebrandt F, Otto E. Cilia and centrosomes: a unifying pathogenic concept for cystic kidney disease? *Nat Rev Genet* 2005; **6**: 928–940.
- 7 Chaki M, Hoefele J, Allen SJ, Ramaswami G, Janssen S, Bergmann C *et al*. Genotype-phenotype correlation in 440 patients with NPHP-related ciliopathies. *Kidney Int* 2011; **80**: 1239–1245.
- 8 Hildebrandt F, Attanasio M, Otto E. Nephronophthisis: disease mechanisms of a ciliopathy. *J Am Soc Nephrol* 2009; **20**: 23–35.
- 9 Nothwang HG, Stubanus M, Adolphs J, Hanusch H, Vossmerbaumer U, Denich D *et al*. Construction of a gene map of the nephronophthisis type 1 (NPHP1) region on human chromosome 2q12-q13. *Genomics* 1998; **47**: 276–285.
- 10 Hildebrandt F, Otto E, Rensing C, Nothwang HG, Vollmer M, Adolphs J *et al*. A novel gene encoding an SH3 domain protein is mutated in nephronophthisis type 1. *Nat Genet* 1997; **17**: 149–153.
- 11 Soliman NA, Hildebrandt F, Otto EA, Nabhan MM, Allen SJ, Badr AM *et al*. Clinical characterization and NPHP1 mutations in nephronophthisis and associated ciliopathies: a single center experience. *Saudi J Kidney Dis Transpl* 2012; **23**: 1090–1098.
- 12 Sang L, Miller JJ, Corbit KC, Giles RH, Brauer MJ, Otto EA *et al*. Mapping the NPHP-JBTS-MKS protein network reveals ciliopathy disease genes and pathways. *Cell* 2011; **145**: 513–528.
- 13 Otto EA, Hurd TW, Airik R, Chaki M, Zhou W, Stoetzel C *et al*. Candidate exome capture identifies mutation of *SDCCAG8* as the cause of a retinal-renal ciliopathy. *Nat Genet* 2010; **42**: 840–850.
- 14 Wolf MT. Nephronophthisis and related syndromes. *Curr Opin Pediatr* 2015; **27**: 201–211.
- 15 Hildebrandt F, Strahm B, Nothwang HG, Gretz N, Schnieders B, Singh-Sawhney I *et al*. Molecular genetic identification of families with juvenile nephronophthisis type 1: rate of progression to renal failure. *Kidney Int* 1997; **51**: 261–269.
- 16 Al-Romaih KI, Genovese G, Al-Mojalli H, Al-Othman S, Al-Manea H, Al-Suleiman M *et al*. Genetic diagnosis in consanguineous families with kidney disease by homozygosity mapping coupled with whole-exome sequencing. *Am J Kidney Dis* 2011; **58**: 186–195.
- 17 Otto EA, Schermer B, Obara T, O'Toole JF, Hiller KS, Mueller AM *et al*. Mutations in *INVS* encoding inversin cause nephronophthisis type 2, linking renal cystic disease to the function of primary cilia and left-right axis determination. *Nat Genet* 2003; **34**: 413–420.
- 18 Otto EA, Loeyes B, Khanna H, Hellemans J, Sudbrak R, Fan S *et al*. Nephrocystin-5, a ciliary IQ domain protein, is mutated in Senior-Loken syndrome and interacts with RPGR and calmodulin. *Nat Genet* 2005; **37**: 282–288.

- 19 Sayer JA, Otto EA, O'Toole JF, Nurnberg G, Kennedy MA, Becker C *et al*. The centrosomal protein nephrocystin-6 is mutated in Joubert syndrome and activates transcription factor ATF4. *Nat Genet* 2006; **38**: 674–681.
- 20 Baala L, Romano S, Khaddour R, Saunier S, Smith UM, Audollent S *et al*. The Meckel-Gruber syndrome gene, MKS3, is mutated in Joubert syndrome. *Am J Hum Genet* 2007; **80**: 186–194.
- 21 Otto EA, Tory K, Attanasio M, Zhou W, Chaki M, Paruchuri Y *et al*. Hypomorphic mutations in meckelin (MKS3/TMEM67) cause nephronophthisis with liver fibrosis (NPHP11). *J Med Genet* 2009; **46**: 663–670.
- 22 Min BJ, Kim N, Chung T, Kim OH, Nishimura G, Chung CY *et al*. Whole-exome sequencing identifies mutations of KIF22 in spondyloepimetaphyseal dysplasia with joint laxity, leptodactylic type. *Am J Hum Genet* 2011; **89**: 760–766.
- 23 McKenna A, Hanna M, Banks E, Sivachenko A, Cibulskis K, Kernysky A *et al*. The Genome Analysis Toolkit: a MapReduce framework for analyzing next-generation DNA sequencing data. *Genome Res* 2010; **20**: 1297–1303.
- 24 Shihab HA, Gough J, Cooper DN, Stenson PD, Barker GL, Edwards KJ *et al*. Predicting the functional, molecular, and phenotypic consequences of amino acid substitutions using hidden Markov models. *Hum Mutat* 2013; **34**: 57–65.
- 25 Adzhubei I, Jordan DM, Sunyaev SR. Predicting functional effect of human missense mutations using PolyPhen-2. *Curr Protoc Hum Genet* 2013; **7**: 20.
- 26 Kumar P, Henikoff S, Ng PC. Predicting the effects of coding non-synonymous variants on protein function using the SIFT algorithm. *Nat Protoc* 2009; **4**: 1073–1081.
- 27 Schwarz JM, Rodelsperger C, Schuelke M, Seelow D. MutationTaster evaluates disease-causing potential of sequence alterations. *Nat Methods* 2010; **7**: 575–576.
- 28 Gilissen C, Hoischen A, Brunner HG, Veltman JA. Disease gene identification strategies for exome sequencing. *Eur J Hum Genet* 2012; **20**: 490–497.
- 29 Estrada-Cuzcano A, Koenekoop RK, Coppieters F, Kohl S, Lopez I, Collin RW *et al*. IQCB1 mutations in patients with leber congenital amaurosis. *Invest Ophthalmol Vis Sci* 2011; **52**: 834–839.
- 30 Brancati F, Barrano G, Silhavy JL, Marsh SE, Travaglini L, Bielas SL *et al*. CEP290 mutations are frequently identified in the oculo-renal form of Joubert syndrome-related disorders. *Am J Hum Genet* 2007; **81**: 104–113.
- 31 Tsurusaki Y, Kobayashi Y, Hisano M, Ito S, Doi H, Nakashima M *et al*. The diagnostic utility of exome sequencing in Joubert syndrome and related disorders. *J Hum Genet* 2013; **58**: 113–115.
- 32 Szymanska K, Berry I, Logan CV, Cousins SR, Lindsay H, Jafri H *et al*. Founder mutations and genotype-phenotype correlations in Meckel-Gruber syndrome and associated ciliopathies. *Cilia* 2012; **1**: 18.
- 33 Brancati F, Iannicelli M, Travaglini L, Mazzotta A, Bertini E, Boltshauser E *et al*. MKS3/TMEM67 mutations are a major cause of COACH Syndrome, a Joubert Syndrome related disorder with liver involvement. *Hum Mutat* 2009; **30**: E432–E442.
- 34 Doherty D, Parisi MA, Finn LS, Gunay-Aygun M, Al-Mateen M, Bates D *et al*. Mutations in 3 genes (MKS3, CC2D2A and RPGRIP1L) cause COACH syndrome (Joubert syndrome with congenital hepatic fibrosis). *J Med Genet* 2010; **47**: 8–21.
- 35 Gentile M, Di Carlo A, Susca F, Gambotto A, Caruso ML, Panella C *et al*. COACH syndrome: report of two brothers with congenital hepatic fibrosis, cerebellar vermis hypoplasia, oligophrenia, ataxia, and mental retardation. *Am J Med Genet* 1996; **64**: 514–520.
- 36 Hoskins BE, Thorn A, Scambler PJ, Beales PL. Evaluation of multiplex capillary heteroduplex analysis: a rapid and sensitive mutation screening technique. *Hum Mutat* 2003; **22**: 151–157.
- 37 Karmous-Benaïly H, Martinovic J, Gubler MC, Sirot Y, Clech L, Ozilou C *et al*. Antenatal presentation of Bardet-Biedl syndrome may mimic Meckel syndrome. *Am J Hum Genet* 2005; **76**: 493–504.
- 38 Halbritter J, Porath JD, Diaz KA, Braun DA, Kohl S, Chaki M *et al*. Identification of 99 novel mutations in a worldwide cohort of 1,056 patients with a nephronophthisis-related ciliopathy. *Hum Genet* 2013; **132**: 865–884.
- 39 Halbritter J, Diaz K, Chaki M, Porath JD, TARRIER B, Fu C *et al*. High-throughput mutation analysis in patients with a nephronophthisis-associated ciliopathy applying multiplexed barcoded array-based PCR amplification and next-generation sequencing. *J Med Genet* 2012; **49**: 756–767.
- 40 Chaki M, Airik R, Ghosh AK, Giles RH, Chen R, Slaats GG *et al*. Exome capture reveals ZNF423 and CEP164 mutations, linking renal ciliopathies to DNA damage response signaling. *Cell* 2012; **150**: 533–548.
- 41 Bredrup C, Saunier S, Oud MM, Fiskerstrand T, Hoischen A, Brackman D *et al*. Ciliopathies with skeletal anomalies and renal insufficiency due to mutations in the IFT-A gene WDR19. *Am J Hum Genet* 2011; **89**: 634–643.
- 42 Hoff S, Halbritter J, Epting D, Frank V, Nguyen TM, van Reeuwijk J *et al*. ANKS6 is a central component of a nephronophthisis module linking NEK8 to INVS and NPHP3. *Nat Genet* 2013; **45**: 951–956.
- 43 Halbritter J, Bizet AA, Schmidts M, Porath JD, Braun DA, Gee HY *et al*. Defects in the IFT-B component IFT172 cause Jeune and Mainzer-Saldino syndromes in humans. *Am J Hum Genet* 2013; **93**: 915–925.
- 44 Failer M, Gee HY, Joo K, Halbritter J, Belkacem L *et al*. Mutations of CEP83 cause infantile nephronophthisis and intellectual disability. *Am J Hum Genet* 2014; **94**: 905–914.
- 45 Schueler M, Braun DA, Chandrasekar G, Gee HY, Klasson TD, Halbritter J *et al*. DCCDC2 mutations cause a renal-hepatic ciliopathy by disrupting Wnt signaling. *Am J Hum Genet* 2015; **96**: 81–92.
- 46 Otto E, Hoefele J, Ruf R, Mueller AM, Hiller KS, Wolf MT *et al*. A gene mutated in nephronophthisis and retinitis pigmentosa encodes a novel protein, nephroretinin, conserved in evolution. *Am J Hum Genet* 2002; **71**: 1161–1167.
- 47 Denamur E, Delezoide AL, Alberti C, Bourillon A, Gubler MC, Bouvier R *et al*. Genotype-phenotype correlations in fetuses and neonates with autosomal recessive polycystic kidney disease. *Kidney Int* 2010; **77**: 350–358.
- 48 Hao X, Liu S, Dong Q, Zhang H, Zhao J, Su L. Whole exome sequencing identifies recessive PKHD1 mutations in a Chinese twin family with Caroli disease. *PLoS One* 2014; **9**: e92661.
- 49 Sharp AM, Messiaen LM, Page G, Antignac C, Gubler MC, Onuchic LF *et al*. Comprehensive genomic analysis of PKHD1 mutations in ARPKD cohorts. *J Med Genet* 2005; **42**: 336–349.
- 50 Kroes HY, van Zon PH, Franssen van de Putte D, Nelen MR, Nijelstein RJ, Wittebol-Post D *et al*. DNA analysis of AHI1, NPHP1 and CYCLIN D1 in Joubert syndrome patients from the Netherlands. *Eur J Med Genet* 2008; **51**: 24–34.
- 51 Hichri H, Stoetzel C, Laurier V, Caron S, Sigaudy S, Sarda P *et al*. Testing for triallelism: analysis of six BBS genes in a Bardet-Biedl syndrome family cohort. *Eur J Hum Genet* 2005; **13**: 607–616.



This work is licensed under a Creative Commons Attribution-NonCommercial-NoDerivs 4.0 International License. The images or other third party material in this article are included in the article's Creative Commons license, unless indicated otherwise in the credit line; if the material is not included under the Creative Commons license, users will need to obtain permission from the license holder to reproduce the material. To view a copy of this license, visit <http://creativecommons.org/licenses/by-nc-nd/4.0/>

Supplementary Information accompanies the paper on Experimental & Molecular Medicine website (<http://www.nature.com/emm>)