

## RESEARCH ARTICLE

# Ultrasonographic Features of Medullary Thyroid Carcinoma: Do they Correlate with Pre- and Post-Operative Calcitonin Levels?

Kyung Eun Cho<sup>1</sup>, Hye Mi Gweon<sup>1</sup>, Ah Young Park<sup>1,2</sup>, Mi Ri Yoo<sup>1</sup>, Jeong-Ah Kim<sup>1</sup>, Ji Hyun Youk<sup>1</sup>, Young Mi Park<sup>2,3</sup>, Eun Ju Son<sup>1\*</sup>

### Abstract

**Purpose:** To correlate ultrasonographic (US) features of medullary thyroid carcinoma (MTC) with preoperative and post-operative calcitonin levels. **Materials and Methods:** A total of 130 thyroid nodules diagnosed as MTC were evaluated. Two radiologists retrospectively evaluated preoperative US features according to size, shape, margin, echogenicity, type of calcification, and lymph node status. Postoperative clinical and imaging follow-up (mean duration  $31.9 \pm 22.5$  months) was performed for detection of tumor recurrence. US features, presence of LN metastasis, and tumor recurrence were compared between MTC nodules with and without elevated preoperative calcitonin ( $>100$  pg/mL). Those with normalized and non-normalized postoperative calcitonin levels groups were also compared. **Results:** Common US features of MTCs were solid internal content (90.8%), irregular shape (44.6%), circumscribed margin (46.2%), and hypoechogenicity (56.2%). Comparing MTC nodules with and without elevated preoperative calcitonin levels, the size and shape of MTC nodule and lymph node metastasis showed statistical significance ( $p < 0.05$ ). Postoperative calcitonin normalization correlated with US features of tumor size ( $p = 0.002$ ), margin ( $p = 0.034$ ), shape ( $p \leq 0.001$ ), and presence of calcification ( $p = 0.046$ ). Tumor recurrence and LN metastasis were more prevalent in patients without normalization of postoperative calcitonin than in those with normalization ( $p = 0.001$ ). **Conclusions:** Serum calcitonin measurement is helpful for early diagnosis and predicting prognosis. Postoperative calcitonin measurement is also important for postoperative US follow up, especially in cases with larger nodule size, presence of calcification, irregular shape, and irregular margin.

**Keywords:** Medullary thyroid cancer - ultrasonographic features - preoperative calcitonin - postoperative calcitonin

*Asian Pac J Cancer Prev*, 17 (7), 3357-3362

### Introduction

Medullary thyroid carcinoma (MTC) is a relatively uncommon malignancy arising from parafollicular C-cells that accounts for 3.5-10% of thyroid cancers (Melvin et al., 1968; McCook et al., 1982). MTC may be more aggressive than well-differentiated thyroid cancer (papillary, follicular) because it has a greater propensity to present with regional or distant metastasis at the time of initial diagnosis (Lairmore et al., 1991; Bankoff et al., 1987; Jimenez et al., 1995), and 10-year survival rates are approximately 40-50% (Gharib et al., 1992). Therefore, early diagnosis of MTC is important to improve long-term prognosis. Among several diagnostic tools for MTC, ultrasonography (US) with fine needle aspiration (FNA) has most often been adopted, as for other well-differentiated thyroid cancers (Frates et al., 2005). However, the reported sensitivity of FNA for diagnosing

MTC is only 56% (Trimboli et al., 2015).

An important additional diagnostic tool is serum calcitonin, a sensitive and specific marker for MTC that has been widely used for diagnosis and post-surgical follow up (Costante et al., 2007). However, routine use of serum calcitonin measurement has been limited because it is not cost effective in North America, European centers and guidelines recommend calcitonin screening in nodular thyroid disease (Kloos et al., 2009; Gharib et al., 2010).

Although several studies have recently documented characteristic US features of MTC (Saller et al., 2002; Kim et al., 2009; Fukushima et al., 2009; Lee et al., 2010; Choi et al., 2011), they focused on comparisons with papillary thyroid cancer (Kim et al., 2009; Lee et al., 2010) or with benign nodules (Saller et al., 2002). To our knowledge, no reports correlating US features of MTC with serum calcitonin level have been published to date.

<sup>1</sup>Department of Radiology and Research Institute of Radiological Science Yonsei University, College of Medicine <sup>2</sup>Department of Radiology, Korea university ansan hospital <sup>2,3</sup>Department of Radiology, Busan Paik Hospital, Inje University Medical college, Busan, Korea \*For correspondence: ejsonrd@yuhs.ac

## Materials and Methods

### Patient selection

The institutional review board approved this retrospective study and the need for informed consent was waived. From November 2007 through October 2010, 188 patients were diagnosed with MTC after total thyroidectomy. We excluded 67 patients without preoperative sonography images and 5 patients without preoperative or postoperative calcitonin levels. Four patients were also excluded because they have already undergone total thyroidectomy at the time of US imaging. The final study group consisted of 112 patients (80 women and 32 men; age range 21-81) with 130 MTCs: a single MTC nodule in 94 patients and bilateral MTC nodules in 18 patients. Mostly, total thyroidectomy with central node dissection was done except nineteen patients (total thyroidectomy with modified radical neck dissection).

### Image analysis

US and FNA were performed as a baseline study before surgery. Six radiologists with 5-15 years of experience performed real-time US with a commercially available 7-12-MHz linear transducer (iU22 scanners, Philips Healthcare). Retrospective review of the sonographic images was performed in consensus by two radiologists with 5 and 15 years of experience who were blinded to the pathologic results. They analyzed US features of thyroid nodules according to internal components (solid or mixed), echogenicity (isoechoic, hypoechoic, or markedly hypoechoic), margins (circumscribed, microlobulated, or irregular), calcifications (microcalcification or macrocalcification), shape (oval, round [taller than wide], or irregular), and final assessment of the nodules. The size of nodules was recorded according to previous sonography reports. We also reviewed preoperative US images for the presence of lymph node metastasis. Postoperative US imaging follow up (mean duration  $31.89 \pm 22.51$  months) was performed for detection of tumor recurrence.

Malignant features were defined on the basis of previously published criteria as marked hypoechoogenicity, microlobulated or irregular margins, microcalcifications, and taller than wide shape (Kim et al., 2002).

When a thyroid nodule showed one or more of the malignant features described previously, it was assessed as suspicious for malignancy. When a thyroid nodule showed none of the malignant or indeterminate features, it was assessed as probably benign. When a thyroid nodule showed one or more indeterminate feature and no malignant features, regardless of the presence of benign features, it was assessed as low suspicion of malignancy.

### Serum calcitonin levels

The majority of patients had values for serum calcitonin measured using chemiluminescent immunoassay (ARUP, UT; Simens Immulite 2000; reference range,  $<5$  pg/mL for women,  $<8.4$  pg/mL for men). The highest calcitonin level in the preoperative period and the lowest calcitonin level in postoperative period were recorded. According to ATA guidelines, elevated preoperative calcitonin was defined as  $> 100$  pg/ml (Kloos et al., 2009).

Postoperative follow-up and evaluation of recurrence in our department were as follows. We routinely measured basal calcitonin levels on the first day and the 7th day after surgery. MTC nodules with normalized postoperative calcitonin level were classified when basal calcitonin was within the normal range and the peak calcitonin level was less than threefold greater than basal calcitonin.

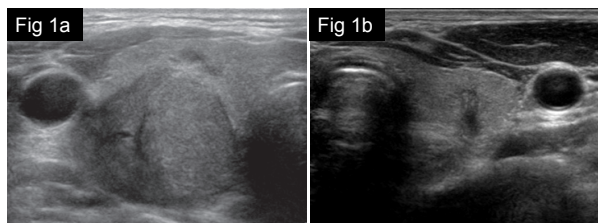
### Statistical analysis

US features, presence of LN metastasis, and tumor recurrence were compared between MTC nodules with and without elevated preoperative calcitonin ( $>100$  pg/mL). MTC nodules with normalized and non-normalized postoperative calcitonin levels (normal value,  $<5$  pg/mL for women,  $<8.4$  pg/mL for men) were also compared. The chi-square test was used for analysis. Statistical analysis of differences in size was performed with the Student's t-test. A value of  $p < 0.05$  was considered statistically significant.

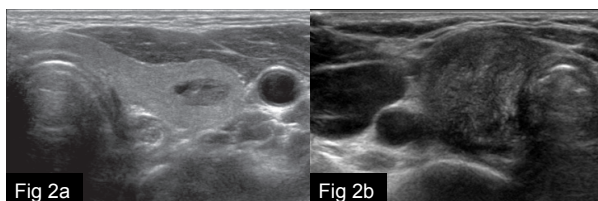
## Results

A summary of the results is presented in Tables 1, 2, and 3. The common US features of MTC were solid internal content (90.8%), irregular shape (44.6%), circumscribed margin (46.2%), and hypoechoogenicity (56.2%). The mean size of 130 MTC nodules was  $16.22 \pm 12.69$  mm. Forty-nine nodules (37.7%) were classified as suspicious for malignancy, 48 (36.9%) as low suspicion for malignancy, and 33 (25.4%) as probably benign.

The study group consisted of 81 MTC nodules



**Figure 1. Medullary Thyroid Carcinomas with (a) Elevated Preoperative Calcitonin and Without (b) Elevated Preoperative Calcitonin Levels.** Both medullary thyroid carcinoma nodules show similar ultrasonographic features including solid internal content, irregular shape and margin, marked hypoechoogenicity except size. (a) A 46-year-old man shows 28 mm sized nodule whereas, (b) A 48-year-old man shows 3 mm sized nodule



**Figure 2. Medullary Thyroid Carcinomas with (a) Postoperative Calcitonin Normalization and without (b) Postoperative Calcitonin Normalization.** (a) A 44-year-old man shows 10 mm sized nodule with ultrasonographic features of oval shape, circumscribed margin without calcification. (b) A 55-year-old woman shows 32 mm sized nodule with ultrasonographic features of irregular shape, irregular margin and presence of calcification

**Table 1. Comparison of Ultrasonographic Features of Medullary Thyroid Carcinoma according to Preoperative Calcitonin Level**

Ultrasonographic features (n=130)	Preoperative calcitonin level >100 (n=81)	Preoperative calcitonin level <100 (n=49)	P value
Mean size (mm ± SD)	21.0±12.79	8.31±7.59	<0.001
Diagnosis			0.947
Probably benign	21 (25.9)	12 (24.5)	
Low suspicion for malignancy	29 (35.8)	19 (38.8)	
Suspicion for malignancy	31 (38.3)	18 (36.7)	
Internal content			0.133
Solid	71 (87.7)	47 (95.9)	
Mixed	10 (12.3)	2 (4.1)	
Shape			0.004
Oval	35 (43.2)	13 (26.5)	
Round	8 (9.9)	16 (32.7)	
Irregular	38 (46.9)	20 (40.8)	
Margin			0.056
Circumscribed	38 (46.9)	22 (44.9)	
Microlobulated	16 (19.8)	3 (6.1)	
Irregular	27 (33.3)	24 (49.0)	
Echogenicity			0.358
Markedly hypoechoic	19 (23.5)	16 (32.7)	
Hypoechoic	46 (56.8)	27 (55.1)	
Isoechoic	16 (19.7)	6 (12.2)	
Calcification			0.589
Absence	40 (49.4)	27 (55.1)	
Presence	41 (50.6)	22 (44.9)	
Type of calcification			0.772
Microcalcification	30 (71.4)	15 (30.6)	
Macrocalcification	11 (28.6)	7 (14.3)	

**Table 2. Comparison of Ultrasonographic Features of Medullary Thyroid Carcinoma according to Presence or Absence of Postoperative Calcitonin Normalization**

Ultrasonographic features (n=130)	Normalized Postoperative Calcitonin (n=82)	Non-normalized Postoperative Calcitonin (n=48)	P value
Mean size (mm ± SD)	13.41±10.76	21.0±14.33	0.002
Diagnosis			0.289
Probably benign	21 (25.6)	12 (25.0)	
Low suspicion for malignancy	34 (41.5)	14 (29.2)	
Suspicion for malignancy	27 (32.9)	22 (45.8)	
Internal content			0.125
Solid	77 (93.9)	41 (85.4)	
Mixed	5 (6.1)	7 (14.6)	
Shape			<0.001
Oval	33 (40.2)	15 (31.3)	
Round	22 (26.8)	2 (4.2)	
Irregular	27 (32.9)	31 (64.6)	
Margin			0.034
Circumscribed	45 (54.9)	15 (31.3)	
Microlobulated	10 (12.2)	9 (18.7)	
Irregular	27 (32.9)	24 (50)	
Echogenicity			0.282
Markedly hypoechoic	26 (31.7)	9 (18.8)	
Hypoechoic	43 (52.4)	30 (62.4)	
Isoechoic	13 (15.9)	9 (18.8)	
Calcification			0.046
Absence	48 (58.5)	19 (39.6)	
Presence	34 (41.4)	29 (60.4)	
Type of calcification			0.58
Microcalcification	23 (28.0)	22 (45.8)	
Macrocalcification	11 (13.4)	7 (14.6)	

associated with elevated preoperative calcitonin and 49 MTC nodules without elevation of calcitonin. Eighty-two MTC nodules showed normalized postoperative calcitonin whereas 48 MTC nodules did not show postoperative

calcitonin normalization (Tables 1, 2).

The mean size of nodules with elevated preoperative calcitonin levels was significantly larger than that of nodules without elevated preoperative calcitonin levels

**Table 3. Correlation between Preoperative and Postoperative Calcitonin Level and Lymph Node Metastasis or Tumor Recurrence**

		LN metastasis		Tumor recurrence		P value
		Absence	Presence	Absence	Presence	
Total (n=130)		87 (66.9)	43 (33.1)	120 (92.3)	10 (7.7)	
Preoperative calcitonin level	Elevated (n=81)	44 (54.3)	37 (45.7)	73 (90.1)	8 (9.9)	<0.001
	Non-elevated (n=49)	43 (87.8)	6 (12.2)	47 (95.9)	2 (4.1)	0.318
Postoperative calcitonin level	Normalized (n=82)	70 (85.4)	12 (14.6)	81 (98.8)	1 (1.2)	<0.001
	Non-normalized (n=48)	17 (35.4)	31 (64.6)	39 (81.3)	9 (18.7)	0.001

LN, lymph node

( $21.0 \pm 12.79$  versus  $8.31 \pm 7.59$  mm;  $p < .001$ ). There was a significant difference in shape between MTC nodules with and without elevated preoperative calcitonin level ( $p = 0.004$ ). However, there was no statistical difference in internal content ( $p = 0.133$ ), margin ( $p = 0.056$ ), echogenicity ( $p = 0.358$ ), and presence of calcification ( $p = 0.589$ ) between MTC nodules with and without elevated preoperative calcitonin levels (Table 1, Figure 1).

The mean size of nodules without postoperative calcitonin normalization was significantly larger than the mean size of nodules with postoperative calcitonin normalization ( $21 \pm 14.33$  versus  $13.41 \pm 10.76$  mm;  $p < 0.002$ ). Comparison of MTC nodules with and without postoperative calcitonin normalization showed statistical significance for margin ( $p = 0.034$ ), shape ( $p < 0.001$ ), and presence of calcification ( $p = 0.046$ ). However, there was no statistical difference in internal content ( $p = 0.125$ ) or echogenicity ( $p = 0.282$ ) between MTC nodules with and without normalization of postoperative calcitonin (Table 2, Figure 2).

Lymph node metastasis showed statistical significance between MTC nodules with and without elevated preoperative calcitonin levels ( $p < 0.001$ ). Both tumor recurrence and LN metastasis were more prevalent in patients without normalization of postoperative calcitonin than in those with normalization ( $p = 0.001$ ) (Table 3).

## Discussion

Although there have been several studies evaluating US findings of MTCs (Kim et al., 2009; Lee et al., 2010; Saller et al., 2002; Fukushima et al., 2009; Choi et al., 2011), our study includes the largest series of US findings in primary MTC reported to date from a single center. Furthermore, the focus of our study was to evaluate US findings according to preoperative and postoperative serum calcitonin, which has not been documented in previous reports.

The most common US findings of MTCs in this study were solid internal content (90.8%), irregular shape (44.6%), circumscribed margin (46.2%), hypoechogenicity (56.2%), and absence of calcification (51.5%). Forty-nine nodules (37.7%) were classified as suspicious for malignancy, 48 (36.9%) as low suspicion for malignancy, and 33 (25.4%) as probably benign.

In terms of echogenicity and margins in US findings of MTC nodules, our study showed similar results to previous studies including hypoechoic internal echogenicity and circumscribed margin (Gorman et al., 1987; Saller et al., 2002; Lee et al., 2010; Choi et al., 2011). Among nodules

with calcification (48.5%), microcalcifications were found in 71.4% of the lesions and macrocalcifications in 28.6%. A similar pattern of calcification was observed in previous studies (Kim et al., 2009; Lee et al., 2010). However, in terms of shape, our study showed that MTC nodules were more likely to have an irregular shape than an oval or round shape, which is different from that reported in other studies. In a study by Lee et al. (Lee et al., 2010), round to oval shape was present in 67.4% of all MTC nodules investigated, whereas irregular and taller than wide shapes of MTC nodules were observed in only 19.6% and 13%, respectively. Kim et al. and Choi et al. also showed that the shape of MTC nodules was more likely to be oval to round than irregular or taller than wide (Kim et al., 2009; Choi et al., 2011). We found that MTC nodules tended to show malignant features rather than benign features, with the exception of the circumscribed margin.

A substantial number of MTC nodules (74.6%) in the current study were classified as low suspicion or suspicious for malignancy; these results are in agreement with previous studies including those of Lee et al. (71.7%), Kim et al. (2009) (81%), Choi et al. (72.2%), and Fukushima et al. (70.1%) (Kim et al., 2009; Lee et al., 2010; Fukushima et al., 2009; Choi et al., 2011). Nonetheless, quite a large number of MTC nodules were diagnosed as probably benign. In this study, 33 of 130 MTC nodules (25.4%) lacked US findings typical for thyroid carcinoma and were diagnosed as probably benign. In other words, based on US findings, at least one out of four MTC nodules would not be diagnosed as possibly malignant and therefore would not undergo FNAB. This might worsen the overall prognosis of MTC patients.

In addition to thyroid US, FNA is another widely adopted diagnostic method for thyroid nodules based on the assumption that it has an acceptable reliability to distinguish between benign and malignant lesions (Kim et al., 2002; Frates et al., 2005). According to several reports, the accuracy, sensitivity, and specificity of FNA was 95%, 83%, and 92%, respectively (Gharib et al., 1994; Danese et al., 1998). However, the use of FNA has been established for papillary thyroid carcinomas, and Bugalho et al. reported the sensitivity of FNA in diagnosing MTCs to be only 63% (Melvin et al., 1968). It was similar with the result of our institution (66%). Failure to detect typical features of MTCs, such as amyloid, in routine methods and the presence of cytologic patterns that mimic papillary, anaplastic, or follicular carcinoma can cause problems (Geddie et al., 1984; Takeichi et al., 1989). If cytologic examination does not show the malignant potential of the tumor, MTC nodules might be diagnosed as benign and



might not undergo thyroidectomy.

Considering the high false-negative rate of FNA (Hahm et al., 2001; Trimboli et al., 2015) and US in diagnosing MTC, we inevitably need an additional diagnostic tool for early and precise diagnosis of MTC. The serum calcitonin level has been considered a sensitive and specific marker for MTC based on the fact that MTC arises from the parafollicular "C" cells and produces calcitonin. Although its effectiveness is still controversial (Costante et al., 2007) several studies have evaluated the utility of serum calcitonin measurement (Hahm et al., 2001; Elisei et al., 2004; Cheung et al., 2008). For example, Elisei et al. reviewed 10,864 patients and found that preoperative serum calcitonin measurement in thyroid nodules is the most informative test for early diagnosis and overcame the frequent false negative results of FNAB. The survival rate was significantly better in MTCs detected by serum calcitonin measurement than in MTCs not detected by serum calcitonin measurement (Elisei et al., 2004). In the present work, tumor size and presence of LN metastasis correlated with preoperative calcitonin level. A similar pattern was also observed in the reports of Yip et al. (2011). Likewise, Cohen et al revealed that serum calcitonin below a threshold calcitonin level of 100 pg/mL was associated with a median tumor size of 0.3 cm, compared with 2.0 cm for a calcitonin level >100 pg/mL (Cohen et al., 2000).

Preoperative serum calcitonin level helps early diagnosis and predicts the prognosis of MTCs whereas postoperative serum calcitonin levels indicate the presence of persistent or recurrent tumors (Yip et al., 2011). We found that postoperative calcitonin normalization correlated not only with tumor size but also with tumor margin, presence of calcification, and tumor recurrence. Therefore, after total thyroidectomy, it is necessary to check the postoperative calcitonin level in addition to postoperative follow up imaging with US, especially for MTC nodules with larger size, presence of calcification, and irregular margin.

There are a few limitations of this study. First, this was a retrospective study design and prospective evaluation with real-time sonography is therefore needed. Additionally, the reviewers were aware of the final diagnosis, which might have influenced the results. Second, not all MTCs secrete calcitonin; for example, advanced tumors may dedifferentiate with a subsequent decrease in calcitonin production. Furthermore, hypercalcitoninemia is also associated with non-tumorous conditions such as autoimmune thyroid disease, hypergastrinemia and C-cell hyperplasia; other factors that increase calcitonin are alcohol consumption, smoking, sepsis, and heterophilic anticalcitonin antibodies (d'Herbomez et al., 2007; Kotzmann et al., 1999). Finally, patients in our study didn't undergo pentagastrin stimulating test (Costante et al., 2007) or calcitonin measurement in washout of the needle after aspiration which may increase diagnostic accuracy (Trimboli et al., 2012).

In conclusion, although most MTCs show US findings of malignant thyroid nodules, at least one out of four MTC nodules appears probably benign on US. In addition, MTC shows a high false-negative rate in

FNA. Therefore, measurement of preoperative serum calcitonin is helpful for early diagnosis and predicting prognosis before performing thyroidectomy. Postoperative calcitonin measurement is also an important supplement to postoperative US follow up, especially in cases with larger nodule size, presence of calcification, irregular shape, and irregular margin.

## References

- Bankoff MS, Tuckman GA, Scarborough D (1987). CT appearance of liver metastases from medullary carcinoma of the thyroid. *J Comput Assist Tomogr*, **11**, 1102-3.
- Bugalho MJ, Santos JR, Sobrinho L et al (2005). Preoperative diagnosis of medullary thyroid carcinoma: fine needle aspiration cytology as compared with serum calcitonin measurement. *J Surg Oncol*, **91**, 56-60.
- Cheung K, Roman SA, Wang TS, et al (2008). Calcitonin measurement in the evaluation of thyroid nodules in the United States: a cost-effectiveness and decision analysis. *J Clin Endocrinol Metab*, **93**, 2173-80.
- Choi N, Moon W, Lee JH, et al (2011). Ultrasonographic findings of medullary thyroid cancer: differences according to tumor size and correlation with fine needle aspiration results. *Acta Radiol*, **52**, 312-6.
- Cohen R, Campos JM, Salaün C, et al (2000). Preoperative calcitonin levels are predictive of tumor size and postoperative calcitonin normalization in medullary thyroid carcinoma. Groupe d'Etudes des Tumeurs a Calcitonine (GETC). *J Clin Endocrinol Metab*, **85**, 919-22.
- Costante G, Meringolo D, Durante C, et al (2007). Predictive value of serum calcitonin levels for preoperative diagnosis of medullary thyroid carcinoma in a cohort of 5817 consecutive patients with thyroid nodules. *J Clin Endocrinol Metab*, **92**, 450-5.
- Danese D, Sciacchitano S, Farsetti A, et al (1998). Diagnostic accuracy of conventional versus sonography-guided fine-needle aspiration biopsy of thyroid nodules. *Thyroid*, **8**, 15-21.
- d'Herbomez M, Caron P, Bauters C, et al (2007). Reference range of serum calcitonin levels in humans: influence of calcitonin assays, sex, age, and cigarette smoking. *Eur J Endocrinol*, **157**, 749-55.
- Elisei R, Bottici V, Luchetti F, et al (2004). Impact of routine measurement of serum calcitonin on the diagnosis and outcome of medullary thyroid cancer: experience in 10,864 patients with nodular thyroid disorders. *J Clin Endocrinol Metab*, **89**, 163-8.
- Frates MC, Benson CB, Charboneau JW, et al (2005). Management of thyroid nodules detected at US: Society of Radiologists in Ultrasound consensus conference statement. *Radiol*, **237**, 794-800.
- Fukushima M, Ito Y, Hirokawa M, et al (2009). Excellent prognosis of patients with nonhereditary medullary thyroid carcinoma with ultrasonographic findings of follicular tumor or benign nodule. *World J Surg*, **33**, 963-8.
- Geddie WR, Bedard YC, Strawbridge HT (1984). Medullary carcinoma of the thyroid in fine-needle aspiration biopsies. *Am J Clin Pathol*, **82**, 552-8.
- Gharib H, McConahey WM, Tieg RD, et al (1992). Medullary thyroid carcinoma: clinicopathologic features and long-term follow-up of 65 patients treated during 1946 through 1970. *Mayo Clin Proc*, **67**, 934-40.
- Gharib H (1994). Fine-needle aspiration biopsy of thyroid nodules: advantages, limitations, and effect. *Mayo Clin Proc*, **69**, 44-9.

- Gharib H, Papini E, Paschke R, et al (2010). American association of clinical endocrinologists, associazione medici endocrinologi, and european thyroid association medical guidelines for clinical practice for the diagnosis and management of thyroid nodules: executive summary of recommendations. *J Endocrinol Invest*, **33**, 1-56.
- Gorman B, Charboneau JW, James EM, et al (1987). Medullary thyroid carcinoma: role of high-resolution US. *Radiol*, **162**, 147-50.
- Hahn JR, Lee MS, Min YK, et al (2001). Routine measurement of serum calcitonin is useful for early detection of medullary thyroid carcinoma in patients with nodular thyroid diseases. *Thyroid*, **11**, 73-80.
- Jimenez JM, Casey SO, Citron M, et al (1995). Calcified pulmonary metastases from medullary carcinoma of the thyroid. *Comput Med Imaging Graph*, **19**, 325-8.
- Kim E, Park CS, Chung WY, et al (2002). New sonographic criteria for recommending fine-needle aspiration biopsy of nonpalpable solid nodules of the thyroid. *Am J Roentgenol*, **178**, 687-91.
- Kim S, Kim B, Jung S, et al (2009). Ultrasonographic findings of medullary thyroid carcinoma: a comparison with papillary thyroid carcinoma. *Korean J Radiol*, **10**, 101-5.
- Kloos RT, Eng C, Evans DB, et al (2009). Medullary thyroid cancer: management guidelines of the American thyroid association. *Thyroid*, **19**, 565-612.
- Kotzmann H, Schmidt A, Scheuba C, et al (1999). Basal calcitonin levels and the response to pentagastrin stimulation in patients after kidney transplantation or on chronic hemodialysis as indicators of medullary carcinoma. *Thyroid*, **9**, 943-7.
- Lairmore TC, Wells SA (1991). Medullary carcinoma of the thyroid: current diagnosis and management. *Semin Surg Oncol*, **7**, 92-9.
- Lee S, Shin JH, Han B, et al (2010). Medullary thyroid carcinoma: comparison with papillary thyroid carcinoma and application of current sonographic criteria. *Am J Roentgenol*, **194**, 1090-4.
- Lips CJ, Landsvater RM, Hoppener JW, et al (1994). Clinical screening as compared with DNA analysis in families with multiple endocrine neoplasia type 2A. *N Engl J Med*, **331**, 828-35.
- McCook TA, Putman CE, Dale JK, et al (1982). Review: Medullary carcinoma of the thyroid: radiographic features of a unique tumor. *Am J Roentgenol*, **139**, 149-55.
- Melvin KE, Tashjian AH (1968). The syndrome of excessive thyrocalcitonin produced by medullary carcinoma of the thyroid. *Proc Natl Acad Sci U S A*, **59**, 1216-22.
- Saller B, Moeller L, Gorges R, et al (2002). Role of conventional ultrasound and color Doppler sonography in the diagnosis of medullary thyroid carcinoma. *Exp Clin Endocrinol Diabetes*, **110**, 403-7.
- Takeichi N, Ito H, Okamoto H, et al (1989). The significance of immunohistochemically staining calcitonin and CEA in fine-needle aspiration biopsy materials from medullary carcinoma of the thyroid. *Jpn J Surg*, **19**, 674-8.
- Trimboli P, Rossi F, Baldelli R, et al (2012). Measuring calcitonin in washout of the needle in patients undergoing fine needle aspiration with suspicious medullary thyroid cancer. *Diagn Cytopathol*, **40**, 394-8.
- Trimboli P, Treglia G, Guidobaldi L, et al (2015). Detection rate of FNA cytology in medullary thyroid carcinoma: a meta-analysis. *Clin Endocrinol. (Oxf)*, **82**, 280-5.
- Yip DT, Hassan M, Pazaitou Panayiotou K, et al (2011). Preoperative basal calcitonin and tumor stage correlate with postoperative calcitonin normalization in patients undergoing initial surgical management of medullary thyroid carcinoma. *Surg*, **150**, 1168-77.