

## Original Article

# Clinicopathological characterization of vulvar sebaceous gland hyperplasia

Gun Yoon<sup>1</sup>, Hyun-Soo Kim<sup>2</sup>

<sup>1</sup>Department of Obstetrics and Gynecology, Pusan National University Yangsan Hospital, Pusan National University School of Medicine, Yangsan-si, Gyeongsangnam-do, Republic of Korea; <sup>2</sup>Department of Pathology, Severance Hospital, Yonsei University College of Medicine, Seoul, Republic of Korea

Received March 26, 2016; Accepted May 28, 2016; Epub July 1, 2016; Published July 15, 2016

**Abstract:** Sebaceous gland hyperplasia (SGH) is a benign condition that originates in the sebaceous follicles and occurs most commonly on the forehead and cheek. It is very rarely found in the genital region; however, a few case reports have described SGH of the vulva. We recently encountered a case of vulvar SGH in a young woman who presented with an asymmetric labium minus and unilateral vulvar hypertrophy. A meticulous histopathological and immunohistochemical examination was performed, and the respective literature was reviewed. The clinicopathological features and immunophenotype of seven previous cases of vulvar SGH were summarized. A careful histopathological examination is required to diagnose vulvar SGH and distinguish it from other vulvar lesions. Given that the increasing incidence of vulvar cancer, it is necessary to biopsy any unusual-appearing lesions on the vulva. Furthermore, it is important to perform histopathological examinations of these lesions to rule out intraepithelial neoplasia or malignancy.

**Keywords:** Vulva, labium minus, sebaceous gland, hyperplasia, immunohistochemistry

## Introduction

Sebaceous gland hyperplasia (SGH) is a benign, hamartomatous condition that originates in sebaceous follicles. Usually, SGH is usually found in older individuals, and is less common among younger people [1, 2]. It presents as solitary or multiple, yellow, umbilicated papules or nodules that most commonly occur on the forehead and cheek. Occasionally, SGH affects the areola, chest, or genital skin [3, 4].

Excluding the palms and soles, sebaceous glands are ubiquitous in the skin. They are usually found in association with hair structures; however, free sebaceous glands (that are not associated with hair) also occur in areas of modified skin, such as the nipple and areola in men and women. Free sebaceous glands are also found on the labium minus and the inner aspect of the prepuce [5]. The labium minus does not usually contain skin appendages. However, in some individuals, the lateral labium minus has sebaceous and sweat glands. The sebaceous gland elements are medial and pos-

terior to the labium minus at the junction with the vulvar vestibule [6].

SGH on the vulva is quite rare, and only a few cases have been reported in the literature [2, 5-10]. Therefore, it is important for clinicians to be aware of this entity and recognize that its clinical presentations on the vulva are variable. The differential diagnosis of vulvar SGH includes a variety of inflammatory and neoplastic lesions of the vulvoperineal skin. Pathologists should consider SGH examining an unusual vulvar lesion.

## Patient and methods

### Case presentation

An 18-year-old nulligravid woman presented with an asymmetric vulva. One year prior to presentation, the patient noticed vaginal discharge and enlargement of the right labium minus. Menarche occurred at 12 years of age, and the patient's menstrual cycles were regular. Her gynecological history was unremarkable. She was not taking oral contraceptives. On exami-

# Vulvar sebaceous gland hyperplasia

**Table 1.** Antibodies used for immunohistochemical staining

Antibody	Source	Clone	Dilution
AR	Dako, Agilent Technologies, Inc., Carpinteria, CA, USA	AR 441	1:100
CEA	Dako, Agilent Technologies, Inc., Carpinteria, CA, USA	II-7	1:400
CK 5/6	Dako, Agilent Technologies, Inc., Carpinteria, CA, USA	D5/16 B4	1:200
EMA	Dako, Agilent Technologies, Inc., Carpinteria, CA, USA	E29	1:200
ER	Thermo Fisher Scientific, Inc., Fremont, CA, USA	SP1	1:100
PR	Dako, Agilent Technologies, Inc., Carpinteria, CA, USA	PgR 636	1:50
p63	Dako, Agilent Technologies, Inc., Carpinteria, CA, USA	DAK-p63	1:150
SMA	Dako, Agilent Technologies, Inc., Carpinteria, CA, USA	1A4	1:500

AR: androgen receptor; CEA: carcinoembryonic antigen; CK: cytokeratin; EMA: epithelial membrane antigen; ER: estrogen receptor; PR: progesterone receptor; SMA: smooth muscle actin.

nation, there was a soft lesion in the right vulva measuring 1.2×1.0×1.0 cm. The lesion was covered with normal-appearing skin without apparent texture changes. The surrounding skin was also unremarkable. A local excision with labioplasty was performed.

### *Histopathological examination*

The resected material was fixed in neutral-buffered formalin and was embedded in one paraffin block. Four-micrometer sections were cut from the block and stained with hematoxylin and eosin. The sections were prepared for immunohistochemical staining. Slides were examined under routine light microscopy.

### *Immunohistochemistry*

The tissue sections were deparaffinized and rehydrated with xylene and alcohol solution. Immunohistochemical staining was performed using the Ventana Discovery XT automated staining system (Ventana Medical Systems, Inc., Tucson, AZ, USA) according to the manufacturer's instructions. The Cell Conditioning 1 buffer (citrate buffer, pH 6.0, Ventana Medical Systems, Inc.) was used for antigen retrieval. The tissue sections were then incubated with primary antibodies (**Table 1**). The ultraView Universal DAB Detection Kit (Ventana Medical Systems, Inc.) was used to perform the chromogenic visualization step. The slides were then counterstained with hematoxylin and coverslipped.

### *Literature review*

The Medline database was thoroughly searched using the PubMed retrieval service. Searches were performed using the key words “seba-

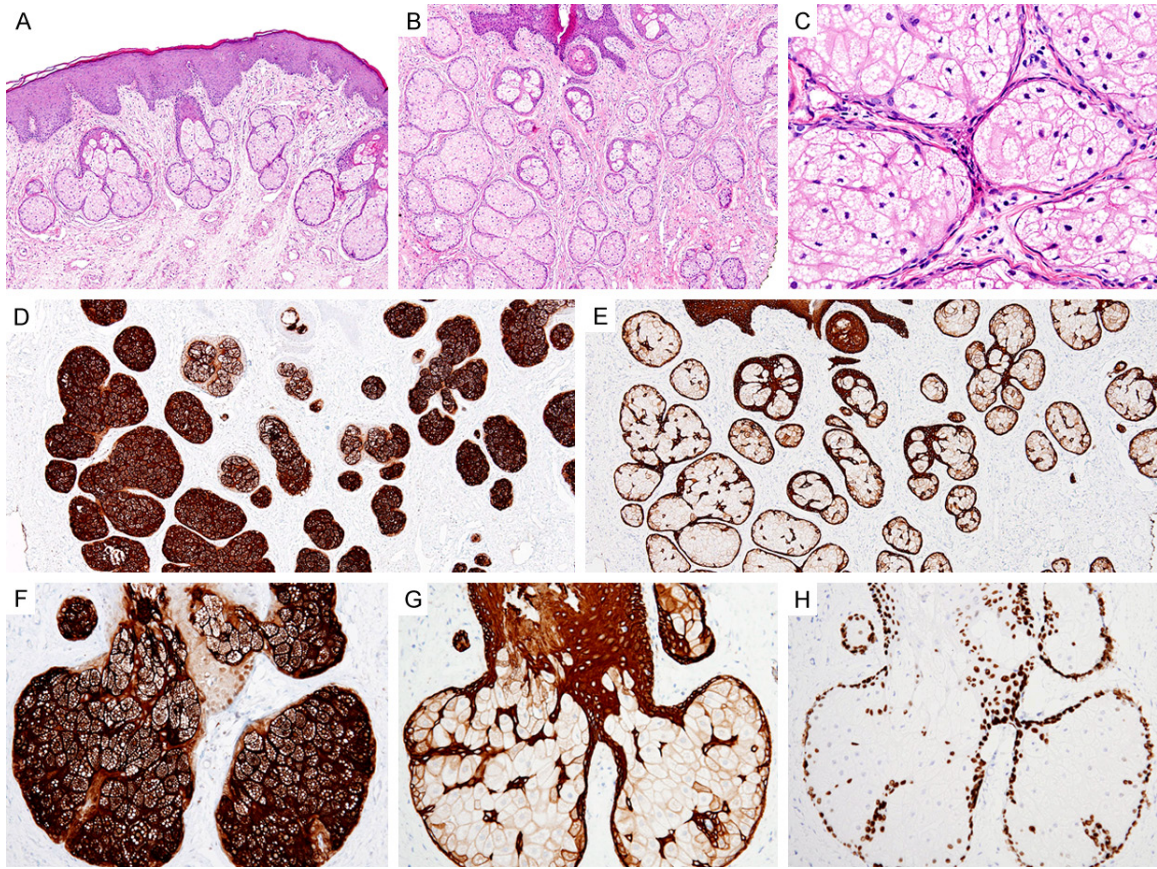
ceous hyperplasia”, “sebaceous”, and “vulva”. Seven cases of vulvar SGH were found. The clinical and pathological features of the seven cases, in addition to our case, were thoroughly reviewed.

### **Results**

On gross examination, the resected specimen consisted of multiple pieces of the skin, which were irregular in size and shape. The largest piece measured 1.5×1.0 cm. The skin did not have any prominent lesions. However, it was slightly thickened with a relatively regular surface. The cut surfaces were pink. Microscopic examination revealed a tumor arising from the sebaceous glands, which consisted of numerous lobules and extended into the dermis in a pattern of well-defined islands (**Figure 1B**). There were significantly more lobules in the tumor tissue compared to in the adjacent normal glands (**Figure 1A**). The sebaceous gland lobules were fully mature; they did not exhibit nuclear enlargement, pleomorphism, hyperchromasia, or mitotic figures (**Figure 1C**). The cells were predominantly mature sebocytes with a peripheral germinal layer, which was not prominent. They displayed a foamy, vesiculated cytoplasm and centrally located nuclei. The lesion also had patchy infiltrate of chronic inflammatory cells.

Both epithelial membrane antigen (EMA; **Figure 1D**) and cytokeratin (CK) 5/6 (**Figure 1E**) immunostaining highlighted scattered hyperplastic lobules. In particular, the sebocytes in the central portion of the glands were positive for EMA (**Figure 1F**). In contrast, CK 5/6 (**Figure 1G**), p63 (**Figure 1H**), and the androgen receptor reacted in the peripheral germinal layer. The specimen was negative for carcinoembryonic

## Vulvar sebaceous gland hyperplasia



**Figure 1.** Histopathological and immunohistochemical findings of vulvar sebaceous gland hyperplasia. (A) Normal epidermis and sebaceous glands of the labium minus. The sebaceous glands are embedded in the dermis. Each gland consists of several lobules. (B) Low-power view of vulvar SGH. The lesion contains an increased number of sebaceous glands with multiple, enlarged, irregularly-arranged lobules. (C) High-power view of Image (B). Each lobule consists of numerous, fully mature sebaceous cells (sebocytes) containing sebum. There are no cytologic atypia or mitotic figures. (D and E) Low-power view of (D) EMA and (E) CK 5/6 immunostaining. The lobules demonstrate diffuse and strong immunoreactivity to both markers. (F) High-power view of Image (D). The sebocytes in the central portion of the gland are strongly positive for EMA. (G) High-power view of Image (E). The peripheral germinative layer exhibits strong positivity for CK 5/6. (H) High-power view of p63 immunostaining. Similar to CK 5/6, p63 reacts with cells in the peripheral germinative layer.

antigen, estrogen receptor, progesterone receptor, and smooth muscle actin.

### Discussion

Vulvar SGH is very rare, with only seven reported cases in the literature. **Tables 2** and **3** list the clinical and pathological features of these seven cases, in addition to the case presented here. The patient age ranged between 18 and 50 years (mean 32.5 years). In five of the eight patients, vulvar SGH presented as a single, unilateral lesion in the labium minus or labium majus. In the three other patients, SGH presented with multiple lesions that were not only in the labium minus or majus, but also in the

mons veneris or vestibule. Five of the eight patients presented with polypoid lesions, which have been previously described as vulvar SGH-specific manifestations [2, 5, 7, 8]. However, the three other patients presented with irregular cutaneous lesions or mucosal thickening or a sessile nodule. Therefore, it is difficult to conclude that a polypoid appearance is a classic indicator of vulvar SGH. Interestingly, two patients also had hyperpigmented lesions. With regard to the variable clinical findings described, SGH should be considered in the case of a polypoid, sessile or pigmented lesion on the vulva. Our literature review demonstrates that vulvar SGH presents with various signs and symptoms. Although the lesion

## Vulvar sebaceous gland hyperplasia

**Table 2.** Clinical features of eight published cases of vulvar sebaceous gland hyperplasia

Case	Author	Age	Location	Clinical presentation	Clinical diagnosis	Associated condition
1	Rocamora et al. [2], 1986	32	Right labium majus (two) and mons veneris (one)	Three soft, nontender, umblicated lesions	Condyloma acuminatum, soft fibroma	None
2	Ortiz-Rey et al. [5], 2002	19	Left labium majus	A soft, polypoid mass covered by normal appearing skin	Not available	None
3	Bakaris et al. [6], 2004	37	Both labia minora	Regularly shaped, smooth, tender tumors covered by normal appearing skin	Not available	Vulvar discomfort, dyspareunia
4	Malliah et al. [8], 2006	50	Left labium minus	Severe burning sensation of vulva	Not available	Remote Bartholin cyst
5	Masmoudi et al. [9], 2006	27	Left labium majus	Multiple soft, nontender lesions	Not available	None
6	Al-Daraji et al. [7], 2007	31	Left labium minus, vestibule	Two soft, nontender, pigmented lesions covered by normal appearing skin	Melanocytic macule, benign tumor	None
7	Mora et al. [10], 2010	45	Left labium minus	Irregular thickening and recurrent inflammatory changes of the skin	Hidradenitis suppurativa	Lymphedema, recurrent dermatitis, recurrent epidermoid cyst
8	Present case, 2016	18	Right labium minus	A single, skin-colored, soft, nontender mass causing asymmetric labia minora	Unilateral labial hypertrophy	Vaginal discharge

**Table 3.** Pathological features of eight published cases of vulvar sebaceous gland hyperplasia

Case	Author	Size (mm)	Gross appearance	Histopathological diagnosis	Immunostaining result
1	Rocamora et al. [2], 1986	15	Polypoid lesions	Sebaceous gland hyperplasia	Not available
2	Ortiz-Rey et al. [5], 2002	25	A polypoid tumor	Sebaceous gland hyperplasia	AR (P), EMA (P), ER (N), PR (N)
3	Bakaris et al. [6], 2004	25	Polypoid, multilobed masses	Sebaceous gland hyperplasia	EMA (P)
4	Malliah et al. [8], 2006	50	Slight mucosal thickening, hyperpigmentation	Sebaceous gland hyperplasia	Not available
5	Masmoudi et al. [9], 2006	5	Multiple polypoid lesions	Sebaceous gland hyperplasia	Not available
6	Al-Daraji et al. [7], 2007	12	Pigmented, polypoid lesions	Sebaceous gland hyperplasia	EMA (P)
7	Mora et al. [10], 2010	20	Irregular skin thickening	Sebaceous gland hyperplasia	CK 5/6 (P), EMA (P), p63 (P), SMA (N), CEA (N), CgA (N)
8	Present case, 2016	12	A sessile nodule	Sebaceous gland hyperplasia	CK 5/6 (P), EMA (P), p63 (P), AR (P), SMA (N), CEA (N), ER (N), PR (N)

AR: androgen receptor; EMA: epithelial membrane antigen; ER: estrogen receptor; PR: progesterone receptor; CK 5/6: cytokeratin 5/6; CEA: carcinoembryonic antigen; CgA: chromogranin A; SMA: smooth muscle actin.

## Vulvar sebaceous gland hyperplasia

described in this report was soft, nontender and covered with normal-appearing skin, other cases have described a burning sensation, dyspareunia, or vaginal discharge. Still further, vulvar SGH may present with recurrent dermatitis caused by eczematous, inflammatory change. Our patient complained of vulvar asymmetry caused by unilateral labial hypertrophy. A sessile nodule (and not necessarily a distinct mass) of vulvar SGH may trigger labial hypertrophy. Vulvar SGH was not suspected preoperatively in any of the reported cases. This suggests that clinicians are not aware of the clinical findings of vulvar SGH, especially given its rarity. Despite having histologically distinctive features, vulvar SGH may be misdiagnosed as a benign tumor (such as soft fibroma), or as an infectious or inflammatory lesion (such as condyloma acuminatum and hidradenitis suppurativa), or a melanocytic macule. Vulvar SGH has several characteristics that distinguish it from SGH occurring elsewhere on the body. The mean age at which facial SGH occurs is 61.2 years [7, 11]. In contrast, vulvar SGH occurs at a mean age of 32.5 years. In particular, six of the eight patients with vulvar SGH were being younger than 40 years. Histopathologically, the mean size of vulvar SGH was 20.5 mm, which is remarkably larger than the usual size of non-vulvar SGH (2-3 mm).

To the best of our knowledge, there are no prior studies that address the immunophenotype of vulvar SGH. However, it is suspected that vulvar SGH has a similar immunophenotype to that occurring elsewhere on the body. EMA is strongly positive in the sebum-rich sebocytes at the central portion of the sebaceous gland lobule. In the peripheral germinative layer, CK 5/6, p63, and AR are positive. These findings are specific to SGH, and can be useful in its diagnosis. Clinically, the differential diagnosis of vulvar SGH includes fibroepithelial polyps (if polypoid), condylomata acuminata, inflammatory processes such as comedos and furuncles, and cutaneous neoplasms. Histopathologically, the differential diagnosis includes other vulvoperineal lesions consisting mostly of mature sebaceous glands such as nevus sebaceous of Jadassohn, sebaceous gland carcinoma, folliculosebaceous cystic hamartoma, sebaceous trichofolliculoma, and sebaceoma [2].

Although the exact pathogenesis of SGH is not yet known, several environmental factors are

suspected to play a role. Ultraviolet radiation, for example, may represent a cofactor involved in its development [12]. Prolonged ultraviolet radiation exposure has been reported to cause SGH in hairless mice [13]. However, this result may not be applicable to vulvar SGH, as there is usually limited ultraviolet exposure to the perineal area. Nodules of mucus-secreting glands have also been associated with prior surgery or states of chronic inflammation [14]. In addition, SGH has been reported in 16% of immunocompromised organ transplant recipients [15]. None of the above-mentioned factors was identified in our patient.

Potential treatments for SGH include cryotherapy, cauterization, topical chemicals, and surgical excision. It is noteworthy that none of the eight reported cases (including the present case) recurred after treatment. Future large cohort studies are needed to clarify the clinical outcome of and therapeutic options for SGH.

Diagnosing vulvar SGH and distinguishing from another vulvar lesion requires a thorough examination of the lesion and an identification of this rare entity. The incidence of vulvar carcinoma is increasing, which makes it necessary to biopsy any unusual-appearing lesions on the vulva. It is similarly important to perform meticulous histopathological examinations of vulvar lesions to exclude intraepithelial neoplasia or malignancy.

### Acknowledgements

This study was supported by a faculty research grant of Yonsei University College of Medicine for 2016 (6-2016-0130).

### Disclosure of conflict of interest

None.

**Address correspondence to:** Dr. Hyun-Soo Kim, Department of Pathology, Severance Hospital, Yonsei University College of Medicine, 50-1, Yonsei-ro, Seodaemun-gu, Seoul 03722, Republic of Korea. Tel: +82-2-2228-1794; Fax: +82-2-362-0860; E-mail: hyunsookim@yuhs.ac

### References

- [1] De Villez RL, Roberts LC. Premature sebaceous gland hyperplasia. *J Am Acad Dermatol* 1982; 6: 933-935.

## Vulvar sebaceous gland hyperplasia

- [2] Rocamora A, Santonja C, Vives R, Varona C. Sebaceous gland hyperplasia of the vulva: a case report. *Obstet Gynecol* 1986; 68: 63S-65S.
- [3] Belinchon I, Aguilar A, Tardio J, Gallego MA. Areolar sebaceous hyperplasia: a case report. *Cutis* 1996; 58: 63-64.
- [4] Hogan DJ. Sebaceous hyperplasia of the chest. *Int J Dermatol* 1991; 30: 306.
- [5] Ortiz-Rey JA, Martin-Jimenez A, Alvarez C, De La Fuente A. Sebaceous gland hyperplasia of the vulva. *Obstet Gynecol* 2002; 99: 919-921.
- [6] Bakaris S, Kiran H, Kiran G. Sebaceous gland hyperplasia of the vulva. *Aust N Z J Obstet Gynaecol* 2004; 44: 75-76.
- [7] Al-Daraji WI, Wagner B, Ali RB, McDonagh AJ. Sebaceous hyperplasia of the vulva: a clinicopathological case report with a review of the literature. *J Clin Pathol* 2007; 60: 835-837.
- [8] Malliah R, Gilhooly P, Lambert WC, Heller DS. Sebaceous hyperplasia of the vulva: case report and review of the literature. *J Low Genit Tract Dis* 2006; 10: 55-57.
- [9] Masmoudi A, Bouassida S, Ayadi L, Elloumi Y, Khabir A, Boudawara T, Turki H, Zahaf A. [Giant sebaceous gland hyperplasia of the vulva]. *Ann Dermatol Venereol* 2006; 133: 571-572.
- [10] Mora M, Boccardo F, Campisi C, Carli C, Ricca R, Fulcheri E. Vulvar sebaceous hyperplasia associated with lymphedema of external genitalia. *Int J Dermatol* 2007; 49: 70-74.
- [11] Schonermark MP, Schmidt C, Raulin C. Treatment of sebaceous gland hyperplasia with the pulsed dye laser. *Lasers Surg Med* 1997; 21: 313-316.
- [12] Zouboulis CC, Boschnakow A. Chronological ageing and photoageing of the human sebaceous gland. *Clin Exp Dermatol* 2001; 26: 600-607.
- [13] Lesnik RH, Kligman LH, Kligman AM. Agents that cause enlargement of sebaceous glands in hairless mice. II. Ultraviolet radiation. *Arch Dermatol Res* 1992; 284: 106-108.
- [14] Prayson RA, Stoler MH, Hart WR. Vulvar vestibulitis. A histopathologic study of 36 cases, including human papillomavirus in situ hybridization analysis. *Am J Surg Pathol* 1995; 19: 154-160.
- [15] de Berker DA, Taylor AE, Quinn AG, Simpson NB. Sebaceous hyperplasia in organ transplant recipients: shared aspects of hyperplastic and dysplastic processes? *J Am Acad Dermatol* 1996; 35: 696-699.