

# Obstructive Sleep Apnea Patients with the Oral Appliance Experience Pharyngeal Size and Shape Changes in Three Dimensions

Seung Hyun Kyung, DDS, PhD<sup>a</sup>; Young-Chel Park, DDS, PhD<sup>b</sup>;  
Eung-Kwon Pae, DDS, MSc, PhD<sup>c</sup>

**Abstract:** Pharyngeal size and shape differences between pre- and posttrials of a mandible-protruding oral appliance were investigated using cine computerized tomography (CT). Fourteen patients diagnosed with obstructive sleep apnea whose apnea-hypopnea index was higher than 5 and arousal index higher than 20 underwent a second overnight sleep study to evaluate the effectiveness of the oral appliance. Three-dimensional changes in pharyngeal shape measured on cross-sectional CT images during two respiratory cycles after oral appliance delivery were estimated by three variables: (1) lateral dimension, (2) anterior-posterior dimension, and (3) cross-sectional area at five vertical levels. Apnea indices improved significantly when the appliance was used. During apnea, measurements at retropalatal and retroglossal levels decreased most. However, the cross-sectional area of these levels appeared to increase significantly ( $P < .05$ ) with the appliance in place during wakefulness. The oral appliance appears to enlarge the pharynx to a greater degree in the lateral than in the sagittal plane at the retropalatal and retroglossal levels of the pharynx, suggesting a mechanism for the effectiveness of oral appliances that protrude the mandible. (*Angle Orthod* 2004;75:15–22.)

**Key Words:** OSA, Cine-CT

## INTRODUCTION

Repetitive occlusion of the upper airway during sleep is correlated with increased morbidity and mortality from cardiovascular and other complications in adults.<sup>1–4</sup> Obstructive sleep apnea (OSA), a common medical disorder in adults,<sup>5</sup> is characterized by recurrent pharyngeal airway obstruction during sleep. This repetitive occlusion of airflow results in recurrent episodes of hypoxia and frequent arousals, which leads to sleep fragmentation.<sup>6,7</sup>

Although nasal continuous positive air pressure (CPAP) arguably<sup>8</sup> remains a noninvasive treatment of choice,<sup>9</sup> various oral appliances inundate the clinical field of treating mild to moderate OSA.<sup>10–17</sup> Given compliance problems

with nasal CPAP treatment,<sup>18</sup> advancing the mandible forward to enlarge the pharynx could be considered an alternative to CPAP therapy. Orthognathic surgical intervention advances the mandible and the tongue base forward<sup>19–23</sup> as do some oral appliances.

Clinical trials demonstrated a comparable effectiveness of oral appliances and nasal CPAP<sup>12</sup> or uvulopalatopharyngoplasty.<sup>13,22,24</sup> However, the mechanisms by which the appliance works remain unknown.<sup>25</sup> In 1934, Robin<sup>26</sup> first introduced an intraoral appliance to treat upper airway obstruction due to a severe retrognathic mandible, but how mandibular advancement maintains the airway is still speculative. Some studies claimed appliances increase genioglossus muscle activity<sup>27</sup> and others<sup>28,29</sup> observed mechanical property changes in the pharyngeal conduit with the appliance in the mouth. However, three-dimensional studies on structural changes of the pharyngeal tube before and after placement of the appliance have not been conclusive.<sup>30</sup>

Cine computerized tomography (CT) offers several advantages.<sup>31–34</sup> First, it provides a three-dimensional image. Second, the image can be obtained in the supine body position. This may be important because body-posture change influences size of the upper airway.<sup>35,36</sup> Third, the technique can capture images during the entire breathing cycle.<sup>37</sup> Size of the pharyngeal lumen fluctuates continuously with the

<sup>a</sup> Assistant Professor, Sungkyunkwan University School of Medicine, Seoul, South Korea.

<sup>b</sup> Professor, Department of Orthodontics, College of Dentistry, Oral Science Research Center, Institute of Craniofacial Deformity, Yonsei University, Seoul, South Korea.

<sup>c</sup> Assistant Professor, Section of Orthodontics, UCLA School of Dentistry, Los Angeles, Calif.

Corresponding author: Eung-Kwon Pae, DDS, MSc, PhD, UCLA School of Dentistry, 10833 Le Conte Avenue, Los Angeles, CA 90095 (e-mail: epae@dentnet.dent.ucla.edu).

Accepted: February 2004. Submitted: November 2003.

© 2004 by The EH Angle Education and Research Foundation, Inc.

phases of respiration. Thus, static images of this dynamic structure may not be ideal for evaluation of the pharynx. The current prospective study seeks to investigate the mechanisms of how the appliance may alleviate OSA and uses the cine-CT technique to monitor pharyngeal changes in size and shape after the placement of an appliance in the mouths of apneic patients.

## MATERIALS AND METHODS

### Participants and procedures

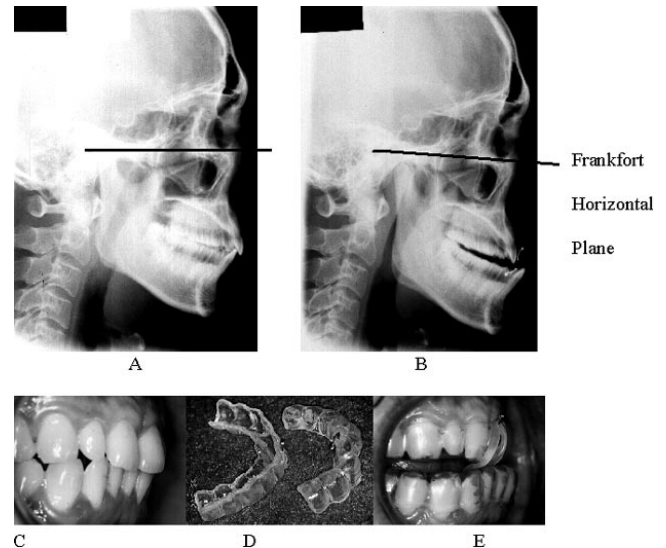
The current investigation was a pre- and posttrial comparison study of OSA patients recruited for the study, who were unwilling to wear the nasal CPAP but who agreed to wear the oral appliance. The purpose of the study and details involved in the procedure were first explained to the patients. Fourteen patients who volunteered and provided written informed consent were included in the study. The study was approved through an institutional reviewing process. The average age of 12 males and two females was 50 years  $\pm$  16 (mean  $\pm$  standard deviation), and the average body mass index (BMI = kg/m<sup>2</sup>) was 25.1  $\pm$  3.0.

All participating patients whose apnea-hypopnea index (AHI) was higher than 5 and arousal index higher than 20 were invited to a second overnight sleep study for titration of nasal CPAP and oral appliance. Nasal CPAP was first used for the initial five hours, followed by oral appliance for the next three hours. Approximately one hour of wash-out and adjustment period was included according to the attending sleep physician's discretion. Compared with the first baseline polysomnogram, no drastic changes in sleep time and body posture were noted in any participant. When CPAP and oral appliance were compared, no significant differences in sleep stages and body posture were observed.

Lateral cephalograms and cine CTs were obtained in accordance with the protocol. The appliance, constructed of orthodontic acrylic resin, positioned the mandibular incisors 1–2 mm further forward from the edge-to-edge bite of the upper and lower anterior incisors. This amount approximates 75% of maximum mandibular advancement that is expected to yield the best treatment outcome with the least adverse effects.<sup>38</sup> Patients showing an excessive vertical opening due to deep overbite were precluded from the study. To avoid any adverse effects in the jaw joint, the amount of protrusion was determined by an orthodontist.<sup>24</sup>

### Cephalometry

A pair of lateral cephalometric radiograms was taken with and without the oral appliance. The incisal edge of the lower central incisors was used as a marker to monitor the position of the mandible. The lateral cephalometric films were superimposed on the Frankfort Horizontal (FH) plane, and the horizontal and vertical differences between anatomical structures with and without the appliance in place were measured, as shown in Figure 1.



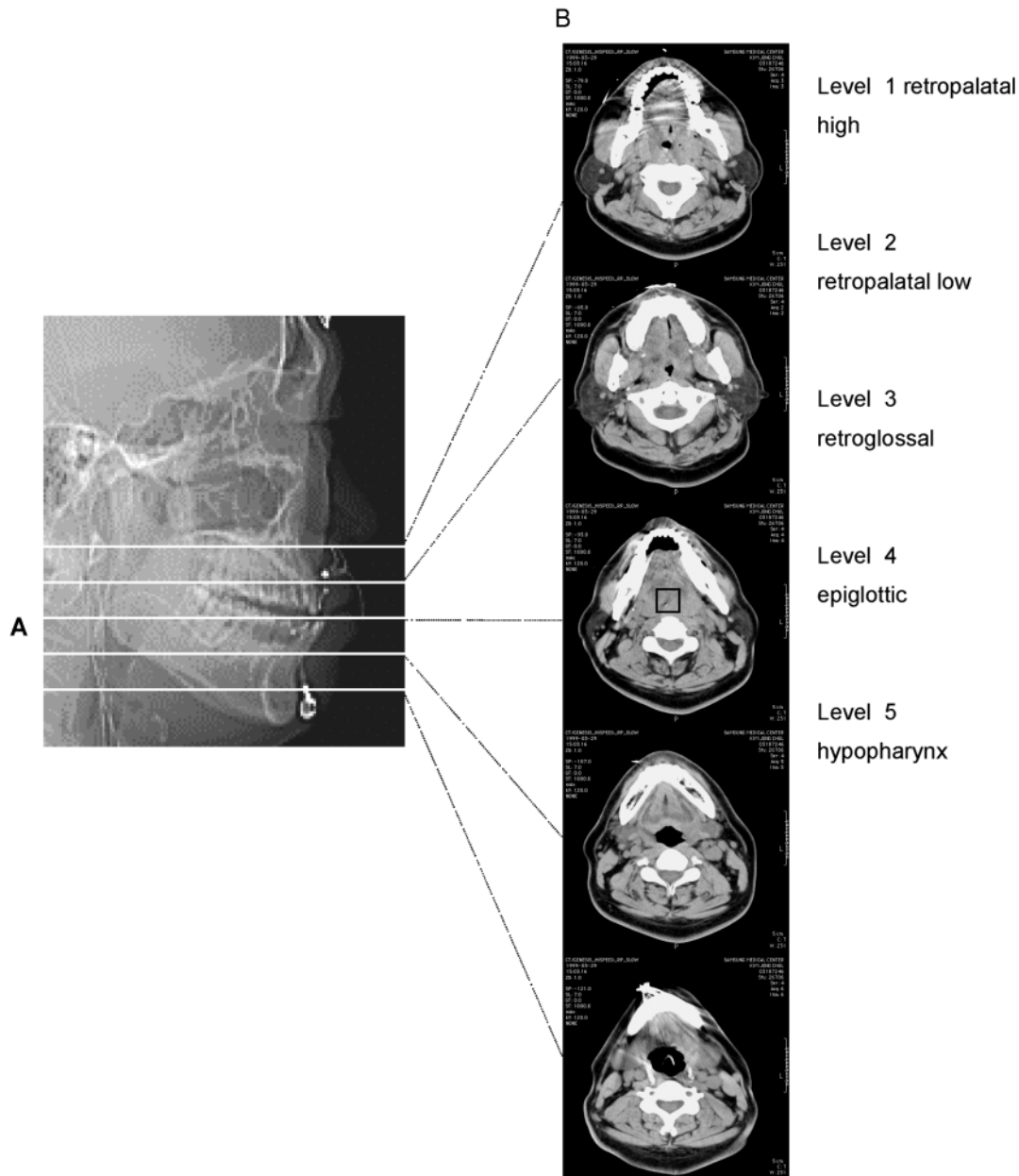
**FIGURE 1.** Lateral cephalograms without (A) and with (B) the oral appliance in place. FH (Frankfort Horizontal) plane denoted by solid lines in the panels A and B connects the cephalometric landmarks porion (upper most part of the external meatus) and orbitale (bottom most part of the orbit). Panel C shows a normal bite. Panel D displays acrylic pieces for the maxillary and mandibular teeth. Panel E shows an assembled oral appliance in the mouth.

### Cine-CT evaluation

The patients adjusted their pillows to find the most comfortable neutral head position close to their habitual sleep position without having their heads excessively flexed or extended. They were instructed to breathe normally through the nose. At the initiation of scanning, they were instructed not to move the head until completion of two respiratory cycles. Seven-millimeter-thick slices were obtained at five different levels between the retropalatal high (level 1) and the hypopharynx (level 5) regions. Levels between level 1 and 5 include retropalatal low (level 2), retroglossal (level 3), and epiglottic (level 4) levels, as shown in Figure 2.

CT imaging was performed using the single-detector-row CT scanner (HiSpeed Advantage; General Electric Medical Systems, Milwaukee, Wisc) both with and without the appliance. Ten CT images were taken for 10 seconds in each session. Each image includes five levels; therefore, a total of 100 images (50 with and 50 without the appliance) during approximately two respiratory cycles per patient were obtained.

The computer-stored images were displayed on a monitor, and a mouse was used to digitize the lumen of the pharynx. A clear outline was observed first. If irregularities found on the margin were difficult to define, areas 0.5 mm<sup>2</sup> or less in size were ignored. The cross-sectional area of the lumen (Cs, unit: mm<sup>2</sup>) and diameters in the lateral (Cx, unit: mm) and sagittal (Cy, unit: mm) planes were measured using imaging-process software (PACS; PathSpeed Workstation, General Electric Medical Systems). The same investigator performed the measurements to avoid interexaminer



**FIGURE 2.** Computerized-tomography images obtained at five different anatomic levels designated in panel A. The five images on the right side (B) were obtained during apnea. Note that level 3 (retroglossal) demonstrates a complete closure of the airway during sleep as indicated in the box.

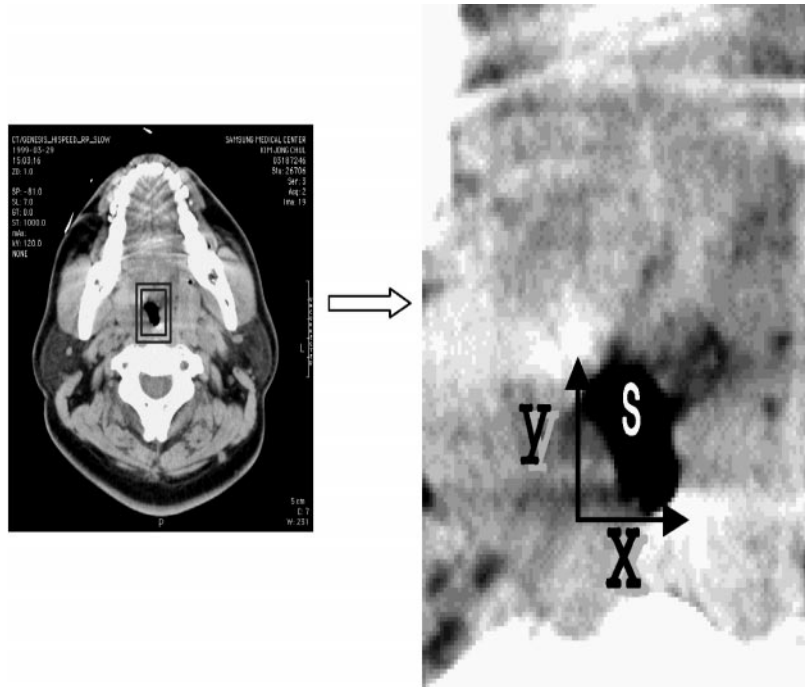
errors (Figure 3). In addition, we obtained a full set of CTs during an apneic period from eight of the subjects. The Student's *t*-tests (paired-samples) and simple correlation tests were used for statistical comparison on mean values and association inferences.

## RESULTS

Cephalograms showed that the mandible moved 7.1 mm forward ( $7.11 \pm 1.93$  mm) and 7.7 mm downward ( $7.70 \pm 2.47$ ) from the maximum habitual bite with the oral appliance in place (Figure 1). Sleep data are shown in Table

1 and Figure 4. The appliance reduced the AHI of patients from an average of 44.9 to 10.9. Associations between the amounts of mandible protrusion by the appliance, the average area changes of each level, and improvement in AHI were also studied, but none of the correlations reached statistical significance.

To investigate the pharyngeal region most involved in apnea, an area-graph (Figure 5) was plotted on the basis of the CT measurements obtained from eight subjects during apnea, ie, complete airway occlusion as illustrated in Table 2. This data set during apnea was collected separately, thus,



**FIGURE 3.** Three measurements on a computerized tomogram. S indicates areas of the upper airway. X indicates the greatest lateral dimension of the upper airway. Y indicates the greatest anteroposterior (sagittal) dimension of the upper airway.

**TABLE 1.** Comparisons of Measurements of Polysomnographic Data with and without Oral Appliances<sup>a</sup>

	Without Appliance Mean ± SD	With Appliance Mean ± SD	Significance Level
Apnea index	25.3 ± 24.1	6.3 ± 19.5	*
Hypopnea index	19.5 ± 13.5	4.5 ± 8.3	**
AHI	44.9 ± 27.2	10.9 ± 23.2	***
Arousal index	56.3 ± 22.6	23.5 ± 19.7	***
SaO <sub>2</sub>	82.9 ± 8.3	90.6 ± 9.2	*

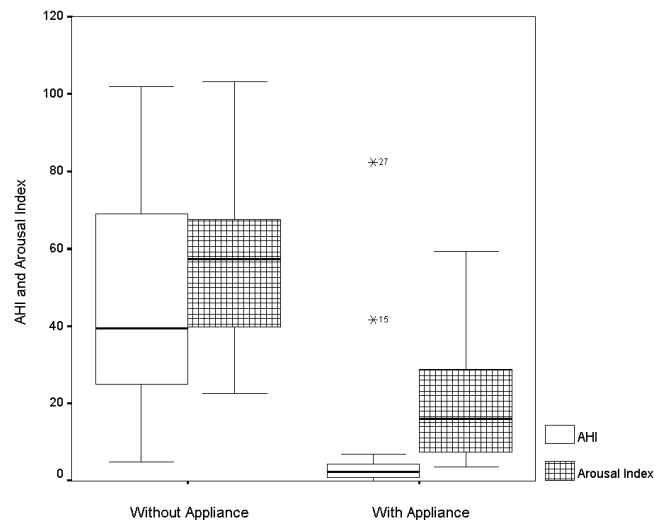
<sup>a</sup> AHI indicates Apnea Hypopnea Index; SD, standard deviation; SaO<sub>2</sub> Oxygen saturation level in artery.

\*  $P < .05$ ; \*\*  $P < .01$ ; \*\*\*  $P < .001$ .

it was not included in the main data set that was obtained during wakefulness. Figure 5 shows that occlusion occurs at levels 2 and 3 more than in other regions. The Cx of the pharyngeal measurements increased significantly with the appliance at levels 1, 2, and 3 (Table 3) during wakefulness ( $P < .05$ ). The Cy increased slightly but significantly at level 3 from 16.1 to 17.5 mm. The Cs increased significantly at level 1 ( $P < .05$ ), 2 ( $P < .05$ ), and 3 ( $P < .01$ ). When changes in two dimensions were compared, the change in lateral (Cx) direction was significantly greater than that in sagittal direction (Cy) ( $P < .05$ ) at levels 1 and 3.

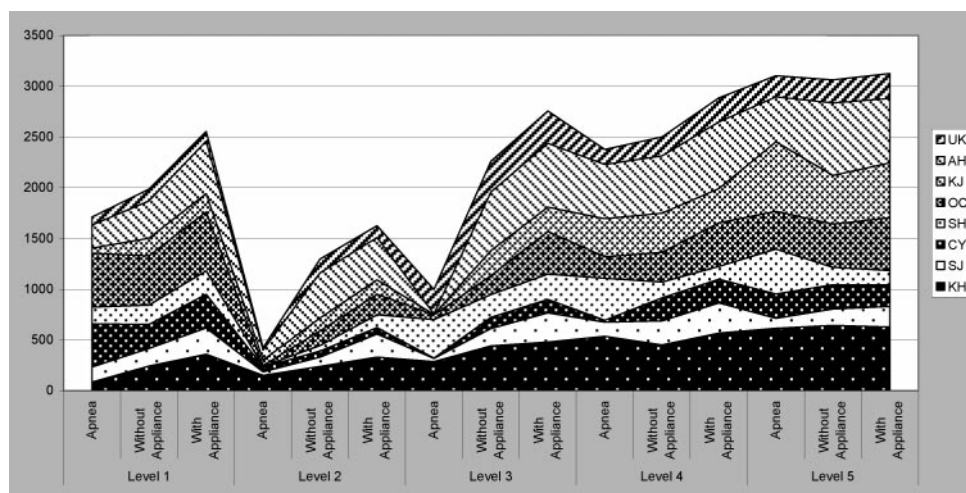
### DISCUSSION

Previous studies reported that OSA patients have a laterally narrowed pharyngeal airway, whereas non-OSA sub-



**FIGURE 4.** Changes in apnea-hypopnea index and arousal index with the oral appliance in place. Patient number 27 and 15 with appliance in the plot indicate outliers, which were not calculated into the means. Note that mean values differ from those shown in Table 1.

jects display a laterally wide pharyngeal lumen.<sup>34</sup> Our OSA patients appear to have a laterally wide Cx similar to the normal group of other previous studies. This lateral narrowing could explain the size difference between OSA patients and non-OSA subjects. However, a recent study by Ciscar et al<sup>39</sup> reported that the long-axis diameter of the laterally widened velopharynx measured in awake subjects is greater than that measured in sleeping subjects, which agrees with our observations.



**FIGURE 5.** Changes of the pharyngeal cross-sectional area during apnea, without and with the oral appliance in eight patients. Y-axis denotes accumulated numbers for the pharyngeal cross-sectional area of each patient.

When we evaluated changes of the lumen by measuring the Cx and the Cy, Cx increased at the retropalatal high, retropalatal low, and retroglottal levels, the Cy (sagittal change) was statistically significant at level 3 (retroglottal level) only, suggesting that the appliance widens a pharyngeal lumen laterally but not sagittally in OSA patients. This observation was underpinned by the results of the comparison study between the change in lateral direction and sagittal direction. The findings also suggest that cephalometric two-dimensional images of the oropharynx in the sagittal direction require careful interpretation.

At the retroglottal level, Cx showed a significant increase from 23.2 to 26.5 mm ( $P = .03$ ), and Cy increased from 16.1 to 17.5 mm ( $P = .02$ ). At this level, both Cx and Cy diameters increased. The clinical significance of the 1.4-mm increase in Cy may require further investigation. Some reports<sup>40</sup> show an increase in Cy in the soft palate but not in the tongue base area. As was shown in Table 3 and Figure 5, either with or without the appliance, level 2 (retropalatal low) is the narrowest area along the pharynx. Some studies reported that oral appliances increase the posterior airway space at the velopharyngeal level (our level 2),<sup>41</sup> whereas others report change at the oropharyngeal level (our level 3).<sup>42</sup> In our studies, no significant differences below the epiglottis were found, ie, the retroglottal or more rostral levels were most affected by the appliance.

Most participants responded favorably to the appliance therapy except for the two patients indicated in Figure 4. These two individuals have AHI of 102.2 and 70.1 without the appliance and still show high AHIs of 82.4 and 41.8 with the appliance in place. When Cs changes at levels 1, 2, and 3 of these two patients (\*27 and \*15 in Figure 4) were compared between with and without appliance, no difference was noted in the first patient (\*27), but a marked change (an increase of 146.5 mm<sup>2</sup> at level 3) was noted in the second patient (\*15). This may suggest that cross-sectional

size changes of the pharynx with an oral appliance would not occur in some severe patients.

Fluoroscopy studies<sup>43,44</sup> reported that obstruction first occurs when the soft palate touches the posterior pharyngeal wall (hooking) and the dorsal surface of the tongue during inspiration. Subsequently, the soft palate and surrounding structures appear to be sucked down (plugging) caudally. At the same time, the pharyngeal airway below the soft palate is progressively narrowed and closed. Previous studies suggest that the “hooking” and “plugging” of the soft palate are often associated with opening of the jaw. We observed that airway occlusion began at the retropalatal (low) and retroglottal level, progressing into the hypopharynx. Kato et al<sup>29</sup> suggested that closing pressure at the velopharynx and oropharynx significantly decreased with mandibular advancement under general anesthesia in a dose-dependant fashion. They also demonstrated that mandibular advancement normalized the pressure cross-sectional area relation of the oropharynx in both obese and non-obese OSA patients<sup>28</sup>. Therefore, if the appliance prevents initial obstruction by moving the tongue base forward, it could prevent the obstruction further downstream in the pharynx and provide a mechanism whereby the oral appliance improves OSA.

Our studies show that the amounts of jaw opening, anatomical changes of the naso- and oropharynx, and the changes in apnea-hypopnea indices are not significantly correlated. A recent study reported that, independent of oral appliances, relative pharyngeal area was reduced by more than 50% in the supine position compared with the upright position.<sup>45</sup> This suggests that maintaining airway size in the supine position with the oral appliance may be related to mechanical quality of the upper airway muscles.<sup>46</sup> Individual anatomical heterogeneity in the patient group may also account for these results.

Although the current study did not synchronize the tim-

**TABLE 2.** Changes in Cross Sectional Area Measurements during Apnea, without and with Appliance at Each Level in Eight Volunteers<sup>a</sup>

Name		Level 1 (Retropalatal High)	Level 2 (Retropalatal Low)	Level 3 (Retroglossal)	Level 4 (Epiglottis)	Level 5 (Hypopharynx)
K.H.	Apnea	82.4	146.9	284.6	535.5	615.0
	Without appliance	241.7 ± 14.46	237.1 ± 17.27	439.2 ± 12.18	449.7 ± 24.95	640.7 ± 14.85
	With appliance	359.1 ± 54.30	329.5 ± 33.4	479.7 ± 8.47	566.7 ± 42.68	627.5 ± 30.12
S.J.	Apnea	149.4	39.2	31.4	138.2	95.7
	Without appliance	173.5 ± 6.29	91.2 ± 5.67	168.9 ± 10.2	236.4 ± 14.94	163.2 ± 16.52
	With appliance	257.7 ± 7.33	226.5 ± 10.91	285.3 ± 26.31	296.3 ± 13.85	202.7 ± 12.19
C.Y.	Apnea	427.1	46.1	3.0	20.0	241.9
	Without appliance	236.5 ± 6.01	61.9 ± 5.99	112.4 ± 27.06	227.5 ± 10.88	238.8 ± 6.72
	With appliance	332.3 ± 12.35	63.5 ± 4.32	130.8 ± 8.96	233.4 ± 10.03	208.2 ± 5.81
S.H.	Apnea	162.2	7.0	381.2	411.7	443.0
	Without appliance	189.2 ± 17.50	51.9 ± 8.78	223.1 ± 14.78	155.2 ± 27.13	172.0 ± 10.19
	With appliance	230.2 ± 29.60	127.5 ± 9.67	253.8 ± 9.17	125.7 ± 9.32	143.42 ± 10.46
O.C.	Apnea	531.4	9.4	45.6	213.8	372.1
	Without appliance	487.782 ± 13.09	145.9 ± 16.52	190.2 ± 52.83	294.8 ± 14.86	426.7 ± 37.82
	With appliance	581.792 ± 23.22	202.8 ± 32.93	420.1 ± 53.19	429.9 ± 18.60	521.8 ± 17.57
K.J.	Apnea	51.5	50.3	2.2	375.0	684.7
	Without appliance	173.4 ± 16.56	125.6 ± 58.53	243.9 ± 27.22	384.993 ± 48.05	479.094 ± 39.67
	With appliance	178.8 ± 18.81	140.6 ± 49.63	238.8 ± 12.23	338.9 ± 21.97	538.3 ± 133.13
A.H.	Apnea	255.2	101.6	5.9	534.3	441.8
	Without appliance	363.8 ± 29.42	445.3 ± 44.67	579.1 ± 34.20	565.9 ± 15.01	713.9 ± 36.15
	With appliance	518.0 ± 28.97	417.3 ± 16.41	628.3 ± 30.04	657.6 ± 23.74	636.5 ± 20.03
U.K.	Apnea	78.9	20.5	242.9	149.1	210.5
	Without appliance	119.5 ± 8.82	137.2 ± 19.4	300.8 ± 19.04	184.5 ± 16.33	227.7 ± 11.84
	With appliance	95.8 ± 4.86	116.2 ± 20.25	319.0 ± 12.56	236.7 ± 6.73	244.4 ± 10.89

<sup>a</sup> Units are in mm<sup>2</sup>.

**TABLE 3.** Comparisons between Measurements with and without the Appliance at Each Level of the Airway<sup>a</sup>

	Without Appliance		With Appliance	
	Mean	SD <sup>b</sup>	Mean	SD
Level 1 (retropalatal high)				
Cx	19.3	4.2	23.3	9.4*
Cy	16.7	6.4	16.9	5.6
Cs	224	104	296	171*
Level 2 (retropalatal low)				
Cx	17.9	10.7	20.1	11.6*
Cy	13.1	6.7	16.4	8.3
Cs	151	129	183.6	130.3*
Level 3 (retroglossal)				
Cx	23.2	8.2	26.5	10.3*
Cy	16.1	4.1	17.5	4.7*
Cs	253	136	300.4	154.1*
Level 4 (epiglottis)				
Cx	28.2	6.91	29.5	8.1
Cy	16.2	4	16.7	3.8
Cs	315	127	335.5	157.7
Level 5 (hypopharynx)				
Cx	30.4	7.9	31.2	8.8
Cy	18	6.7	18.8	6.0
Cs	362	189	378.6	179.6

<sup>a</sup> Cx indicates lateral dimension (mm); Cy, sagittal dimension (mm); and Cs, cross sectional area (mm<sup>2</sup>).

<sup>b</sup> SD indicates standard deviation.

\* Significant at  $P < .05$ .

ing of CTs to the same breathing stage on every patient, measurements obtained from 10 images at each level during two respiratory cycles should have provided a robust averaging effect. When the mandible is guided to a protrusive position, the amount of vertical opening of the lower jaw is affected by the amount of vertical overlap of the upper and lower anterior teeth. Thus, the vertical opening rather than horizontal protrusion of the lower jaw due to an anterior bite-depth would not open the hypopharynx enough. This could be the reason why the appliance did not induce significant changes in level 4 (epiglottis) and level 5 (hypopharynx).

Within the limitations of the study, we demonstrate that the oral appliance appears to change the geometry of pharyngeal conduit. The cross-sectional area increased at both retropalatal high and retropalatal low levels because of an increase in lateral direction. The increase in both lateral and sagittal dimensions at the retroglossal level resulted in an increase of cross-sectional area.

## CONCLUSIONS

We conclude that airway enlargement in the lateral dimension may play a role in the mechanism of the oral appliance in reducing OSA.

## REFERENCES

1. Peker Y, Hedner J, Norum J, Kraiczi H, Carlson J. Increased incidence of cardiovascular disease in middle-aged men with ob-

- structive sleep apnea. A 7-year follow-up. *Am J Respir Crit Care Med.* 2002;166:159–165.
2. Von Kanel R, Dimsdale JE. Hemostatic alterations in patients with obstructive sleep apnea and the implications for cardiovascular disease. *Chest* 2003;124(5):1956–1967.
  3. Shamsuzzaman AS, Gersh BJ, Somers VK. Obstructive sleep apnea: implications for cardiac and vascular disease. *JAMA* 2003;290(14):1906–1914.
  4. Davies CW, Crosby JH, Mullins RL, Traill ZC, Anslow P, Davies RJ, Stradling JR. Case control study of cerebrovascular damage defined by magnetic resonance imaging in patients with OSA and normal matched control subjects. *Sleep* 2001;24(6):715–720.
  5. Young T, Peppard P, Gottlieb DJ. Epidemiology of obstructive sleep apnea. *Am J Respir Crit Care Med.* 2002;165:1217–1239.
  6. Cistulli PA, Sullivan CE. Pathophysiology of sleep apnea. In: Sullivan CE, Saunders NA, eds. *Sleep and Breathing*. 2nd ed. New York, NY: Marcel Dekker; 1994:405–488.
  7. Harding SM. Complications and consequences of obstructive sleep apnea. *Curr Opin Pulm Med.* 2000;6:485–489.
  8. Barnes M, Houston D, Worsnop CJ, et al. A randomized controlled trial of continuous positive airway pressure in mild obstructive sleep apnea. *Am J Respir Crit Care Med.* 2002;165:773–780.
  9. Malhotra A, Ayas NT, Epstein LJ. The art and science of continuous positive airway pressure therapy in obstructive sleep apnea. *Curr Opin Pulm Med.* 2000;6:490–495.
  10. Wade PS. Oral appliance therapy for snoring and sleep apnea: preliminary report on 86 patients fitted with an anterior mandibular positioning device, the Silencer. *J Otolaryngol.* 2003;32(2):110–113.
  11. Ng AT, Gotsopoulos H, Qian J, Cistulli PA. Effect of oral appliance therapy on upper airway collapsibility in obstructive sleep apnea. *Am J Respir Crit Care Med.* 2003;168(2):238–241. Epub April 30, 2003.
  12. Tan YK, L'Estrange PR, Luo YM, Smith C, Grant HR, Simonds AK, Spiro SG, Battagel JM. Mandibular advancement splints and continuous positive airway pressure in patients with obstructive sleep apnea: a randomized cross-over trial. *Eur J Orthod.* 2002;24:239–249.
  13. Walker-Engstrom ML, Tegelberg A, Wilhelmsson B, Ringqvist I. 4-year follow-up of treatment with dental appliance or uvulopalatopharyngoplasty in patients with obstructive sleep apnea: a randomized study. *Chest* 2002;121:739–746.
  14. Johnston CD, Gleadhill IC, Cinnamon MJ, Gabbey J, Burden DJ. Mandibular advancement appliances and obstructive sleep apnea: a randomized clinical trial. *Eur J Orthod.* 2002;24:251–262.
  15. Petit FX, Pepin JL, Bettega G, Sadek H, Raphael B, Levy P. Mandibular advancement devices: rate of contraindications in 100 consecutive obstructive sleep apnea patients. *Am J Respir Crit Care Med.* 2002;166:274–278.
  16. Mehta A, Qian J, Petocz P, Darendeliler A, Cistulli PA. A randomized, controlled study of a mandibular advancement splint for obstructive sleep apnea. *Am J Respir Crit Care Med.* 2001;163:1457–1461.
  17. Liu Y, Lowe AA, Fleetham JA, Park YC. Cephalometric and physiologic predictors of the efficacy of an adjustable oral appliance for treating obstructive sleep apnea. *Am J Orthod Dentofacial Orthop.* 2001;120:639–647.
  18. Sin DD, Mayers I, Godfrey CWM, Pawluk L. Long-term compliance rates to continuous positive airway pressure in obstructive sleep apnea. *Chest* 2002;121:430–435.
  19. Miller FR, Watson D, Malis D. Role of the tongue base suspension suture with The Repose System bone screw in the multilevel surgical management of obstructive sleep apnea. *Otolaryngol Head Neck Surg.* 2002;126:392–398.
  20. Bettega G, Pepin J-L, Veale D, Deschaux C, Raphael B, Levy P. Obstructive sleep apnea syndrome. Fifty-one consecutive patients treated by maxillofacial surgery. *Am J Respir Crit Care Med.* 2000;162:641–649.
  21. Li KK, Riley RW, Powell NB, Guilleminault C. Maxillomandibular advancement for persistent obstructive sleep apnea after phase I surgery in patients without maxillomandibular deficiency. *Laryngoscope* 2000;110:1684–1688.
  22. Walker-Engstrom ML, Wilhelmsson B, Tegelberg A, Dimenas E, Ringqvist I. Quality of life assessment of treatment with dental appliance or UPPP in patients with mild to moderate obstructive sleep apnoea. A prospective randomized 1-year follow-up study. *J Sleep Res.* 2000;9:303–308.
  23. Ringqvist M, Walker-Engstrom ML, Tegelberg A, Ringqvist I. Dental and skeletal changes after 4 years of obstructive sleep apnea treatment with a mandibular advancement device: a prospective, randomized study. *Am J Orthod Dentofacial Orthop.* 2003;124:53–60.
  24. Lindman R, Bondemark L. A review of oral devices in the treatment of habitual snoring and obstructive sleep apnea. *Swed Dent J.* 2001;25:39–51.
  25. Gale DJ, Sawyer RH, Woodcock A, Stone P, Thompson R, O'Brien K. Do oral appliances enlarge the airway in patients with obstructive sleep apnea? A prospective computerized tomographic study. *Eur J Orthod.* 2000;22:159–168.
  26. Robin P. Glossoptosis due to atresia and hypotrophy of the mandible. *Am J Dis Child.* 1934;48:541–547.
  27. Adachi S, Lowe AA, Tsuchiya M, Ryan CF, Fleetham JA. Genioglossus muscle activity and inspiratory timing in obstructive sleep apnea. *Am J Orthod Dentofacial Orthop.* 1993;104(2):138–145.
  28. Isono S, Tanaka A, Tagaito Y, Sho Y, Nishino T. Pharyngeal patency in response to advancement of the mandible in obese anesthetized persons. *Anesthesiology* 1997;87:1055–1062.
  29. Kato J, Isono S, Tanaka A, Watanabe T, Araki D, Tanzawa H, Nishino T. Dose-dependent effects of mandibular advancement on pharyngeal mechanics and nocturnal oxygenation in patients with sleep-disordered breathing. *Chest* 2000;117:1065–1072.
  30. Smith SD. A three-dimensional airway assessment of the treatment of snoring and/or sleep apnea with jaw repositioning intraoral appliances: a case study. *Cranio* 1996;14:332–343.
  31. Ell SR, Jolles H, Keyes WD, Galvin JR. Cine CT technique for dynamic airway studies. *AJR Am J Roentgenol.* 1985;145:35–36.
  32. Galvin JR, Rooholamini SA, Stanford W. Obstructive sleep apnea: diagnosis with ultrafast CT. *Radiology* 1989;171:775–778.
  33. Shepard JW Jr, Stanson AW, Sheedy PF, Westbrook PR. Fast-CT evaluation of the upper airway during wakefulness in patients with obstructive sleep apnea. *Prog Clin Biol Res.* 1990;345:273–279.
  34. Schwab RJ, Gupta KB, Gefter WB, Metzger LJ, Hoffman EA, Pack AI. Upper airway and soft tissue anatomy in normal subjects and patients with sleep-disordered breathing. *Am J Respir Crit Care Med.* 1995;152:1673–1689.
  35. Oksenberg A, Khamaysi I, Silverberg DS. Apnoea characteristics across the night in severe obstructive sleep apnoea: influence of body posture. *Eur Respir J.* 2001;18:340–346.
  36. Pae E, Lowe AA, Sasaki K, Fleetham JA, Price C, Tsuchiya M. A cephalometric and electromyographic study of upper airway structures in the upright and supine position. *Am J Orthod Dentofacial Orthop.* 1994;106:52–59.
  37. Schwab RJ. Imaging for the snoring and sleep apnea patient. *Dent Clin North Am.* 2001;45:759–796.
  38. Walker-Engstrom M-L, Ringqvist I, Vestling O, Wilhelmsson B, Tegelberg A. A prospective randomized study comparing two different degrees of mandibular advancement with a dental appliance in treatment of severe obstructive sleep apnea. *Sleep Breath.* 2003;7:119–130.

39. Ciscar MA, Juan G, Martinez V, et al. Magnetic resonance imaging of the pharynx in OSA patients and healthy subjects. *Eur Respir J*. 2001;17:79–86.
40. Bonham PE, Currier GF, Orr WC, Othman J, Nanda RS. The effect of a modified functional appliance on obstructive sleep apnea. *Am J Orthod Dentofacial Orthop*. 1988;94:384–392.
41. Schmidt-Nowara WW, Meade TE, Hays MB. Treatment of snoring and obstructive sleep apnea with a dental orthosis. *Chest* 1991;99:1378–1385.
42. Ferguson KA, Love LL, Ryan F. Effect of mandibular and tongue protrusion on upper airway size during wakefulness. *Am J Respir Crit Care Med*. 1997;155:1748–1754.
43. Suratt PM, Dee P, Atkinson RL, Armstrong P, Wilholt SC. Fluoroscopic and computed tomographic features of the pharyngeal area in obstructive sleep apnea. *Am Rev Respir Dis*. 1983;127:487–492.
44. Pepin JL, Ferretti G, Veale D, Romand P, Coulomb M, Brambilla C, Levy PA. Somnofluoroscopy, computed tomography and cephalometry in the assessment of the air way in obstructive sleep apnea. *Thorax* 1992;47:150–156.
45. Fransson AM, Svenson BA, Isacsson G. The effect of posture and a mandibular protruding device on pharyngeal dimensions: a cephalometric study. *Sleep Breath*. 2002;6:55–68.
46. Veldi M, Vasar V, Hion T, Vain A, Kull M. Myotonometry demonstrates changes of lingual musculature in obstructive sleep apnea. *Eur Arch Otorhinolaryngol*. 2002;259:108–112.