J Korean Soc Ultrasound Med
2004;24:123-130

The Benefit of Sonography in Pregnancy-associated Breast Cancer

Eun Ju Son, M.D., Ki Keun Oh, M.D., Eun Kyung Kim, M.D

Department of Diagnostic Radiology, Yonsei University, College of Medicine

= Abstract =

PURPOSE : To evaluate the sonographic, mammographic and MRI features of pregnancy-associated breast cancer with the major focus on the sonographic benefit in a diagnosis of pregnancy-associated breast cancer.

MATERIALS and METHODS : From 1998 to 2002, sonography was performed on a total 7 patients (age 23 to 38 years), who were pathologically diagnosed with breast cancer during pregnancy. Six of those patients underwent mammography. Five patients underwent a breast MRI, preoperatively. The radiological findings were evaluated retrospectively. Six patients underwent surgery and 1 patient underwent a core biopsy and chemotherapy. The histological, nuclear grading and pathological staging were evaluated.

RESULTS : The sonographic findings showed a mass with irregular shapes (n=6), irregular margins (n=6), a non-parallel orientation (n=5), complex echo patterns (n=5). Associated findings could be observed in 3 patients, including Cooper's ligament thickening (n=2), edema (n=2), skin thickening (n=1) and axillary lymphadenopathy (n=3). The sonographic findings were positive and showed masses in 6 patients. All the patients had a dense breast in mammography. The mammographic findings included masses (n=4), masses with microcalcifications (n=2), masses with axillary lymphadenopathy (n=3), calcifications alone (n=1), an asymmetric density alone (n=1), extremely dense breasts with negative findings (n=2). A breast MRI showed an irregular shaped mass (n=4) with a rim-like enhancement (n=3), linear ductal enhancement without a mass (n= 1), and the time intensity cure revealed the typical pattern and level of enhancement in the carcinoma.

CONCLUSION : Sonography is a valuable tool for diagnosing pregnancy-associated breast cancer. However, mammography should be performed if there is a suspicious lesion on sonography in order to confirm the pregnancy-associated breast cancer. Mammography has a lower sensitivity during pregnancy due to the physiologic changes in the breasts. However, calcifications and associated findings are helpful in confirming pregnancy-associated breast cancer. physicians

논문접수 : 2005년 2월 21일, 수정제의 : 2005년 3월 14일, 수정논문접수 : 2005년 3월 28일, 논문게제결정 : 2005년 5월 10일
Address for reprints : Ki Keun Oh, M.D., Department of Diagnostic Radiology, Yongdong Severance Hospital, Yonsei University College of Medicine, #146-92 Dokok-dong, Kangnam-Gu, Seoul, 135-270, Korea.
Tel. 82-2-2019-3510 Fax. 82-2-3462-5472 E-mail: kbrrdoh@yumc.yonsei.ac.kr

should not consider a rapidly growing lump in the breast during pregnancy to be benign and should perform radiological examinations and imaging-guided biopsies.

Index Words : Breast neoplasms, US
Breast radiography
Pregnancy

Introduction

One to two percent of all breast cancers occur during pregnancy or lactation [1, 2]. Breast cancer is believed to be associated with a pregnancy if the diagnosis is made during or within 1 year after a pregnancy. One study reported at least 15% of patients with breast cancer younger than age 40 years and another reported that 25% of patients with breast cancer younger than age 35 years were pregnancy related [3, 4].

Striking changes take place in the mammary glands during pregnancy and lactation. The ductal-lobular-alveolar system undergoes considerable hypertrophy and prominent lobules are formed [5]. The intense hormonal environment causes the breasts to increase in volume and firmness . The physiological changes associated with pregnancy make the detection and evaluation of breasts masses quite difficult. These changes cause the breasts to become denser during pregnancy, which lower the sensitivity of the mammogram. In addition, there is some controversy regarding the safety of mammography during pregnancy or lactation. Previous reports showed some concern regarding the role of the mammography during pregnancy. However, the sonography could be more valuable for evaluating a breast mass during this period because sonography is safe and most masses can be detected. According to the literature, the radiological findings of pregnancy-associated breast cancer are non-specific and do not differ significantly from the findings of cancer in non-pregnant women. The aim of this study was to evaluate the efficacy of sonography in examining pregnancy-associated breast cancer, and to compare the results with those obtained from mammography with the main focus on the early diagnosis of pregnancy-associated breast cancer using ultrasonography.

Materials and Methods

During the past 5 years (1998 to 2002), a total of 7 patients (age, 28 to 35 years, mean 33 years) were pathologically diagnosed with breast cancer during pregnancy (PABC) at our institute. Sonography was performed on all the patients, and 6 patients underwent subsequent mammography. A breast MRI was performed for cancer staging and to evaluate the multifocality. Five patients underwent a preoperative breast MRI. The three radiologists evaluated the radiological findings. The sonographic images were assessed for the presence of solid masses. If there were masses, their shapes, margins, orientations, echo patterns, posterior acoustic features, and the effects on the surrounding tissue, were recorded according to the ACR BI-RADS ultrasound lexicon [6]. The density of the parenchyma on mammography was classified according to the American College of Radiology (ACR) Breast Imaging Reporting and Data System (BI-RADS). The mammographic findings were analyzed in order to establish the presence of a mass, calcifications and any associated findings. The shape, margin of the mass and morphology, as well as the distribution of the calcifications were evaluated according to the BI-RADS criteria. The MRI findings of the shape and margin of the mass, the enhancement pattern and the time-intensity curve as well as the morphology of the enhancement were also evaluated. Six patients underwent surgery and 1 patient underwent a core biopsy and chemotherapy. The histological, nuclear grade and pathological staging were then evaluated.

Results

Six of the patients complained of a palpable mass (n=6), combined skin thickening (n=1), and palpable axillary lymphadenopathy (n=2). All seven patients were

pregnant and their intrauterine period ranged from 8 to 36 weeks (mean 21 weeks). Five patients had an induced abortion and 2 patients delivered prior to surgery or chemotherapy. The sonographic findings were positive and showed masses in 6 patients. The sonographic findings were as follows: a mass with an irregular shape (n=6), irregular margins (n=6), non-parallel orientation (n=5), complex echo patterns (n=5) relatively ill-defined margin with lack of spiculation (n=5). Associated findings were noted in 3 patients, which included Cooper's ligament thickening (n=2), edema (n=2), skin thickening (n=1) and axillary lymphadenopathy (n=3). Mammography showed that all 6 patients had dense breast parenchyma. The mammographic findings included masses (n=4), masses with microcalcifications (n=2), mass with axillary lymphadenopathy (n=3), calcifications alone (n=1), and asymmetric density alone (n=1), extremely dense breasts with negative findings (n=2) (Fig. 1C). One patient without symptoms had undergone a side mammogram taken 2 weeks earlier and was unaware that she was pregnant at the time. The magnification view was performed and there was clustered microcalcifications but the breast ultrasound was negative. The breast MRI showed an irregular shaped mass (n=4) with a rim-like enhancement (n=3) (Fig. 2D), and a linear ductal enhancement without a mass (n= 1). In addition, the time intensity curve showed a typical pattern and the level of enhancement in the carcinoma.

The pathological diagnoses of the PABC were invasive ductal carcinoma (n= 6) and ductal carcinoma in-situ with a microinvasion (n=1). Metastatic axillary lymph nodes were positive in 5 patients and 1 patient had a distant metastasis to the lung and spine. The nuclear grading for the 7 patients was 2 (n=2) and 3 (n=5), and the histological grading were II (n=4) and III (n=2) and one DCIS case was found to be Van-Nuys group 3.

Six patients underwent a modified radical mastectomy, and the pathological staging was IV in 2 patients, III in 3 patients, II in 1 patient and I in 1 patient. Only 1 patient showed a pathologically lymph node negative state.

Table 1 lists the radiological findings and histopathology results.

Discussion

One to two percent of all breast cancers occur during pregnancy or lactation. The incidence of PABC appears to have increased over the past several years, possibly because more women are becoming pregnant in their 30s and 40s, and the incidence of breast cancer increases with age [7]. Many studies have reported a poor prognosis for patients with PABC. However, more recently, several investigators have shown no statistically significant difference in the mortality rates between the patients with PABC and patients with non-PABC [8]. The advanced stage of PABC at diagnosis creates difficulties in evaluating the breasts during and shortly after pregnancy [9]. According to Liberman L. et al [9], the sensitivity of mammography in detecting PABC was 78 %. They also reported that the sensitivity is reduced

Table 1. The Imaging Findings and Pathological Features of the Pregnancy-associated Breast Cancer

Case	Age (years)	IUP (weeks)	Sx Du (weeks)	US*	XM*	MRI*	Path	Tumor Size (cm)	Ax LN	NG**	HG**
1	31	10	4	4	0	5	IDCa	2.0	(+)	2	II
2	32	12	6	5	1	5	IDCa	1.6	(+)	3	II
3	31	21	6	4	1	5	IDCa	2.4	(+)	2	III
4	31	8	-	1	4	4	DCIS	3.8	(-)	3	***
5	35	36	10	5	5	5	IDCa	2.5	(+)	3	III
6	33	16	9	4	0	-	IDCa	1.8	(-)	3	II
7	28	34	12	5	-	-	IDCa	4.6	(+)	3	III

* Numbers presented the BI-RADS category of each imaging findings

** Nuclear and histologic grading were reported according to Bloom & Richardson classification

*** DCIS case was comedo type and Van-Nuys group 3

IUP; intrauterine period Sx Du; Symptom Duration US; ultrasonography

XM; Mammography Path; Pathologic result Ax LN; Axillary lymphnode involvement

NG; nuclear grading HG; histologic grading

as a result of the increased glandularity and water content of the breasts associated with the pregnancy, which increases the parenchymal density on mammogram. In this study, two cases showed mammographically negative findings due to the physiologic changes in the breasts (Fig. 1). The radiological findings of PABC in mammography and ultrasonography are similar to those of non-PABC. However, other reports suggested that the sonographic findings of frequent posterior acoustic enhancement and the remarkable cystic components in some masses are somewhat different from the appearance of a breast cancer in non-pregnant women. This is possibly due to the physiological changes associated with pregnancy and lactation [10]. Our patients showed no cystic changes and a remarkable posterior acoustic enhancement, which might have originated

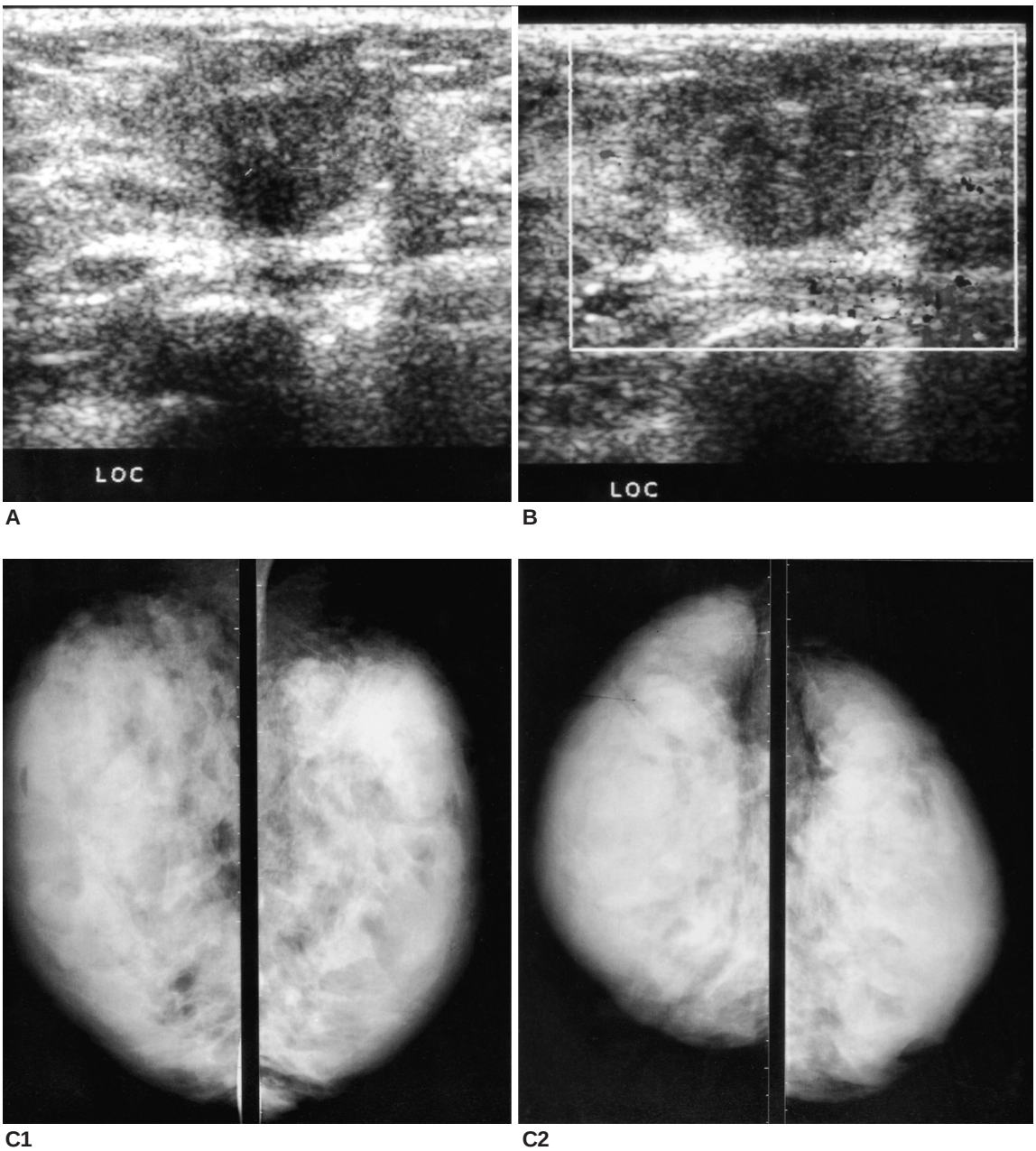

Fig. 1. A 31-year-old woman with IUP 21 weeks presented with a palpable lump in the left breast.
A. Sonography showed an ill-defined low echoic mass with non-parallel orientation. **B.** On Doppler US study, increased blood flow was noted in central portion of the mass. **C.** Bilateral mammograms showed extremely dense breasts without mass or calcifications in the both breasts (BI-RADS Category 1).

from the secretary change of the breasts during the lactation period than during the pregnancy period. According to Ahn et al [10], the sensitivity of mammography and sonography was 86.7 % and 100%, respectively. In our study, all the patients presenting with a mass showed a sonographic suspicious lesion. The patients then underwent mammography prior to the breast surgery. The sonographic findings were not significantly different from the non-pregnant patients but clinically, the mass showed rapid growth during pregnancy and the relatively lack of spiculation on sonography showed fewer desmoplastic reactions of the mass-

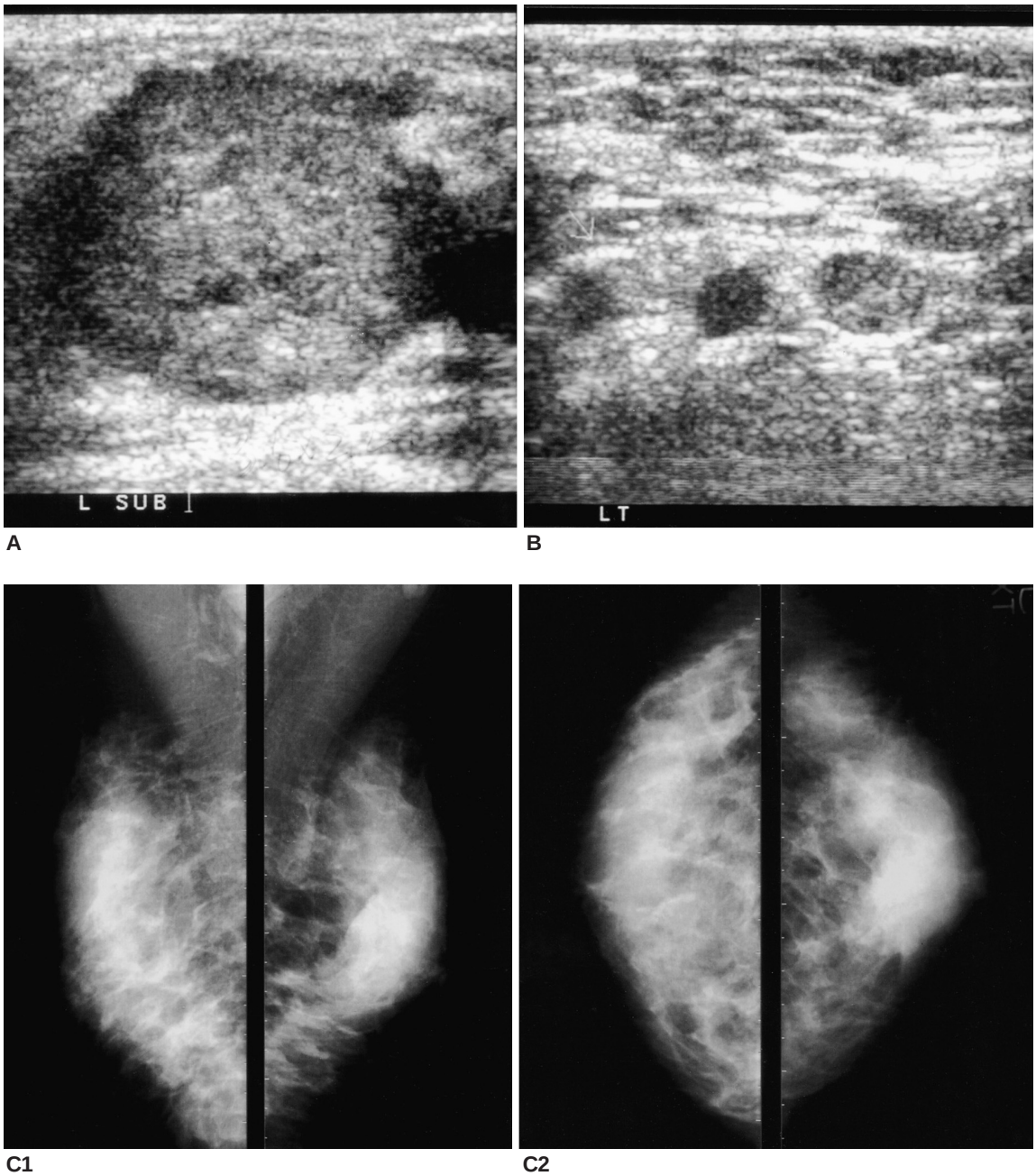

Fig. 2. A 35-year-old woman with IUP 36 weeks presented with a palpable lump at the subareolar area in the left breast.
A. Sonography of the patient showed an irregular shaped low echoic mass in the left subareolar area. **B.** Sonography at the left axilla area showed multiple enlarged metastatic lymph nodes. **C.** Bilateral mammograms showed heterogeneous breast parenchyma with increased density in the left subareolar area with an irregular shaped mass with spiculation (BI-RADS category 4). **D.** Breast MRI study was performed.

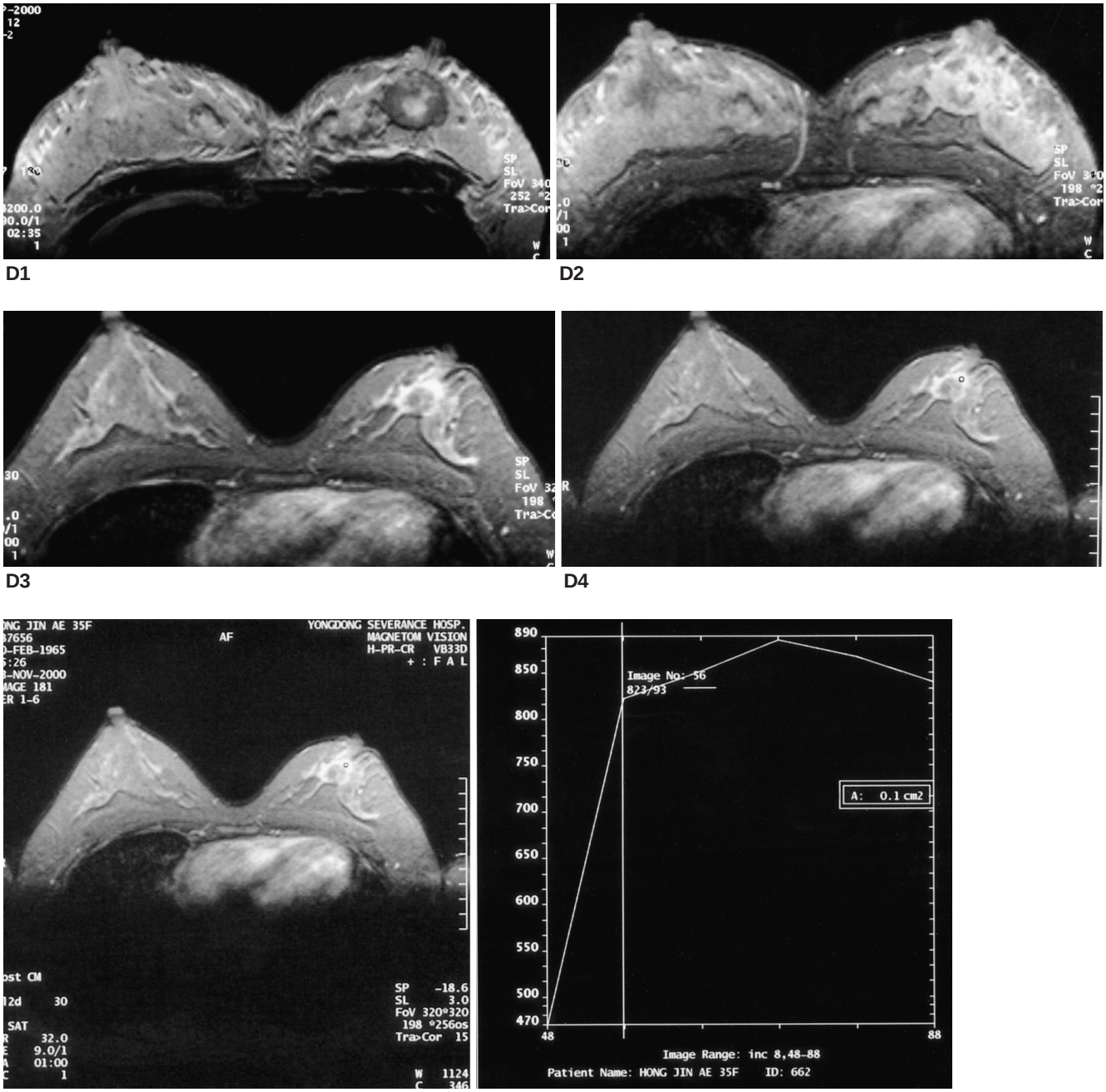

Fig. 2. D-1: T2 weighted image showed a round mass with lobulation at the left subareolar area. The mass showed an internal high signal portion, which is suggestive of central necrosis. **D-2:** After Gadolinium injection, 1 minute enhancement image showed a strong, marginal enhancement. **D-3:** Subtraction image of 1 minute showed a more prominent enhancement of the mass. **D-4:** Delayed subtraction image of 5 minute showed the relative wash out of enhancement. **D-5:** Dynamic curve of enhancement showed a typical enhancement pattern of the breast carcinoma

es. Mammography during pregnancy is less sensitive than sonography; two patients in our study showed negative findings on mammography. One of the 7 patients, who only revealed microcalcifications in mammography, had negative sonography findings. It is obvious that the mammographic sensitivity is reduced during pregnancy and the mass is more definite in sonography. On the other hand, the mass might not be observed in sonography in cases where the comedo type DCIS and radiological finding is a mammograph-

ic calcification only. In this study, the sensitivity of the breast MRI was 100%. One DCIS in a PABC case showed a linear ductal enhancement with the typical morphology of the time-intensity curve. MRI is a highly sensitive imaging modality that (Fig. 2) but there is some controversy regarding the safety to the fetus, and the fact that gadolinium is classified as a pregnancy category C drug [7]. Of our patients, those who underwent a MRI study either delivered or aborted the fetus prior to treatment. In addition, a physician must be concerned about any unknown effects of a strong magnetic field and the clinical care for the mother.

Many studies have shown an advanced stage of breast cancer during pregnancy, which was also shown in this study. This indicates the difficulty in evaluating the breasts during pregnancy. A breast mass may be difficult to perceive in these patients at a physical examination due to the increasing firmness, nodularity, and hypertrophy of the breasts. Even when a mass is palpable, it is often attributed to a benign disease and is not investigated any further. Therefore, physicians should not consider a locally growing lesion in the breasts during pregnancy as being a benign condition and should use sonography as the first choice of examination. When the findings of sonography are BI-RADS category 1, 2 or 3, a follow-up would make sense. However, a further diagnostic procedure should be performed when sonography indicates category 4 or 5 lesions . All the patients in this study underwent sonography first followed by mammography. Although mammography is seldom preformed during pregnancy due to the concerns associated with fetal irradiation, ill effects to the fetus are unlikely to occur with modern mammography [9]. Mammography has a lower sensitivity during pregnancy due to the physiological changes in the breasts. However, calcifications and the associated findings are helpful for making a proper diagnosis of PABC.

In conclusion, sonography is valuable for diagnosing PABC. Mammography can be performed for confirmation if there is a suspicious lesion on sonography. Mammography has a lower sensitivity during pregnancy due to the physiologic changes in the breasts. However, calcifications and their associated findings are helpful in diagnosing PABC. Sonography could be choice of examination if there is a rapidly growing lump in the breast during pregnancy on account of its safety, high sensitivity and specificity. Mammography and breast MRI can be performed to confirm and stage the PABC.

References

1. Petrek JA. Breast cancer and pregnancy. In: Harris JR, Hellman S, Henderson IC, Kinne DW, eds. Breast diseases. 2nd ed. Philadelphia, Pa: Lippincott, 1987;809-816
2. Wallack MK, Wolfe JA Jr, Bedwinek J, et al. Gestational carcinoma of female breast. Curr Probl Cancer 1983;7:1-58
3. Treves N, Holleb AI. A report of 549 cases of breast cancer in women 35 years of age or younger. Surg Gynecol Obstet 1958;107:271-283
4. Horsley JS III, Alrich EM, Wright CB. Carcinoma of the breast in women 35 years of age or younger. Ann Surg 1969;169:839-843
5. Smith MS, Patton HD, Fuchs AF, Mille B, Scher AM, Steiner R. Textbook of physiology. 21st edition Philadelphia: Saunders 1989;1408-1421
6. Mendelson EB, Berg WA, Merritt CRB. Toward a standardized breast ultrasound lexicon, BI-RADS: ultrasound. InL Miller WT, Berg WA(eds). Seminars in Roentgenology: Breast Imaging. Vol 36. Philadelphia, PA: WB Saunders Co;2001:217-225.
7. Petrek JA. Breast cancer during pregnancy. Cancer 1994;74:518-527
8. Greene FL, Leis HP. Management of breast cancer in pregnancy: a thirty-five-year multi-institutional experience (abstr). Proc Am Soc Clin Oncol 1989;8:25
9. Liberman L. Giess CS, Dershaw DD, Deutch BM, Petreck JA. Imaging of pregnancy-associated breast cancer. Radiology 1994;191:245-248
10. Ahn BY, Kim HH, Moon WK, Pisano ED, Kim HS, Cha ES et al. Pregnancy-and lactation-associated breast cancer. J Ultrasound Med 2003;22:491-497
11. Mattison DR, Angtuaco T. Magnetic resonance imaging in prenatal diagnosis. Clin Obstet Gynecol 1988;31:353-389

대한초음파의학회지 2005;24:123-130

=초록=

임신과 관련된 유방암에서 유방초음파 검사의 유용성

연세의대 영동세브란스병원 진단방사선과학교실

손은주 · 오기근 · 김은경

목적 : 임신과 관련된 유방암에서 유방 촬영과 초음파, 자기공명영상의 소견을 알아보고, 특히, 임신 중 발견 된 유방암의 진단에서 유방 초음파의 유용성을 분석 한다.

재료와 방법 : 1998년부터 2002년까지 임신 중 유방암이 진단 된 7명의 환자를 대상으로 하였다. 환자의 나이는 23세에서 38세까지 였고 모든 환자에서 초음파를, 6명의 환자에서 유방 촬영을 시행하였으며 5명의 환자에서 자기공명영상을 시행 하였다. 이 중 6명의 환자는 수술을 받았고 1명의 환자는 조직 생검 후 항암제 치료를 받았다. 술 후 조직학적 검사와 핵 등급, 병리학적 병기를 분석 하였다.

결과 : 유방초음파 검사 결과는 종괴의 경우, 불규칙한 모양(6예), 불규칙한 변연(6예), 흉벽과 평행하지 않는 경우(5예), 혼합 에코(5예)가 보였다. 동반 소견은 3명의 환자에서 보였는데, 쿠퍼씨 인대의 비후(2예), 부종(2예), 피부 비후(1예)와 겨드랑이 임피절 비후(3예)가 있었다. 초음파 에서 총 6예의 환자에서 이상 소견을 볼 수 있었고 이 환자들은 유방 촬영 상 치밀 유방 소견을 보였다. 유방 촬영 소견 상 종괴(4예), 종괴와 동반 된 미세 석회화(2예), 종괴와 겨드랑이 임파절 비대(3예), 석회화만 있는 경우(1예), 비대칭 성 음영만 있는 경우(1예), 과치밀 유방으로 이상 소견이 없는 경우(2예)가 있었다. 유방 자기 공명 영상의 경우 불규칙한 음영을 갖는 종괴(4예), 종괴와 테두리 조영 증강(3예), 종괴없이 선상 유도관 조영증강이 있는 경우(1예) 가 있었으며 시간에 따른 조영증강의 양과 형태는 유방암의 전형적인 소견을 보였다.

결론 : 유방 초음파 검사는 임신과 관련된 유방암의 진단에 유용하다. 만약 초음파에서 의심스러운 병변이 있다면 유방 촬영술을 시행해야 하며, 임신에의한 유방조직의 변화로 인해 유방촬영의 민감도가 감소 하지만 석회화나 동반 소견 등이 유방암의 확진에 도움을 줄 수 있다. 임신 기간 중 빨리 자라는 종괴가 있다면 이를 양성 종괴로 간과 하지 말고 반드시 영상 검사와 조직생검을 통해 진단에 도움을 줄 수 있어야 한다.