

# 대퇴 사두건을 이용한 관절경적 이중 다발 전방 십자 인대 재건술

연세대학교 의과대학 정형외과학교실

김성재 · 정광암 · 송대흠

## Arthroscopic Double Bundle ACL Reconstruction using Autogenous Quadriceps Tendon -Technical Note-

Sung-jae Kim, M.D., Kwang-Am Jung, M.D., Dae-Heup Song, M.D.

Department of Orthopaedic Surgery, Yonsei University College of Medicine, Seoul, Korea

Recently, the interest on anatomical ACL reconstruction with double bundle technique is increased to reproduce the original load distribution, and kinematics of the knee. We developed an arthroscopic double bundle ACL reconstruction technique using autogenous quadriceps tendon with 2 splitted graft and patellar bone plug. The anteromedial bundle and posterolateral bundle of the ACL is replicated with each splitted graft of quadriceps tendon and fixed with biodegradable interference screw on the 2 femoral tunnels. The patellar bone plug of quadriceps tendon is fixed with biodegradable interference screw within the 1 tibial tunnel. We suggest that our technique using quadriceps tendon may be an alternative in arthroscopic double bundle ACL reconstruction.

**KEY WORDS:** ACL, Double bundle reconstruction, Quadriceps tendon

### Introduction

Recently, several studies reported that the anatomic structure of the ACL should be reconstructed to restore not only anterior-posterior tibial stability but also rotational stability, although the single bundle ACL reconstruction is still widely used method with a satisfactory result.<sup>1-9</sup> Single bundle reconstruction that predominantly reproduce anteromedial bundle cannot withstand the load distributed in the normal ACL, because 2 bundle have different behavior according to the amount of stress and

direction on which they are loaded.<sup>3</sup> Gabriel et al.<sup>10</sup> have shown that anteromedial bundle and posterolateral bundle have different distributions of in situ forces when the knee is subjected to anteroposterior and rotary loads. Based on these research, the interest on anatomical ACL reconstruction with double bundle technique to reproduce as much as possible the original load distribution and kinematics of an intact knee is increased.<sup>2,6,7</sup> Various surgical techniques and graft selection for double bundle ACL reconstruction have been presented.<sup>1-6,8,9,11-18</sup> We successfully performed an arthroscopic double bundle ACL reconstruction using autogenous quadriceps tendon with 1 tibial tunnel and 2 femoral tunnel. We suggest that our technique using quadriceps tendon may be an alternative in arthroscopic double bundle ACL reconstruction.

\* Adress correspondence and reprint requests to

**Kwang-Am Jung, M.D.**

Department of Orthopaedic Surgery, Yonsei University  
College of Medicine C.P.O. Box 8044, 134, Shinchon-Dong,  
Seodaemun-Ku, 120-752, Seoul, Korea

Tel: 82-2-2228-5679, Fax: 82-2-363-6248

E-mail: Sungjaekim@yumc.yonsei.ac.kr

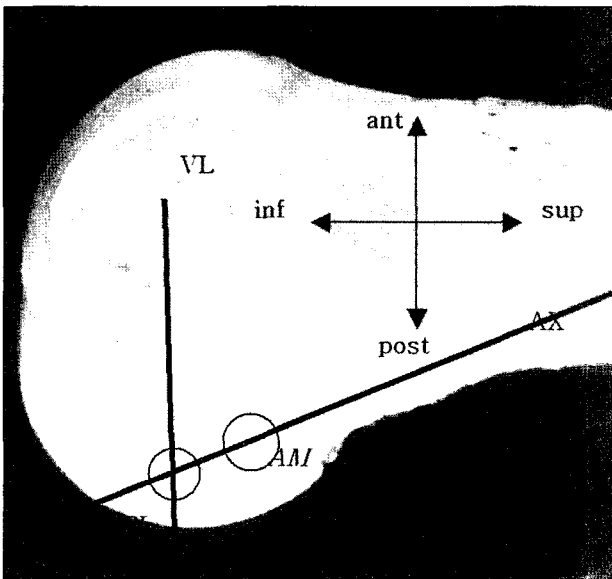
## Surgical Technique

A 7 cm long longitudinal midline incision is placed on the proximal site of the patella, extending proximally to provide adequate exposure. After dissection of the soft tissue layers over the anterior surface of the patella, a trapezoidal shaped bone plug with a width of 11 mm, length of 20 mm, and depth of 10 mm is harvested with the attached quadriceps tendon using a small oscillating saw. The tendon portion is 50 to 55 mm long, 11 mm wide and 10 to 11 mm thickness, including the full thickness of 3 tendon (the rectus tendon, vastus lateralis oblique-vastus medialis oblique tendon and vastus intermedius tendon) layers. Special care should be given to avoid entering the underlying synovium and suprapatellar pouch, and a curved Kelly instrument is placed behind the 3 tendon layers to protect the underlying joint synovium.<sup>19</sup> If the synovium is perforated, meticulous repair should be done. Then, the quadriceps tendon split coronally into the ratio of about two to three, resulting in a diameter of 7 and 9 mm thickness bundle and set aside in a saline soaked moist sponge for later use. High anterolateral portal and low anteromedial portal are established.<sup>20</sup> After a complete diagnostic arthroscopy is performed, the injured ACL is examined using an arthroscopic probe. The remnant of the ruptured ACL on the lateral femoral condyle is excised using a motorized shaver and Arthrocare bipolar radiofrequency device (Arthrocare, Sunnyvale, CA) to allow anatomic ACL attachment sites to be visualized. If necessary, adequate intercondylar notchplasty is performed. First, the posterolateral femoral tunnel is drilled. This is performed via an accessory anteromedial portal located 1cm medial to the anteromedial portal just above the medial meniscus. A 3.2 mm guidepin is passed into the center of posterolateral bundle which is located approximately at the crossing point of the 2 lines, the long axis line of the ACL attachment and the vertical line drawn through the contact point between the femoral condyle and the tibial plateau at 90 degree of the knee flexion.<sup>8,9</sup>

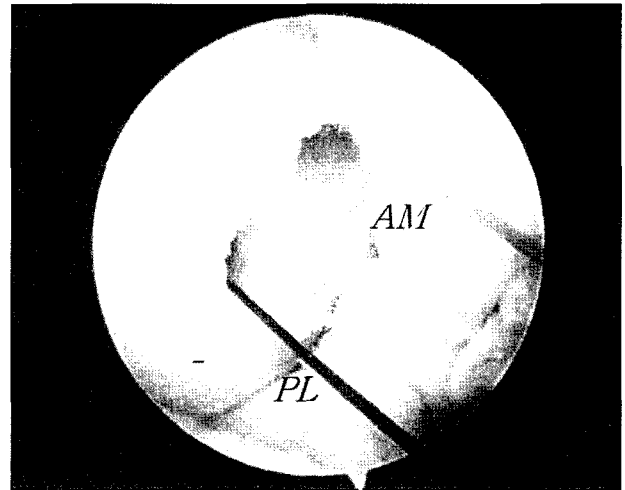
The tunnel is placed at 9:30 o'clock(right) and 2:30 o'clock(left) when using conventional clock direction. Once the pin is in an acceptable position through an accessory anteromedial portal, the tunnel is drilled with a 7mm diameter headed reamer (the same diameter as that of the proximal diameter of splitted graft for posterolateral bundle) over the guidepin with to a depth of approximately 35 mm. The posteroinferior border of the tunnel should be on the posteroinferior border of the footprint of posterolateral bundle. Then, femoral tunnel for anteromedial bundle is made. A transtibial technique is used in the same fashion as a single bundle reconstruction. A 6 mm over-the-top guide is placed on the proximal cortex of the notch at about 11 o'clock(right) and 1 o'clock(left). The guidepin is passed. The tunnel is drilled over the guidepin with 9 mm diameter headed reamer to a depth of 40 mm. The anterosuperior border of the tunnel should be on the anterosuperior border of the footprint of anteromedial bundle. (Fig. 1) The distance between the 2 sockets should be more than 4mm to avoid socket bridge breakage. (Fig. 2) The edges of femoral socket and tibial socket are chamfered to reduce stress concentration on the graft. And then the intraarticular lengths of each bundle of the ACL are measured with slightly posterior translation load maintained on the proximal tibia and with the knee in 90 degree of flexion for the anteromedial bundle and 10 degree flexion for the posterolateral bundle. The length of intraarticular anteromedial bundle is measured by a calibrated headed reamer used on anteromedial femoral tunneling. The length of intraarticular posterolateral bundle is measured by a ruler that is placed between the tibial tunnel and posterolateral femoral tunnel as follows. The each end of thin paper ruler is stitched with a 1-0 ethibond sutures. The plastic cannula with 4.5 mm diameter (Linvatec Largo Florida) is positioned on accessory anteromedial portal. The leading suture of ruler is pulled out through the accessory anteromedial portal via tibial tunnel. And then guidepin with eyelet is passed through posterolateral socket through

plastic cannula positioned on the accessory anteromedial portal. The proximal leading suture of ruler is connected to eyelet of guidepin. After passage of guidepin out of the posterolateral socket, the ruler is positioned within posterolateral tunnel. And then we measure the exact intraarticular length with slightly posterior translation loads maintained on the proximal tibia with the knee in 10 degree of flexion. The suturing with baseball stitches on each bundle are done from the point of intraarticular length from the bone tendon junction about 30 mm long. The 7 mm and 9mm diameter EndoPearl(Linvatec, Largo, FL) devices are fixed to each end using No.2 ethibond suture. Two drill holes are made in the patellar bone plug. We pass 2 ethibond sutures through the bone plugs(Fig. 3) Viewing through the high antero-


lateral portal, two guidepins with the slotted eye are advanced proximally until the slotted eyes are inside both anteromedial and posterolateral femoral socket. A leading suture is passed through the tibial tunnel and pulled out with the grasper through the anteromedial portal with 4.5 mm plastic cannula. The leading sutures attached to the end of bone plug is pulled from proximal to distal. The anteromedial portal is widened by using a knife for easy passage of the graft. The distal bone plug is passed through the anteromedial portal and placed in the tibial tunnel by pulling the leading sutures distally. Then the tip of guidepin with the slotted eye is withdrawn into the joint



**Fig. 1.** A.The posterolateral bundle (PL) is located at the crossing point of the 2 lines,the long axis of ACL attachment (AX) and vertical line (VL) drawn through the contact point between the femoral condyle and tibial plateau at 90 degree of the knee flexion.The posteroinferior border of the tunnel should be on the posteroinferior border of the footprint of posterolateral bundle. B.The tunnel for anteromedial bundle (AM) is created by transtibial technique as a single bundle reconstruction.The anterosuperior border of the tunnel should be on the anterosuperior border of the footprint of anteromedial bundle.



**Fig. 2.** The distance between tunnel for anteromedial bundle (AM) tunnel and tunnel for posterolateral (PL) bundle should be more than 4mm to avoid socket bridge collapse.



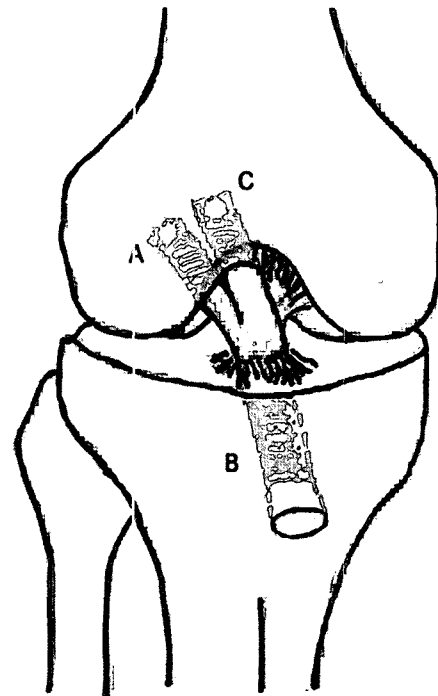
**Fig. 3.** Two bundles using autogenous quadriceps tendon are prepared. The graft is consist of 2 coronally splitted graft for replication of anteromedial and posterolateral bundle.

from the femoral socket for the posterolateral bundle. The leading suture of the posterolateral graft bundle is hooked into the eye of the guidepin and the guidepin is pulled out to the lateral femoral condyle. The graft is guided into the closed end of the femoral socket for the posterolateral bundle. In the same manner, the anteromedial graft bundle is guided into the femoral socket for the anteromedial bundle. First, femoral fixation of the posterolateral bundle graft is obtained with the absorbable interference screw through the accessory anteromedial portal with the knee in 90 degree of flexion. And then tension is applied by pulling of ethibond sutured to bone plug in the tibial tunnel while moving the knee 20 times through a full range of motion. The knee is brought to the 10 degree flexion position. The distal bone plug is tensioned and secured by an absorbable interference screw. The proper advancement of the screw is confirmed by viewing through the high anterolateral portal. Once more, tension is applied on the graft in the femoral socket for the anteromedial bundle while moving the knee 20 times through a full range of motion. Next, femoral fixation of the anteromedial graft bundle is obtained with the absorbable interference screw through the low anteromedial portal with the knee in 100 degree of flexion while an posteriorly directed force is applied. (Fig. 4)

### Discussion

Various surgical procedures and graft selection for double bundle ACL reconstruction have been presented in the literature. Some procedures used 1 tibial and 1 femoral tunnel<sup>3,15,17</sup> and other procedures used 1 tibial and 2 femoral tunnels<sup>2,14,18</sup> or 2 tibial and 2 femoral tunnels<sup>1,4-9,12</sup> or 3 tibial and 2 femoral tunnels.<sup>16</sup> The selected grafts in these procedures are also various: hamstring tendon, quadriceps tendon, hamstring-patellar tendon composite autograft and tibialis posterior allograft. Some authors recommend the anatomic anterior cruciate ligament reconstruction using the EndoButton fixation device loaded two double-looped hamstring

tendon grafts with 2 femoral and 2 tibial tunnels.<sup>1,6-9</sup> The optimal method for anatomical double bundle ACL reconstruction is controversial yet. We developed the technique under several considerations. First, the number of tunnel should be decreased, if possible, for later revision with preservation of biomechanical characteristics of anatomical reconstruction.<sup>21</sup> Considering the importance of PL bundle for resistance of rotary motion of the knee, 2 femoral tunnels are necessary for reconstruction of anatomical ACL reconstruction. However, the intraarticular location of tibial aperture appear to be less critical relative to femoral side, even though some authors reported the importance of



**Fig. 4.** (A) First, femoral fixation of the posterolateral bundle graft is obtained with the absorbable interference screw through the accessory anteromedial portal with the knee in 90 degree of flexion. (B) After pretensioning, the distal bone plug placed in the tibial tunnel is secured in 10 degree of flexion by an absorbable interference screw. (C) After pretensioning, femoral fixation of the anteromedial graft bundle is obtained with the absorbable interference screw through the low anteromedial portal with the knee in 100 degree of flexion while an posteriorly directed force is applied

tibial tunnel to replicate anteromedial and posterolateral bundle more anatomically when considering the direction of graft and graft tension. The comparison between one tibial tunnel with 2 femoral tunnel and 2 tibial tunnel with 2 femoral tunnel is not reported by this time. Mae T et al.<sup>2</sup> presented that double bundle ACL reconstruction with 2 femoral tunnel and single tibial tunnel showed better clinical results and restoration of normal kinematics of the knee in biomechanical study. So we made two femoral tunnel and one tibial tunnel instead of two tibial tunnel. Secondary, we tried to search the graft materials to improve the fixation strength with small number of adjunctive fixation instrument. Recently, some surgeons prefer an EndoButton fixation using hamstring tendon on the femoral site for both the anteromedial and posterolateral bundle reconstructions. However complications associated with the EndoButton fixation device have been reported. Endobutton drill bit failure, intraarticular migration, soft tissue interposition between the Endobutton and the femoral cortex., bungee effect and malposition within the cancellous bone of the femoral tunnel in double bundle ACL reconstruction.<sup>22</sup> Using the quadriceps tendon, many advantages have been reported in aspect of graft material.<sup>23,24,25</sup> Moreover in some report, the laxity was much higher that used the hamstring as graft source than autologous patella tendon.<sup>26</sup> The intraarticular length of the ACL measured in the procedure makes the interference screw fix the graft to the original ACL attachment site, which may increase knee stability by decreasing the so-called bungee, windshield and stress shield effect. To enhance the femoral interference screw fixation of the grafts, the EndoPearl device are applied to end of the each splitted graft, which add fixation strength to more than 50% of the loads.<sup>27</sup> We experienced total of 8 cases of patients since Nov. 2004 and showed good preliminary results. Because arthroscopic double bundle ACL reconstruction including this procedure and other procedure are in a time of evolution and is technically demandable, it is not recommended for all orthopaedic surgeons.

However, it is worthwhile for surgeons to seek the better clinical results especially in the patients who have generalized laxity. In conclusion, our technique using quadriceps tendon may be an alternative in arthroscopic double bundle ACL reconstruction but clinical and biomechanical studies to investigate the long term results of this procedure are necessary.

## REFERENCES

- 1) **Christel P, Franceschi JP, Sbihi A, Colombet P, Djian P, Bellier G.** Anatomic anterior cruciate ligament reconstruction: The French experience. *Oper Tech Ortho* 2005;15:103-110.
- 2) **Mae T, Shino K and Miyama T et al.** Single- versus two-femoral socket anterior cruciate ligament reconstruction technique Biomechanical analysis using a robotic simulator. *Arthroscopy* 2001;17:708-716.
- 3) **Marcacci M, Zaffagnini S, Marchesini L, Delcogliano M, Bruni M.** Anatomic anterior cruciate ligament reconstruction using the over-the-top passage of hamstring tendons. *Oper Tech Ortho* 2005;15:123-129.
- 4) **Muneta T, Sekiya I, Yagishita K, Ogiuchi T, Yamamoto H, Shinomiya K.** Two-bundle reconstruction of the anterior cruciate ligament using semitendinosus tendon with Endobuttons: operative technique and preliminary results. *Arthroscopy* 1999;15:618-624.
- 5) **Vidal AF, Brucker PU, Fu FH.** Anatomic double bundle anterior cruciate ligament reconstruction using anterior tendon allografts. *Oper Tech Ortho* 2005;15:140-145.
- 6) **Yagi M, Kuroda R, Yoshiya S, Kurosaka M.** Anatomic anterior cruciate ligament reconstruction: The Japanese experience. *Oper Tech Ortho* 2005;15:116-122.
- 7) **Yagi M, Wong E, Kanamori A, Debski RE, Fu FH, Woo SL.** Biomechanical analysis of an anatomic anterior cruciate ligament reconstruction. *Am J Sports Med* 2002;30:660-666.
- 8) **Yasuda K, Kondo E and Ichiyama H et al.** Anatomic reconstruction of the anteromedial and posterolateral bundles of the anterior cruciate ligament using hamstring tendon grafts. *Arthroscopy* 2004;20:1015-1025.
- 9) **Yasuda K, Kondo E, Ichiyama H, Tanabe Y, Tohyama H.** Surgical and biomechanical concepts of anatomic anterior cruciate ligament reconstruction. *Oper Tech Ortho* 2005;15:96-102.
- 10) **Gabriel MT, Wong EK, Woo SL, Yagi M, Debski RE.** Distribution of in situ forces in the anterior cruciate ligament in response to rotatory loads. *J Orthop Res* 2004;22:85-89.

- 11) **Aglietti P, Cuomo Pierluigi, Giron Francesco, Boerger T.** Double-bundle anterior cruciate ligament reconstruction: Surgical technique. *Oper Tech Ortho* 2005;15:111-115.
- 12) **Adachi N, Ochi M, Uchio Y, Iwasa J, Kuriwaka M, Ito Y.** Reconstruction of the anterior cruciate ligament Single-versus double-bundle multistranded hamstring tendons. *J Bone Joint Surg Br* 2004;86: 515-520.
- 13) **Brucker P, Lorenz S, Imhoff A.** Anatomic fixation in double-bundle anterior cruciate ligament reconstruction. *Oper Tech Ortho* 2005;15:135-139.
- 14) **Hamada M, Shino K and Horibe S et al.** Single- versus bi-socket anterior cruciate ligament reconstruction using autogenous multiple-stranded hamstring tendons with EndoButton femoral fixation A prospective study. *Arthroscopy* 2001;17:801-807.
- 15) **Hara K, Kubo T, Suginoshita T, Shimizu C, Hirasawa Y.** Reconstruction of the anterior cruciate ligament using a double bundle. *Arthroscopy* 2000;16:860-864.
- 16) **Shino K, Nakata K and Nakamura N et al.** Anatomic anterior cruciate ligament reconstruction using two double-looped hamstring tendon grafts via twin femoral and triple tibial tunnels. *Oper Tech Ortho* 2005;15:130-134.
- 17) **Takeuchi R, Saito T, Mituhashi S, Suzuki E, Yamada I, Koshino T.** Double-bundle anatomic anterior cruciate ligament reconstruction using bone-hamstring-bone composite graft. *Arthroscopy* 2002;18:550-555.
- 18) **TD Rosenberg, B Graf.** Techniques for ACL reconstruction with Multi-Trac drill guide. Mansfield, MA, *Acufex Microsurgical Inc.*, 1994.
- 19) **Noyes FR, Medvecky MJ, Bhargava M.** Arthroscopically assisted quadriceps double-bundle tibial inlay posterior cruciate ligament reconstruction: An analysis of techniques and a safe operative approach to the popliteal fossa. *Arthroscopy* 2003;19:894-905.
- 20) **Kim SJ, Kim HJ.** High portal: Practical philosophy for positioning portals in knee arthroscopy. *Arthroscopy* 2001;17:333-337.
- 21) **Harner CD, Poehling GG.** Double bundle or double trouble. *Arthroscopy* 2004;20:1013-1014.
- 22) **Brucker PU, Zelle BA, Fu FH.** Intraarticular EndoButton displacement in anatomic anterior cruciate ligament double-bundle reconstruction: A case report *Oper Tech Orthop* 2005;15:154-157.
- 23) **Fulkerson JP, Langeland R.** An alternative cruciate reconstruction graft: The central quadriceps tendon. *Arthroscopy* 1995;11:252-254.
- 24) **H.U. Staubli.** Arthroscopically assisted ACL reconstruction using autologous quadriceps tendon. In: R.P. Jakob, H.U. Staubli, eds., *Cruciate ligaments*, Berlin: *Springer-Verlag*, 1992; 443-451.
- 25) **H.U. Staubli** The quadriceps tendon-patellar bone construct for ACL reconstruction. *Sports Med Arthroscopy Rev* 1997;5:59-67.
- 26) **T.F. Taggart, A. Kumar, D.R. Bickerstaff** Revision anterior cruciate ligament reconstruction: a midterm patient assessment. *The knee* 2004;11:29-36.
- 27) **Weiler A, Richter M, Schmidmaier G, Kandziora F, Sudkamp NP.** The EndoPearl device increases fixation strength and eliminates construct slippage of hamstring tendon grafts with interference screw fixation. *Arthroscopy* 2001;17:353-359.