연세대학교
YONSEI UNIVERSITY

Development of a new hybrid biodegradable drug-eluting stent for the treatment of peripheral artery disease

Jung-Hee Lee

Department of Medicine

The Graduate School, Yonsei University

연세대학교
YONSEI UNIVERSITY

Development of a new hybrid biodegradable drug-eluting stent for the treatment of peripheral artery disease

Directed by Professor Young-Guk Ko

The Doctoral Dissertation
submitted to the Department of Medicine,
the Graduate School of Yonsei University
in partial fulfillment of the requirements
for the degree of Doctor of Philosophy

Jung-Hee Lee

June 2016

연세대학교
YONSEI UNIVERSITY

This certifies that the Doctoral Dissertation of Jung-Hee Lee is approved.

Thesis Supervisor : Donghoon Choi

Thesis Committee Member#1 : Young-Guk Ko

Thesis Committee Member#2 : Joon Hyuk Kong

Thesis Committee Member#3: Jong Yun Won

Thesis Committee Member#4: Jong-Chul Park

The Graduate School
Yonsei University

June 2016

ACKNOWLEDGEMENTS

The authors would like to acknowledge the contribution of the member of the member of the Cardiovascular Research Institute, Yonsei University College of Medicine: Soon-Joong Kim, PhD and the member of the Cardiovascular Product Evaluation Center, Yonsei University College of Medicine: Se-Il Park, PhD

TABLE OF CONTENTS

LIST OF FIGURES

LIST OF TABLES

ABSTRACT

Development of a new hybrid biodegradable drug-eluting stent for the treatment of peripheral artery disease

Jung-Hee Lee

Department of Medicine

The Graduate School, Yonsei University

(Directed by Professor Young-Guk Ko)

Background: Despite the superior benefits of nitinol metal stents, there are several major concerns regarding their metallic components in the treatment of peripheral artery disease (PAD). However, there is little clinical data available on the use of biodegradable stents for treating PAD and limited experimental trials investigating the development of new models of biodegradable stents.

Purpose: The purpose of this study was the development of a new biodegradable stent for PAD that could provide sufficient radial force to maintain patency, flexibility, and long-term patency.

Methods: All self-expandable hybrid biodegradable stents were designed using a knitting structure composed of poly-L-lactic acid (PLLA) and nitinol. Four different types of stents were implanted in 20 iliac arteries in 10 mini pigs: a bare-metal stent (BMS) (Group 1, n=5), a drug-free hybrid stent (Group 2, n=5), a 50% (50:100, w/w) paclitaxel (PTX)/poly-lactide-co-glycolic acid (PLGA) (fast PTX-releasing form) hybrid stent (Group 3, n=5), and a 30% (30:100, w/w) PTX/PLGA (slow PTX-releasing form) hybrid stent (Group 4, n=5). We performed angiography after each stent implantation as well as follow-up angiography and intravascular ultrasound (IVUS) at 4 and 8 weeks. Histologic specimens were analyzed at the experimental end point.

Results: All stents were successfully implanted in all animals. In a comparison of Groups 1, 2, 3, and 4, less diameter stenosis was observed in Group 4 when compared with the other groups at the 4-week follow-up on angiographic analysis (19.0±12.7% vs. 39.3±18.1% vs. 46.8±38.0% vs. 4.8±4.2%, respectively; p=0.032). IVUS findings further suggested that the neointima of Group 4 tended to be lesser than that of the others. The stent area measured by IVUS did not show significant changes at the 8-week follow-up. In histologic analysis, lower vascular traumas and inflammatory reactions were observed in Group 4.

Conclusions: Our new biodegradable 30% PTX/PLGA (slow-releasing form) stent showed more favorable results for patency and safety when compared with the other stent types. This study provides new concepts for developing a new biodegradable stent for the treatment of PAD.

Key Words: Drug-eluting stents, Biodegradable, Peripheral artery disease

Development of a new hybrid biodegradable drug-eluting stent for the treatment of peripheral artery disease

Jung-Hee Lee

Department of Medicine

The Graduate School, Yonsei University

(Directed by Professor Young-Guk Ko)

I. INTRODUCTION

Biodegradable stents appear to be one of the most promising tools in the field of endovascular intervention, offering numerous potential benefits over permanent implants for the treatment of cardiovascular disease. Percutaneous transluminal angioplasty with primary stenting for peripheral artery disease (PAD) can result in technical success and clinical benefits.[1] Endovascular stenting using nitinol metal stents may avoid problems such as early elastic recoil, residual stenosis, and flow-limiting dissection after balloon angioplasty, along with improved flexibility.[2-4]

Despite the superiority of nitinol metal stents, there are several major concerns regarding their metallic components, including stent fracture, late stent thrombosis, and late restenosis. The superficial femoral artery is a harsh environment for a metallic stent, as mechanical forces such as bending, torsion, compression, and elongation occur during everyday activities.[5] Hence, the use of biodegradable stents in PAD has previously been investigated.[6,7] These biodegradable stents have had several limitations, including vascular inflammation, lack of radial force for long-term patency, and acute recoiling after stent implantation. However, there is little clinical data available regarding the use of biodegradable stents for peripheral disease or experimental trials aimed at developing new models of biodegradable stents. Thus, the development of a new biodegradable stent for use in PAD is necessitated. The primary aim of this study was the development of a new biodegradable stent for PAD that could provide sufficient radial force for the maintenance of patency, flexibility to vessel geometry, and long-term patency by inhibiting intimal hyperplasia.

II. MATERIALS AND METHODS

1. Stent design

The hybrid biodegradable stents were designed to be flexible and self-expanding using a knitting structure comprising poly-L-lactic acid (PLLA) with a strut thickness of 225μm and nitinol (Figure 1). Using a dipping method, we loaded paclitaxel (PTX) to the PLLA/Nitinol composite stent. Dip coating was performed by immersing the PLLA/Nitinol composite stent in a coating solution (12% poly-lactide-co-glycolic acid (PLGA) + 2:3 v/v ethanol:dimethyl sulfoxide (DMSO)). For the purposes of achieving optimal PTX levels, we used multiple dipping methods. By controlling the dipping time or contents of the solvent, we were able to regulate the level of PTX loaded on a PLLA/Nitinol composite stent. The amount of PTX released by each sample was measured using HPLC (1% SDS in PBS, 37℃). After analyzing variable PTX loading methods, we chose to use two types of drug-eluting PLLA/Nitinol composite stents: a 50% (50:100, w/w) PTX/PLGA (fast PTX-releasing form) hybrid stent and a 30% (30:100, w/w) PTX/PLGA (slow PTX-releasing form) hybrid stent.

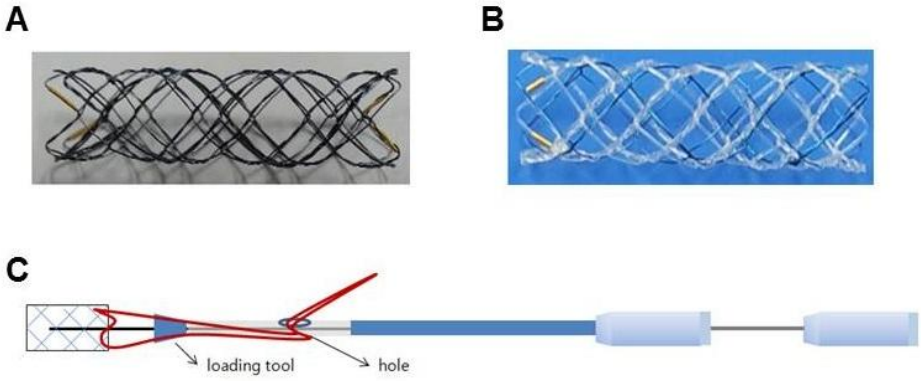

Figure 1. Stent design

(A) Conventional bare metal stent. (B) Poly-L-lactic acid (PLLA) and nitinol knitting structure of the hybrid biodegradable stent. (C) Self-expandable delivery system of the hybrid biodegradable stent.

2. Stent implantation procedure

This study was approved by the Yonsei University Institutional Animal Care and Use Committee. Experiments were planned using 20 common iliac arteries in 10 mini pigs. All animals received 100 mg aspirin and 300 mg clopidogrel at least 12 hours before the procedure. All animals received humane care in compliance with the Animal Welfare Act and "The Guide for the Care and Use of Laboratory Animals" formulated by the Institute of Laboratory Animal Research.[8] Anesthesia was performed via intramuscular injection of ketamine (20 mg/kg) and xylazine (2 mg/kg). After adequate systemic anesthesia, animals were placed in the supine position under mechanical ventilation and isoflurane (1-2%) was delivered using a precision vaporizer and a circle absorption breathing system, with periodic arterial blood gas monitoring. After surgical exposure of the carotid artery, an arteriotomy of the carotid artery was performed under sterile conditions and a 6-Fr vascular access sheath was inserted. During the procedure, vital signs were consistently monitored using surface electrocardiography. Prior to the procedure, heparin (150 units/kg) was injected to maintain an activated clotting time ≥250 seconds. Based on quantitative imaging analyses, oversized balloon inflation with a 1.3:1.0 balloon artery ratio was applied twice for a period of 30 seconds at a time within each iliac artery. After balloon injury, four different types of stents were randomly implanted in 20 common iliac arteries under fluoroscopic guidance: a bare-metal stent (BMS) (Group 1, n=5), a drug-free hybrid stent (Group 2, n=5), a 50% PTX/PLGA (fast PTX-releasing form) hybrid stent (Group 3, n=5), and a 30% PTX/PLGA (slow PTX-releasing form) hybrid stent (Group 4, n=5). Operators were blinded to the types of stent used for each procedure. After implantation,

conventional angiography was performed and the carotid arteries were repaired using suture material suited until subsequent use of the carotid arteries. All animals received 100 mg aspirin and 75 mg clopidogrel daily after stent implantation. The animals were fed a regular diet throughout the duration of the study. Follow-up angiography was performed and gray-scale intravascular ultrasound (IVUS) examinations were conducted in the region of the inserted stent at 4 and 8 weeks after stent implantation. A 2.9-Fr IVUS imaging catheter (Eagle Eye, Volcano Corp, Rancho Cordova, CA) with a 20-MHz phased-array transducer was used. Follow-up IVUS imaging was not performed where angiography had showed total in-stent occlusion. After 8 weeks, the animals were euthanized and the iliac arteries harvested.

3. Quantitative coronary angiography and intravascular ultrasound analysis

Quantitative angiography analyses were performed using an offline computerized quantitative coronary angiographic system (CASS System, Pie Medical Imaging, Maastricht, The Netherlands) in an independent core laboratory (Cardiovascular Research Center, Seoul, Korea). The minimal lumen diameter (MLD) with diameter stenosis and reference diameter (RD) of treated iliac vessels were measured. The percentage of diameter stenosis was calculated using the following formula: percent diameter = [(mean RD – MLD) / mean RD]*100, mean RD = (proximal reference vessel diameter + distal vessel diameter)/2.

Conventional gray-scale quantitative IVUS analyses were performed according to the criteria of the clinical expert consensus document on IVUS and included the external elastic membrane (EEM), lumen, plaque, and media (P&M; P&M=EEM minus lumen) volumes.[9] Cross-sectional IVUS images were analyzed at 1 mm intervals. All IVUS images were analyzed at the core laboratory (Cardiovascular Research Center, Seoul, Korea) by analysts who were blinded to the treatment and procedures performed on each animal.

4. Histologic analysis

All animals were euthanized under anesthesia after the 8-week follow-up images had been acquired. Immediately after the iliac arteries were harvested, the stented vascular segments were fixed for 24 hours using 4% formaldehyde. After dehydration, samples were embedded in a glycol methacrylate (GMA) polymerization solution (Technovit 7200VLC, Heraeus Kulzer Gmbh, Germany). Each stented segment was cut proximal, medial, and distal using an EXAKT saw (EXAKT Apparatebau, Germany); stained; dried; and glued onto EXAKT slides; and polished down using an EXAKT-polish machine (EXAKT 400 CS, EXAKT Apparatebau, Germany). Data analysis was performed using a microscope (GE-OEC Series 9800, USA) and its corresponding imaging software (Sigmascan Pro, Systat Software Inc., USA). All embedded sections were stained with hematoxylin-eosin (H&E).

5. Evaluation of inflammatory and vessel injury scores

The inflammatory score for each individual was defined as follows: 0 = no inflammatory cells surrounding the strut; 1 = light, non-circumferential lymphohistiocytic infiltrate surrounding the strut; 2 = localized, non-circumferential, moderate-to-dense cellular aggregate surrounding the strut; and 3 = circumferential dense lymphohistiocytic cell infiltration of the strut.[10,11] The vessel injury score was graded as follows: 0 = internal elastic lamina intact; 1 = internal elastic lamina lacerated; 2 = internal elastic lacerated; and 3 = external elastic lamina lacerated.[10]

6. Statistical analysis

Statistical analysis was performed using SPSS (Version 20.0.0, IBM, Armonk, NY, USA). Data were expressed as the number (%) or the mean ± standard deviation or the median (interquartile range). Continuous variables were compared using one-way analysis of variance (ANOVA) or the Kruskal-Wallis test. Abnormally distributed continuous variables were compared using the Mann-Whitney U test. Comparisons of categorical data were performed using χ-square statistics or Fisher's exact test. Pearson's correlation analysis was performed to evaluate the correlation between changes in the MLD. A P-value <0.05 was considered to be statistically significant.

III. RESULTS

1. Quantitative imaging evaluation

All stents were successfully implanted to both common iliac arteries in all 10 animals. The findings from quantitative imaging analyses are presented in Table 1. There were no significant differences in the RD of iliac arteries pre-procedure, at the 4-week follow-up, or at the 8-week follow-up. When Groups 1, 2, 3, and 4 were compared; less diameter stenosis was observed in the 30% PTX/PLGA (slow PTX-releasing form) hybrid stent (Group 4) when compared with the other groups at the 4-week follow-up (19.0±12.7% vs. 39.3±18.1% vs. 46.8±38.0% vs. 4.8±4.2%, respectively; p=0.032, Figure 2). The MLD in Group 4 (3.39±0.45mm) also tended to be greater than that of the other groups at the 8-week follow-up, although this difference was not statistically significant (p=0.108). However, the MLD in Group 4 showed more favorable results when compared with Groups 2 (the drug-free hybrid stent) and 3 (the 50% PTX/PLGA, fast PTX-releasing form hybrid stent) (Figure 3).

Table 1. Quantitative imaging analyses

	Group 1 (n=5)	Group 2 (n=5)	Group 3 (n=5)	Group 4 (n=5)	*p*
Pre-procedure RD (mm)	3.79±0.50	4.20±0.38	3.71±0.52	4.00±0.60	0.453
4-week follow-up					
RD (mm)	3.72±0.63	3.30±1.09	3.63±0.67	3.85±0.82	0.778
MLD (mm)	3.01±0.52	1.97±0.81	2.11±1.66	4.06±0.39	0.013
DS (%)	19.0±12.7	39.3±18.1	46.8±38.0	4.8±4.2	0.032
8-week follow-up					
RD (mm)	3.90±0.39	3.39±0.81	3.51±0.54	4.02±0.29	0.242
MLD (mm)	3.03±0.46	1.80±1.08	1.81±1.67	3.39±0.45	0.108
DS (%)	24.6±4.8	47.3±29.8	53.6±42.5	14.6±6.3	0.172

Group 1: bare-metal stent (BMS), Group 2: drug-free hybrid stent, Group 3: 50% PTX/PLGA (fast PTX releasing form) hybrid stent, Group 4: 30% PTX/PLGA (slow PTX releasing form) hybrid stent.

RD: reference diameter, MLD: minimal luminal diameter, DS: diameter stenosis

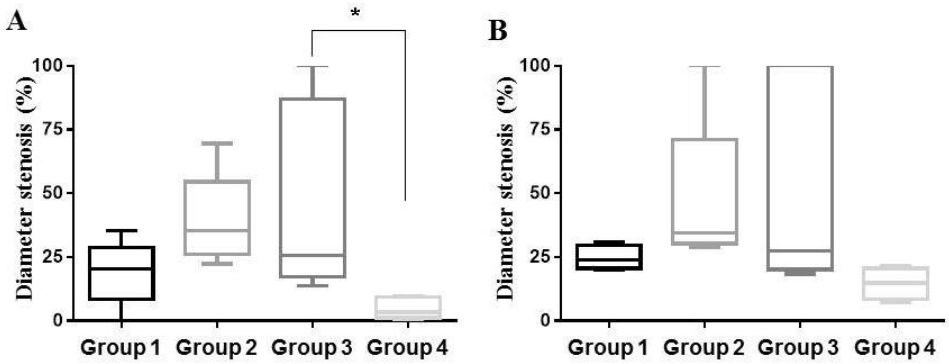

Figure 2. Comparison of diameter stenosis between groups (*p<0.05)

(A) At 4-week follow up. (B) At 8-week follow up.

G1 (Group 1): bare-metal stent (BMS), G2 (Group 2): drug-free hybrid stent, G3 (Group 3): 50% PTX/PLGA (fast PTX-releasing form) hybrid stent, G4 (Group 4): 30% PTX/PLGA (slow PTX-releasing form) hybrid stent

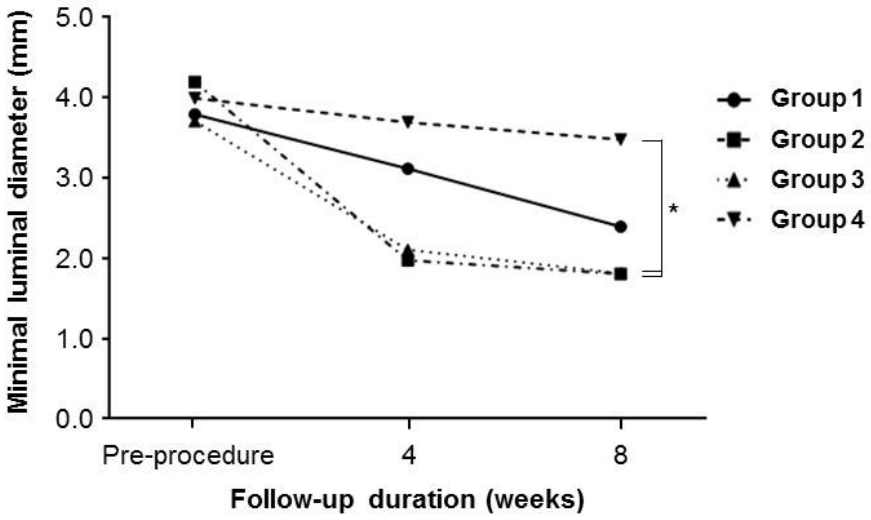

Figure 3. Serial changes in minimal luminal diameter at 4-week and 8-week follow-up (*p<0.05)

G1 (Group 1): bare-metal stent (BMS), G2 (Group 2): drug-free hybrid stent, G3 (Group 3): 50% PTX/PLGA (fast PTX-releasing form) hybrid stent, G4 (Group 4): 30% PTX/PLGA (slow PTX-releasing form) hybrid stent

2. IVUS analysis

The findings from IVUS imaging analyses are summarized in Table 2. IVUS imaging was not performed if angiography showed total in-stent occlusion. One lesion treated in Group 3 showed total occlusion at the 4-week follow-up; while one lesion treated in Group 2 and two lesions treated in Group 3 showed total occlusion at the 8-week follow-up. IVUS images obtained at the 4-week follow-up revealed that the lumen area of Group 4 was significantly larger than that of other groups. The neointimal area of the Group 4 stent also tended to be less than that of the other stents used, although this difference was not statistically significant. IVUS images obtained at the 8-week follow-up showed similar results, although no statistically significant differences were observed in the lumen and neointimal area. The stent area as measured by IVUS did not show statistically significant changes during the study periods across groups.

Table 2. Intravascular ultrasound findings of maximum neointimal site at 4-week and 8-week follow-up

	Group 1 (n=5)	**Group 2** (n=5)	**Group 3** (n=4)	**Group 4** (n=5)	***p***
4-week follow-up					
Stent area, mm^2	23.0±1.1	20.8±2.7	22.6±5.0	24.9±2.5	0.218
Lumen area, mm^2	12.9±6.4	8.4±3.3	10.2±5.2	18.2±4.3	0.037
Neointimal area, mm^2	10.0±5.8	12.4±3.3	12.6±4.7	6.8±3.7	0.196
Percentage of NIH (%)	44.3±25.9	59.8±14.7	56.1±17.4	27.4±15.3	0.072
8-week follow-up	(n=5)	(n=4)	(n=3)	(n=5)	
Stent area, mm^2	23.1±1.3	19.2±3.4	23.6±6.1	23.6±3.1	0.248
Lumen area, mm^2	9.5±2.7	7.5±3.7	12.5±3.9	12.9±2.2	0.072
Neointimal area, mm^2	13.6±1.9	11.7±1.6	11.2±2.6	10.7±3.8	0.379
Percentage of NIH (%)	59.1±10.4	62.6±14.8	47.5±4.9	44.5±12.0	0.104

Group 1: bare-metal stent (BMS), Group 2: drug-free hybrid stent, Group 3: 50% PTX/PLGA (fast PTX-releasing form) hybrid stent, Group 4: 30% PTX/PLGA (slow PTX-releasing form) hybrid stent

NIH: Neointimal hyperplasia

3. Histopathologic analysis

The findings from histopathologic assessment are presented in Table 3. All Group 1 (n=5) and Group 4 (n=5) stents revealed a low-grade inflammatory score (0 – 1) 8 weeks after stent implantation. Furthermore, all Group 4 stents showed a low-grade vessel injury score (0 – 1) at 8 weeks post-procedure. Figure 4 shows representative histologic images of each stent type.

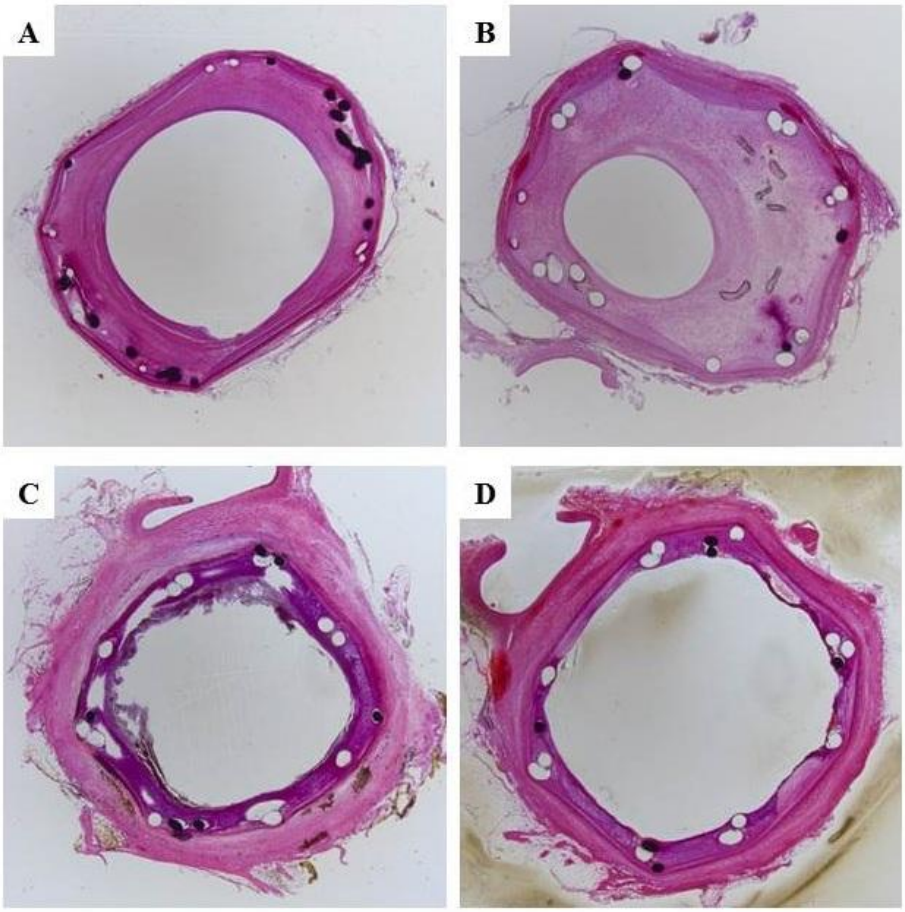

Figure 4. Representative histological images of each stent

(A) Bare-metal stent (Group 1) (B) Drug-free hybrid stent (Group 2) (C) 50% PTX/PLGA (fast PTX-releasing form) hybrid stent (Group 3) (D) 30% PTX/PLGA (slow PTX-releasing form) hybrid stent (Group 4)

Table 3. Histopathologic assessment of porcine iliac arteries 8 weeks after stenting

	Group 1 (n=5)	Group 2 (n=5)	Group 3 (n=5)	Group 4 (n=5)	*p*
Inflammatory score, n (%)					0.172
0 – 1	5 (100)	3 (60)	3 (60)	5 (100)	
2 – 3	0 (0)	2 (40)	2 (40)	0 (0)	
Vessel injury score, n (%)					0.414
0 – 1	3 (60)	3 (60)	3 (60)	5 (100)	
2 – 3	2 (40)	2 (40)	2 (40)	0 (0)	

Group 1: bare-metal stent (BMS), Group 2: drug-free hybrid stent, Group 3: 50% PTX/PLGA (fast PTX-releasing form) hybrid stent, Group 4: 30% PTX/PLGA (slow PTX-releasing form) hybrid stent

IV. DISCUSSION

The major findings of this study were: (1) our new hybrid biodegradable stents designed to be self-expanding with a knitting structure composed of PLLA and nitinol were easy to deploy without complication; and (2) the 30% PTX/PLGA (slow PTX-releasing form) hybrid stent effectively inhibited neointimal hyperplasia without inflammation and vascular injury when compared with the other stent types.

The necessity of a new biodegradable stent

Self-expandable nitinol stents have been developed for the treatment of femoropopliteal disease and primary nitinol stenting is recommended as a first-line treatment for superficial femoral artery lesions.[3,4,12] However, the high rate of in-stent restenosis is a major problem of endovascular treatment with metallic stents.[13] Furthermore, previous case reports have shown that nitinol stents have major limitations attributable to their metallic components, such as stent fracture or crushed stents.[14,15] Biodegradable scaffolds have clear advantages over metallic stents, not only for coronary intervention but also for peripheral artery revascularization, including lower incidence of adverse events such as thrombotic stent re-occlusion and stent fracture.[16,17] PLLA consists of a crystalline component of semi-crystalline polymer and is widely used in biodegradable scaffolds.[16,18] In general, in vivo studies investigating bioresorbable scaffolds have shown an initial reduction in molecular weight, a

decrease in radial support at about 6 months, loss in mass starting at 12 months, and subsequent completion at 24 months.[16,18,19] However, radial support for just 6 months may not be sufficient for peripheral artery intervention; considering that these arteries encounter a significant amount of compression, torsion, extension, and bending. In the present study, IVUS findings demonstrated that our new biodegradable stents did not show significant recoil during the 8 week follow-up period. These new biodegradable stents for the treatment of PAD are expected to provide superior radial support when compared with conventional bioresorbable scaffolds consisting only of PLLA.

Clinical implication of biodegradable stents

Several recent studies have suggested that clinical outcomes in patients treated with everolimus-eluting bioresorbable scaffolds for coronary artery revascularization are within the range for non-inferiority when compared with drug-eluting metallic stents.[20-23] A study by Werner et al. previously reported their experience with the use of a biodegradable balloon expandable stent composed of PLLA – the Igaki-Tamai biodegradable stent – for the treatment of de novo lesions in the femoral artery.[6] The authors demonstrated excellent short-term results, however, sustainable luminal patency over time and the inflammatory reaction continue to be a concern. That bioabsorbable polymer is more likely to be associated with an inflammatory reaction than a nitinol-based BMS. The results of the present study found that a 30% PTX/PLGA (slow PTX-releasing form) hybrid stent showed a low level of inflammation comparable to that of BMS. Therefore, our new hybrid biodegradable drug-eluting stent for the

treatment of PAD has potential clinical benefits by reducing the inflammatory reaction after stent implantation. Furthermore, we expect that our new hybrid biodegradable stent will enable vascular surgeons to easily perform surgical procedures on stenting lesions after stent restenosis.

Pharmacokinetic results

The present study demonstrated that the 30% PTX/PLGA (slow PTX-releasing form) hybrid stent in Group 4 was associated with inhibition of in-stent neointimal hyperplasia when compared with the drug-free hybrid stent (Group 2) and the 50% PTX/PLGA (fast PTX-releasing form) hybrid stent (Group 3). A study to evaluate the kinetics of paclitaxel release on the neointima showed that the longer-releasing paclitaxel-eluting stent had the best results on the inhibition of in-stent neointimal hyperplasia.[24] Our findings too suggested that the duration of paclitaxel release had a significant impact on the suppression of in-stent neointimal hyperplasia. While clear reasons for these results are uncertain, it is hypothesized that the inhibition of the proliferative reaction requires a minimum period of time.

Limitations

This study had several limitations. First, this study was not based on the atherosclerotic porcine peripheral artery model. Therefore, the results of the present study require caution when applied to a clinical setting for the treatment

of atherosclerotic PAD. Second, the statistical power of our findings was not sufficient due to a relatively small sample size and short study period. However, angiography results were statistically significant at the 4-week follow-up and IVUS findings were similar to these quantitative imaging analysis results. Third, we were not able to fully evaluate the total occluded stent segments by IVUS. However, we analyzed all histopathologic assessment regardless of total occlusion.

V. CONCLUSION

Our new self-expandable, biodegradable 30% PTX/PLGA (slow-releasing form) stent was successfully implanted to all iliac arteries and showed the most favorable results for patency and safety when compared with the other stent types. These findings strongly suggest the need for further, large-scale, and long-term experimental study aimed at clinical application. However, our study provides new concepts for developing a new biodegradable stent for the treatment of PAD.

REFERENCES

1. Dormandy JA, Rutherford RB. Management of peripheral arterial disease (PAD). TASC Working Group. TransAtlantic Inter-Society Consensus (TASC). J Vasc Surg 2000;31:S1-S296.

2. Schillinger M, Sabeti S, Loewe C, Dick P, Amighi J, Mlekusch W, et al. Balloon angioplasty versus implantation of nitinol stents in the superficial femoral artery. N Engl J Med 2006;354:1879-88.

3. Schillinger M, Sabeti S, Dick P, Amighi J, Mlekusch W, Schlager O, et al. Sustained benefit at 2 years of primary femoropopliteal stenting compared with balloon angioplasty with optional stenting. Circulation 2007;115:2745-9.

4. Dick P, Wallner H, Sabeti S, Loewe C, Mlekusch W, Lammer J, et al. Balloon angioplasty versus stenting with nitinol stents in intermediate length superficial femoral artery lesions. Catheter Cardiovasc Interv 2009;74:1090-5.

5. Scheinert D, Scheinert S, Sax J, Piorkowski C, Braunlich S, Ulrich M, et al. Prevalence and clinical impact of stent fractures after femoropopliteal stenting. J Am Coll Cardiol 2005;45:312-5.

6. Werner M, Micari A, Cioppa A, Vadala G, Schmidt A, Sievert H, et al. Evaluation of the biodegradable peripheral Igaki-Tamai stent in the treatment of

de novo lesions in the superficial femoral artery: the GAIA study. JACC Cardiovasc Interv 2014;7:305-12.

7. Bunger CM, Grabow N, Sternberg K, Goosmann M, Schmitz KP, Kreutzer HJ, et al. A biodegradable stent based on poly(L-lactide) and poly(4-hydroxybutyrate) for peripheral vascular application: preliminary experience in the pig. J Endovasc Ther 2007;14:725-33.

8. Institute of Laboratory Animal Resources (U.S.), Guide for the Care and Use of Laboratory Animals, National Academy Press, Washington, DC, USA, 1996.

9. Mintz GS, Nissen SE, Anderson WD, Bailey SR, Erbel R, Fitzgerald PJ, et al. American College of Cardiology Clinical Expert Consensus Document on Standards for Acquisition, Measurement and Reporting of Intravascular Ultrasound Studies (IVUS). A report of the American College of Cardiology Task Force on Clinical Expert Consensus Documents. J Am Coll Cardiol 2001;37:1478-92.

10. Schwartz RS, Huber KC, Murphy JG, Edwards WD, Camrud AR, Vlietstra RE, et al. Restenosis and the proportional neointimal response to coronary artery injury: results in a porcine model. J Am Coll Cardiol 1992;19:267-74.

11. Lim SY, Jeong MH, Hong SJ, Lim do S, Moon JY, Hong YJ, et al. Inflammation and delayed endothelization with overlapping drug-eluting stents in a porcine model of in-stent restenosis. Circ J 2008;72:463-8.

12. European Stroke O, Tendera M, Aboyans V, Bartelink ML, Baumgartner I, Clement D, et al. ESC Guidelines on the diagnosis and treatment of peripheral artery diseases: Document covering atherosclerotic disease of extracranial carotid and vertebral, mesenteric, renal, upper and lower extremity arteries: the Task Force on the Diagnosis and Treatment of Peripheral Artery Diseases of the European Society of Cardiology (ESC). Eur Heart J 2011;32:2851-906.

13. Schlager O, Dick P, Sabeti S, Amighi J, Mlekusch W, Minar E, et al. Long-segment SFA stenting--the dark sides: in-stent restenosis, clinical deterioration, and stent fractures. J Endovasc Ther 2005;12:676-84.

14. Suh Y, Ko YG, Lee SH, Kim MD, Choi D. Crushed stent with acute occlusion in superficial femoral artery after enhanced external counterpulsation. JACC Cardiovasc Interv 2014;7:e141-2.

15. Lee YJ, Shin DH, Kim JS, Kim BK, Ko YG, Hong MK, et al. Femoropopliteal Artery Stent Fracture with Recurrent In-Stent Reocclusion and Aneurysm Formation: Successful Treatment with Self-Expandable Viabahn Endoprosthesis. Korean Circ J 2015;45:522-5.

16. Onuma Y, Serruys PW. Bioresorbable scaffold: the advent of a new era in percutaneous coronary and peripheral revascularization? Circulation 2011;123:779-97.

17. Ormiston JA, Serruys PW. Bioabsorbable coronary stents. Circ Cardiovasc Interv 2009;2:255-260.

18. Oberhauser JP, Hossainy S, Rapoza RJ. Design principles and performance of bioresorbable polymeric vascular scaffolds. EuroIntervention 2009;5 Suppl F:F15-22.

19. Prabhu S, Hossainy S. Modeling of degradation and drug release from a biodegradable stent coating. J Biomed Mater Res A 2007;80:732-41.

20. Ellis SG, Kereiakes DJ, Metzger DC, Caputo RP, Rizik DG, Teirstein PS, et al. Everolimus-Eluting Bioresorbable Scaffolds for Coronary Artery Disease. N Engl J Med 2015;373:1905-15.

21. Gao R, Yang Y, Han Y, Huo Y, Chen J, Yu B, et al. Bioresorbable Vascular Scaffolds Versus Metallic Stents in Patients With Coronary Artery Disease: ABSORB China Trial. J Am Coll Cardiol 2015;66:2298-309.

22. Serruys PW, Chevalier B, Dudek D, Cequier A, Carrie D, Iniguez A, et al. A bioresorbable everolimus-eluting scaffold versus a metallic everolimus-eluting stent for ischaemic heart disease caused by de-novo native coronary artery lesions (ABSORB II): an interim 1-year analysis of clinical and procedural secondary outcomes from a randomised controlled trial. Lancet 2015;385:43-54.

23. Kimura T, Kozuma K, Tanabe K, Nakamura S, Yamane M, Muramatsu T, et al. A randomized trial evaluating everolimus-eluting Absorb bioresorbable scaffolds vs. everolimus-eluting metallic stents in patients with coronary artery disease: ABSORB Japan. Eur Heart J 2015;36:3332-42.

24. Serruys PW, Sianos G, Abizaid A, Aoki J, den Heijer P, Bonnier H, et al. The effect of variable dose and release kinetics on neointimal hyperplasia using a novel paclitaxel-eluting stent platform: the Paclitaxel In-Stent Controlled Elution Study (PISCES). J Am Coll Cardiol 2005;46:253-60.

APPENDICES

Abbreviation lists

PAD = peripheral artery disease, PLLA = poly-L-lactic acid, BMS = bare-metal stent, PTX = paclitaxel, PLGA = poly-lactide-co-glycolic acid, IVUS = intravascular ultrasound, DMSO = ethanol dimethyl sulfoxide, MLD = minimal lumen diameter, RD = reference diameter, DS = diameter stenosis, EEM = external elastic membrane, P&M = plaque and media, GMA = glycol methacrylate

ABSTRACT(IN KOREAN)

말초혈관용 하이브리드 생분해성 약물 용출 스텐트 개발

<지도교수 고영국>

연세대학교 대학원 의학과

이 중 희

배경: 말초동맥 질환의 치료에 있어서 금속 스텐트를 이용한 혈관 성형술은 그 치료효과가 우수함에도 불구하고, 금속 자체의 특성으로 인한 한계점을 가지고 있다. 하지만, 말초동맥 질환의 치료에 이용 가능한 생분해성 스텐트는 아직 임상적 근거가 부족한 실정이며, 새로운 생분해성 스텐트 개발에 있어서 전임상 단계의 실험 모델도 매우 부족한 현실이다.

목적: 본 연구의 목적은 말초혈관 질환의 치료에 사용 가능하도록 충분한 지지력(radial force)을 가지고, 유연성(flexibility)을 가지며, 장기적으로도 개방성(patency)을 유지할 수 있는 새로운 말초혈관용 하이브리드 생분해성 약물 용출 스텐트를 개발함에 있다.

방법: 본 연구에 사용된 하이브리드 생분해성 스텐트는 니티놀(nitinol)과 poly-L-lactic acid(PLLA)가 knitting structure로 결합된 자가팽창형(self-expandable) 스텐트이다. 본 실험에서는 다음과 같이 4가지의 서로 다른 스텐트가 총 10마리의 미니돼지(mini pig) 양쪽 장골동맥(20 iliac arteries)에 무작위로 삽입 되었다: 금속 스텐트(bare-metal stent) (Group 1, n=5), 약물이 없는 하이브리드 스텐트 (Group 2,

n=5), 50% (50:100, w/w) paclitaxel(PTX)/poly-lactide-co-glycolic acid(PLGA) (빠른 PTX방출 형태) 스텐트 (Group 3, n=5), 30% (30:100, w/w) PTX/PLGA (느린 PTX방출 형태) 스텐트 (Group 4, n=5). 스텐트 삽입한 뒤 4주 및 8주째 혈관 조영술과 혈관 내 초음파(intravascular ultrasound, IVUS)를 시행 했으며, 8주째 실험 이후에는 미니돼지의 장골동맥 조직을 채취하여 조직학적 분석을 실시하였다.

결과: 실험에 사용된 스텐트는 합병증 없이 모두 성공적으로 삽입이 되었다. 4주 째 시행한 혈관 조영술 상에서, Group 4 스텐트는 나머지 Group 1,2,3 스텐트에 비해 스텐트 내 재협착의 발생이 유의하게 낮았고 (Group 1 vs. 2 vs. 3 vs. 4= 19.0±12.7% vs. 39.3±18.1% vs. 46.8±38.0% vs. 4.8±4.2%; p=0.032), IVUS상에서도 Group 4 스텐트 삽입 부위에 신생 내막(neointima)의 증식이 다른 스텐트에 비해 적음을 알 수 있었다. 또한, 스텐트 삽입 후 8주째까지 IVUS 상에서 스텐트 내 면적은 변화가 없어, 스텐트 recoil현상은 발생하지 않았음을 알 수 있었다. 조직학적 분석에서는 Group 4 스텐트를 삽입 했을 때, 혈관 손상(vascular trauma) 및 염증 반응(inflammatory reaction)이 적게 발생함을 볼 수 있었다.

결론: 본 실험에서 사용된 30% PTX/PLGA (느린 PTX방출 형태) 하이브리드 생분해성 스텐트는 다른 종류의 스텐트에 비해 혈관 개통성 및 안정성에 있어서 우수한 결과를 보여주었다. 본 연구는 말초혈관 질환의 치료에 사용될 수 있는 생분해성 스텐트 개발에 새로운 개념을 선사했다는 것에 큰 의의를 둘 수 있겠다.

핵심되는 말 : 약물방출 스텐트, 생분해성, 말초동맥 질환