



저작자표시-비영리-변경금지 2.0 대한민국

이용자는 아래의 조건을 따르는 경우에 한하여 자유롭게

- 이 저작물을 복제, 배포, 전송, 전시, 공연 및 방송할 수 있습니다.

다음과 같은 조건을 따라야 합니다:



저작자표시. 귀하는 원저작자를 표시하여야 합니다.



비영리. 귀하는 이 저작물을 영리 목적으로 이용할 수 없습니다.



변경금지. 귀하는 이 저작물을 개작, 변형 또는 가공할 수 없습니다.

- 귀하는, 이 저작물의 재이용이나 배포의 경우, 이 저작물에 적용된 이용허락조건을 명확하게 나타내어야 합니다.
- 저작권자로부터 별도의 허가를 받으면 이러한 조건들은 적용되지 않습니다.

저작권법에 따른 이용자의 권리는 위의 내용에 의하여 영향을 받지 않습니다.

이것은 [이용허락규약\(Legal Code\)](#)을 이해하기 쉽게 요약한 것입니다.

[Disclaimer](#)

Feasibility of three-dimensional
reconstruction and automated
measurement of fetal long bones using
5D Long Bone™



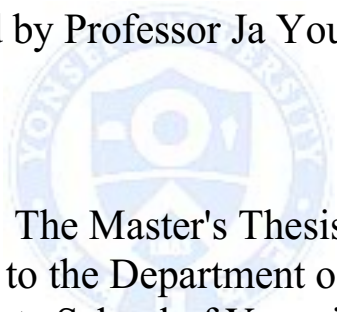
Hyewon Hur

Department of Medicine

The Graduate School, Yonsei University

Feasibility of three-dimensional
reconstruction and automated
measurement of fetal long bone using
5D Long Bone™

Directed by Professor Ja Young Kwon



The Master's Thesis
submitted to the Department of Medicine,
the Graduate School of Yonsei University
in partial fulfillment of the requirements for the degree
of Master of Medical Science

Hyewon Hur

June 2015

This certifies that the Master's Thesis of
Hyewon Hur is approved.

Thesis Supervisor: Ja Young Kwon

Thesis Committee Member#1: Jinna Kim

Thesis Committee Member#2: EunJi Nam



The Graduate School
Yonsei University

June 2015

ACKNOWLEDGEMENTS

I would like to express my sincere gratitude to Professor Ja Young Kwon for her guidance and support. I also thank Professor Jinna Kim, Professor EunJi Nam for their valuable comments and Bo Hyon Yun for helping with the examination of fetal ultrasonography.

Finally, thank you to my family for their continued love and support.



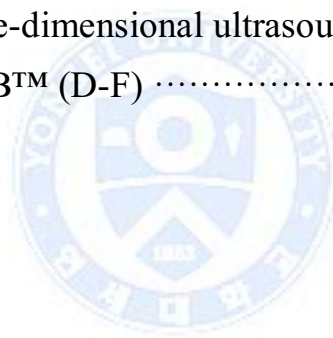
<TABLE OF CONTENTS>

ABSTRACT	1
I. INTRODUCTION	3
II. MATERIALS AND METHODS	5
1. Study population	5
2. Lower limb long bone length measurement	5
3. Statistical analysis	7
III. RESULTS	8
IV. DISCUSSION	13
V. CONCLUSION	18
REFERENCES	19
ABSTRACT(IN KOREAN)	22



LIST OF FIGURES

Figure1. Three-dimensional ultrasound images showing initial planes for three-dimensional volume acquisition of femur longitudinal-90(A), femur longitudinal-45 (B), and the tibia and fibula (C)	6
Figure2. Long bone measurement by 5D Long Bone™	7
Figure3. Bland–Altman plots showing variability in long bone lengths measurements using two-dimensional ultrasound (2D-US) and three-dimensional ultrasound (3D-US) (A-C), 2D-US and 5D LB™ (D-F)	12



LIST OF TABLES

Table 1. Success rate, error rate and fail rate of measurements of the femur (longitudinal-90, longitudinal-45), tibia and fibula by 5D LB TM	8
Table 2. Comparison of femur length measurement by three-dimensional ultrasound (3D-US) and 5D LB TM in relation to volume sweeping angles	9
Table 3. Intraobserver agreement in long bone measurement for each technique : two-dimensional ultrasound (2D-US), three-dimensional ultrasound (3D-US) and 5D LB TM	10
Table 4. Interobserver agreement in long bone measurement for each technique : two-dimensional ultrasound (2D-US), three-dimensional ultrasound (3D-US) and 5D LB TM	11
Table 5. Comparison of long bone measurement techniques by comparing three-dimensional ultrasound (3D-US) and 5D LB TM measurements with the two-dimensional ultrasound (2D-US) measurements	11
Table 6. Comparison of long bone measurement techniques by comparing three-dimensional ultrasound(3D-US) and 5D LB TM measurements with the two-dimensional ultrasound (2D-US) measurements	12

ABSTRACT

Feasibility of three-dimensional reconstruction and automated measurement of fetal long bones using 5D Long Bone™

Hyewon Hur

*Department of Medicine
The Graduate School, Yonsei University*

(Directed by Professor Ja Young Kwon)

Objective: To evaluate the feasibility of 5D Long Bone™ (5D LB™), a new technique that automatically archives, reconstructs images, and measures lengths of fetal long bones, to assess whether the direction of volume sweep influences fetal long bone measurements in three-dimensional (3D) ultrasound and 5D LB™, and to compare measurements of fetal long bone lengths obtained with 5D LB™ and those obtained with conventional two-dimensional (2D) and manual 3D techniques.

Methods: This prospective study included 39 singleton pregnancies at 26+0 to 32+0 weeks of gestation. Multiple pregnancies, fetuses with multiple congenital anomalies, and mothers with underlying medical diseases were excluded. Fetal long bones of the lower extremities—the femur, tibia, and fibula were measured by 2D and 3D ultrasound, and 5D LB™, by an expert and non-expert examiner. First, we analyzed the 3D ultrasound and 5D LB™ data according to 2 different sweeping angles. We analyzed intra- and interobserver variability and agreement between ultrasound techniques. Paired t-test, interclass correlation coefficient

(ICC), Bland-Altman plot and Passing-Bablok regression were used for statistical analysis.

Results: There was no statistical difference between long bone measurements analyzed according to 2 different volume-sweeping angles by 3D ultrasound and 5D LB™. Intra- and interobserver variability were not significantly different among all 3 ultrasound techniques. Comparing 2D ultrasound and 5D LB™, the ICC for femur, tibia, and fibula was 0.91, 0.92, and 0.89, respectively.

Conclusion: 5D LB™ is reproducible and comparable with conventional 2D and 3D ultrasound techniques for fetal long bone measurement.



Key words :fetal long bone; fetal biometry ; two-dimensional ultrasonography; three-dimensional ultrasonography; 5D Long Bone™

Feasibility of three dimensional reconstruction and automated measurement of fetal long bones using 5D Long Bone™

Hyewon Hur

*Department of Medicine
The Graduate School, Yonsei University*

(Directed by Professor Ja Young Kwon)

I. INTRODUCTION

During the process of long bone measurement, locating precise anatomic plane to perform ultrasound biometry and reducing inter- and intra-operator measurement error are critical for diagnosis. With respect to fetal ultrasonography, the biometry of the fetal femur is technically simple due to the one-dimensional nature of the measurement. However, unlike the proximal extremities, the long bones of the distal areas can be difficult to measure. For example, in the distal upper and lower limbs, radius and ulna, and tibia and fibula, the paired bones are located too close together for proper differentiation. Other exacerbating factors, including constant fetal movements, the consequent variation in fetal position, degree of the expectant mother's obesity, quantity of the amniotic fluid, and location of the placenta further aggravate the difficulty in making proper measurements.

In conventional two-dimensional (2D) ultrasonography, the sonographer must manipulate the transducer accordingly to locate an appropriate plane for fitting measurements. The 2D-ultrasonography is also burdensome as sonographers must meet with patients directly to conduct a lengthy examination. Furthermore, the accuracy of diagnosis and construction of images

mainly depend on the degree of the sonographer's experience and expertise. However, the newer three-dimensional (3D) ultrasonography scans volume data in a short period of time and reconstruct a 3D image, which can be cut into multiple sections for further manipulation to obtain precise plane much like the saved images of computed tomography (CT) or magnetic resonance imaging (MRI). 3D-ultrasonography is also particularly useful in that the saved images allow diagnostic deliberation by the sonographer even after the examination ends and the patient is unavailable for further testing. Recently published studies have verified the utility of 3D-ultrasonography in various diagnostic areas, including fetal biometry, skeletal dysplasia, facial anomaly, and fetal echocardiography.¹⁻⁵ However, three-dimensional ultrasonography also requires the manipulation of 3D volume data to reconstruct the images, which requires time and effort. Furthermore, such manipulation efforts also depend on the expertise and experience of the sonographer.

To compensate for these weaknesses, long bone automated detection system, 5D LB™ was made available to streamline the process of reconstructing the lower limb long bone images and performing fetal biometry. The present study compared the biometric data of conventional 2D-ultrasonography, manually manipulated 3D volume data, and 5D LB™-treated 3D volume data to determine the feasibility of 5D LB™ functions in light of other available methods.

II. MATERIALS AND METHODS

1. Study population

This study was performed with 39 pregnant women with singleton pregnancies at 26 + 0 to 32 + 0 weeks of gestation who visited the Department of obstetrics at the Yonsei University Health System between August and September 2011. Subjects with fetal abnormality was suspected on ultrasound examination, those who had a medicosurgical disease, or multiple pregnancies were excluded from the study. This study was approved by the institutional review board and informed consent was obtained from all the participants.

2. Lower limb long bone length measurement

One experienced operator (Operator 1, a Maternal–Fetal Medicine Clinical Instructor) and one inexperienced operator (Operator 2, two gynecology residents) participated in the ultrasound examination. Every two- dimensional and three- dimensional ultrasound examination was performed twice, once by the inexperienced operator and again by the experienced operator. Each ultrasound scanned the proximal (femur) and distal (tibia and fibula) areas of the long bones of the right lower limb. For the measurement, the Accuvix V20 Prestige (Medison Co., Ltd., Seoul, Korea) was used. For 2D-ultrasound measurements, a 2–6MHz transabdominal ultrasound transducer was used and 3D volume data were acquired using a 4–8MHz volume transducer.

For 2D-ultrasound measurement, the transducer was aligned to the long axis of the diaphysis, and the image was captured and used to measure the length. To obtain 3D volume data, the entire bone length of the femur was identified on the screen, as in the 2D-ultrasound measurement, and the long axis of the femur was placed in the direction of the x-axis in the image in which the ultrasound beam was perpendicular to the bone. The femur was included in the volume box such that the bone length occupied about 80% of the entire image, and the

volume data were captured using 3D scanning (Figure 1A).

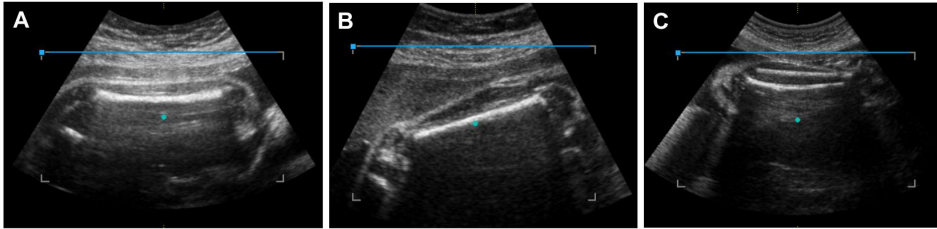


Figure 1. Three-dimensional ultrasound images showing the initial planes for three-dimensional volume acquisition of femur longitudinal-90(A), femur longitudinal-45 (B), and the tibia and fibula (C).

These data were designated the longitudinal-90 (long-90) set. Then, the femur was rotated clockwise or counterclockwise by 45 degrees on the screen, and the volume data were again captured using 3D scanning (Figure 1B). These data were designated the longitudinal-45 (long-45) set. The distal lower extremity bones, i.e., the right tibia and fibula, were measured similarly: the entire bone length was identified on the screen, the long axis of the bones was placed in the direction of the x-axis in the image, as was femur long-90 and the volume data were captured using 3D scanning (Figure 1C).

The 3D-ultrasonograph long bone length was measured offline by a maternal-fetal medicine specialist (J.Y.K.) who had not participated in the ultrasonograph measurements. The acquired volume data were reconstructed in a multiplanar mode to adjust the x, y, and z-axes of each plane. Then, an appropriate plane was located for the long bone length measurements of the right lower limb.

Subsequently, the long bone length was measured using the 5D LB™ with the following procedures. The volume data used in the manual 3D-ultrasound

measurement were displayed in an offline multiplanar mode, and the 5D LBTM set key was pressed on the system, wherein the system automatically analyzed the 3D volume data, reconstructed the 3D image of the long bones, and displayed the measured lengths of the long bones on the screen (Figure 2).

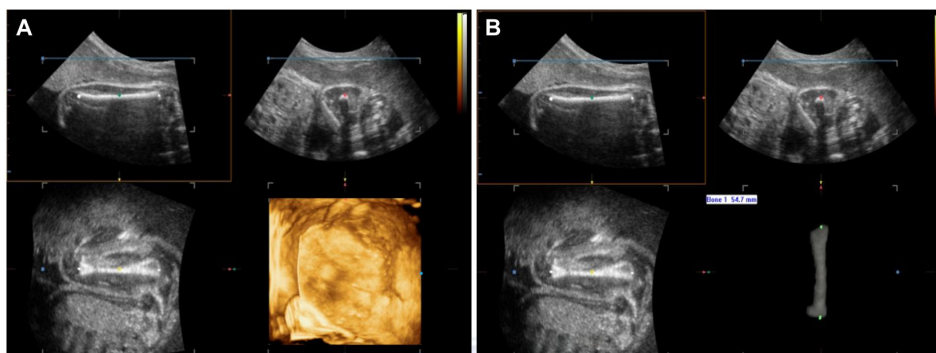


Figure 2. Long bone measurement by 5D Long BoneTM(5D LBTM). The three-dimensional volume data were displayed in the multiplanar mode (A) and the 5D LBTM set key was pressed. The system reconstructed a three-dimensional image of the long bones and the length of the long bone was measured automatically (B).

3. Statistical analysis

Statistical analysis was performed using the SPSS version 18.0 (SPSS Inc., Chicago, IL, USA) and MedCalc version 12.7 (MedCalc Software, Ostend, Belgium). The Kolmogorov–Smirnov test was used to test the normal distribution of the measurement data. The paired *t*-test was performed to analyze intra–interobserver variability. Agreement was analyzed by using Bland–Altman plot, Passing–Bablok regression and calculating the interclass correlation coefficient (ICC). P-value of <0.05 was considered statistically significant.

III. RESULTS

To measure the length of the fetal femur, tibia, and fibula using different methods, two operators performed 2D and 3D-ultrasound examinations with a total of 39 subjects two times each. Of the 624 total 5D LBTM measurements, the overall success rate was 86.2% (538/624); the overall failure rate, 8.3% (52/624); and the overall error rate, 5.4% (34/624). For the femur, the success rate of long-90 measurement was 91.0% (142/156) and that of long-45 measurement was 96.1% (150/156). As such, the long-45 success rate was slightly higher than that of the long-90. The success rate was lower for the measurements of the tibia (80.7% (126/156)) and fibula (76.9% (120/156)), in which the length of both bones was measured simultaneously, than for the measurements of the femur (Table 1).

Table 1 Success rate, error rate and fail rate of measurements of the femur (longitudinal-90, longitudinal-45), tibia and fibula by 5D LBTM

	Femur		Tibia	Fibula	Total
	Long – 90	Long – 45			
Success rate (n (%))	142 (91.0)	150 (96.1)	126 (80.7)	120 (76.9)	538 (86.2)
Error rate (n (%))	10 (6.4)	6 (3.8)	8 (5.1)	10 (6.4)	34 (5.4)
Fail rate (n (%))	4 (2.5)	0 (0)	22 (14.1)	26 (16.6)	52 (8.3)

5D LBTM, five dimensional Long BoneTM; Long-90, longitudinal-90; long-45, longitudinal-45

To examine the variation in the long bone length measurements depending on the volume scanning angles in the 3D-ultrasonography, the variability and agreement were analyzed between the femur long-90 and femur long-45 measurements obtained by manual 3D-ultrasonography and 5D LBTM. As shown in Table 2, neither 3D-ultrasonography nor 5D LBTM exhibited a

significant difference in measurement values between the different scanning angles. In fact, the scanning angles exhibited an ICC >0.9, showing a high level of agreement. Consequently, long-90 data were used in all subsequent analyses.

Table 2 Comparison of femur length measurement by three-dimensional ultrasound (3D-US) and 5D LBTM in relation to volume sweeping angles

Measurement technique	Mean diff±SD (cm)	95% CI (cm)	P	ICC (95% CI)
3D-US				
Operator 1	-0.01±0.15	-0.04 to 0.02	0.55	0.935 (0.898 to 0.959)
Operator 2	0.02±0.18	-0.19 to 0.06	0.26	0.904 (0.847 to 0.940)
5D LB TM				
Operator 1	0.03±0.15	-0.02 to 0.09	0.23	0.922 (0.835 to 0.963)
Operator 2	0.01±0.18	-0.19 to 0.06	0.26	0.938 (0.857 to 0.973)

3D-US, three-dimensional ultrasound; CI, confidence interval; ICC, interclass correlation coefficient; 5D LBTM, five dimensional Long BoneTM; SD, standard deviation

The intra- and inter-observer variability and reproducibility were analyzed with respect to the three measurement methods, and the results showed no significant differences among the methods; in fact, a rather high degree of agreement was noted (Tables 3 and 4).

Then, the measurement values of 3D-ultrasonography and 5D LBTM were compared with the standard 2D-ultrasound measurement values to verify the reproducibility of the two former methods. When the 3D-ultrasonography and 5D LBTM methods were compared with the 2D-ultrasonography, the measurement values did not exhibit a significant difference. The ICC was >0.89 and the Bland–Altman plot showed an even distribution near zero (Table 5, Figure 3). Passing-Bablok Regression showed no significant systemic or proportional differences (Table 6).

Table 3 Intraobserver agreement in long bone measurement for each technique : two-dimensional ultrasound (2D-US), three-dimensional ultrasound (3D-US) and 5D LB™

Measurement technique	Operator 1				Operator 2			
	Mean diff ± SD (cm)	95% CI of mean diff (cm)	P	ICC (95% CI)	Mean diff ± SD (cm)	95% CI of mean diff (cm)	P	ICC (95% CI)
2D-US								
Femur	0.02±0.02	-0.04 to 0.09	0.42	0.950 (0.885-0.976)	0.00±0.07	-0.01 to 0.03	0.39	0.968 (0.939-0.983)
Tibia	0.02±0.02	-0.04 to 0.02	0.76	0.970 (0.942-0.984)	0.02±0.12	-0.01 to 0.06	0.31	0.900 (0.816-0.946)
Fibula	0.02±0.02	-0.04 to 0.02	0.26	0.932 (0.869-0.965)	0.01±0.12	-0.03 to 0.05	0.59	0.887 (0.792-0.940)
3D-US								
Femur	0.00±0.06	-0.02 to 0.01	0.82	0.981 (0.964-0.990)	0.00±0.09	-0.03 to 0.03	0.95	0.961 (0.924-0.980)
Tibia	0.02±0.07	0.00 to 0.04	0.09	0.966 (0.934-0.983)	0.01±0.10	-0.02 to 0.04	0.52	0.921 (0.851-0.959)
Fibula	0.00±0.07	-0.02 to 0.02	0.81	0.966 (0.934-0.982)	0.00±0.06	-0.01 to 0.02	0.57	0.973 (0.948-0.986)
5D LB™								
Femur	0.00±0.00			1.0	0.00±0.00			1.0
Tibia	0.00±0.00			1.0	0.00±0.00			1.0
Fibula	0.00±0.00			1.0	0.00±0.00			1.0

2D-US two-dimensional ultrasound; 3D-US, three-dimensional ultrasound; CI, confidence interval; diff, difference between pairs of measurements; ICC, interclass correlation coefficient; 5D LB™, five dimensional Long Bone™; SD, standard deviation

Table 4 Interobserver agreement in long bone measurement for each technique : two-dimensional ultrasound (2D-US), three-dimensional ultrasound (3D-US) and 5D LBTM

	Mean diff±SD (cm)	95% CI (cm)	P	ICC (95% CI)
2D-US				
Femur	-0.01±0.12	-0.05 to 0.02	0.55	0.915 (0.840-0.955)
Tibia	0.06±0.12	-0.04 to 0.04	0.98	0.902 (0.819-0.948)
Fibula	-0.01±0.17	-0.07 to 0.04	0.60	0.902 (0.803-0.950)
3D-US				
Femur	-0.04±0.17	-0.08 to 0.00	0.06	0.921 (0.872-0.951)
Tibia	0.00±0.12	-0.03 to 0.02	0.84	0.894 (0.834-0.932)
Fibula	-0.02±0.16	-0.06 to 0.01	0.15	0.897 (0.828-0.938)
5D LBTM				
Femur	-0.03±0.11	-0.07 to 0.00	0.12	0.903 (0.874-0.950)
Tibia	-0.01±0.10	-0.06 to 0.02	0.35	0.903 (0.869-0.955)
Fibula	-0.02±0.09	-0.05 to 0.00	0.17	0.895 (0.810-0.958)

2D-US two-dimensional ultrasound; 3D-US, three-dimensional ultrasound; CI, confidence interval; diff, difference between pairs of measurements; ICC, interclass correlation coefficient; 5D LBTM, five dimensional Long BoneTM; SD, standard deviation

Table 5 Comparison of long bone measurement techniques by comparing three-dimensional ultrasound (3D-US) and 5D LBTM measurements with the two-dimensional ultrasound (2D-US) measurements

	Mean diff±SD (cm)	95% CI (cm)	P	ICC (95% CI)
2D-US vs 3D-US				
Femur	-0.02±0.16	-0.08 to 0.02	0.34	0.893 (0.832-0.922)
Tibia	0.01±0.16	-0.03 to 0.07	0.51	0.891 (0.787-0.958)
Fibula	-0.02±0.11	-0.06 to 0.01	0.16	0.894 (0.881-0.955)
2D-US vs 5D LBTM				
Femur	0.00±0.06	-0.02 to 0.01	0.65	0.912 (0.874-0.961)
Tibia	0.00±0.16	-0.05 to 0.06	0.92	0.922 (0.877-0.967)
Fibula	-0.02±0.11	-0.11 to 0.01	0.12	0.897 (0.822-0.956)

2D-US two-dimensional ultrasound; 3D-US, three-dimensional ultrasound; CI, confidence interval; diff, difference between pairs of measurements; ICC, interclass correlation coefficient; 5D LBTM, five dimensional Long BoneTM; SD, standard deviation

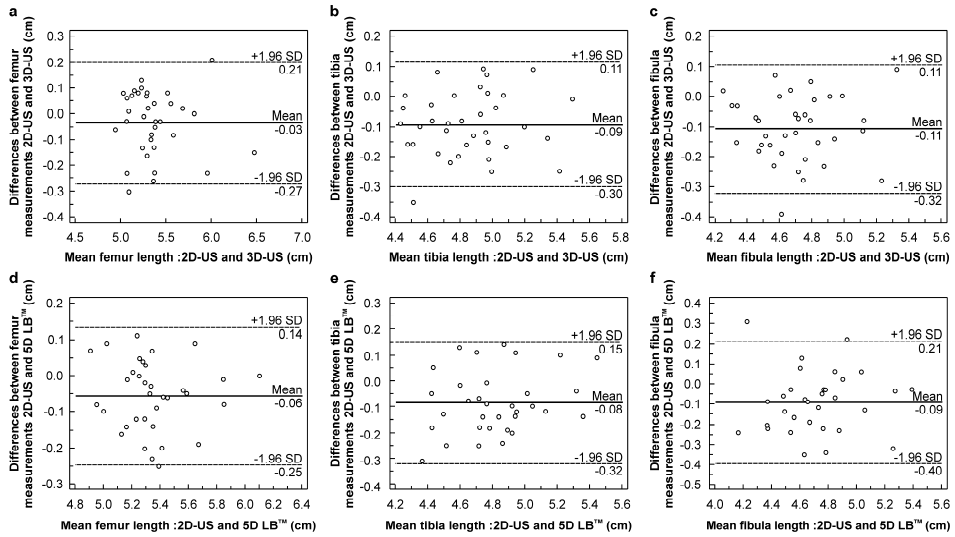


Figure 3. Bland–Altman plots showing variability in long bone lengths measurements using two-dimensional ultrasound (2D-US) and three-dimensional ultrasound (3D-US) (A–C), 2D-US and 5D LB™ (D–F).

Table 6 Comparison of long bone measurement techniques by comparing three-dimensional ultrasound (3D-US) and 5D LB™ measurements with the two-dimensional ultrasound (2D-US) measurements

	Slope (95% CI)	Intercept (95% CI)
2D-US vs 3D-US		
Femur	0.89 (0.77 to 1.08)	0.52 (-0.45 to 1.17)
Tibia	1.06 (0.90 to 1.25)	-0.40 (-1.30 to 0.36)
Fibula	1.01 (0.84 to 1.18)	-0.09 (-0.96 to 0.65)
2D-US vs 5D LB™		
Femur	0.95 (0.80 to 1.10)	0.21 (-0.62 to 1.01)
Tibia	1.02 (0.89 to 1.23)	-0.21 (-1.25 to 0.41)
Fibula	1.04 (0.81 to 1.35)	-0.29 (-1.76 to 0.77)

2D-US two-dimensional ultrasound; 3D-US, three-dimensional ultrasound; 5D LB™, five dimensional Long Bone™; CI, confidence interval

IV. DISCUSSION

Ultrasound examination can be safely applied to women of childbearing age or pregnant women because it does not use ionizing radiation and is able to obtain real-time tomograms of any region depending on the position at which the sonographer places the probe. In addition, the newer 3D-ultrasonograph method can reconstruct the images from saved volume data to enable the sonographer to analyze the images in various sections even after the patient leaves the examination room. In other words, only a single scan is required to provide sufficient data for in-depth analysis. Even better, the recent development of an automated 3D-ultrasonography further reduces the time and effort required to manually manipulate the volume data by automatically reconstructing images from the scanned volume data through a preloaded program on the apparatus.

Volume imaging through 3D-ultrasound is useful since the desired image may be reconstructed by manipulating volume data acquired by volume sweeping even if the correct plane is not found at the time of examination. Benacerraf et al. reported that volume data were acquired within 2 minutes and interpreted in 6–7 minutes using 3D-ultrasound in the standard fetal anatomic survey, indicating that the temporal efficiency of the 3D-ultrasonography was greater than that of 2D-ultrasonography, which took 19.6 minutes. They also reported that 3D-ultrasound may be useful in fetal anatomic surveillance because it allows for tomographic imaging study, like CT or MRI.⁵

Acquired 3D volume data can be displayed in three orthogonal planes and provide all the 2D planes for a complete anatomical evaluation of the particular organ. Therefore, 3D ultrasonography with multiplanar reconstruction or surface rendering has advantages in the evaluation of complex anatomy, such as fetal heart, central nervous system and face.⁶⁻¹⁰ For example, a single volume sweep provides reconstruction of a midsagittal plane for evaluation of nuchal

translucency and nasal bone.^{11,12} From 3D fetal echocardiography, standardized planes and intracardiac structures of the fetal heart can be reconstructed from volume data in real time. Spatiotemporal image correlation (STIC) enables an automated volume acquisition of the fetal heart by using a mechanical volume transducer and software. Real-time three-dimensional echocardiography is another kind of technology using a matrix array transducer which can display the fetal heart in real time. Furthermore, 3D ultrasound provides the ability to store volume data that can be manipulated after the patient has left the examination room and also be transmitted electronically to evaluate elsewhere.

Despite these advances of 3D ultrasound, the manipulation of volume data requires a learning curve and is also operator dependent. Automated 3D imaging will allow an operator independent and standardized approach to evaluate complex anatomical evaluation and improve the efficiency by reducing the time to complete the ultrasound examination.

Buoyed by the recent advancements in ultrasound technology, numerous studies have been conducted to develop a more efficient and precise automated ultrasound system for biometry. Zador et al. performed automated measurements of the biparietal diameter, occipitofrontal diameter, and head circumference using a personal computer-based system. The results showed that the automated measurements not only were highly correlated with the measurements taken by an experienced sonographer using conventional methods but also decreased the amount of time needed to make the measurements available for analysis.¹³ Thomas et al. conducted computerized measurements of the femur and humerus.¹⁴ Other studies have verified the feasibility of computerized automated fetal biometry measurement and its good intra-interobserver variability.^{15,16}

Ultrasound diagnosis based on automated computerized systems can be considered semi-automatic, since the operator searches for the correct plane and the computer performs the automated caliper placement through image

subtraction. Thus, the ultimate goal is to create a fully automated system, in which the correct plane is also determined by the instrument.

The present study is significant in that it verified the feasibility of automated long bone length measurements through 5D LB™ system. Our study focused on gestational ages of 26-32 weeks to assist less experienced operator in avoiding falsely including the triangular spur artifacts and the distal femoral epiphysis in the late trimester ; 20 weeks long bone measurement is quite straight forward as only the diaphysis is seen and to facilitate multiple long bone measurements. In a fetus with suspected skeletal dysplasia, measuring all of the long bones may be cumbersome and skeletal dysplasia (or long bone shortening) usually manifests in the late 2nd to 3rd trimester.

The volume sweep initiated by the automated long bone detection system only takes a few seconds to perform and the acquired volume data are available for offline manipulation. Such processes decrease the duration of the examination period, reduce the incidence of musculoskeletal stress-induced injuries common among sonographers,^{17,18} and construct a more precise image plane by being less affected by the movement or position of the fetus. In addition, the manual volume data manipulation required by 3D-ultrasonography was replaced by an automated system that enables the manipulation to be completed in just a few seconds. In our study, volume sweep takes 2 seconds with sweep angle of 30 degrees and software execution to measurement output takes 4 seconds.

Nonetheless, biometric measurement using 5D LB™ still requires improvement. In this study, the overall success rate of 5D LB™ measurements was 86.2% (538/624), the overall failure rate was 8.3% (52/624), and the overall error rate was 5.4% (34/624). Among the above measurements, the femur long-90 and femur long-45 exhibited a relatively high success rate of 91.0% (142/156) and 96.1% (150/156), respectively. However, the tibia and fibula length measurement exhibited lower success rates at 80.7% (126/156)

and 76.9% (120/156), respectively. Although it is estimated that the femur long-90 has highest success rate theoretically, the femur long-45 has slightly higher than long-90. Based on 4 cases that had failed, the thigh was abutting uterine wall without space filled with amniotic fluid between the wall and the thigh, thus the software was unable to differentiate bright bone outline and high echogenic skin line. However, when the femur was at 45 degrees-angle of inclination, there was amniotic fluid pocket thus less error for the software in selecting out bone outline.

Some of the reasons for 5D LB™ measurement failures include failure to locate the appropriate sagittal plane to construct an image of the long bone, misplacement of the caliper due to the unusually high soft tissue echo near the target long bone, unclear differentiation between the bone and soft tissue due to the low bone echo, image blurring due to fetal movements or maternal obesity, and acoustic shadowing due to the obstruction of nearby organs or the position of the two long bones. Such measurement errors have been reported since conventional 2D-ultrasound was first used. While volume data manipulation has made strides in rectifying some of the measurement errors, such measurement errors still occur in 3D-ultrasound examination.¹⁹ These errors need to be eliminated, perhaps by compensation using the 5D LB™ system algorithm.


Ultrasound is highly operator dependent thus the quality of ultrasound examination can vary accordingly. In hope to aid in standardization and reduce operator dependency, software that semi-automatically or automatically reproduce 2D image plane or measurement using 3D volume data was developed and has been promising.^{6,7,9-12} But limitation lies in that with current ultrasound machine that enables us to perform 2D and 3D ultrasound using two separate transducers, adding 3D software may not be practical but rather cumbersome and time-consuming since we need to switch back and forth between functions to apply the 3D software. Thus, automated femur measurement software by itself may not be attractive at present setting. However, ultrasound technology is innovating towards combining 2D and 3D

transducer functions²⁰⁻²² which will allow integration of multiple 3D software with real-time scanning in a most practical way. In such future perspective on where ultrasound technology is heading, 5D LB™ function should serve as one of gateway to automated biometry software.



V. CONCLUSION

The present study performed a comparative analysis of the feasibility of the 5D LB™ program with respect to its fetal long bone length measurement capacity. The capacity of the 5D LB™ program was compared with that of the conventional 2D- and 3D-ultrasound. Fetal lower limb long bone measurement using 5D LB™ demonstrated low intra–interobserver variability and a high level of agreement compared with data acquired using the conventional imaging techniques. As such, the 5D LB™ program exhibited high feasibility with respect to its capacity to perform fetal biometry. However, further improvements on the measurement failures and errors must be made for 5D LB™ to replace conventional 2D-ultrasound fetal biometry. Through this process, more efficient and precise ultrasound diagnosis will be possible.



REFERENCES

1. Schramm T, Gloning KP, Minderer S, Tutschek B. 3D ultrasound in fetal spina bifida. *Ultraschall Med* 2008;29 Suppl 5:289-90.
2. Bromley B, Shipp TD, Benacerraf B. Assessment of the third-trimester fetus using 3-dimensional volumes: a pilot study. *J Clin Ultrasound* 2007;35:231-7.
3. Krakow D, Williams J, 3rd, Poehl M, Rimoin DL, Platt LD. Use of three-dimensional ultrasound imaging in the diagnosis of prenatal-onset skeletal dysplasias. *Ultrasound Obstet Gynecol* 2003;21:467-72.
4. Verwoerd-Dikkeboom CM, Koning AH, Hop WC, Rousian M, Van Der Spek PJ, Exalto N, et al. Reliability of three-dimensional sonographic measurements in early pregnancy using virtual reality. *Ultrasound Obstet Gynecol* 2008;32:910-6.
5. Benacerraf BR, Shipp TD, Bromley B. Three-dimensional US of the fetus: volume imaging. *Radiology* 2006;238:988-96.
6. Tonni G, Grisolia G, Sepulveda W. Second trimester fetal neurosonography: reconstructing cerebral midline anatomy and anomalies using a novel three-dimensional ultrasound technique. *Prenat Diagn* 2014;34:75-83.
7. Liu X, Yu J, Wang Y, Chen P. Automatic localization of the fetal cerebellum on 3D ultrasound volumes. *Med Phys* 2013;40:112902.
8. Abuhamad A, Falkensammer P, Reichartseder F, Zhao Y. Automated retrieval of standard diagnostic fetal cardiac ultrasound planes in the second trimester of pregnancy: a prospective evaluation of software. *Ultrasound Obstet Gynecol* 2008;31:30-6.
9. Xiong Y, Liu T, Wu Y, Xu JF, Ting YH, Yeung Leung T, et al. Comparison of real-time three-dimensional echocardiography and

- spatiotemporal image correlation in assessment of fetal interventricular septum. *J Matern Fetal Neonatal Med* 2012;25:2333-8.
10. Acar P, Battle L, Dulac Y, Peyre M, Dubourdiou H, Hascoet S, et al. Real-time three-dimensional foetal echocardiography using a new transabdominal xMATRIX array transducer. *Arch Cardiovasc Dis* 2014;107:4-9.
 11. Cho HY, Kwon JY, Kim YH, Lee KH, Kim J, Kim SY, et al. Comparison of nuchal translucency measurements obtained using Volume NT(TM) and two- and three-dimensional ultrasound. *Ultrasound Obstet Gynecol* 2012;39:175-80.
 12. Lee MY, Won HS, Jeong BD, Hyun MK, Lee HY, Shim JY, et al. Measurement of intracranial translucency using three-dimensional ultrasound and Volume IT. *Prenat Diagn* 2012;32:472-5.
 13. Zador IE, Salari V, Chik L, Sokol RJ. Ultrasound measurement of the fetal head: computer versus operator. *Ultrasound Obstet Gynecol* 1991;1:208-11.
 14. Thomas JG, Jeanty P, Peters RA, 2nd, Parrish EA, Jr. Automatic measurements of fetal long bones. A feasibility study. *J Ultrasound Med* 1991;10:381-5.
 15. Rahmatullah B, Besar R. Analysis of semi-automated method for femur length measurement from foetal ultrasound. *J Med Eng Technol* 2009;33:417-25.
 16. Chalana V, Winter TC, 3rd, Cyr DR, Haynor DR, Kim Y. Automatic fetal head measurements from sonographic images. *Acad Radiol* 1996;3:628-35.
 17. Schoenfeld A, Goverman J, Weiss DM, Meizner I. Transducer user syndrome: an occupational hazard of the ultrasonographer. *Eur J Ultrasound* 1999;10:41-5.

18. Mercer RB, Marcella CP, Carney DK, McDonald RW. Occupational health hazards to the ultrasonographer and their possible prevention. *J Am Soc Echocardiogr* 1997;10:363-6.
19. Hull AD, Pretorius DH, Lev-Toaff A, Budorick NE, Salerno CC, Johnson MM, et al. Artifacts and the visualization of fetal distal extremities using three-dimensional ultrasound. *Ultrasound Obstet Gynecol* 2000;16:341-4.
20. Matrone G, Quaglia F, Magenes G. Simulating ultrasound fields for 2D phased-array probes design optimization. *Conf Proc IEEE Eng Med Biol Soc* 2011;2011:8507-10.
21. Wygant IO, Zhuang X, Yeh DT, Oralkan O, Sanli Ergun A, Karaman M, et al. Integration of 2D CMUT arrays with front-end electronics for volumetric ultrasound imaging. *IEEE Trans Ultrason Ferroelectr Freq Control* 2008;55:327-42.
22. Wygant IO, Jamal NS, Lee HJ, Nikoozadeh A, Oralkan O, Karaman M, et al. An integrated circuit with transmit beamforming flip-chip bonded to a 2-D CMUT array for 3-D ultrasound imaging. *IEEE Trans Ultrason Ferroelectr Freq Control* 2009;56:2145-56.

ABSTRACT(IN KOREAN)

5D Long Bone™을 이용한
태아장골의 3차원적 재구성 및 길이측정의 유용성

<지도교수 권자영>

연세대학교 대학원 의학과

허혜원

목적: 본 연구에서는 5D LB™을 이용한 태아 장골길이의 측정에 있어 부피스캔이 미치는 영향을 평가하고, 기존의 2차원, 3차원 초음파 장비로 측정된 장골길이와 5D LB™과의 비교를 시행하여 5D LB™을 이용한 장골 측정의 재현성을 검토하였다.

방법: 총 39명의 임신 26주에서 32주의 산모를 대상으로 태아 하지 장골을 측정하였다. 숙련된 시술자와 비숙련 시술자가 각각 2차원, 3차원 초음파와 5D LB™을 이용하여 대퇴골, 경골, 비골을 두 번씩 측정하였다. 먼저, 부피 스캔 각도의 영향을 살펴보기 위해 3차원 초음파와 5D LB™에서 두 가지 다른 각도로 부피 스캔한 길이를 분석하였다. 또한, 각각의 장비의 측정값의 검사자내, 검사자간 오차와 측정 장비 사이의 결과의 일치도와 오차를 대응표본 T검정, 블랜드-알트만 플롯과 급내 상관관계수 검정을 이용해 시행하였다. P값의 유의 수준은 0.05 미만으로 하였다.

결과: 두 가지 다른 각도에서 부피스캔을 시행한 결과에는 서로

유의한 차이가 없었다. 3가지 장비에서 시행한 측정값 모두 검사자내, 검사자간 오차가 유의하게 증가하지 않았고, 측정 장비간의 일치도를 비교했을 때, 2차원 초음파와 3차원 초음파, 2차원 초음파와 5D LB™의 측정값은 급내 상관 계수가 0.9 이상으로 일치도가 높은 것으로 나타났다.

결론 : 5D LB™은 기존의 2차원 및 3차원 초음파와 비교했을 때 5D LB™을 통한 태아 하지의 장골 측정은 검사자내, 검사자간 오차가 낮고, 기존의 영상 장비와 비교하였을 때에도 높은 측정 일치도를 보여 태아계측에 있어 높은 효용성을 보였다.



핵심되는 말: 태아 장골, 태아 계측, 2차원 초음파, 3차원 초음파, 5D Long Bone™