

---

**MAJOR PAPER**

---

## **Correlation between Hyperintense Vessels on FLAIR Imaging and Arterial Circulation Time on Cerebral Angiography**

Seung Ha LEE<sup>1</sup>, Kwon Duk SEO<sup>1</sup>, Ji Hwa KIM<sup>1</sup>, Sang Hyun SUH<sup>2,3</sup>,  
Sung Jun AHN<sup>2</sup>, and Kyung-Yul LEE<sup>1,3\*</sup>

<sup>1</sup>*Department of Neurology, Gangnam Severance Hospital, Yonsei University College of Medicine  
211 Eonjuro, Gangnam-gu, Seoul 135–720, Korea*

<sup>2</sup>*Department of Radiology, Gangnam Severance Hospital, Yonsei University College of Medicine*

<sup>3</sup>*Severance Institute for Vascular and Metabolic Research, Yonsei University*

(Received January 23, 2015; Accepted June 10, 2015; published online September 4, 2015)

**Purpose:** Hyperintense vessels (HVs) on fluid-attenuated inversion recovery (FLAIR) imaging are associated with the leptomeningeal collateral circulation in cases of arterial occlusive lesions. Nevertheless, the relationship between HVs on FLAIR imaging and arterial circulation time (ACT) on cerebral angiography has not been defined.

**Methods:** We analyzed images of 11 patients with acute occlusion of the distal internal carotid artery or proximal middle cerebral artery and calculated the difference in ACT (DACT) between infarcted and normal hemispheres. ACT was defined as the time interval from the initial opacification of the ipsilateral or contralateral cavernous internal carotid artery to the late arterial phase of the carotid artery territories. We scored HVs on FLAIR imaging using a modified Alberta Stroke Program Early Computerized Tomography Score (ASPECTS) and determined collateral circulation by grading collateral flow.

**Results:** We detected HVs on FLAIR images in 10 patients (median score, 4; range, 0 to 6). Comparison of infarcted and normal hemispheres demonstrated absent or subtle HVs on FLAIR imaging when the DACT was too short (<one second) or too long (>7.98 s) and prominent HVs with moderate DACT (2 to 5 s). The score of HVs on FLAIR was estimated well by DACT using a quadratic regression model ( $R^2 = 0.602$ ) and better than by grading collateral flow ( $R^2 = 0.256$ ).

**Conclusion:** In cases of large arterial occlusion, the hyperintensity of vessels on FLAIR images may be dependent on arterial circulation time via retrograde filling of the leptomeningeal collateral circulation.

**Keywords:** *arterial circulation time, collateral circulation, hyperintense vessel, magnetic resonance image*

### **Introduction**

Hyperintense vessels (HVs) on fluid-attenuated inversion recovery (FLAIR) magnetic resonance (MR) imaging are frequently observed in patients with acute cerebral infarction with large arterial stenosis or occlusion.<sup>1–6</sup> They are associated with good arterial collateral circulation and small infarction volume.<sup>1,3,5,7</sup> Their absence on FLAIR images in normal healthy people or in patients with lacunar

infarction has suggested that slow blood flow is a possible mechanism of HVs.<sup>1,2,7</sup> However, the relationship between hyperintense vessels on FLAIR imaging and arterial circulation time (ACT) has not been defined with regard to the velocity of arterial flow.<sup>1–6</sup>

HVs on FLAIR images are signs of major arterial occlusion, and FLAIR images play an important role in determining whether a patient should undergo perfusion study because the vessels can help predict areas at risk for infarction and collateral circulation.<sup>1,5,7</sup> A few reports have associated HVs on FLAIR images with poor prognosis, whereas others

---

\*Corresponding author, Phone: +82-2-2019-3325, Fax: +82-2-3462-5904, E-mail: kylee@yuhs.ac

propose the vessels hold no specific prognostic meaning other than information regarding arterial occlusion.<sup>6,8</sup> Nevertheless, HVs on FLAIR images have been associated with smaller infarct volumes and good clinical outcomes in acute stroke.<sup>1,9</sup>

Though the mechanism underlying the hyperintense vessels on FLAIR imaging remains to be established, possible explanations suggested for their appearance include stationary blood and slow antegrade or retrograde filling of the leptomeningeal collateral circulation.<sup>1,2,5,10</sup> Verification of the clinical implications of these vessels requires comparison of similar groups of patients with HVs on FLAIR imaging, such as those with similar sites of arterial occlusion.<sup>1</sup> Accordingly, we sought to characterize these hyperintense vessels by comparing them with findings on digital subtraction angiography (DSA) performed within 3 hours of MR imaging in acute ischemic stroke.<sup>7</sup> Moreover, we set out to analyze the relationships between the appearance of HVs on FLAIR imaging and differences in ACT (DACT) on cerebral angiography in cases of acute occlusion of the internal carotid artery (ICA) or proximal middle cerebral artery (MCA).

## Materials and Methods

We retrospectively reviewed consecutive patients with acute ischemic stroke between July 1, 2012 and July 31, 2013. Our institutional review board approved this study.

Patients were selected who underwent MR imaging within 3 days of symptom onset and DSA within 3 hours of the MR imaging that showed distal ICA or proximal MCA occlusion. Two 3.0-tesla MR imaging scanners (Discovery MR750, GE Medical Systems, Milwaukee, WI, USA; Achieva, Philips Medical Systems, Nederland) were used to obtain MR images.

FLAIR parameters for the Discovery MR750 scanner were: repetition time (TR)/echo time (TE), 12000/144 ms; inversion time (TI), 2518 ms; field of vision (FOV), 21 × 21 cm; matrix size, 352 × 224; slice thickness, 4 mm; and inter-slice gap, one mm.

Parameters for the Achieva scanner were: TR/TE, 11000/125 ms; TI, 2800 ms; FOV, 22 × 22 cm; matrix size, 340 × 299; slice thickness, 4 mm; and interslice gap, one mm.

Hyperintense vessels on FLAIR imaging were defined as linear or serpentine-appearing hyperintensity relative to gray matter in the subarachnoid space that corresponded with a typical arterial course.<sup>1</sup>

DSA was acquired using a biplane C-arm digital angiography suite (Artis Zee; Siemens, Erlangen,

Germany). All angiographic studies included images of the arterial, capillary, and venous phases (4 frames/s). ACT was calculated according to the modified method described by Yamamoto and associates.<sup>11</sup> ACT was defined as the time interval from the initial opacification of the ipsilateral or contralateral carotid siphon to the late arterial phase of the carotid artery territory on DSA, whereas DACT was defined as the difference in ACT between the occlusive and normal hemispheres.

Two neuroradiologists with 10 years of experience who were blinded to clinical information reviewed FLAIR images to score HVs and DSA images to grade collateral flow in consensus. They counted the number of territories with HVs on FLAIR images, and scores ranged from zero to 7 points. The Alberta Stroke Program Early Computerized Tomography Score (ASPECTS) is commonly used to assess CT scans of patients with acute stroke,<sup>12</sup> but we modified its territorial definitions for patients with acute stroke on FLAIR MR imaging.

We defined the insula and M1 to M3 as the level of the basal ganglia and the M4 to M6 as the level of the ventricles immediately above the basal ganglia. M1, defined as the anterior MCA cortex, corresponded with the frontal operculum; M2, defined as the MCA cortex lateral to the insular ribbon, corresponded with the anterior temporal lobe; and M3, representing the posterior MCA cortex, corresponded with the posterior temporal lobe. M4, M5, and M6 represented the anterior, lateral, and posterior MCA territories immediately superior to M1 (M4), M2 (M5), and M3 (M6).<sup>12</sup>

On DSA images, we used the grading system of the American Society of Intervention and Therapeutic Neuroradiology/Society of Interventional Radiology (ASITN/SIR) to assess collateral flow,<sup>13</sup> with Grade 0 corresponding with no collaterals visible to the ischemic site; Grade 1, with slow collateral flow to the periphery of the ischemic site, with persistence of some of the defect; Grade 2, with rapid collateral flow to the periphery of the ischemic site, with persistence of some of the defect, and to only a portion of the ischemic territory; Grade 3, with collaterals with slow but complete angiographic blood flow to the ischemic bed during the late venous phase; and Grade 4, with complete and rapid collateral blood flow to the vascular bed throughout the entire ischemic territory by retrograde perfusion. Slow collateral flow is defined, arbitrarily, as filling that is more than 2 s longer than that in the contralateral side; rapid collateral flow is defined as filling that is within 2 s of that in the contralateral side.<sup>13</sup>

**Table.** Demographic characteristics and image findings

| Case | Age (years) | Sex | Initial NIHSS | Occlusion site   | Symptom onset to MR imaging (min) | MR imaging to angiography (min) | DACT (s) | Grade of collateral flow | Score of HVs on FLAIR imaging |
|------|-------------|-----|---------------|------------------|-----------------------------------|---------------------------------|----------|--------------------------|-------------------------------|
| 1    | 57          | M   | 5             | Rt. proximal MCA | 271                               | 161                             | 0.53     | 4                        | 0                             |
| 2    | 66          | M   | 13            | Rt. distal ICA   | 162                               | 42                              | 1.59     | 4                        | 5                             |
| 3    | 79          | M   | 23            | Rt. distal ICA   | 184                               | 107                             | 2        | 4                        | 5                             |
| 4    | 68          | F   | 8             | Rt. proximal MCA | 276                               | 10                              | 2.66     | 3                        | 5                             |
| 5    | 49          | F   | 9             | Rt. proximal MCA | 124                               | 56                              | 3.19     | 3                        | 5                             |
| 6    | 52          | M   | 10            | Rt. proximal MCA | 67                                | 52                              | 4.26     | 3                        | 6                             |
| 7    | 72          | M   | 23            | Rt. proximal MCA | 112                               | 71                              | 5.26     | 3                        | 4                             |
| 8    | 76          | F   | 25            | Rt. distal ICA   | 89                                | 24                              | 5.32     | 3                        | 4                             |
| 9    | 42          | M   | 15            | Lt. proximal MCA | 98                                | 37                              | 5.32     | 1                        | 4                             |
| 10   | 64          | M   | 19            | Lt. distal ICA   | 245                               | 56                              | >7.98    | 0                        | 3                             |
| 11   | 60          | M   | 16            | Rt. distal ICA   | 156                               | 21                              | >8.25    | 1                        | 2                             |

DACT, difference in arterial circulation time; FLAIR, fluid-attenuated inversion recovery imaging sequence; HV, hyperintense vessel; ICA, internal carotid artery; Lt., left; MCA, middle cerebral artery; MR, magnetic resonance; NIHSS, National Institutes of Health Stroke Scale; Rt., right

Statistical analysis was performed with SPSS® Statistics software for Windows (Version 20, IBM Corporation, Armonk, NY, USA). We applied a quadratic regression model to estimate non-linear correlation in addition to Pearson's correlation coefficient to assess linear correlation between scores of HVs on FLAIR imaging and DACT or collateral flow grade. A 2-tailed value of  $P < 0.05$  was considered statistically significant.

## Results

Among 327 patients admitted with acute ischemic stroke, we evaluated images of 11 patients. Six patients showed proximal MCA occlusion, and five had distal ICA occlusion. The mean time interval from symptom onset and MR imaging was  $162 \pm 73.9$  min and from MR imaging to angiography,  $57.9 \pm 43.3$  min (Table).

There was no correlation between score of HVs on FLAIR imaging and initial National Institutes of Health Stroke Scale score, the time between MR imaging and angiography, and age.

Ten of the 11 patients demonstrated HVs on FLAIR imaging. Analyzing the ten, we noted a significant correlation between the score of the HVs and DACT between the normal and occlusive hemispheres ( $r = -0.842$ ,  $P = 0.002$ ). We also discovered a significant correlation between the HV score and grade of collateral flow ( $r = 0.743$ ,  $P = 0.014$ ). However, if we analyzed all 11 patients including the one case without HVs on FLAIR imag-

ing (Case 1), we noted no significant correlation between either the HV score and DACT ( $r = -0.104$ ,  $P = 0.761$ ) or between the HV score and grade of collateral flow ( $r = 0.161$ ,  $P = 0.639$ ).

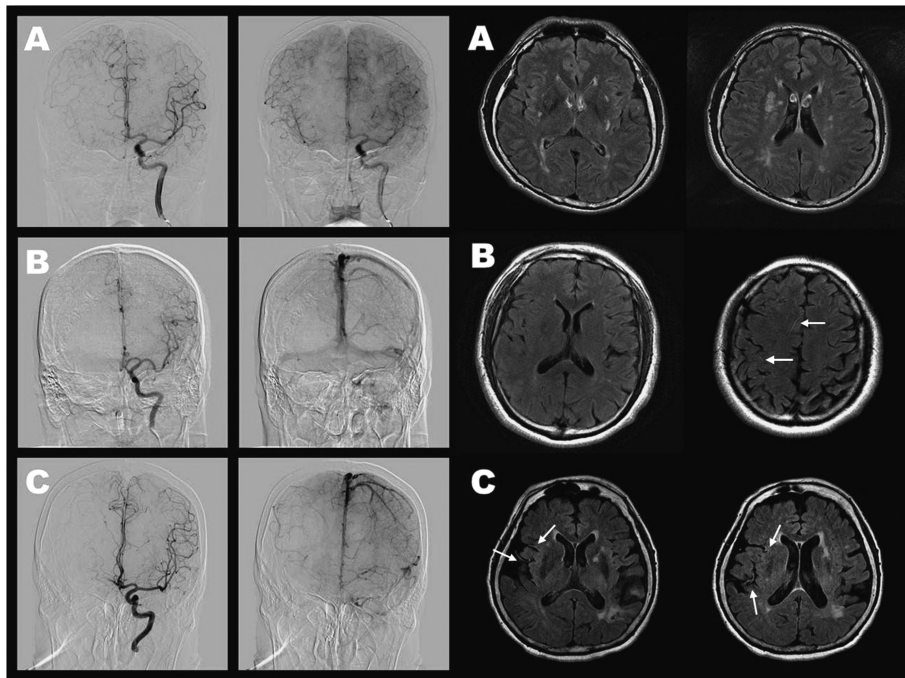
We then observed the relationship between HVs on FLAIR imaging and DACT in individual cases (Table). When ACT of the lesion side was similar to that for the normal side, as in Case 1 (DACT, 0.53 s), no HVs were observed on FLAIR images, and they were rarely detected when ACT of the lesion side was much longer than that of the normal side, as in Cases 10 and 11 (DACT  $\geq 7.98$  s). However, when DACT was moderate, HVs were easily detected and prominent, as seen in Cases 3 to 9 (Fig. 1). If DACT was plotted against the HV score on FLAIR imaging, a convex-like relationship could be expected (Fig. 2). We applied a quadratic function to estimate the correlation between these 2 parameters and arrived at the following formula to describe the relationship:

$$\begin{aligned} \text{FLAIR HV score} \\ = 0.9619 + 1.9305 \times (\text{DACT}) \\ - 0.2210 \times (\text{DACT})^2 \quad (R^2 = 0.602). \end{aligned}$$

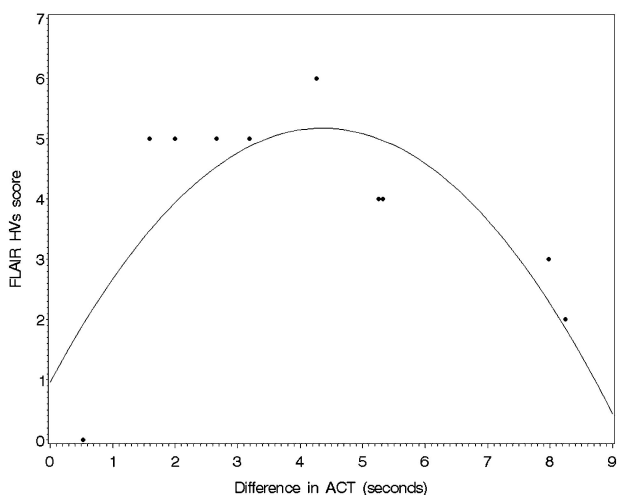
When we applied the quadratic function to estimate the correlation between the grade of collateral flow and score of HVs on FLAIR images, the estimation was poor ( $R^2 = 0.256$ ).

## Discussion

This study showed that HVs on FLAIR imaging



**Fig. 1.** Digital subtraction angiography (DSA) and hyperintense vessels (HVs) on fluid-attenuated inversion recovery (FLAIR) images. (A) DSA shows good retrograde filling of the leptomenigeal collateral circulation in the right hemisphere. HVs on FLAIR images are not detected in Case 1. (B) DSA shows poor retrograde filling of the leptomenigeal collateral circulation in the right hemisphere; the middle cerebral artery is not visualized in the right hemisphere until the last frame. Subtle HVs on FLAIR images (arrows) are observed in the right anterior cerebral artery territory and right parietal region in Case 11. (C) DSA shows moderate retrograde filling of the leptomenigeal collateral circulation in the right hemisphere. Prominent HVs on FLAIR images (arrows) are observed in the right middle cerebral artery territory in Case 8.



**Fig. 2.** Correlation between differences of arterial circulation time (DACT) and scores of hyperintense vessels (HVs) on fluid-attenuated inversion recovery (FLAIR) imaging HVs. The correlation is well estimated using quadratic regression mode (parabolic line).

correlate with the time of retrograde filling of the leptomenigeal collateral circulation in arterial occlusive lesions. Many studies have reported that these HVs represent slow collateral blood flow rather than thrombus in cases of cerebral arterial occlusive disease.<sup>1,2,7,14</sup> The pial collaterals assessed by cerebral angiography have been reported to have prognostic significance and are associated with smaller infarct volumes and good clinical outcomes in acute ischemic stroke.<sup>9</sup> Collateral flow can prolong tissue viability and maximize the volume of salvageable tissue, so information about collateral blood flow has potential in clinical applications and prognosis.<sup>1</sup> Collateral blood flow can be evaluated by several methods, such as cerebral angiography, quantitative MR angiography, and transcranial Doppler sonography.<sup>9,15–18</sup> Nevertheless, studies have yet to compare HVs on FLAIR images in relation to the velocity of arterial flow. One transcranial Doppler study showed the association of these HVs with reduced average flow velocity in comparison with that in the contralateral MCA,<sup>2</sup> but the reduced blood flow velocity in the

MCA in that study only suggested that there was an occlusive lesion in the MCA and did not indicate leptomeningeal collateral circulation.

In this pilot study, we speculated that differences in arterial circulation time on DSA represents arterial flow velocity via retrograde filling of the leptomeningeal collateral circulation, and we found that the degree of vascular hyperintensity on FLAIR imaging is dependent on the DACT between normal and occluded hemispheres. When DACT was too short or too long, HVs were rarely observed on FLAIR images, but when DACT was moderate, meaning collateral flow was slow, HVs were prominent. HVs on FLAIR images would gradually become prominent with prolongation of the DACT up to 4 to 5 s and then begin to diminish; in other words, the correlation between the score of HVs on FLAIR imaging and DACT would be a quadratic rather than linear form as an estimated curve in Fig. 2. Technically, in the setting of normal hemodynamics, the blood vessels show dark signal intensity on spin echo sequences, such as FLAIR, because of the dephasing effect from mixed spin echoes and stimulated echoes, as well as because of disrupted spin echo mechanism due to through-plane blood motion. The retrograde slow flow results in the loss of flow void phenomenon, and vessels appear hyperintense against the background of dark cerebrospinal fluid.<sup>19,20</sup> Nevertheless, although we discovered a correlation between HVs on FLAIR imaging and DACT, we could not define the exact time range for moderate DACT. Because DACT is influenced by the velocity of arterial flow, a quantitative MR imaging study in a phantom using different flow velocities would help define the exact range of flow velocities that cause HVs on FLAIR imaging.

The relationship between the grade of collateral flow grade and score of HVs on FLAIR images ( $R^2 = 0.256$ ) was poorer than relationship between DACT and score of HVs on FLAIR images ( $R^2 = 0.602$ ). The score of HVs on FLAIR imaging is either zero (Case 1) or five (Case 2, 3) in the case of collateral flow Grade 4 (as shown in Table). It may be that the grade of collateral flow could not distinguish excellent (Case 1: DACT < one second) from good (Cases 2, 3) collateral flow.

Our pilot study had several limitations. Because we wanted to analyze relatively homogenous patients with only proximal MCA or distal ICA occlusion as well as corresponding MR and DSA images, we included only a small number of patients. We included only one case with excellent collateral (DACT < one second) blood flow. A study with a larger number of patients including patients with

excellent collateral flow is needed to verify our findings. As our results show, if we did not include Case 1, with no HVs on FLAIR imaging, the score of HVs would have a significant linear correlation with both DACT and the grade of collateral flow. Additionally, FLAIR sequence parameters differed between the 2 different MR imaging scanners used in this study. Although the difference in parameters may be trivial, this might have changed the appearance of HVs.<sup>21</sup>

## Conclusion

Hypervascular vessels on fluid-attenuated inversion recovery imaging are frequently observed in acute ischemic stroke with large arterial occlusion, but they do not appear to the same degree in patients with proximal MCA or ICA occlusion. Our quantitative evaluation of arterial circulation time in patients with large arterial occlusion revealed a relationship between DACT and the appearance of HVs on FLAIR imaging. Further study is needed to elucidate the clinical significance of these hypervascular vessels.

## Acknowledgements

The authors would like to thank Anthony Thomas Milliken (Editing Synthase, Seoul, Korea) for his help with the editing of this manuscript.

## References

1. Lee KY, Latour LL, Luby M, Hsia AW, Merino JG, Warach S. Distal hyperintense vessels on FLAIR: an MRI marker for collateral circulation in acute stroke? *Neurology* 2009; 72:1134–1139.
2. Kamran S, Bates V, Bakshi R, Wright P, Kinkel W, Miletich R. Significance of hyperintense vessels on FLAIR MRI in acute stroke. *Neurology* 2000; 55: 265–269.
3. Seo KD, Lee KO, Choi YC, Kim WJ, Lee KY. Fluid-attenuated inversion recovery hyperintense vessels in posterior cerebral artery infarction. *Cerebrovasc Dis Extra* 2013; 3:46–54.
4. Cheng B, Ebinger M, Kufner A, et al. Hyperintense vessels on acute stroke fluid-attenuated inversion recovery imaging: associations with clinical and other MRI findings. *Stroke* 2012; 43:2957–2961.
5. Toyoda K, Ida M, Fukuda K. Fluid-attenuated inversion recovery intraarterial signal: an early sign of hyperacute cerebral ischemia. *AJNR Am J Neuroradiol* 2001; 22:1021–1029.
6. Schellinger PD, Chalela JA, Kang DW, Latour LL, Warach S. Diagnostic and prognostic value of early MR Imaging vessel signs in hyperacute stroke pa-

- tients imaged <3 hours and treated with recombinant tissue plasminogen activator. *AJNR Am J Neuroradiol* 2005; 26:618–624.
7. Sanossian N, Saver JL, Alger JR, et al. Angiography reveals that fluid-attenuated inversion recovery vascular hyperintensities are due to slow flow, not thrombus. *AJNR Am J Neuroradiol* 2009; 30:564–568.
  8. Girot M, Gauvrit JY, Cordonnier C, et al. Prognostic value of hyperintense vessel signals on fluid-attenuated inversion recovery sequences in acute cerebral ischemia. *Eur Neurol* 2007; 57:75–79.
  9. Christoforidis GA, Mohammad Y, Kehagias D, Avutu B, Slivka AP. Angiographic assessment of pial collaterals as a prognostic indicator following intra-arterial thrombolysis for acute ischemic stroke. *AJNR Am J Neuroradiol* 2005; 26:1789–1797.
  10. Noguchi K, Ogawa T, Inugami A, et al. MRI of acute cerebral infarction: a comparison of FLAIR and T<sub>2</sub>-weighted fast spin-echo imaging. *Neuroradiology* 1997; 39:406–410.
  11. Yamamoto S, Watanabe M, Uematsu T, Takasawa K, Nukata M, Kinoshita N. Correlation of angiographic circulation time and cerebrovascular reserve by acetazolamide-challenged single photon emission CT. *AJNR Am J Neuroradiol* 2004; 25:242–247.
  12. Pexman JH, Barber PA, Hill MD, et al. Use of the Alberta Stroke Program Early CT Score (ASPECTS) for assessing CT scans in patients with acute stroke. *AJNR Am J Neuroradiol* 2001; 22:1534–1542.
  13. Higashida RT, Furlan AJ, Roberts H, et al. Trial design and reporting standards for intra-arterial cerebral thrombolysis for acute ischemic stroke. *Stroke* 2003; 34:e109–e137.
  14. Lee JY, Lee KY, Suh SH. Different meaning of vessel signs in acute cerebral infarction. *Neurology* 2010; 75:668.
  15. Ruland S, Ahmed A, Thomas K, et al. Leptomeningeal collateral volume flow assessed by quantitative magnetic resonance angiography in large-vessel cerebrovascular disease. *J Neuroimaging* 2009; 19:27–30.
  16. Kim Y, Sin DS, Park HY, Park MS, Cho KH. Relationship between flow diversion on transcranial Doppler sonography and leptomeningeal collateral circulation in patients with middle cerebral artery occlusive disorder. *J Neuroimaging* 2009; 19:23–26.
  17. Alexandrov AV, Babikian VL, Adams RJ, et al. The evolving role of transcranial Doppler in stroke prevention and treatment. *J Stroke Cerebrovasc Dis* 1998; 7:101–104.
  18. Liebeskind DS, Cotsonis GA, Saver JL, et al. Warfarin-Aspirin Symptomatic Intracranial Disease (WASID) Investigators. Collaterals dramatically alter stroke risk in intracranial atherosclerosis. *Ann Neurol* 2011; 69:963–974.
  19. Tsushima Y, Endo K. Significance of hyperintense vessels on FLAIR MRI in acute stroke. *Neurology* 2001; 56:1248–1249.
  20. Storey P, Atanasova IP, Lim RP, et al. Tailoring the flow sensitivity of fast spin-echo sequences for non-contrast peripheral MR angiography. *Magn Reson Med* 2010; 64:1098–1108.
  21. Kwag E, Lim SM, Park JE, Chae IH. Arterial hyperintensity on BLADE fluid-attenuated inversion recovery images (FLAIR) in hyperacute territorial infarction: comparison with conventional FLAIR. *Eur Radiol* 2014; 24:2045–2051.
-