

Perception of 3-Dimensional Dynamic Images after Successful Surgery for Exotropia

Young Joo Cho

Department of Medicine

The Graduate School, Yonsei University

Perception of 3-Dimensional Dynamic Images after Successful Surgery for Exotropia

Directed by Professor Sueng-Han Han

The Master's Thesis
submitted to the Department of Medicine
the Graduate School of Yonsei University
in partial fulfillment of the requirements for the degree
of Master of Medical Science

Young Joo Cho

December 2014

This certifies that the Master's Thesis of
Young Joo Cho is approved.



Thesis Supervisor : Sueng-Han Han



Thesis Committee Member#1 : Hyung Keun Lee



Thesis Committee Member#2 : Jae-Jin Kim

The Graduate School
Yonsei University

December 2014

ACKNOWLEDGEMENTS

First of all, I would like to express my deep and sincere gratitude to my mentor, Professor Sueng-Han Han, M.D., who gave me specific guidelines for my academic research and has always been supportive academically.

I am deeply indebted to Jinu Han, M.D. and So Young Han, M.D., whose stimulating suggestions and encouragement helped my academic research.

I wish to express my warm and sincere thanks to Professor Hyung Keun Lee, M.D., M.D. and Professor Jae-Jin Kim, M.D. for valuable advice and encouragement throughout my years at the graduate school.

I would like to thank my resident colleagues especially Yong Woo Ji M.D., and Eun Young Choi, M.D. for their help and encouragements. I thank my most loving family who was a strong advocate throughout my life.

<TABLE OF CONTENTS>

ABSTRACT	1
I. INTRODUCTION	3
II. MATERIALS AND METHODS	4
1. Subjects	4
2. 3-Dimensional dynamic stereotest	5
3. Statistical analysis	6
III. RESULTS	7
1. Stereoacuity in control group	7
2. Stereoacuity in IXT group	8
3. Correlations between 3-D motion perception and Titmus stereoacuity	9
IV. DISCUSSION	10
V. CONCLUSION	11
REFERENCES	12
ABSTRACT(IN KOREAN)	14

LIST OF FIGURES

Figure 1. Measurement of 3-D motion perception	6
Figure 2. Correlations between threshold of 3-D depth level and Titmus stereotest in IXT group	9

LIST OF TABLES

Table 1. Baseline characteristics	7
Table 2. Changes of 3-D motion perception and Titmus stereoacuity after IXT surgery	8

ABSTRACT

Perception of 3-Dimensional Dynamic Images after Successful Surgery for Exotropia

Young Joo Cho

*Department of Medicine
The Graduate School, Yonsei University*

(Directed by Professor Sueng-Han Han)

Purpose: To evaluate the perception of 3-dimensional (3-D) dynamic imaging in patients with intermittent exotropia (IXT) after surgery.

Methods: Fifty-one subjects, including 26 patients who planned surgery for IXT and 25 age-matched controls, were enrolled. The 3-D dynamic images were divided in 10 units from 0 (0-mm image disparity, 2-D image) to 100 (15-mm image disparity).

Results: In the control group, the mean 3-D motion perception was 48.43 ± 18.45 arcsec, and the mean stereoacuity in the Titmus stereotest was 60.38 ± 37.25 arcsec. There was positive correlation between the mean 3-D motion perception (Log arcsec) and Titmus stereoacuity (Log arcsec) (Correlation=0.421, $p=0.026$). In the IXT group, the mean preoperative distance deviation was prism diopters (PD) at distance and 26.04 ± 8.09 PD at near range; these measurements improved to 1.36 ± 3.56 PD at distance and 0.28 ± 0.68 PD at near range after surgery. The mean 3-D motion perception was 61.26 ± 25.97 arcsec preoperatively, which improved to 49.01 ± 20.44 arcsec three months after surgery ($p=0.024$). The mean stereoacuity in the Titmus stereotest was 90.40 ± 77.75 arcsec preoperatively, which improved to 63.20 ± 29.40 arcsec three months after surgery ($p=0.030$). The mean 3-D motion perception and mean

stereoacuity in the Titmus stereotest showed statistically significant positive correlations preoperatively (Correlation=0.709, $p<0.001$) and postoperatively (Correlation=0.466, $p=0.038$).

Conclusions: 3-D motion perception and Titmus stereoacuity improved after successful IXT surgery. Thus, 3-D dynamic stereotesting may be a useful measurement for successful IXT surgery due to correlations with real-life 3-D images.

Key words : stereoacuity, 3-dimensional dynamic Image, exotropia

Perception of 3-Dimensional Dynamic Images after Successful Surgery for Exotropia

Young Joo Cho

*Department of Medicine
The Graduate School, Yonsei University*

(Directed by Professor Sueng-Han Han)

I. INTRODUCTION

In intermittent exotropia (IXT), stereoacuity is important for optimal timing of surgery. Although some authors suggest that stereoacuity is preserved without intervention¹, many authors propose that early surgery for IXT could preserve stereoacuity²⁻⁴. Indeed, improved stereoacuity has been reported following surgery for IXT.^{5,6} However, the benefits of stereoacuity, including actual 3-Dimensional (3-D) motion perception after surgery for IXT, remain unknown.

The most common way that children experience stereoacuity is by watching 3-D movies. However, conventional stereoacuity tests using vectographic or anaglyphic methods include only stationary, interwoven images, which differ from actual 3-D images. More dynamic images with large disparities are used in movies; additional information, such as motion parallax, is also present. Therefore, we investigated whether the perception of 3-D dynamic images with 3-D dynamic stereotests and Titmus stereotests improved following surgery for IXT.

II. MATERIALS AND METHODS

Subjects

This prospective study enrolled 51 subjects who were older than five years and visited the Squint Service Clinic of Yonsei University Medical Center between February 2012 and December 2013. The inclusion criteria for the IXT group were: (1) diagnosis of IXT of the basic or divergence excess type and (2) the ability to perform stereoacuity tests. Other exclusion criteria included convergence insufficiency type of exotropia, presence of amblyopia, more than 2 prism diopters of vertical deviation, history of previous squint surgery, high refractive error (more than 5 D spherical or 2.5 D cylinder), and any other ocular pathology that may reduce vision and stereoacuity. Subjects in the control group were age-matched and included those who did not squint or have any confounding ocular illnesses that may affect vision and stereoacuity. This study was approved by the Institutional Review Board of Yonsei University College of Medicine and was conducted in accordance with the tenets of the Declaration of Helsinki. Informed consent was obtained from patients or parents. We certify that all applicable institutional and governmental regulations concerning the ethical use of human volunteers were followed during this research.

All patients with IXT received bilateral lateral rectus recession. The cover/uncover test and alternate prism cover test at 1/3 m and 6 m were conducted on all patients; patients wore their glasses when necessary. A comprehensive ophthalmic evaluation, including best-corrected visual acuity, the near Titmus stereotest at 1/3m (Stereo Optical Inc., Chicago, IL, USA), and the near 3-D dynamic stereotest using Tridef software (DDD Inc., Los Angeles, CA, USA), was also performed on all subjects. The illuminance of the room was 5 lx. Each test was performed preoperatively and postoperatively at three months follow-up with the full cooperation of patients.

3-Dimensional dynamic stereotest

A 3-D dynamic stereotest was performed using the polarized glasses 3-D system, which is the most popular modality for 3-D vision. We investigated the threshold of 3-D depth at which the patient felt different from 2-dimensional (2-D) vision by changing the image disparity of 3-D vision using the polarized 3-D system. A 15-inch 3-D liquid crystal display (LCD) laptop (LG A530, Seoul, Korea) was prepared. At a distance of one meter, each subject watched the 3-D animation “Ice Age 2” with Tridef® software for two minutes. Tridef software created 3-D images on polarized film, which coated the LCD. The 3-D image was divided in to 10 units from 0 (0-mm image disparity, 2-D image) to 100 (15-mm image disparity). The examiner asked the patient with polarized glasses whether two images looked different, comparing the 2-D image and 3-D images divided in 10 units (Figure 1). The minimum 3-D parameter at which the patient saw differences from the 2-D image was recorded. In conclusion, the 3-D depth level was expressed in arcsec and the depth of focus was controlled from 0 to 100.

To determine the feasibility of the 3-D dynamic stereotests, the study was conducted first in the control group with conventional Titmus stereotesting. Correlations between the results of the 3-D dynamic stereotest and those of the Titmus stereotest were confirmed; 3-D dynamic stereoacuity was then compared in the IXT group before and after surgery.




Figure 1. In measurement of 3-D motion perception, the subjects were asked to choose when difference was noted between two images, and the minimal value at which the change was noted was defined as the threshold of 3-D depth level.

Statistical analysis

For analysis, 3-D dynamic stereoacuity values were transformed to log arcsec. Intergroup comparisons were performed with appropriate non-parametric tests (Mann–Whitney U and Wilcoxon rank sum tests). Stereoacuity values were compared to those of preoperative data by the Wilcoxon signed rank test. Spearman’s correlation was used to evaluate associations between parameters. Statistical analyses were performed with SPSS (Ver. 18.0, Statistical Package for the Social Sciences; SPSS, Inc, Chicago, IL). Statistical significance was approved for $p < 0.05$.

III. RESULTS

Stereoacuity in control group

Fifty-one subjects, including 26 patients who planned surgery for IXT and 25 age-matched controls, were enrolled. The mean age of each group was 8.60 ± 3.27 (range 6–19) and 9.31 ± 2.21 (range 6–15), respectively ($p=0.367$). Both groups had a male preponderance, including 17 male subjects in the IXT group and 18 male subjects in the control group ($p=1.000$). Refractive errors were measured by cycloplegic refraction with no significant difference; OD spherical equivalents were -1.26 ± 1.70 in the IXT group and -1.51 ± 1.78 in the control group ($p=0.605$). OS spherical equivalents were -1.10 ± 1.75 in the IXT group and -1.47 ± 1.65 in the control group ($p=0.428$). Best-corrected vision was logMAR 0 (20/20) in both eyes for all subjects.

In the control group, the mean threshold for the 3-D depth level was 28.46 ± 10.84 (range 20–60); the 3-D motion perception was 48.43 ± 18.45 arcsec (range 53.18–159.53), and the mean stereoacuity in the Titmus stereotest was 60.38 ± 37.25 arcsec (range 40–200). There was a positive correlation between the threshold of 3-D depth (Log arcsec) and Titmus stereoacuity (Log arcsec) in the control group (Correlation=0.421, $p=0.026$).

Table 1. Baseline characteristics

Characteristics	X(T)	Control	<i>p</i> value
Number of subjects	25	26	
Male : Female	17:8	18:8	1.000
Age (years)	8.60 ± 3.27 (6-19)	9.31 ± 2.21 (6-15)	0.367
Spherical equivalent (D)			
OD	-1.26 ± 1.70	-1.51 ± 1.78	0.605
OS	-1.10 ± 1.75	-1.47 ± 1.65	0.428

Mean \pm Standard deviation (range), X(T)=intermittent exotropia; SD=standard deviation; BCVA=best corrected visual acuity; M=months; D=dioptr

Stereoacuity in IXT group

In the IXT group, the preoperative and postoperative ocular deviation and stereoacuity parameters are depicted in Table 1. The mean preoperative deviation was 28.04 ± 9.93 (range 18–55) prism diopters (PD) at distance and 26.04 ± 8.09 (range 18–45) PD at near range. There were significant improvements in the distance and near deviations after surgery (all $p < 0.001$); the mean postoperative distance deviations at three months were 1.36 ± 3.56 (range 0–10) PD at distance and 0.28 ± 0.68 (range 0–3) PD at near range.

The mean threshold of the 3-D depth level was 36.00 ± 15.26 (range 20–80), and 3-D motion perception was 61.26 ± 25.97 arcsec (range 53.18–212.71) preoperatively. The mean threshold of 3-D depth level improved to 28.80 ± 12.01 (range 20–60), and the 3-D motion perception was 49.01 ± 20.44 arcsec (range 53.18–159.53) three months after surgery ($p = 0.024$). The mean stereoacuity in the Titmus stereotest was 90.40 ± 77.75 arcsec (range 40–400) preoperatively, which improved to 63.20 ± 29.40 arcsec (range 40–140) three months after surgery ($p = 0.030$). The differences were significant in both 3-D motion perception and Titmus stereotest (Table 2).

Table 2. Changes of 3-D motion perception and Titmus stereoacuity after IXT surgery

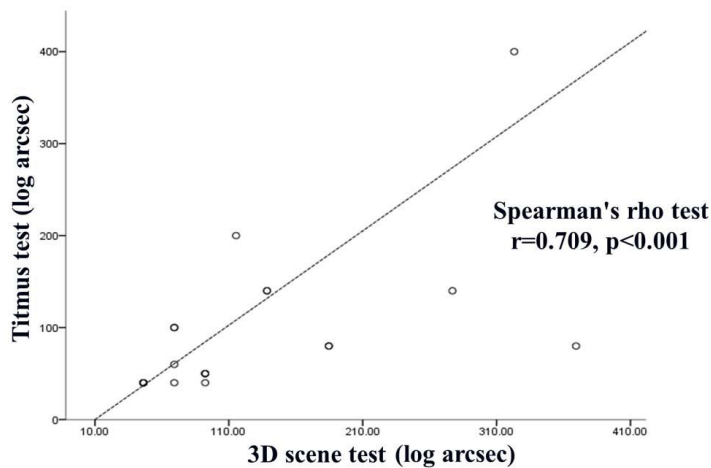
Parameters	Preoperative	Postoperative 3M	<i>p</i> value
Mean deviation angle (PD)			
At distance	28.04 ± 9.93 (18-55)	1.36 ± 3.56 (0-10)	<0.001
At near	26.04 ± 8.09 (18-45)	0.28 ± 0.68 (0-3)	<0.001
3-D motion perception (arcsec)	61.26 ± 25.97 (53.18-212.71)	49.01 ± 20.44 (53.18-159.53)	0.024
Titmus stereotest (arcsec)	90.40 ± 77.75 (40-400)	63.20 ± 29.40 (40-140)	0.030

Mean \pm Standard deviation (range); PD=prism diopter; M=months

Correlations between 3-D motion perception and Titmus stereoacuity

There were positive correlations between the 3-D motion perception (Log arcsec) and Titmus stereoacuity (Log arcsec) preoperatively (Correlation=0.709, $p<0.001$) and postoperatively at three months (Correlation=0.466, $p=0.038$, Figure 2).

(a) Preoperative stereoacuity



(b) Postoperative stereoacuity

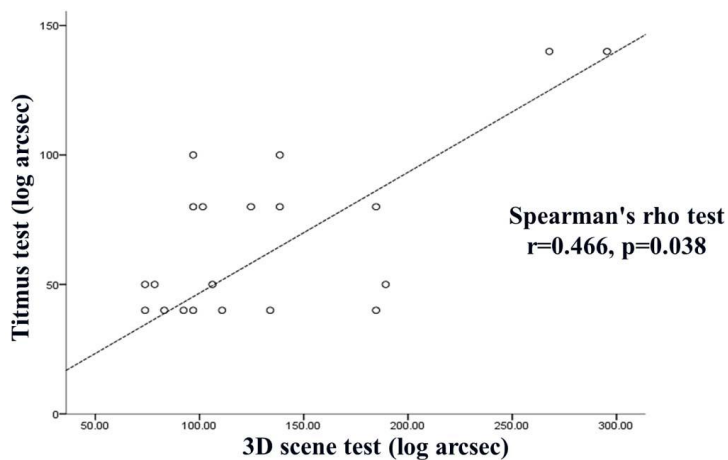


Figure 2. Correlations between threshold of 3-D motion perception and Titmus stereotest in IXT group

IV. DISCUSSION

IXT is known to affect distance and near stereoacuity. Consistent with our results, previous studies demonstrated that stereoacuity in IXT improved after surgery for IXT according to 2-D stereotests^{4,5,7-9}; however, studies showed that patients did not reach normal levels six months after surgery.^{4,7} Stereoacuity is one of the tools used to determine the timing of surgery for IXT; declining stereoacuity is an indication for surgical intervention.^{6,10}

Stereoacuity tests are designed primarily for measurement and are much different from actual 3-D images in real life¹¹. One study for the perception of 3-D dynamic images used only subjective questionnaires to assess accompanying symptoms¹². The most common way that 3-D stereoacuity is experienced is through watching 3-D videos; however, conventional stereoacuity tests use stationary, interwoven images, which differ from actual 3-D images. Therefore, we decided to investigate the change in 3-D motion perception with 3-D dynamic images before and after IXT surgery.

Prior to starting this study, we considered the fact that most of the subjects would be children with poor stereoacuity. Because these patients have never experienced real-life stereoacuity, it would be difficult for them to assess differences between two 3-D images. Therefore, we asked patients to assess differences between 3-D images and 2-D images of the same scene or other depth levels of 3-D images.

We found that the 3-D motion perception of 3-D dynamic stereotests were better than that of the static stereoacuity with the Titmus test. There are several potential explanations for these results. First, the 3-D dynamic stereotest has motion clues. Basic researches have suggested the existence of two possible cues to 'motion-in-depth perception'.¹³ One cue, called interocular velocity differences, would involve early motion processing at monocular levels of vision. This would be followed by a binocular combination of the monocular motion signals to yield information about the object's movement in depth; however, this idea remains controversial.¹⁴⁻¹⁸ The other cue, called cyclopean motion, would

involve a motion-computation process applied to dynamic disparity signals. This motion process would occur at binocular-integration levels of vision to yield information about movement in depth.¹⁹ Second, the method that we used to assess 3-D motion perception was to compare 3-D images with the 2-D images. In contrast, the Titmus stereotest requires patients to find the correct answer. Therefore, subjects would be likely to show better performance on the 3-D dynamic stereotest than on the Titmus stereotest.

There are some limitations in this study. We included patients older than five years; thus, the findings may not be directly applied to children younger than five years. We did not examine the 3-D depth level with discontinuous values; therefore, further studies are required. Assessments of 3-D perception require comparisons with not only the Titmus stereotest, but also with other stereotests. Although there are several methods for studying 3-D systems, including the shutter glasses method, this study was performed using the polarized 3-D system, which is the most popular.

V. CONCLUSION

Stereoacuity was significantly improved in both 3-D motion perception and Titmus stereotests after IXT surgery. We found high correlations between 3-D motion perception and Titmus stereotest in IXT patients and normal subjects. Further studies will assess whether these results can be compared to other stereotests, and whether the method is useful for screening children for other visual abnormalities. Furthermore, the 3-D dynamic stereotest may be useful for assessing outcomes of IXT surgery, as the results of these tests correlated with real-life 3-D images.

REFERENCES

1. Rutstein RP, Corliss DA. The clinical course of intermittent exotropia. *Optom Vis Sci* 2003;80:644-49.
2. Abroms AD, Mohny BG, Rush DP, *et al.* Timely surgery in intermittent and constant exotropia for superior sensory outcome. *Am J Ophthalmol* 2001;131:111-6.
3. Pratt-Johnson JA, Barlow JM, Tillson G. Early surgery in intermittent exotropia. *Am J Ophthalmol* 1977;84:689-94.
4. Sharma P, Saxena R, Narvekar M, *et al.* Evaluation of distance and near stereoacuity and fusional vergence in intermittent exotropia. *Indian J Ophthalmol* 2008;56:121-5.
5. Adams WE, Leske DA, Hatt SR, *et al.* Improvement in distance stereoacuity following surgery for intermittent exotropia. *J AAPOS* 2008;12:141-4.
6. Singh A, Sharma P, Singh D, *et al.* Evaluation of FD2 (Frisby Davis distance) stereotest in surgical management of intermittent exotropia. *Br J Ophthalmol* 2013;97:1318-21.
7. Saxena R, Kakkar A, Menon V, *et al.* Evaluation of factors influencing distance stereoacuity on Frisby-Davis Distance Test (FD2) in intermittent exotropia. *Br J Ophthalmol* 2011;95:1098-101.
8. Yildirim C, Mutlu FM, Chen Y, *et al.* Assessment of central and peripheral fusion and near and distance stereoacuity in intermittent exotropic patients before and after strabismus surgery. *Am J Ophthalmol* 1999;128:222-30.
9. O'Neal TD, Rosenbaum AL, Stathacopoulos RA. Distance stereo acuity improvement in intermittent exotropic patients following strabismus surgery. *J Pediatr Ophthalmol Strabismus* 1995;32:353-7.
10. Holmes JM, Leske DA, Hatt SR, *et al.* Stability of near stereoacuity in childhood intermittent exotropia. *J AAPOS* 2011;15:462-7.

11. Breyer A, Jiang X, Rutsche A, *et al.* A new 3D monitor-based random-dot stereotest for children. *Invest Ophthalmol Vis Sci* 2006;47:4842-6.
12. Kim SH, Suh YW, Yun CM, *et al.* 3D asthenopia in horizontal deviation. *Curr Eye Res* 2013;38:614-9.
13. Patterson R. Unresolved issues in stereopsis: dynamic disparity processing. *Spat Vis* 2009;22:83-90.
14. Fernandez JM, Farell B. Seeing motion in depth using inter-ocular velocity differences. *Vision Res* 2005;45:2786-98.
15. Harris JM, McKee SP, Watamaniuk SN. Visual search for motion-in-depth: stereomotion does not 'pop out' from disparity noise. *Nat Neurosci* 1998;1:165-8.
16. Brooks KR, Stone LS. Stereomotion suppression and the perception of speed: accuracy and precision as a function of 3D trajectory. *J Vis* 2006;6:1214-23.
17. Brooks KR, Stone LS. Spatial scale of stereomotion speed processing. *J Vis* 2006;6:1257-66.
18. Tyler CW. Stereoscopic depth movement: two eyes less sensitive than one. *Science* 1971;174:958-61.
19. Patterson R. Stereoscopic (cyclopean) motion sensing. *Vision Res* 1999;39:3329-45.

ABSTRACT(IN KOREAN)

외사시수술 전후의 입체시 및 삼차원영상 인지양상의 변화

< 지도교수 한 승 한 >

연세대학교 대학원 의학과

조 영 주

목적 : 간혈외사시 수술 전과 수술 3개월 후 삼차원영상 인지양상 변화를 분석하고자 하였다.

방법 : 총 51명을 대상으로 시행하였으며, 본원에서 간혈외사시 수술 예정인 환자 26명과 대조군 25명이 포함되었다. 삼차원영상은 0 (0 mm 영상분리, 이차원영상)부터 100 (15 mm 영상분리)까지 10단위로 나누어 구분하였다.

결과 : 대조군에서 삼차원영상 인지양상은 평균 48.43 ± 18.45 초각 이었고, 티트무스 입체시는 평균 60.38 ± 37.25 초각이었으며, 삼차원영상 인지양상과 티트무스 입체시 모두 양의 상관관계를 보였다 (상관계수=0.421, $p=0.026$). 간혈성외사시군의 수술 전 평균 사시각도는 원거리에서 28.04 ± 9.93 프리즘 디옵터, 근거리에서 26.04 ± 8.09 프리즘 디옵터였으며, 수술후 3개월째 원거리 1.36 ± 3.56 프리즘 디옵터, 근거리 0.28 ± 0.68 프리즘 디옵터로 호전된 양상을 보였다. 간혈성외사시군의 수술 전 삼차원영상 인지양상은 평균 61.26 ± 25.97 초각에서 수술 후 3개월째 평균 49.01 ± 20.44 초각으로 호전되었고 ($p=0.024$), 티트무스 입체시는 수술전 평균 90.40 ± 77.75 초각에서 수술 후 3개월째 63.20 ± 29.40 초각으로 호전되었다 ($p=0.030$). 또한 삼차원영상 인지양상과 티트무스 입체시는 수술 전 (상관계수=0.709, $p<0.001$)과 수술 후

(상관계수=0.466, $p=0.038$) 모두 양의 상관관계를 보였다.

결론 : 성공적인 외사시 수술 후 삼차원영상 인지양상과 티트무스 입체시는 모두 호전되는 양상을 보였다. 따라서 삼차원영상 인지양상 검사를 통해 실제 입체시 생활과 관련되어 성공적인 외사시 수술을 가늠하는 척도로도 사용될 수 있을 것이다.

핵심되는 말 : 입체시, 삼차원영상, 외사시