

## Total Necrosis of Hepatocellular Carcinoma Due to Spontaneous Occlusion of Feeding Artery

Sang-Cheol Lee<sup>1</sup>, Hye Won Chung<sup>1</sup>, Jae-Bock Chung<sup>1</sup>, Young-Nyun Park<sup>2</sup>, Sang-Hoon Ahn<sup>1</sup>,  
Seung-Woo Park<sup>1</sup>, Chae-Yoon Chun<sup>1</sup>, Young-Myoung Moon<sup>1</sup>, Jin-Kyung Kang<sup>1</sup>, and In-Suh Park<sup>1</sup>

Departments of <sup>1</sup>Internal Medicine, <sup>2</sup>Pathology, Yonsei University College of Medicine, Seoul, Korea.

Spontaneous total necrosis of hepatocellular carcinoma is extremely rare, with only 15 cases reported to date in the English literature, and the involved mechanism remains unresolved. This paper describes a case of spontaneous necrosis of hepatocellular carcinoma in a 70-year-old man with chronic hepatitis. The patient suffered epigastric pain on admission and computed tomography revealed a 4 cm mass with low density in the left lobe of the liver. Fine needle aspiration biopsy revealed a few scattered, naked and irregular nuclei exhibiting nuclear hyperchromasia in the dirty necrotic background, a finding highly suggestive of malignancy. The lobectomized liver revealed a 3.5 cm, well encapsulated, round, and nearly totally necrotic mass. On microscopic examination, the tumor was found to be composed of thick trabeculae of necrotic tumor cells, supporting the diagnosis of hepatocellular carcinoma.

After surgery and throughout 13 months of follow up the patient has recovered well.

**Key Words:** Hepatocellular carcinoma, spontaneous necrosis

### INTRODUCTION

Hepatocellular carcinoma (HCC) usually exhibits a poor prognosis. The risk factors of hepatocellular carcinoma are chronic hepatitis B, chronic hepatitis C and aflatoxin B1.<sup>1</sup> Surgical resection offers a chance for long-term survival to only a small percentage of patients. Transarterial chemoembolization and the injection of ethanol

have been attempted in surgically unresectable cases.

Spontaneous necrosis of HCC is extremely rare with only 15 cases having been reported in the English medical literature.<sup>2-16</sup> Although the exact mechanism of spontaneous necrosis of HCC is not understood, numerous mechanisms including rapid tumor growth, infection, gastrointestinal bleeding, arterial thrombus, and immune mechanism have been suggested.

We report a case of spontaneously necrotized hepatocellular carcinoma found after lobectomy of the liver.

### CASE REPORT

A 70-year-old male was admitted to our hospital with epigastric pain of 2 months duration. Although he had received medication from a pharmacist, he was suffering from pain and generalized weakness on admission. He had been a social drinker and denied a history of hepatitis. His family history was unremarkable.

Physical examination revealed tenderness of the abdominal right upper quadrant. The liver and spleen were not palpable. Cardiac, pulmonary, and neurologic examinations were normal. Laboratory studies disclosed the following values: WBC count 4000/mm<sup>3</sup> (neutrophil 1800/mm<sup>3</sup>, lymphocyte 700/mm<sup>3</sup>, monocyte 440/mm<sup>3</sup>, eosinophil 1100/mm<sup>3</sup>); total bilirubin, 1.1 mg/dl; serum alkaline phosphatase, 81 IU/L (normal 38 - 115); serum aspartate transaminase, 21 IU/L; serum alanine transaminase, 20 IU/L; prothrombin time 12.9 sec (control 11.5 - 14.5 sec) and

Received February 28, 2001

Accepted October 12, 2001

Reprint address: requests to Dr. Jae Bock Chung, Department of Internal Medicine, Yonsei University College of Medicine, C.P.O. Box 8044, Seoul 120-752, Korea. Tel: 82-2-361-5410, Fax: 82-2-393-6884, E-mail: jbchung@yumc.yonsei.ac.kr

alpha-fetoprotein, 1.47 IU/L. Hepatitis B surface antigen (HBsAg), hepatitis B surface antibody (anti-HBs) and antibody to hepatitis C virus were negative by radioimmunoassay. Hepatitis B core antibody (anti-HBc) was positive. Stool exam was negative for ova and parasite.

Liver ultrasonography showed a  $3 \times 3$  cm sized hypoechoic lesion with a surrounding halo rim in the left medial lobe. The tumor appeared as a low-density lesion on contrast enhanced CT scans (Fig. 1). Although efforts were made to detect the primary lesion using esophagoduodenoscopy and colonoscopy, no significant findings were made except two polyps, one at the ascending colon and the other at the sigmoid colon. MRI performed for evaluation of the mass lesion, resulted

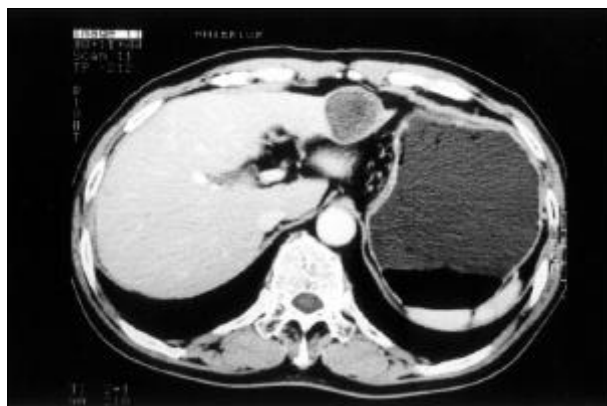


Fig. 1. CT scan at the time of diagnosis of hepatocellular carcinoma. A 4 cm low density mass lesion can be seen on left lobe of liver, with a well margined capsule.

in a high T2 signal and a low T1 signal. Enhancement of the mass in dynamic study was not definite (Fig. 2).

Fine needle aspiration biopsy of the liver indicated the presence of cytologically malignant cells, which were interpreted as being consistent with a malignant tumor, and revealed almost total necrosis with a few scattered naked nuclei exhibiting nuclear hyperchromasia and irregular nuclear membranes (Fig. 3). Immunohistochemical staining didn't show any result to clarify the diagnosis due to decreased cellularity and marked necrosis.

Because poor vascularity of the lesion was suspected, hepatic angiography was not performed and the patient underwent left hepatic lobectomy for diagnosis and treatment on the 24<sup>th</sup> admission day. The resected liver showed a 3.5 cm well circumscribed, encapsulated round mass displaying a whitish yellow & necrotic cut surface in the medial segment of the lateral lobe (Fig. 4). The tumor was nearly totally necrotic and its/the thick trabecular pattern of necrotic tumor cells supported the diagnosis of hepatocellular carcinoma (Fig. 5). Microscopic features of feeding arteries near the tumor demonstrated complete or partial occlusion (Fig. 6). The histology of the remaining liver parenchyma disclosed chronic hepatitis with lobular activity, mild porto-periportal activity and septal fibrosis. Focal ductal hyperplasia and adenomatoid mural glandular hyperplasia were noted in the remaining liver parenchyma and there was a suspicion of clonorchis

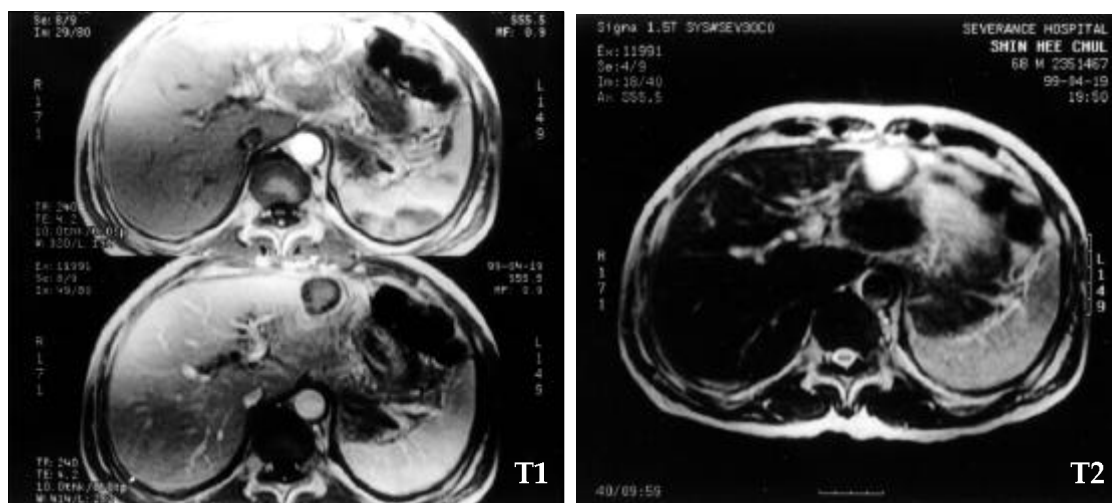
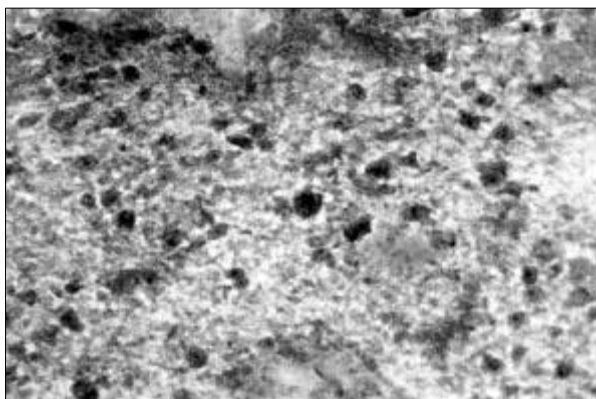
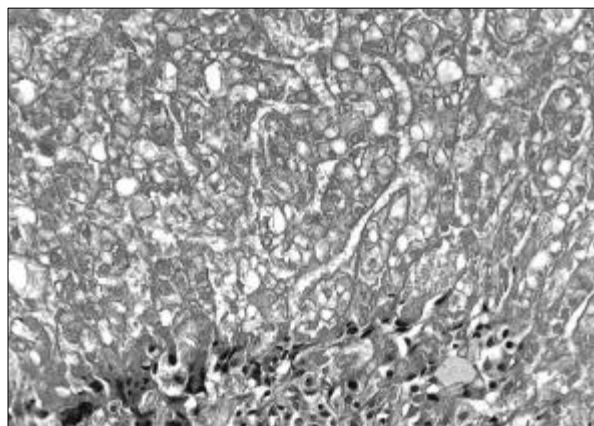



Fig. 2. MRI at the time of diagnosis shows low signal mass in T1 weighted image and high signal in T2 weighted image.



**Fig. 3.** Almost total necrosis with a few scattered naked nuclei showing nuclear hyperchromasia and irregular nuclear membranes in an aspiration biopsy specimen of the tumor (Papanicolaou stain,  $\times 400$ ).



**Fig. 5.** Microscopic features of the tumor demonstrating a thick trabecular pattern and extensive necrotic change (H & E stain,  $\times 200$ ).



**Fig. 4.** Gross features of the tumor. A well circumscribed, encapsulated, and round mass showing a whitish yellow & necrotic cut surface.



**Fig. 6.** Microscopic features of the feeding artery. The lumen of the feeding artery shows/reveals partial occlusion (Elastic-VanGieson's stain,  $\times 100$ ).

sinensis infection. We concluded that the histologic findings of the tumor were compatible with a diagnosis of hepatocellular carcinoma. Two nodules smaller than 1 cm, observed in segments 7 and 8, revealed eosinophilic infiltration histologically without any evidence of malignancy, a finding that suggested eosinophilic abscess probably due to parasite infection.

After surgical treatment, the patient recovered well and throughout 13 months of follow up in the outpatient clinic he has continued to be asymptomatic.

## DISCUSSION

The phenomenon of spontaneous necrosis of

hepatocellular carcinoma is very rare. The mechanisms previously proposed include sudden rapid tumor growth,<sup>5</sup> gastro-intestinal bleeding,<sup>11,14</sup> the effects of local cytokines,<sup>4</sup> withdrawal of environmental factors required for tumor growth,<sup>4,7,11,13</sup> deprivation of oxygen and nutrients,<sup>10</sup> use of unconventional drugs,<sup>4</sup> fever,<sup>3,8</sup> massive transfusion,<sup>6</sup> and infection.<sup>8</sup>

The histological features favoring HCC are moderate to severe nuclear atypia, plates or trabeculae more than two or three cells wide, loss of reticulin fibers, pseudoglandular growth pattern and infiltrative growth or invasion of veins.<sup>17</sup> Necrosis is a feature of moderately or poorly differentiated HCC and has been reported in some cases of spontaneously necrotized HCC.<sup>10</sup> The evidence supporting the diagnosis of HCC in this

case was a thick trabeculae pattern of width more than two or three cells, although detailed cytologic features could not be evaluated due to massive ischemic necrosis.<sup>17</sup> Because the tumor exhibited totally necrotic features and included only a few viable cells, immunohistochemical stains such as HBs Ag, UCD/PRD 10.11,<sup>12</sup> and Qbend10,<sup>2</sup> which had been performed in some HCC cases reported previously, were not possible. The presence of HBc Ab and the histologic feature of chronic hepatitis in the liver parenchyme also supported the diagnosis of HCC.

Everson and Cole<sup>17</sup> considered regression of cancer to be spontaneous if it occurred without the administration of anticancer drugs or surgical resection. We believe that the present case is compatible with this definition of spontaneous necrosis of cancer as the tumor demonstrated total necrosis without previous anticancer drug therapy or surgical resection. Although the slight possibility that the tumor was an adenoma remains, we believe this possibility is low because adenomas are usually unencapsulated and are rare in the parenchyme of chronic hepatitis.

HCC is a rapidly growing tumor and therefore, highly dependent on its blood supply. Massive gastrointestinal bleeding followed by severe and prolonged shock causes a relative decrease in blood supply to the tumor, which may lead to necrosis. Tumor ischemia may develop acutely by the occlusion of a feeding artery, such as reported by Imaoka et al.<sup>10</sup> Furthermore, Haltren et al.<sup>16</sup> reported that fast growing HCC in a poorly vascularized cirrhotic liver could lead to ischemia and necrosis in a chronic condition. Rapid tumor growth triggered by infection or immunologic factors can induce tumor necrosis, due to a relative decrease in the blood supply. In the present case, the most probable mechanism of spontaneous necrosis is occlusion of feeding arteries by thrombus as confirmed in the microscopic findings even though the cause of occlusion was not revealed. Since the parenchyme of the liver was not cirrhotic, liver cirrhosis could not be the cause. Other possible mechanisms such as drugs, transfusion, fever, abstinence of drinking, herbal medication, infection, and hormonal effects could all be ruled out by history.

In summary, we report a patient with a spon-

taneously regressed hepatocellular carcinoma, found after lobectomy of the liver, and his ongoing survival during 13 months of follow up without any evidence of recurrence. Although the definitive mechanism has not been confirmed, it is important / essential to report all cases of spontaneously regressed HCC in order to contribute to the understanding of this extraordinarily unusual phenomenon.

## REFERENCES

1. Hadziyannis SJ. Hepatocellular carcinoma and type B hepatitis. *Clin Gastroenterol* 1980;9:117-34.
2. Kaczynski J, Hansson G, Remotti H, Wallerstedt S. Spontaneous regression of hepatocellular carcinoma. *Hepatology* 1998;32:147-50.
3. Markovic S, Ferlan-Marolt V, Hlebanja Z. Spontaneous regression of hepatocellular carcinoma. *Am J Gastroenterol* 1996;91:392-3.
4. Grossmann M, Hoermann R, Weiss M, Jauch KW, Oertel H, Staebler A, et al. Spontaneous regression of hepatocellular carcinoma. *Am J Gastroenterol* 1995;90:1500-3.
5. Suzuki M, Okazaki N, Yoshino M, Yoshida T. Spontaneous regression of hepatocellular carcinoma: a case report. *Hepatogastroenterology* 1989;36:160-3.
6. Sato Y, Fujiwara K, Nakagawa S, Kanishima S, Ohta Y, Oka Y, et al. A case of spontaneous regression of hepatocellular carcinoma with bone metastasis. *Cancer* 1985;56:667-71.
7. Gottfried EB, Steller R, Paronetto F, Lieber CS. Spontaneous regression of hepatocellular carcinoma. *Gastroenterology* 1982;82:770-4.
8. Lam KC, Ho JC, Yeung RT. Spontaneous regression of hepatocellular carcinoma: a case report. *Cancer* 1982;50:332-6.
9. Tarav PG. Spontaneous necrosis of liver cancer: One more possible cause. *Am J Gastroenterol* 1996;91:1872-3.
10. Imaoka S, Sasaki I, Masutani S, Ishikawa H, Furukawa T, Kabuto M, et al. Necrosis of hepatocellular carcinoma caused by spontaneously arising arterial thrombus. *Hepatogastroenterology* 1994;41:359-62.
11. Gaffey MJ, Joyce JP, Carlson GC, Esteban JM. Spontaneous regression of hepatocellular carcinoma. *Cancer* 1990;65:2779-83.
12. Ozeki Y, Matsubara N, Tateyama K, Kokubo M, Shimoji H, Katayama M. Spontaneous complete necrosis of hepatocellular carcinoma. *Am J Gastroenterol* 1996;91:391-2.
13. McCaughan GW, Bilous MJ, Gallagher ND. Long-term survival with tumor regression in androgen-induced liver tumors. *Cancer* 1985;56:2622-6.
14. Tocci G, Conte A, Guarascio P, Visco G. Spontaneous

- remission of hepatocellular carcinoma after massive gastrointestinal haemorrhage. *BMJ* 1990;300:641-2.
15. Chien RN, Chen TJ, Liaw YF. Spontaneous regression of hepatocellular carcinoma. *Am J Gastroenterol* 1992; 87:903-5.
16. Van Halteren HK, Salemans JM, Peters H, Vreugdenhil G, Driessen WM. Spontaneous regression of hepatocellular carcinoma. *J Hepatol* 1997;27:211-5.
17. Everson TC, Cole WH. Spontaneous regression of cancer. Philadelphia: WB Saunders, 1966;6-7. International Working Party. Terminology of nodular hepatocellular lesions. *Hepatology* 1995;22:983-93.