

가

Limb Salvage with Low Heat Treated Autobone and Conventional Prosthesis

**Moon-Soo Park, M.D., Kyung Soo Suk, M.D.*, Kyoo-Ho Shin, M.D.,
Chang Dong Han, M.D., Soo Bong Hahn, M.D., Eung Shick Kang, M.D.**

*Department of Orthopaedic Surgery, Yonsei University College of Medicine
Department of Orthopaedic Surgery, College of Medicine, Kyung Hee University*, Seoul, Korea*

Limb salvage using a low heat treated autobone and conventional joint prosthesis was done in 12 patients with nine osteosarcomas, one chondrosarcoma, and two malignant spindle cell sarcomas, composed of six proximal femurs and six proximal humeri. The overall union rate of the low heat treated autobone with normal host bone was 91.7%, and the mean union time was 4.6 months (range, 3-7 months) after surgery. The functional result of the proximal femur and proximal humerus were 76.7% and 56.8%, respectively. Complications were included hip dislocation (8.3%), fracture of the low heat treated bone (16.7%), and absorption of the low heat treated autobone in four of six patients of the humerus (66.7%). The five years survival rate of the low heat treated autobone was 83.3% using Kaplan Meier survival analysis. Based on the results of this study, limb salvage with the low heat treated autobone appears to be effective in treating primary bone sarcoma with proven high survival and low complication rate, circumventing complications of allograft bone.

Key Words : Malignant bone tumor, Limb salvage, Autobone graft, Conventional prosthesis

* Address for Correspondence : **Kyoo-Ho Shin, M.D.**
Department of Orthopaedic Surgery, Yonsei University College of Medicine
#134 Shinchon-dong, Seodaemun-gu, Seoul, 120-752, Korea
Tel : 82-2-361-5650, Fax : 82-2-363-1139, E-mail : qshin@yumc.yonsei.ac.kr

58 . 9 ,
 2 , 1 6 ,
 6 . Enneking⁸⁾
 IIA가 3 , IIB가 9 (Table 1).

1, 5, 13, 15, 18)
 9, 10, 20, 22), 12, 17, 19, 25)
 가 2, 4, 11, 16)
 가
 가
 가

2.
 . 9
 cisplatin(Cisplan120 mg/m²,
) adriamycin
 (25 mg/m²,)
 3 .

가
 가
 가

3cm
 3

가
 가

65 30

1.
 1994 1998
 가

(DePuy CMW 1 original bone cement,
 Warsaw, IN) stem
 (DePuy global shoulder system or DePuy
 Elite Plus hip system)

31.8 11

62 가 7 , 가 5
 26.1 , 10

(Fig. 1,2).

Bard mesh(Davol Inc. Cranston RI)

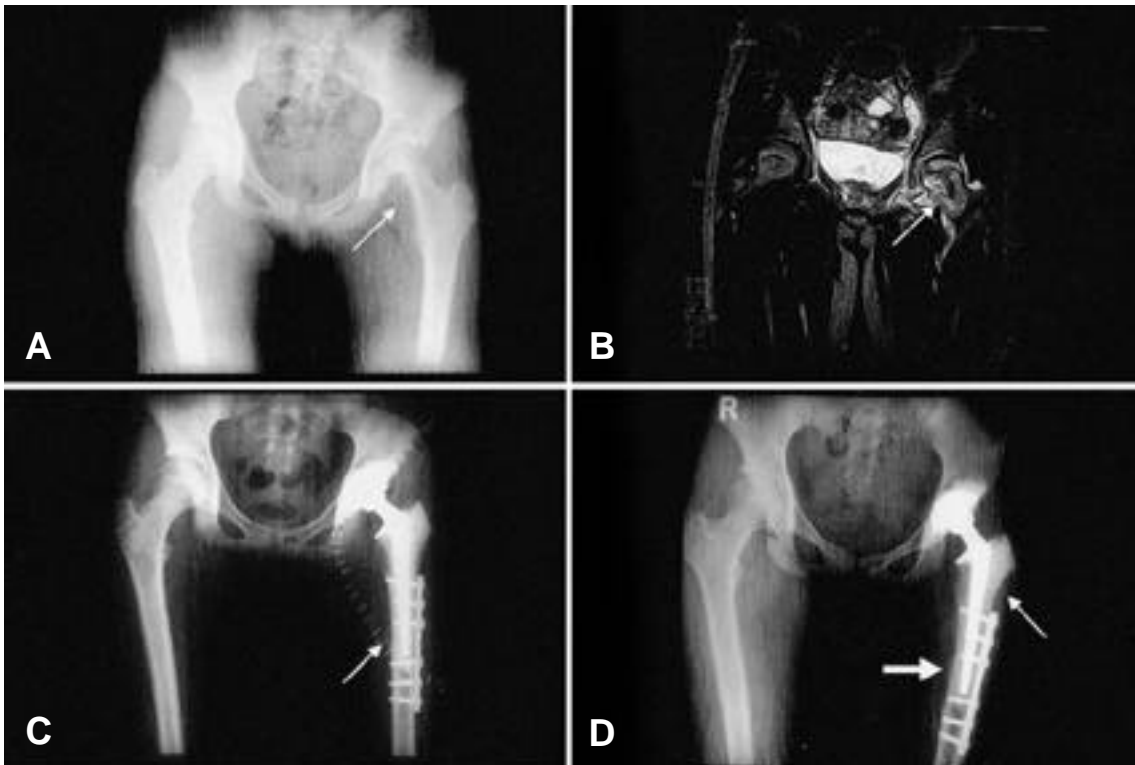


Fig. 1A-D. A 13-year-old girl had osteoblastic osteosarcoma of the femoral head and neck. **(A)** A preoperative plain radiograph shows a radiolucent lesion (arrow) on the inferomedial aspect of the femoral head and neck. **(B)** A T2-weighted coronal magnetic resonance image shows invasion of the hip by a tumor mass (white arrow). **(C)** A postoperative radiograph shows the reconstruction of the hip with total hip arthroplasty after extraarticular excision, and the osteotomy site (white arrow) **(D)** A plain radiograph obtained at the 42-month followup shows a solid bony union (large white arrow). New bone formation was found on the lateral aspect of the low heat treated bone (small white arrow).

가 90% methotrexate
 (10 g/m², ,) ifosfamide
 (Holoxan 1.5 g/m², ,)
 etoposide(Laste100 mg/m², , ,)
)
 가 가
 가 가
 가 Enneking 7)

Mann-Whitney U test, chi square test, Fisher's exact test

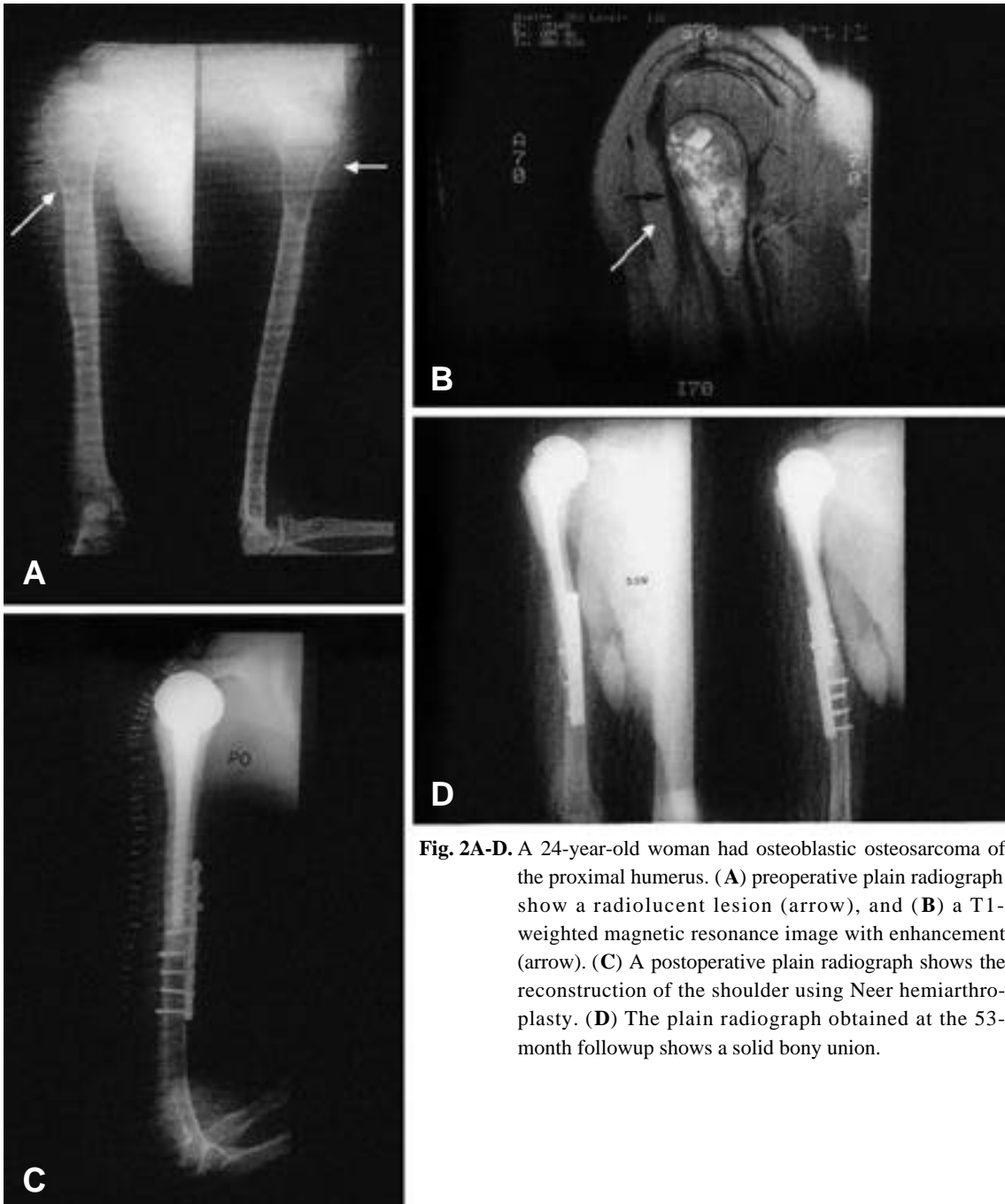


Fig. 2A-D. A 24-year-old woman had osteoblastic osteosarcoma of the proximal humerus. (A) preoperative plain radiograph show a radiolucent lesion (arrow), and (B) a T1-weighted magnetic resonance image with enhancement (arrow). (C) A postoperative plain radiograph shows the reconstruction of the shoulder using Neer hemiarthroplasty. (D) The plain radiograph obtained at the 53-month followup shows a solid bony union.

Table 1. Patients' Data

Patient	Age (Years)/ Gender	Lesion	Diagnosis	Enneking Stage	Operation	Union	Union Time (Months)	Function(%)	Chemotherapy	Tumor Necrosis (%)	Distant Metastasis	State of Patients	Followup (Months)
1	16/M	Femur	Osteosarcoma	IIB	Bipolar	Yes	4	57	+	99	(-)	CDF	11
2	58/M	Femur	Malignant spindle sarcoma	IIA	Bipolar	Yes	4	80	-	(-)	(-)	CDF	17
3	18/F	Femur	Osteosarcoma	IIB	THR	Yes	3	80	+	70	(-)	CDF	13
4	15/M	Femur	Osteosarcoma	IIB	THR	Yes	7	77	+	10	Lung	DOD	20
5	13/F	Femur	Osteosarcoma	IIB	THR	Yes	3	83	+	80	Lung	DOD	52
6	39/M	Femur	Malignant spindle sarcoma	IIA	Bipolar	Yes	4	80	-	(-)	(-)	CDF	12
7	52/M	Humerus	Chondrosarcoma	IIA	Neer	Yes	6	67	-	(-)	(-)	CDF	44
8	17/F	Humerus	Osteosarcoma	IIB	Neer	No	-	53	+	100	Lung	NED	42
9	10/M	Humerus	Osteosarcoma	IIB	Neer	Yes	4	67	+	100	(-)	CDF	45
10	23/F	Humerus	Osteosarcoma	IIB	Neer	Yes	7	60	+	99	(-)	CDF	30
11	24/F	Humerus	Osteosarcoma	IIB	Neer	Yes	3	47	+	100	(-)	CDF	62
12	28/M	Humerus	Osteosarcoma	IIB	Neer	Yes	6	47	+	100	(-)	CDF	35

M : Male

F : Female

Bipolar: Bipolar hip hemiarthroplasty

THR: Total hip replacement

Neer: Neer shoulder hemiarthroplasty


CDF: continuous disease free

NED: no evidence of disease

DOD: died of disease

(22.8) 가
56.8%(17.0) .
가 Mann Whitney U test
1. Fisher's exact test
가 (Table 1, p=0.011).
11) 1 .
100% 5.
83.3% . 4.6 4 가 100% 2
(3 7) 90% , 3 90% (80%, 70%
4.2 10%) (Table 1).
5.2 . 가 3 22.7 (17
(p=1.000) (p=0.300) 34)
가 (Table 1). . 90% 3
2. 가 2 17 가
2 가 1 1 34 가
가 . Kaplan Meier survival analysis
analysis 가 52.4
57.3 52 5
62 5 83.3% . 36
17 5 0% .
3. 33.3%(12 4) (Table 1).
3 (25.0%) . 2
, 1 7
, 1 11 가
2-4,11,16)
. 6 2), 가 16) 11,14)
4 가 (Fig. 1), 1 .
1956 Thompson Stegga²⁴⁾
가 가 .
3 가 1 (131)
. 5
. 70
4. 가 1
가 66.5%(19.6) . Lu ¹⁶⁾
가 76.7% 가 50

Ham ¹⁰⁾ 65 , (Fig. 1)
 3 , 3 ,
 Liebergall ¹⁴⁾ 60 Neer (Fig. 2) 6
 30 가 . 3
 (Fig. 1).
 Bohm Stihle⁹⁾ 가 . 1 , 1
 45 11 .
 65 30 가
 91.7% Neer ,
 4.6 2
 (65 30) 3,21) 6 4
 가
 가 1
 57.3
 62 5 83.3%
 가 9,10,20,22) 가 76.7%
 (22.8)
 가 6)
 65 30 가 56.8%(17.0)
 가
 Bacci ¹⁾ , 가 5 43.8%
 가 17
 가 52



REFERENCES

- 1) **Bacci G, Ferrari S, Mercuri M, et al** : Predictive factors for local recurrence in osteosarcoma: 540 patients with extremity tumors followed for minimum 2.5 years after neoadjuvant chemotherapy. *Acta Orthop Scand* 69:230-236, 1998.
- 2) **Bohm P** : Replantation of extracorporeally devitalized bone segments for defect reconstruction in tumor orthopedics - An overview. *Z Orthop Ihre Grenzgeb* 136:197-204, 1998.
- 3) **Bohm P, Springfield R and Springer H** : Re-implantation of autoclaved bone segment in musculoskeletal tumor surgery. Clinical experience in 9 patients followed for 1.1-8.4 years and review of the literature. *Arch Orthop Trauma Surg* 118:57-65, 1998.
- 4) **Bohm P and Stihler J** : Intraosseous temperature during autoclaving. *J Bone Joint Surg* 77-B:649-653, 1995.
- 5) **Bruns J, Luessenhop S and Behrens P** : Cost analysis of three different surgical procedures for treatment of a pelvic tumor. *Langenbecks Arch Surg* 383:359-363, 1998.
- 6) **Davis AM, Devlin M, Griffin AM, Wunder JS and Bell RS** : Functional outcome in amputation versus limb-sparing of patients with lower extremity sarcoma: A matched case-control study. *Arch Phys Med Rehabil* 80:615-618, 1999.
- 7) **Enneking WF, Dunham W, Gebhardt MC, Malawar M and Pritchard DJ** : A system for the functional evaluation of reconstructive procedures after surgical treatment of tumors of the musculoskeletal system. *Clin Orthop* 286:241-246, 1993.
- 8) **Enneking WF, Spanier SS and Goodman MA** : A system for the surgical staging of musculoskeletal sarcoma. *Clin Orthop* 153:106-120, 1980.
- 9) **Fabroni RH, Castagno A, Aguilera AL, Steverlynck AM and Zeballos J** : Long-term results of limb salvage with the Fabroni custom made endoprosthesis. *Clin Orthop* 358:41-52, 1999.
- 10) **Ham SJ, Schraffordt KH, Veth RP, van Horn JR, Molenaar WM and Hoekstra HJ** : limb salvage surgery for primary bone sarcoma or the lower extremities: Long-term consequences of endoprosthetic reconstructions. *Ann Surg Oncol* 5:423-436, 1998.
- 11) **Inoguchi T and Ninomiya H** : Studies on heat treatment for immediate replantation of resected bone. *J Craniomaxillofac Surg* 19:19-39, 1991.
- 12) **Kumta SM, Leung PC, Griffith JF, Roebuck DJ, Chow LT and Li CK** : A technique for enhancing union of allograft to host bone. *J Bone Joint Surg* 80-B:994-998, 1998.
- 13) **Kuntz CA, Asselin TL, Dernel WS, Powers Be, Straw RC and Withrows SJ** : Limb salvage surgery for osteosarcoma of the proximal humerus: Outcome in 17 dogs. *Vet Surg* 27:417-422, 1998.
- 14) **Liebergall M, Simkin A, Mendelson S, Rosenthal A, Amir G and Segal D** : Effect of moderate bone hyperthermia on cell viability and mechanical function. *Clin Orthop* 349:242-248, 1998.
- 15) **Lindner NJ, Ramm O, Hillmann A, et al** : Limb salvage and outcome of osteosarcoma. The University of Muenster experience. *Clin Orthop* 358:83-89, 1999.
- 16) **Lu S, Wang J and Hu Y** : Microwave heating and neoadjuvant chemotherapy for malignant bone tumor. *Chung Hua Wai Ko Tsa Chih* 35:196-199, 1997.
- 17) **McGoveran BM, Davis AM, Gross AE and Bell RS** : Evaluation of the allograft-prosthesis

- composite technique for proximal femoral reconstruction after resection of a primary bone tumor. *Can J Surg* 42:37-45, 1999.
- 18) **Rha SY, Chung HC, Gong SJ, et al** : Combined pre-operative chemotherapy with intra-arterial cisplatin and continuous intravenous Adriamycin for high grade osteosarcoma. *Oncol Rep* 6:631-637, 1999.
 - 19) **Rogala P, Nazar J, Krasny I, Tabiszewski M and Szule A** : Massive allogenic bone grafts in reconstructive surgery after local resection of malignant bone tumor. *Chir Narzadow Ruchu Ortop Pol* 63:413-421, 1998.
 - 20) **Sanjay BK and Moreau PG** : Limb salvage surgery in bone tumor with modular endoprosthesis. *Int Orthop* 23:41-46, 1999.
 - 21) **Sanjay BK, Moreau PG and Younge DA** : Reimplantation of autoclaved tumor bone in limb salvage surgery. *Int Orthop* 21:291-297, 1997.
 - 22) **Shin DS, Wever KL, Chao EY, An KN and Sim FH** : Reoperation for failed prosthetic replacement used for limb salvage. *Clin Orthop* 358:53-63, 1999.
 - 23) **Sluga M, Windhager R, Lang S, Leinzi H, Bielack S and Kotz R** : Local and systemic control after ablative and limb-sparing surgery in patients with osteosarcoma. *Clin Orthop* 358:120-127, 1999.
 - 24) **Thompson VP and Steggall CT** : Chondrosarcoma of the proximal portion of the femur treated by resection and bone replacement. *J Bone Joint Surg* 38-A:357-367, 1956.
 - 25) **Wang Z, Liang G and Yin Q** : Limb salvage surgery using massive allografts in malignant bone tumors. *Chung Hua Wai Ko Tsa Chih* 35: 200-203, 1997.

