

, *

. . * . .

Abstract

A Case of Lupus Nephritis in a Patient with Takayasu's Arteritis

Seung Hoon Lee, M.D., Yong Bum Park, M.D., Hyeon Joo Jeong, M.D.*,
Dae Suk Han, M.D.** , Soo Kon Lee, M.D.

*Division of Rheumatology and Nephrology** , Department of Internal Medicine,
Department of Pathology* , College of Medicine, Yonsei University, Seoul, Korea*

Takayasu's arteritis (TA) is a chronic inflammatory disease which involves large vessels such as aorta, its major branches, and pulmonary vessels, and develops into an obstructive process. The disease affects most frequently oriental races, especially young women, and its etiology has not been found. Systemic lupus erythematosus is a disease which involves mainly small vessels and has been unusually reported to accompany TA in foreign reports, but not yet in Korea. The authors observed a rare case in which a patient diagnosed to have TA at the age of 30, and was accompanied by lupus nephritis. This case doesn't have its precedent in Korea and we review of literatures and report the case.

Key Words : Takayasu's arteritis, Systemic lupus erythematosus, Lupus nephritis

< : 2001 3 5 , : 2001 5 13 >

:

134

Tel : 02) 361-5410, Fax : 02) 393-6884, E-mail : sookonlee@yumc.yonsei.ac.kr

Takayasu

가 가 () Takayasu 6,300/mm³, 10.6g/dl, 238,000/mm³
 가 () 3.4%,
 가 Takayasu 62mm/hr, C- 0.373 mg/dl
 33 Takayasu 가 SGOT/SGPT 28/10IU/L, 0.9mg/dl,
 306mg/dl, alkaline phosphatase
 55IU/L, LDH 489IU/L, BUN 26mg/dl, creati-
 nine 1.2mg/dl, IgG 1550mg/dl(,
 800~1,800), IgA 232mg/dl(, 90~450), IgM
 127mg/dl(, 60-250), C3 102mg/dl(,
 43~105), C4 29.3mg/dl(, 11~47)
 (1: 640 , speckled pattern),
 : , 63 RNP 793.4AU(, <10)
 : DNA , Ro/La , Sm ,
 가 : IgG/IgM cardiolipin ,
 : (lupus anticoagulant),
 (ANCA)
 , , 2 5-10/HPF, 3+ 24
 가 가 5898mg/24hr, (CCr)
 49.22ml/min/1.73m²
 : 33 , : 1996 2
 (1),
 : 15
 2 Takayasu . 1996 가
 15 3 (2).
 : IgG IgM, C3,
 C4 C1q (3A,B).
 160/80mmHg, 175/60mmHg
 84 /min, 36.6 , 12 가
 /min 가 15, 0
 WHO 4
 : Takayasu

(1mg/kg/day)
10
24
565mg/24hr

30
가
50%
3

Takayasu

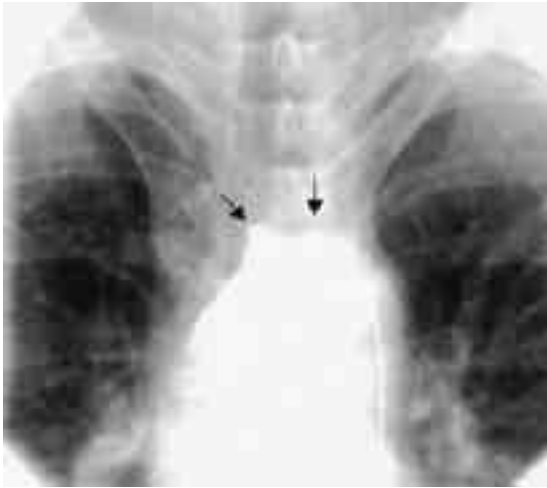


Fig. 1. Angiogram of the right innominate artery (left black arrow) and the left subclavian artery (right black arrow) shows complete obstruction

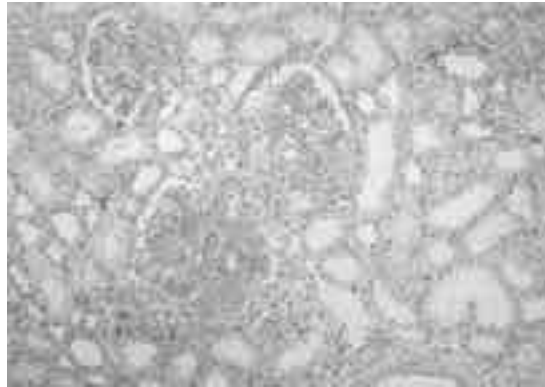


Fig 2. Diffuse proliferative glomerulonephritis. Light microscope of glomeruli show diffuse mesangial cell proliferation and increased mesangial matrix (PAS, x200)

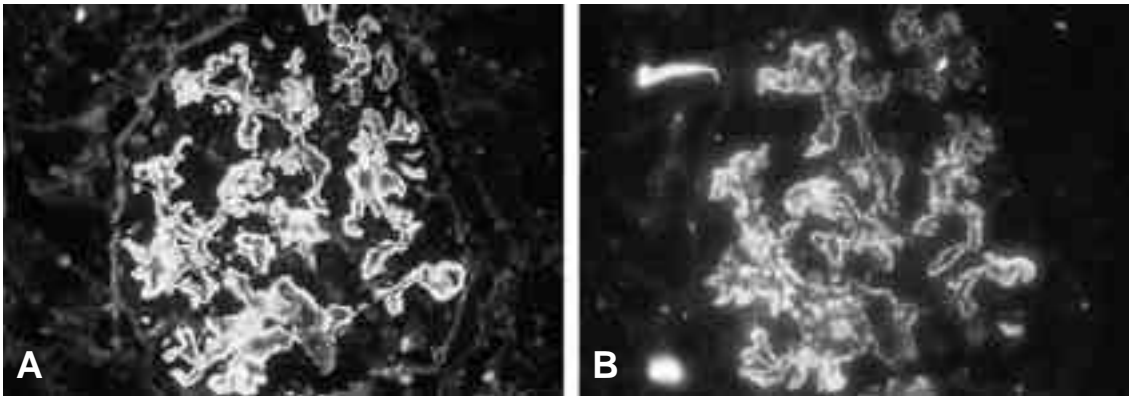


Fig 3. Immunofluorescence microscopy of glomerulus. The glomerulus shows extensive deposits of IgG (A) and moderate deposits of complement (C3) along the capillary loops (B)

가
 Lupi ¹⁾
 (96%), (94%), (72%), (1:640
 (72%) (43%),), 24 5898mg/24hr
 (57%), (41%)
 (13%)

Takayasu
 2/3
 가 . Ito ²⁾ 가 ⁸⁻¹⁰⁾
 Takayasu 2148 Sm
 , DNA , 가, 가 가 .

가 가
 33 , ,
 , 1996 2 Takayasu ^{11,12)}

24
 가 가
 가 Takayasu 가
 가 Takayasu
 가 ^{3,4)} 가

가 ^{5,6)} 가 가
 가 . Philippe Roy
 Takayasu ⁷⁾,
 가 19
 40 ± 13
 , 1:18 ,

Takayasu
 , 가 Takayasu
 (1:640), 24 5898mg/24hr,
 Takayasu
 가 ,

REFERENCES

- 1) Lupi-Herrear E, Sanchez-Torres G, Marcus-Hammer J. Takayasu's arteritis: Clinical study of 107 cases. *Am heart J* 1977;93:93-103.
- 2) Ito I. Aortitis syndrome. *Jpn Med J.* 1977; 2778:7-11.
- 3) Ikeda M. Immunologic studies on Takayasu's arteritis. *Jpn Circ J* 1996;30:87-9.
- 4) Riehl JL, Brown WJ. Takayasu's arteritis: An autoimmune disease. *Arch Neurol* 1965;12:92-7.
- 5) Siguier F, Godeau P, Benichou C. Takayasu's syndrome and lupus disease. *Ann Med Intern* 1970;121:531-5.
- 6) Takahashi S, Sasagawa M, Mitsuma T. A case of aortitis syndrome complicated with systemic lupus erythematosus. *Intern Med* 1985;56:793-6.
- 7) Saxe PA, Altman RD. Takayasu's arteritis syndrome associated with systemic lupus erythematosus. *Semin Arthritis Rheum* 1992; 21:295-305.
- 8) Lai KN, Chan KW, Ho CP. Glomerulonephritis associated with Takayasu's arteritis. Report of three cases and review of the literature. *Am J Kidney Dis* 1986;7:197-204.
- 9) Hellmann DB, Hardy K, Lindenfeld S, Ring E. Takayasu's arteritis associated with crescentic glomerulonephritis. *Arthritis Rheum* 1987;30:451-3.
- 10) Yoshikawa Y, Truong LD, Mattioli CA, Lederer E. Membranoproliferative glomerulonephritis in Takayasu's arteritis. *Am J Nephrol* 1988;8:240-4.
- 11) Schroeder JO, Euler HH, Loffler H. Synchronization of plasmapheresis and pulse cyclophosphamide in severe systemic lupus erythematosus. *Ann Int Med* 1987;107:344-6.
- 12) Austin HA, Klippel JH, Balow JE. Therapy of lupus nephritis. *N Engl J Med* 1986;614-9.