

뇌지주막하 출혈 후 뇌혈관 연축에 대한 동맥내 Papaverine 주입의 치료효과

신준재 · 이재환 · 신용삼** · 허승곤 · 김동익* · 이규창

= Abstract =

Effect of the Intra-arterial Papaverine Infusion on the Symptomatic Cerebral Vasospasm after Aneurysmal Subarachnoid Hemorrhage

Jun Jae Shin, M.D., Jae Whan Lee, M.D., Yong Sam Shin, M.D.,**
Seung Kon Huh, M.D., Dong Ik Kim, M.D.,* Kyu Chang Lee, M.D.

Department of Neurosurgery and Diagnostic Radiology,* Yonsei University College of Medicine, Seoul, Korea
National Health Insurance Congress Ilsan Hospital,** Ilsan, Korea

Objective : To clarify the benefits and therapeutic effects of intra - arterial papaverine infusion on the symptomatic cerebral vasospasm, we analyzed the results of treatment in 32 patients retrospectively.

Methods : A total of 510 patients underwent surgical clipping or endovascular intra - aneurysmal treatment for ruptured intracranial aneurysm between May, 1996 and June, 1999. The delayed ischemic deficit(DID) was developed in 90 of 510 patients. Of these 90 patients, 32 developed symptomatic vasospasm inspite of using modest “3H therapy”. The brain CT scan was taken before the intra - arterial infusion of papaverine. The 32 patients underwent 42 intra - arterial papaverine infusion. The symptomatic vasospasm was divided into three groups : deterioration of mental status(Group 1), appearance of a focal neurologic deficit(Group 2), or both(Group 3). We measured Glasgow Coma Scale(GCS), arterial diameters, and cerebral circulation time(CCT) at the time of pre - and postangioplasty.

Results : The number of patients in group 1, 2 and 3 were 26, 7, 9 respectively. Eighteen cases showed improvement of GCS more than 2 scores, 16 more than 1, and 8 showed no change of GCS. Average cerebral circulation time(CCT) was decreased ranging from 0.0% - 67.5%, and arterial diameters were increased in 21 cases ranging from 1 to 4 folds.

Conclusion : Intra - arterial papaverine infusion seemed to have therapeutic effects on symptomatic vasospasm by improving the neurological signs and increasing the arterial diameter. We suggest that intra - arterial papaverine infusion would be an useful adjunctive therapeutic modality in symptomatic vasospasm.

KEY WORDS : Subarachnoid hemorrhage · Symptomatic vasospasm · Intra - arterial papaverine infusion.

서 론

4~9 70%
, 20~30% (sy-
mptomatic vasospam) 13).

(angiographic vasospasm)

“3H therapy(, , 가; hyper-

Papaverine

volemia, hemodilution, hypertension) ”
6)

가

column)

(lateral margin)

soft lead pencil

, 1984 Zubkov
(transluminal angioplasty)
5)

23) 1990

50%,

50%

25%

25~

50%

papaverine

11)12)

(supraclinoid)

A1,

papaverine

M1, P1

A2, A3, M2, M3, angular,

15)

가

P2, P3

papaverine

(nonionic

,

,

,

가

contrast)

(bias)

가

(blinded manner)

papaverine

가

대상 및 방법

papaverine

(cerebral circulation time)

1956 Greitz

1996 3

1999 6

(GDC)

(maximum opacification)

(pa-

510

rietal vein)

(delayed ischemic deficit)

90

10)

“3H therapy”

(parietal cortical vein) 가

32

32

42

papaverine

frame

9)

(digital subtraction ang-

iography ; DSA)

(arterial phase)

(Table 1).

4frame/sec,

(capillary phase)

2frame/sec,

(venous phase)

1frame/

sec

(absolute cerebral circulation time)

(change

percentage)

25%

(transcranial Doppler, TCD)

“3H

, 25~50%

, 50%

therapy”

(Ca⁺⁺ channel blocker)

가

papaverine

papaverine

papaverine 100mg~300mg

100

0.2mm

ml

30 1

가 midarterial image

(contrast

papaverine

0.1%(100mg in 100ml)

Table 1. Clinical summary of 42 cases treated with intra-arterial infusion of papaverine

Case No.	Age (yrs), Sex	Location of Aneurysm	Hunt-Hess Grade*	Fisher Group SAH to Angioplasty***	Interval from papaverine	Delayed Ischemic Deficit (DID)	Dose (mg)**	GCS score Before papaverine	After	Vessels in Spasm	Increase rate of Diameter	CCT Decrease rate
1	64, F	ANCOM	3	3	9		300	8	9	50% prox	0	10%
2	40, F	ICPCOM, Rt	3	3	6	(Lt G1 G4)	300	7	10	20% int	25%	40%
3	40, F	ICPCOM, Rt	3	3	6	(Lt G2)	300	7	10	50% dist	50%	56.5%
4	40, F	ICPCOM, Rt	3	3	6		300	10	10	50% dist	0	37.7%
5	55, F	ICPCOM, Lt	2	2	6	(Rt G4- G4+)	120	11	12	29% dist	0	17.5%
6	56, F	ANCOM	3	3	12	(Lt G4- G40)	250	11	11	80% dist	300%	37%
7	53, M	ICdist, Rt	2	3	3	(Lt G1 G3)	210	11	12	25% dist	0	0
8	48, F	MCBIF, Lt	2	3	5	(Rt G2)	150	11	11	25% dist	0	0
9	41, F	ICBIF, Lt	3	3	9	(Rt G3)	210	11	12	50% dist	66.7%	14.9%
10	49, F	MCBIF, Rt	4	3	11		200	8	11	50% dist	0	50%
11	50, F	ICPCOM, Rt	5	3	6	(Lt G2 G3)	300	8	10	40% dist	0	67.5%
12	50, F	ICPCOM, Rt	5	3	8		300	8	10	40% dist	0	0
13	63, F	ANCOM	4	4	7		200	8	9	44% dist	25%	41.3%
14	63, F	ANCOM	4	4	9		200	8	9	44% dist	0	51.1%
15	54, F	A2, Rt	3	3	6		100	11	12	47% prox	0	- 9%
16	75, M	MCBIF, Lt	3	3	5		220	10	10	17% int	- 10%	5%
17	41, M	ANCOM	3	3	19	(Rt G3 G4 -)	300	10	12	20% int	0	14.3%
18	32, M	ANCOM	5	4	4		150	6	9	50% dist	0	17.8%
19	55, F	A1, Lt	4	3	4	(Rt G0 G2)	300	8	10	44% dist	50%	5%
20	55, F	A1, Lt	4	3	11		300	8	10	77% dist	200%	8.5%
21	52, M	ANCOM	2	3	7		230	11	12	88% int	300%	50%
22	47, M	ANCOM	2	2	7		100	11	12	50% dist	50%	20%
23	48, F	ICPCOM, Rt	4	3	14	(Lt G3 G4)	150	9	9	56% dist	25%	0
24	48, F	ICPCOM, Rt	4	3	15		250	9	9	67% int	33.3%	28.3%
25	48, M	ANCOM	3	3	12		150	11	12	50% dist	100%	35.1%
26	55, M	ANCOM	4	3	2		200	11	12	50% prox	0	11.3%
27	47, M	MCBIF, Rt	2	3	9		150	10	12	67% dist	0	59.7%
28	46, M	IC-opth, Lt	2	2	7		300	8	12	17% int	20%	16.7%
29	59, M	ANCOM	3	4	3	(Lt G3 G4)	300	8	10	63% int	0	0
30	44, M	ICCHO, Rt	4	3	8	(Lt G3 G4)	300	8	11	75% dist	200%	14%
31	44, M	ICCHO, Rt	4	3	11		300	8	11	50% dist	50%	14%
32	76, F	ICPCOM, Rt	3	3	7		150	6	6	0	0	30%
33	38, M	ANCOM	4	4	6		300	8	9	50% int	33.3%	33.3%
34	38, M	ANCOM	4	4	9		300	8	9	50% dist	100%	9.1%
35	38, M	ANCOM	4	4	11		300	8	9	50% dist	66.7%	9.1%
36	58, M	ANCOM	5	3	8		200	8	9	25% dist	0	12.5%
37	51, M	MCBIF, Rt	1	2	14		200	9	11	43% prox	25%	35.6%
38	55, F	ANCOM	4	3	3		300	7	10	25% int	0	11.1%
39	23, M	primary SAH	4	3	8	(Lt G0 G4)	300	10	12	0	0	12.5%
40	23, M	primary SAH	4	3	8	(Lt G0 G4)	300	10	12	0	0	12.5%
41	43, F	IC2-3, Lt	3	3	5	(Lt G2)	300	12	12	25% int	33.3%	- 12.5%
42	70, F	MCBIF, Lt	3	3	5		200	10	11	44% int	25%	41.4%

ANCOM : anterior communicating cerebral artery, MCA : middle cerebral artery, MCBIF : middle cerebral bifurcation artery, ICdist : internal cerebral distal artery, ICPCOM : posterior communicating artery, A1, A2, IC2-3 : segments of the anterior cerebral artery, and internal cerebral artery, respectively, IC-opth : internal cerebral-ophthalmic artery, ICCHO : internal cerebral-anterior choroidal artery, primary SAH : primary subarachnoid hemorrhage, *Hunt and Hess grade, **Glasgow Coma Scale score, *** SAH grouping according to Fisher, et al, CCT : cerebral circulation time

Papaverine

0.3%(300mg in 100ml) 가 140~ 150mmHg . 22 , 21 (superselection) papaverine GCS 4~15 . Papa- verine GCS 가 2 가 16 , GCS 가 18 , 1 가 8 Papaverine GCS가 가 가 8 12 4 가 가 . 7 , papaverine Glas- 15 , 21 . 21 , 2 papaverine 가 가 2 , papaverine 가 4 , 가 15 2 , 3 papaverine . Papaverine 가 25% () 가 6 , 25~50%() 가 7 , 50% () 가 8 . 400% 가 . , 42 21 (50%) 가 (Fig. 1).

결 과

32 papaverine (cerebral circulation time) 42 papaverine 16 , 16 , 49.8 Fisher 6.98sec 6.19sec group 가 4 , 가 24 , 가 4 , 11 , 가 1 , 15 , 6 , (, papaverine 4.78sec . 25% () 가 19 , 25~50%() 가 10 , 50% () 가 6 . 2 가 22.7% , 67.1% 5 , “3H therapy”

(refractory vasospasm)

고 찰

papaverine 2 19 Papaverine opioid (bensylisoquinoline opium alkaloid) cyclic adenosine monophosphate(c- AMP) cyclic guanosine 3,5 monophosphate(c -GMP) phosphodiesterase 18) , 0.1%(100mg) (239mg). 가 26 , c - AMP c -GMP 가 27) . 0.3%(300mg) 가 (가 7 , 16 12 가 9 .

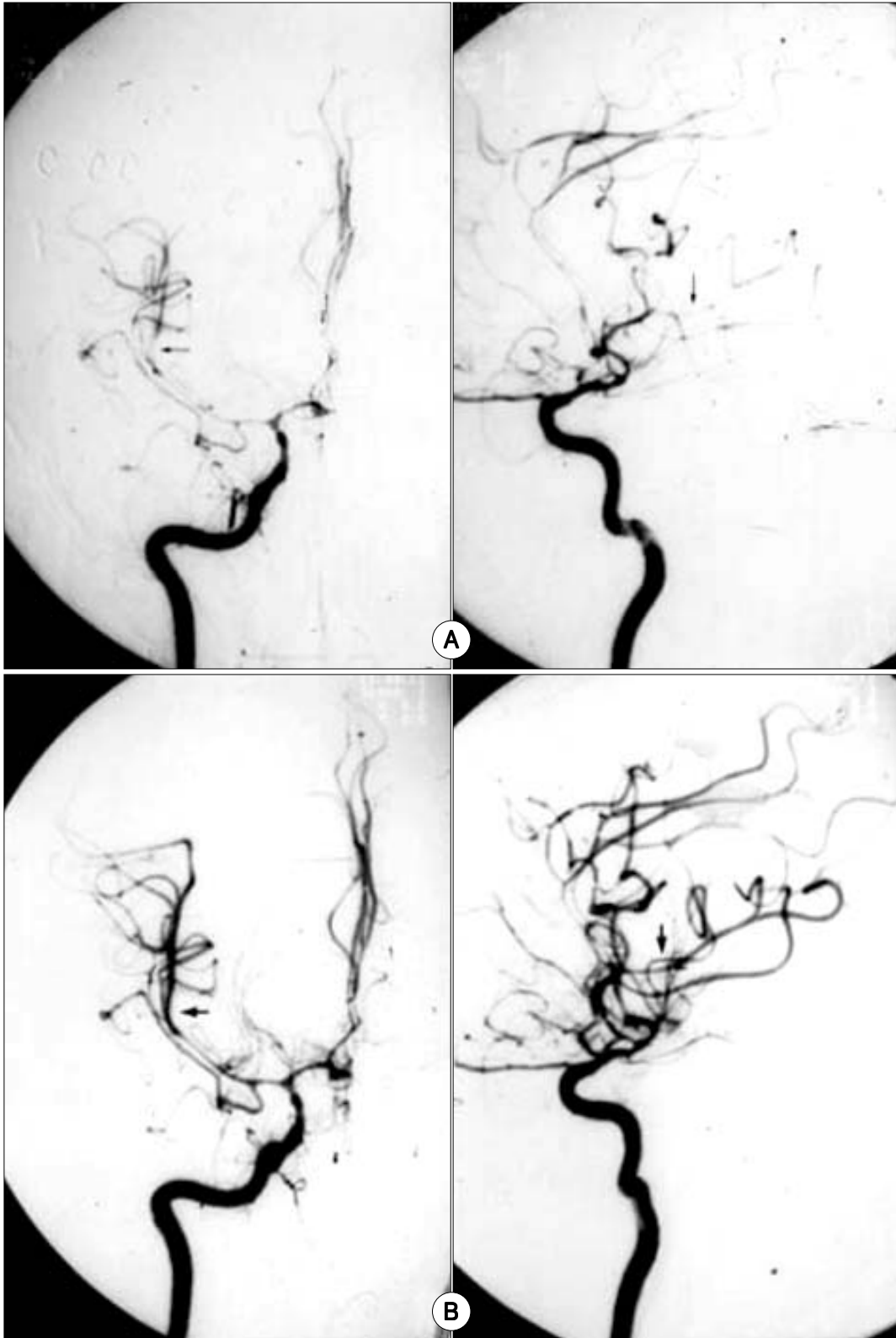


Fig. 1. A : 38-year-old man presented with acute deterioration of the level of consciousness 7 days after rupture of anterior communicating artery aneurysm.
 A : Demonstrates marked vasospasm, especially in right M2 with poor distal opacification (arrow). B : After infusion of 300mg of papaverine into the supraclinoid carotid artery, the right M2 segments showed marked dilatation (large arrow). Consciousness level was improved after the papaverine.

Papaverine

Nitroso (ischemic penumbra)

가 , papaverine (intrathecal) 가 papaverine (cistern) 가 papaverine 가 papaverine 2). Vorkapic 28), Macdonald 16), Mathis 18) papaverine Fujiwara 7) 가 papaverine 1992 Kaku 11) 가 papaverine 10 37 papaverine , Kaku 34% , 10 “3H therapy” 8 2 12 Kassell 12 papaverine rine 3 GCS 2 Clouston 3) 23). TCD 가 papaverine Yoshimura 29) Kinoshita 가 19) papaverine 0.2~0.3% 24), 가 25)27). papaverine (evaluation papaverine 300mg 600mg criteria) 가 papaverine 2). Mathis papaverine 0.3% 18), 가 . 42 34 (micro - emboli) 가 42 Yoshimura 0.8% papaverine 37 (88%) , 6 pa- 29). paverine 2 , 2 3 100~300mg papaverine(239mg) 100ml 40 60 papaverine 가 가 0.8 가 가 (actual effective half - life) 100~220mg 가 가 18). 4 papaverine , 0.3% papaverine 2)12). 가 가 2 , 3 . , papaverine (cerebral circulation time ; CCT) 1956 Greitz (carotid si- phon) (maximum opacification)

(parietal vein)⁹⁾

(parietal cortical vein) 가
 . Gado⁸⁾ C¹⁵O가
 (cerebral blood volume ; CBV),
 (cerebral blood flow ; CBF),
 (mean transit time) , 34
 (cerebral blood volume ; CBV)/
 (cerebral blood flow ; CBF) . ,
 (cerebral blood volume ; CBV)
 (cerebral circulation time ; CCT) (cerebral
 blood flow ; CBF) . Papa-
 verine (CBV)
 가 , (CCT)
 (CBF) 가 .)

(PaCO₂) (PaO₂)
 papaverine 18 2
 30 1 (pulse oxy- 16 1
 meter) , (PaCO₂) 9
 (PaO₂) GCS가 3

1956 Greitz
 Triurol contrast agent (ce-
 rebral circulation time) 4.13 ± 0.78sec
⁹⁾ Leeds Teveras¹³⁾ Hypaque
 (cerebral circulation time) 4.37
 ± 0.83sec , Greitz Urografin
 3.43 ± 0.51sec
²⁰⁾ Milburn 59
 6.8 ± 1.1sec
 , papaverine
 6.1 ± 1.2sec, papaverine 가
 3.8 ± 0.8sec , 58
²⁰⁾
 Visipaque nonionic contrast
 6.98sec .

papaverine
 6.19sec, papaverine
 4.78sec .
 papaverine

papaverine

(cerebral blood flow)
 papaverine
 가 ,
 가 42
 (88%) papaverine
 papaverine
 (TCD)
 , ,
 ,
 ,⁶⁾
 ()
 papaverine
 GCS ,
 ,
 ,
 papaverine 가
 GCS가 3
 .
 (refractory vasospasm)
 가
 GCS 가
 (ophthalmic artery)
 (vertebral artery)
 papaverine ,
 가
¹¹⁾ Numaguchi
 , papaverine 가
 가
²⁵⁾
 papaverine
 (A1 - ACA)
 ,
 papaverine ,

(ophthalmic artery)
papaverine
Kaku , Kassell , Livingston
(balloon angioplasty)
4)15)30), (micro-
catheter)가
(percutaneous transluminal angioplasty ; PTA)

papaverine 가
5)11)
,
11)12)14)16)22)
Hendrix 10) papaverine
(ophthalmic artery) 가
(mydriasis) (vertebrobasilar
infusion)

papaverine
(monocular blindness) 1)22)
Barr 1) (paradoxical artery con-
striction) (hyperemia), (crystal
precipitation) (thrombocyto-
penia), (tonic - clonic seizure),
(psychomotor depression) 17)21)

papaverine
papaverine
(tachypnea) 1
(paradoxical artery constriction)
24). papaverine
(hyperemia)

가
가
papaverine
가
papaverine
가

- : 2000 7 18
 - : 2000 9 14
 - :
- 120 - 752 134
- : 02) 361 - 5621, 6201, : 02) 393 - 9979
E - mail : leekc@yumc.yonsei.ac.kr

References

- 1) Barr JD, Mathis JM, Horton JA : *Transient severe brainstem depression during intra-arterial papaverine infusion for cerebral vasospasm. AJNR 15 : 719-723, 1994*
- 2) Cook P, James I : *Cerebral vasodilators. N Engl J Med 305 : 1508-1513, 1981*
- 3) Clouston JE, Numaguchi Y, Zoarski GH, Aldrich EF, Simard JM, Zitnay KM : *Intracranial papaverine infusion for cerebral vasospasm after subarachnoid hemorrhage. AJNR 16 : 27-38, 1995*
- 4) Elliott JP, Newell DW, Lam DJ, Eskridge JM, Douville CM, Le Roux PD, et al : *Comparison of balloon angioplasty and papaverine infusion for the treatment of vasospasm following aneurysmal subarachnoid hemorrhage. J Neurosurg 88 (2) : 277-284, 1998*
- 5) Eskridge JM, Song JK : *A practical approach to the treatment of vasospasm. AJNR 18 : 1653-1660, 1997*
- 6) Findlay JM, Macdonald RL, Weir BKA : *Current concepts of pathophysiology and management of cerebral vasospasm following aneurysmal subarachnoid hemorrhage. Cerebrovasc Brain Metab Rev 3 : 336-361, 1991*
- 7) Fujiwara N, Honjo Y, Ohkawa M, Tanobe M, Irie K, Nagao S : *Intra-arterial infusion of papaverine in experimental cerebral vasospasm. AJNR 18 : 255-262, 1997*
- 8) Gado M, Eichling J, Grubb R, Phelps M, Raichle M, Ter-Pogossian MM : *Appraisal of the angiographic circulation time as an index of cerebral blood flow. Radiology 115 : 107-112, 1975*
- 9) Greitz T : *A radiologic study of the brain circulation by rapid serial angiography of the carotid artery. Acta Radiol Suppl 140 : 1-123, 1956*
- 10) Hendrix LE, Dion JE, Jensen ME, Phillips CD, Newman SA : *Papaverine-induced mydriasis. AJNR 15 : 716-718, 1994*
- 11) Kaku Y, Yonekawa Y, Tsukabara T, Kazekawa K : *Superselective intra-arterial infusion of papaverine for the treatment of cerebral vasospasm after subarachnoid hemorrhage. J Neurosurg 77 : 842-847, 1992*
- 12) Kassell NF, Helm G, Simmons N, Phillips CD, Cail WS : *Treatment of cerebral vasospasm with intra-arterial papaverine. J Neurosurg 77 : 848-852, 1992*
- 13) Leeds NE, Taveras JM : *Changes in local circulation time in frontal and parietal tumours studied by rapid serial angiography. Acta Radiol (Diagn) 1 : 332-342, 1963*

- 14) Linskey ME, Horton JA, Rao GR, Yonas H : *Fatal rupture of the intracranial carotid artery during transluminal angioplasty for vasospasm induced by subarachnoid hemorrhage. J Neurosurg* 74 : 985-990, 1991
- 15) Livingston K, Hopkins LN : *Intra-arterial papaverine as an adjunct to transluminal angioplasty for vasospasm induced by subarachnoid hemorrhage. AJNR* 14 : 346-347, 1993
- 16) Macdonald RL, Zhang J, Sima B, Johns L : *Papaverine sensitive vasospasm and arterial contractility and compliance after subarachnoid hemorrhage in dogs. Neurosurgery* 37 : 962-968, 1995
- 17) Marks MP, Steinberg GK, Lane B : *Intra-arterial papaverine for the treatment of vasospasm. AJNR* 14 : 822-826, 1993
- 18) Mathis JM, Jensen ME, Dion JE : *Technical considerations on intra-arterial papaverine hydrochloride for cerebral vasospasm. Neuroradiol* 39 (2) : 90-98, 1997
- 19) Milburn JM, Moran CJ, Cross DT III, Diringner MN, Pilgram TK, Dacey RG Jr : *Effect of intra-arterial papaverine on cerebral circulation time. AJNR* 18 : 1081-1085, 1997
- 20) Milburn JM, Moran CJ, Cross DT III, Diringner MN, Pilgram TK, Dacey RG Jr : *Increase in diameters of vasospastic intracranial arteries by intra-arterial papaverine administration. J Neurosurg* 88 : 38-42, 1998
- 21) Miller JA, Cross DT, Moran CJ, Dacey RG, McFarland JG, Kiringer MN : *Severe thrombocytopenia following intra-arterial papaverine for the treatment of vasospasm. J Neurosurg* 83 : 435-437, 1995
- 22) McAuliffe W, Townsend M, Eskridge JM, Newell DW, Grady MS, Winn HR : *Intracranial pressure changes induced during papaverine infusion for treatment of vasospasm. J Neurosurg* 83 : 430-434, 1995
- 23) Newell DW, Eskridge JM, Mayberg MR, Grady MS, Lewis D, Winn HR : *Angioplasty for the treatment of symptomatic vasospasm following subarachnoid hemorrhage. J Neurosurg* 71 : 654-660, 1989
- 24) Numaguchi Y, Zoarski GH : *Intra-arterial papaverine treatment for cerebral vasospasm our experience and review of the literature. Neurol Med Chir* 38 (4) : 189-195, 1998
- 25) Park SJ, Choi CH : *The effect of intra-arterial papaverine injection in cerebral vasospasm : Kor J Cerebrovascular Disease* 2 (1) : 30-37, 2000
- 26) Polin RS, Hansen CA, German P, Chaddock JB, Kassell NF : *Intra-arterially administered papaverine for the treatment of symptomatic cerebral vasospasm. Neurosurg* 42 (6) : 1256-1267, 1998
- 27) Lee KC, Park HS, Huh SK, Shin YS, Kim DI, Chung SK, et al : *Development of protocol for the management of patients with delayed ischemic deficits following rupture of cerebral aneurysm : A prospective study. J Kor Neurosurg Soc* 26 : 1527-1536, 1997
- 28) Vorkapic P, Bevan RD, Bevan JA : *Longitudinal time course of reversible and irreversible components of chronic cerebrovasospasm of the rabbit basilar artery. J Neurosurg* 74 : 951-955, 1991
- 29) Yoshimura S, Hashimoto N, Goto Y, Sempei K, Takahara T, Iihara K : *Intra-arterial infusion of high concentration papaverine damages cerebral arteries in rats. AJNR* 17 : 1891-1894, 1996
- 30) Zubkov YI, Nikiforov BM, Shustin VA : *Balloon catheter technique for dilatation of constricted cerebral arteries after aneurysmal subarachnoid hemorrhage. Acta Neurochir* 70 : 65-79, 1984