

심근조영심초음파

임 세 중

Myocardial Contrast Echocardiography

Se-Joong Rim, MD

Cardiology Division, Department of Internal Medicine, Yonsei University College of Medicine, Seoul, Korea

(microbubble)가 sonicated albumin 가
 (mechanical index) 가
 가 (backscatter) 가
 가 Levovist®가
 가 , 가 ,
 가 가
 가 (perfusion) 가 가
 가 가 가

심근조영심초음파(MCE)의 발전

har-har-
 , 가 가가 . monic frequency .
 . 가 .¹⁾ power Doppler pulse inversion 가
 가 . air - filled soni-
 cated radio - opaque contrast dye air - filled ultrasound beam .²⁾
 : , 120 - 752 134 mechanical
 : (02) 361 - 7071 . : (02) 393 - 2041 index
 E - mail : sejoong@yumc.yonsei.ac.kr 가

임상적 응용

혈류의 측정(Quantification of coronary blood flow)

MCE

videointensity가 1 (linear relationship)

가, ³⁾ MRI CT

mechanical index 가

가 (Fig. 1).

videointensity 0 가

가 destruction - refilling time - intensity curve

⁴⁾ , time - intensity data

$$y = A(1 - e^{-\beta t})$$

y ; videointensity

t ; time

A ; peak videointensity

β ; rate constant of rise in videointensity

peak intensity " A " (blood volume)

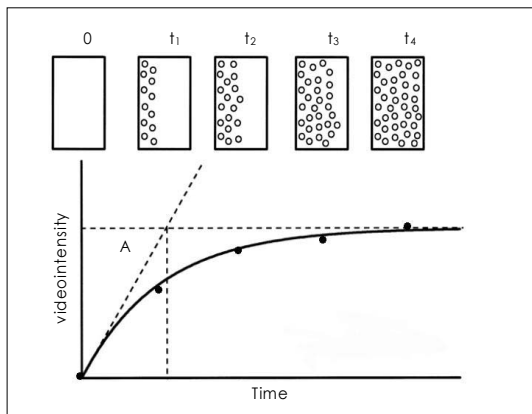


Fig. 1. Refilling of microbubbles in ultrasound imaging plane after destruction using high power-ultrasound. Lower panel shows corresponding time-intensity curve.

⁵⁾ " β "

" β "

가

$A \times \beta$ 가

가

⁶⁾⁷⁾

, ⁸⁾ ,

급성 흉통환자에서 심근관류의 평가(Myocardial perfusion in acute coronary syndrome)

가

가

MCE

risk area

⁹⁻¹¹⁾ risk area

가

MCE

risk area

. Risk area

risk area

MCE

¹²⁾¹³⁾

가

risk area

가

MCE

(myocardial viability)가

¹⁴⁾

, MCE

가

가

¹⁵⁾

direct PTCA

sonicated radio - opaque dye

관상동맥질환의 진단(Myocardial perfusion in suspicious coronary artery disease)

MCE

pharmaco-

logical stress

peak

videointensity

, myocardial blood volume

¹⁶⁾

가

¹⁷⁾¹⁸⁾

time - intensity curve

(β)

MCE가

최신 연구동향

가 , protocol
 가 ,
 가 ,
 19)20)
 21)22)
 23)24)
 25)
 결론
 MCE가
 (myocardial per-
 fusion) 가
 MCE

REFERENCES

- 1) Burns PN, Powers JE, Simpson DH, Uhlenhof V, Fritzsche T. *Harmonic imaging: principles and preliminary results. Clin Radiol* 1996;51 (suppl 1):50-5.
- 2) Porter TR, Xie F. *Transient myocardial contrast after initial exposure to diagnostic ultrasound pressures with minute doses of intravenously injected microbubbles: demonstration and potential mechanisms. Circulation* 1995; 92:2391-5.
- 3) Skyba DM, Jayaweera AR, Goodman NC, Ismail S, Camarano GP, Kaul S. *Quantification of myocardial perfusion with myocardial contrast echocardiography from left atrial injection of contrast: implications for venous injection. Circulation* 1994;90:1513-21.
- 4) Wei K, Jayaweera AR, Firoozan S, Linka A, Skyba DM,

- Kaul S. *Quantification of myocardial blood flow with ultrasound-induced destruction of microbubbles administered as a constant venous infusion. Circulation* 1998;97:473-83.
- 5) Kaul S, Jayaweera AR. *Coronary and myocardial blood volumes: noninvasive tools to assess the coronary microcirculation? Circulation* 1997;96:719-24.
- 6) Keller MW, Segal SS, Kaul S, Duling B. *The behavior of sonicated albumin microbubbles within the microcirculation: A basis for their use during myocardial contrast echocardiography. Circ Res* 1989;65:458-67.
- 7) Jayaweera AR, Edwards N, Glasheen WP, Villanueva FS, Abbott RD, Kaul S. *In vivo myocardial kinetics of air-filled albumin microbubbles during myocardial contrast echocardiography: comparison with radiolabeled red blood cells. Circ Res* 1994;74:1157-65.
- 8) Wei K, Le E, Bin JP, Coggins M, Thorpe J, Kaul S. *Quantification of renal blood flow with contrast-enhanced ultrasound. J Am Coll Cardiol* 2001;37:1135-40.
- 9) Kemper AJ, O'Boyle JE, Cohen CA, Taylor A, Parisi AF. *Hydrogen peroxide contrast echocardiography: quantification in vivo of myocardial risk area during coronary occlusion and the necrotic area remaining after myocardial reperfusion. Circulation* 1984;70:309-17.
- 10) Villanueva FS, Glasheen WP, Sklenar J, Kaul S. *Assessment of risk area during coronary occlusion and infarct size after reperfusion with myocardial contrast echocardiography using left and right atrial injections of contrast. Circulation* 1993;88:596-604.
- 11) Firschke C, Camarano G, Lindner JR, Wei K, Goodman NC, Kaul S. *Myocardial perfusion imaging in the setting of coronary artery stenosis and acute myocardial infarction using venous injection of FS-069, a second-generation echocardiographic contrast agent. Circulation* 1997;96: 959-67.
- 12) Sabia PJ, Powers ER, Ragosta M, Sarembock IJ, Burwell LR, Kaul S. *An association between collateral blood flow and myocardial viability in patients with recent myocardial infarction. N Engl J Med* 1992;372:1825-31.
- 13) Sabia PJ, Powers ER, Jayaweera AR, Ragosta M, Kaul S. *Functional significance of collateral blood flow in patients with recent acute myocardial infarction: A study using myocardial contrast echocardiography. Circulation* 1992;85:2080-9.
- 14) Ito H, Tomooka T, Sakai N, Yu H, Higashino Y, Fujii K, Masuyama T, Kitabatake A, Minamino T. *Lack of myocardial perfusion immediately after successful thrombolysis: A predictor of poor recovery of left ventricular function in anterior myocardial infarction. Circulation* 1992;85: 1699-705.
- 15) Ragosta M, Camarano GP, Kaul S, Powers E, Sarembock IJ, Gimple LW. *Microvascular integrity indicates myocellular viability in patients with recent myocardial infarction: new insights using myocardial contrast echocardiography. Circulation* 1994;89:2562-9.
- 16) Lindner JR, Skyba DM, Goodman NC, Jayaweera AR, Kaul S. *Changes in myocardial blood volume with graded coronary stenosis: An experimental evaluation using myocardial contrast echocardiography. Am J Physiol* 1997; 272:H567-75.
- 17) Kaul S, Senior R, Dittrich H, Raval U, Khattar R, Lahiri A. *Detection of coronary artery disease using myocardial*

- contrast echocardiography: comparison with ^{99m}Tc-sestamibi single photon emission computed tomography. Circulation 1997;96:785-92.*
- 18) Porter TR, Li S, Kricsfeld D, Armbruster RW. *Detection of myocardial perfusion in multiple echocardiographic windows with one intravenous injection of microbubbles using transient response second harmonic imaging. J Am Coll Cardiol 1997;29:791-9.*
 - 19) Lindner JR, Dayton PA, Coggins MP, Ley K, Song J, Ferrara K, Kaul S. *Noninvasive imaging of inflammation by ultrasound detection of phagocytosed microbubbles. Circulation 2000;102:531-8.*
 - 20) Lindner JR, Song J, Xu F, Klivanov AL, Singbartl K, Ley K, Kaul S. *Noninvasive ultrasound imaging of inflammation using microbubbles targeted to activated leukocytes. Circulation 2000;102:2745-50.*
 - 21) Skyba DM, Price RJ, Linka AZ, Skalak TC, Kaul S. *Direct in vivo visualization of intravascular destruction of microbubbles by ultrasound and its local effects on tissue. Circulation 1998;98:290-3.*
 - 22) Price RJ, Skyba DM, Kaul S, Skalak TC. *Delivery of colloidal particles and red blood cells to tissue through microvessel ruptures created by targeted microbubble destruction with ultrasound. Circulation 1998;98:1264-7.*
 - 23) Mukherjee D, Wong J, Griffin B, Ellis SG, Porter T, Sen S, Thomas JD. *Ten-fold augmentation of endothelial up-take of vascular endothelial growth factor with ultrasound after systemic administration. J Am Coll Cardiol 2000; 35: 1678-86.*
 - 24) Shohet RV, Chen S, Zhou YT, Wang Z, Meidell RS, Unger RH, Grayburn PA. *Echocardiographic destruction of albumin microbubbles directs gene delivery to the myocardium. Circulation 2000;101:2554-6.*
 - 25) Birnbaum Y, Luo H, Nagai T, Fishbein MC, Peterson TM, Li S, Kricsfeld D, Porter TR, Siegel RJ. *Noninvasive in vivo clot dissolution without a thrombolytic drug: recanalization of thrombosed iliofemoral arteries by transcatheter ultrasound combined with intravenous infusion of microbubbles. Circulation 1998;97:130-4.*