

Generalized Nonconvulsive Status Epilepticus in Two Patients with End-Stage Renal Disease

Won-Seok Oh, M.D., Young-Dae Kim, M.D., Sang-Won Seo, M.D., Yong Jeong, M.D., Sun-Ah Park, M.D., Kyoung Heo, M.D., Byung-In Lee, M.D.

Department of Neurology, Yonsei University, College of Medicine

We report two patients of generalized nonconvulsive status epilepticus (GNSE) accompanied by end-stage renal disease. Both patients were presented with impaired responsiveness and behavioral abnormalities. Continuous generalized epileptiform discharges were noted on EEG. GNSEs of our patients were responsive to benzodiazepines clinically and electroencephalographically. And they were controlled by short-term antiepileptic treatment and improvement of uremic condition.

J Korean Neurol Assoc 19(5):533~536, 2001

Key Words : Nonconvulsive status epilepticus, Uremia, Electroencephalography

		13		1
	가			
		가		
1				
	가			
				가
2				
			" "	
1			180 mmHg,	100
52	가	mmHg		307
		mg/dl,	14 mg/dl,	5
가		mg/dl		
			2 Hz	
		가	(Fig. 1A).	lorazepam 4
		mg	가	가
			(Fig. 1B).	phenytoin
		10	가	
		20		

Manuscript received March 20, 2001.
 Accepted in final form May 11, 2001.
 * Address for correspondence
Kyoung Heo, M.D.
 Department of Neurology,
 Yonsei University, College of Medicine
 Sinchon-dong, Seodaemun-gu, Seoul, 120-752, Korea
 Tel : +82-2-361-5460 Fax : +82-2-393-0705
 E-mail : kheo@yumc.yonsei.ac.kr

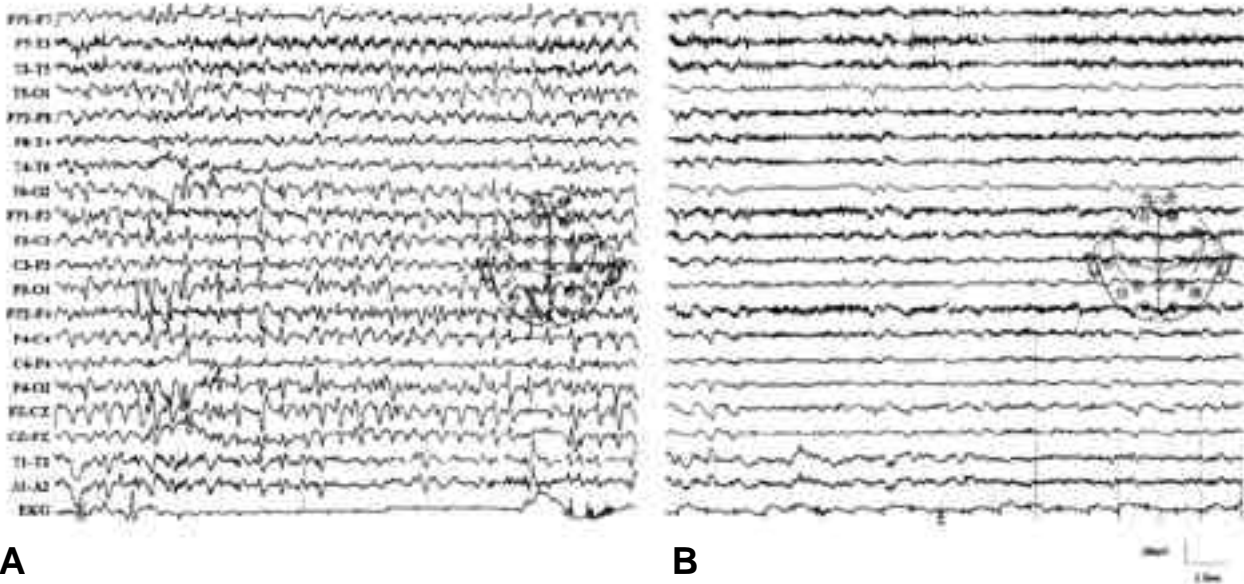


Figure 1. A. EEG tracing showing continuous generalized 2 Hz spike and slow waves. B. After administration of intravenous lorazepam, ictal EEG resolved.

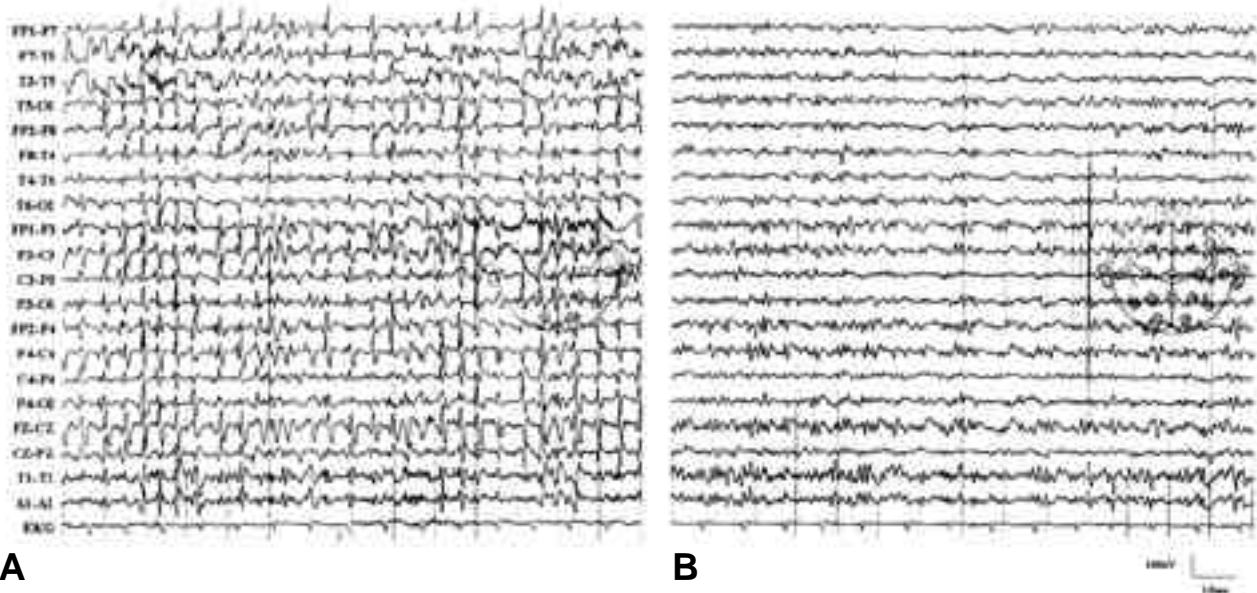


Figure 2. A. EEG tracing showing continuous generalized 2-3 Hz spike and slow waves. B. After administration of intravenous lorazepam, continuous generalized ictal discharges changed into fragmentary form.

2
70
3
가
lorazepam
lorazepam
phenytoin
“ ”

가 , 4)

71 mg/dl, 9.2 mg/dl 1
 (-13.5 mg/dl, - GNSE
 6.0 mg/dl)

2~3
 Hz 가 (Fig. 2A). GNSE , .⁵

lorazepam midazolam 가

가 (Fig. 2B) 가 ^{3,6} 가

GNSE

가 . Phenytoin valproate ⁵ NCSE가

가 5 가 가 GNSE 가 ⁸

NCSE

가 7 가

가 가

가 가

(nonconvulsive status epilepti-
 cus, NCSE) 가 30 GNSE
 가 GNSE

가 ³ GNSE

2 가 GNSE

1

가 GNSE

1

GNSE
 lorazepam mida-
 zolam 2 가 5 GNSE

가 2

NCSE 가

NCSE (partial
 nonconvulsive status epilepticus) 6 , 2 2 , 1

가 NCSE

(generalized nonconvulsive status epilepticus,
 GNSE) . GNSE 가 GNSE

Kaplan ³ 1) 가

3 Hz spike and waves가

, 2) 가 가

, 3)

REFERENCES

1. Kaplan PW. Assessing the Outcomes in patients with non-convulsive status epilepticus: nonconvulsive status epilep-

- ticus is underdiagnosed, potentially overtreated, and confounded by comorbidity. *J Clin Neurophysiol* 1999;16:341-352.
2. Delanty N, Vaughan CJ, French JA. Medical cause of seizures. *Lancet* 1998;352:383-390.
 3. Kaplan PW. Nonconvulsive status epilepticus. *Semin Neurol* 1996;16:33-40.
 4. Daly DD, Pedley TA. Current practice of clinical electroencephalography. 2nd Ed. *New York: Raven Press*, 1990; 374-377.
 5. Thomas P, Beaumanoir A, Genton P, Dolisi C, Chatel M. 'De novo' absence status epilepticus of late onset: report of 11 cases. *Neurology* 1992;42:104-110.
 6. Guberman A, Cantu-Reyna G, Stuss D, Broughton R. Nonconvulsive generalized status epilepticus: clinical features, neuropsychological testing, and long-term follow-up. *Neurology* 1986;36:1284-1291.
 7. Krumholz A, Sung GY, Fisher RS, Barry E, Bergey GK, Grattan LM. Complex partial status epilepticus accompanied by serious morbidity and mortality. *Neurology* 1995;45:1499-1504.
 8. Gokyigit A, Caliskan A. Diffuse spike-wave status of 9-year duration without behavioral change or intellectual decline. *Epilepsia* 1995;36:210-213.
 9. Litt B, Wityk RJ, Hertz SH, Mullen PD, Weiss H, Ryan DD et al. Nonconvulsive status epilepticus in the critically ill elderly. *Epilepsia* 1998;39:1194-1202.