

OPEN

# Overestimated Oncologic Significance of Lymph Node Metastasis in G1 Nonfunctioning Neuroendocrine Tumor in the Left Side of the Pancreas

Young Jin Yoo, Seok Jeong Yang, MD, Ho Kyoung Hwang, MD, Chang Moo Kang, MD, PhD, Hogeun Kim, MD, PhD, and Woo Jung Lee, MD, PhD

**Abstract:** Recent studies have expounded on the oncologic significance of lymph node metastasis in nonfunctioning (NF) neuroendocrine tumors (NETs) of the pancreas and suggest regional lymph node dissection for treating pancreatic NET. We tested this recommendation in NF pancreatic NET-G1, as these tumors are generally small and suitable for function-preserving minimally invasive pancreatectomy.

From January 2005 to December 2014, medical records of patients who underwent pancreatectomy for pathologically confirmed NF NET-G1 of the left side of the pancreas were retrospectively reviewed. Oncologic outcomes were compared between limited pancreatectomy and distal pancreateosplenectomy.

Thirty-five patients (14 males and 21 females) with a mean age of  $55.9 \pm 11.4$  years were enrolled in this study. Six patients (17.1%) underwent distal pancreateosplenectomy. Limited pancreatectomies comprised 15 spleen-preserving distal pancreatectomies (42.8%), 10 enucleations (28.6%), and 4 central pancreatectomies (11.4%). Lymph node metastasis was not found in 6 patients who underwent distal pancreatectomy with a splenectomy; meanwhile, the others were regarded as pNx since no lymph node retrieval was attempted during the limited pancreatectomy. Overall disease-free survival was 36.5 months (95% confidence interval [CI]: 25.9–47.1) and no tumor-related mortality was noted. Minimally invasive pancreatectomy ( $P=0.557$ ) and limited pancreatectomy ( $P=0.758$ ) showed no adverse impact in treating NF NET-G1 of the left side of the pancreas.

The oncologic significance of lymph node metastasis is overestimated in NF NET-G1 of the left side of the pancreas. Routine conventional distal pancreateosplenectomy to retrieve regional lymph nodes may be too excessive in treating NF NET-G1 of the distal pancreas.

(*Medicine* 94(36):e1404)

**Abbreviations:** CI = confidence interval, G = grade, NEC = neuroendocrine carcinoma, NET = neuroendocrine tumor, NF = nonfunctioning, Nx = regional lymph nodes cannot be assessed, pN = pathologic nodal status, PNET = pancreatic neuroendocrine tumor.

Editor: Isabella Reccia.

Received: May 2, 2015; revised: July 3, 2015; accepted: July 26, 2015. From the Department of Hepatobiliary and Pancreatic Surgery, Yonsei University College of Medicine (YJY, SJY, HKH, CMK, WJL); Department of Pathology, Yonsei University College of Medicine (HK); and Pancreaticobiliary Cancer Clinic, Yonsei Cancer Center, Severance Hospital, Seoul, Korea (SJY, HKH, CMK, HK, WJL).

Correspondence: Chang Moo Kang, Department of Surgery, Yonsei University College of Medicine, 50 Yonsei-ro, Seodaemun-gu, Seoul 120–752, Korea (e-mail: cmkang@yuhs.ac).

The authors have no funding and conflicts of interest to disclose.

Copyright © 2015 Wolters Kluwer Health, Inc. All rights reserved.

This is an open access article distributed under the Creative Commons Attribution License 4.0, which permits unrestricted use, distribution, and reproduction in any medium, provided the original work is properly cited. ISSN: 0025-7974

DOI: 10.1097/MD.0000000000001404

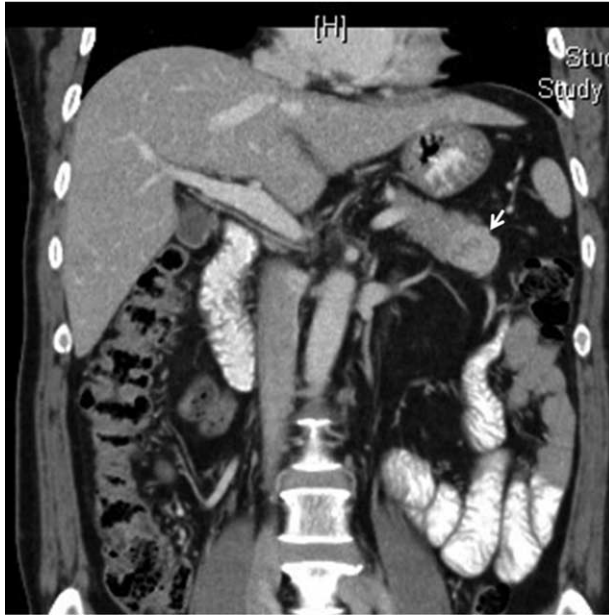## INTRODUCTION

There is some debate as to which surgical option is appropriate for treating a single nonfunctioning (NF) neuroendocrine tumor (NET) on the left side of the pancreas (as seen in Figure 1). Pancreatic NETs, known as islet cell tumors, are low grade malignant tumors that rarely occur, about 3% of all primary pancreatic neoplasms.<sup>1</sup> NETs are characterized as G1 or G2 NETs and neuroendocrine carcinomas (NEC, highly malignant).<sup>2</sup> In pancreatic NET, surgery is the primary treatment for localized tumors, and remains the treatment of choice for metastatic disease.<sup>3</sup> Thus far, surgery has proven to be the only curative treatment thereof, providing 5-year survival rates of 80% to 100% in resectable cases.<sup>4</sup>

Commonly, reports suggest that NF NET of the pancreas can be removed by minimally invasive approaches (robotic or laparoscopic) and by function-preserving limited pancreatectomy, such as enucleation, central pancreatectomy, and spleen-preserving pancreatectomy.<sup>5,6</sup> However, recent studies have shown that lymph node metastasis from NET varies in grade (G1, 15% to 20%; G2, 30% to 40%; G3, more than 50%)<sup>7</sup> and that metastasis to lymph nodes is a poor prognostic factor.<sup>8–10</sup> Therefore, regional lymph node dissection is strongly recommended in treating NET of the pancreas. Accordingly, this would mean that distal pancreateosplenectomy for lymph node retrieval would be appropriate in treating NF NET should it be found in the left side of the pancreas.

The reasons why we chose to investigate NF NET-G1 of the distal pancreas are as follows: First, greater use of more advanced imaging modalities has led to an increased incidence of asymptomatic NETs.<sup>11,12</sup> Second, most NF NETs are relatively small in size.<sup>7,13</sup> Third, NF NET-G1 shows quite good survival outcomes in long-term survival.<sup>7,14</sup> Considering that minimally invasive enucleation, spleen-preserving distal pancreatectomy, and central pancreatectomy are regarded as safe and effective treatment options to treat benign and low-grade malignant tumors, function-preserving and minimally invasive pancreatectomy could be ideal approaches for NF NET-G1 of the distal pancreas. Lastly, laparoscopic distal pancreatectomy is generally accepted as safe and effective. On the contrary, applications of laparoscopic pancreaticoduodenectomy are still debated, and its counterpart of limited pancreatectomy (ie, duodenum-preserving pancreatic head resection) is technically demanding.

Therefore, in this study, we focused specifically on NF NET-G1 of the left side of the pancreas, for which minimally invasive and limited pancreatectomy are suitable. We evaluated oncologic outcomes of NF NET-G1s of the left side of the pancreas according to clinicopathological factors, surgical approach, and extent of pancreatectomy to suggest the role of minimally invasive and function-preserving limited pancreatectomy in treatment thereof.



**FIGURE 1.** A 61-year-old male patient with NET of the left side of the pancreas (white arrow). He underwent laparoscopic spleen-preserving distal pancreatectomy. He was found to have no evidence of tumor recurrence after more than 70 months of postoperative follow-up. Pathologic diagnosis revealed a 3-cm NET-G1 with a Ki 67 index <1% and no mitosis. NET = neuroendocrine tumor.

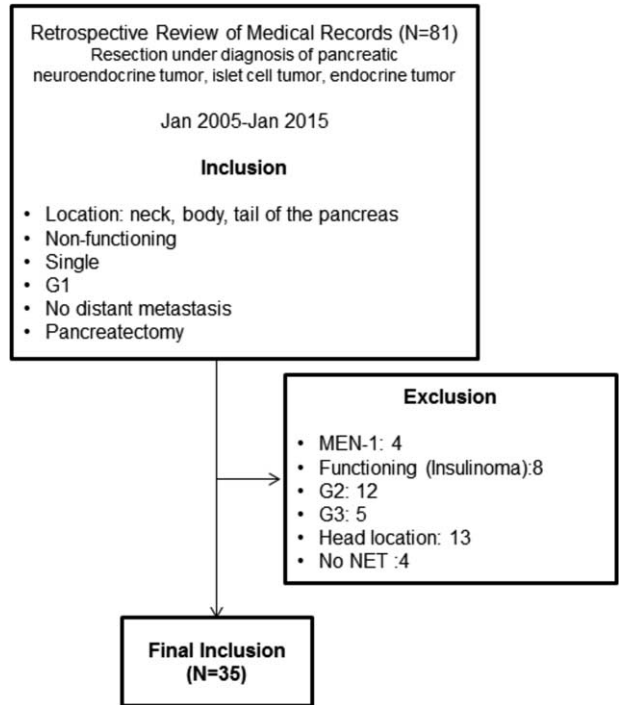
**METHODS**

This study was approved by our institutional review board, and informed consent was not required. From January 2005 to December 2014, the medical records of patients who underwent pancreatectomy for a pathological diagnosis of NET of the left side of the pancreas were retrospectively reviewed. Only patients fulfilling inclusion criteria were included in this study (criteria are shown in Table 1 and Figure 2). Clinicopathological variables, such as age, gender, symptom, radiologic tumor size, surgical procedures, grade, Ki-67 proliferative index, complications, recurrence, and disease-specific mortality, were checked. A specialized pathologist re-evaluated tumor grades

**TABLE 1.** Inclusion and Exclusion Criteria

<b>Inclusion criteria</b>	
Left-sided (neck, body, tail of the pancreas) nonfunctioning	
NET (G1)	
No distant metastasis	
Single tumor	
Patients with distal pancreateo-splenectomy (DPS), spleen-preserving DP (SpDP), enucleation, central pancreatectomy	
Open, laparoscopic, or robotic approach	
<b>Exclusion criteria</b>	
MEN/multiple NETs/functioning NETs	
G2, NEC (G3)	
Distant metastasis on preoperative image	

NEC = neuroendocrine carcinoma; NET = neuroendocrine tumor.

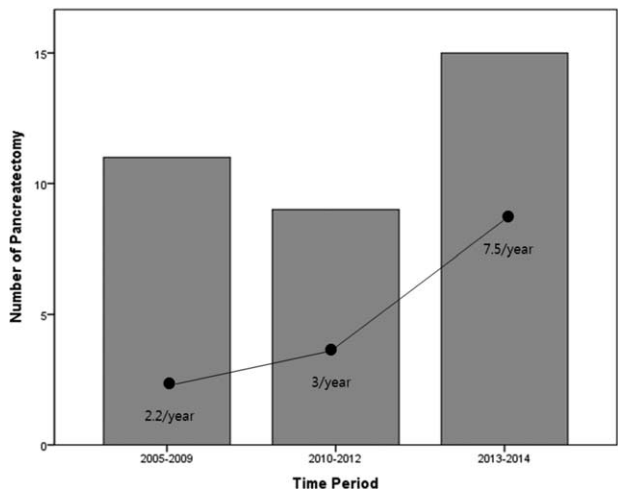


**FIGURE 2.** Diagram for study enrollment.

by performing Ki-67 staining and mitotic counts according to the World Health Organization (WHO) grading system for NET.<sup>9</sup> pN-stage was determined based on complete pathological examination of a conventional distal pancreatectomy. In cases of limited pancreatectomy, pN stage was regarded as pNx, because regional lymph nodes were not retrieved.

**Statistical Analyses**

Continuous variables are described as mean ± standard deviation, and categorical variables are described as frequencies (%). Student *t* test and chi-squared test or Fisher’s exact test



**FIGURE 3.** Incidence of pancreatectomy for NF NET-G1 of the left side of the pancreas. NET = neuroendocrine tumor; NF = nonfunctioning.

**TABLE 2.** Characteristics of Pancreatectomy to Treat G1 NF-NET of the Left-Sided Pancreas

	Pancreatectomy		Total
	Open	MIS	
EN	3	7	10
CP	1	3	4
SpDP	1	14	15
DPS	2	4	6
Total	7	28	35

CP = central pancreatectomy; DPS = distal pancreatectomy; EN = enucleation; MIS = Minimally invasive surgery; NET = neuroendocrine tumor; SpDP = spleen-preserving distal pancreatectomy.

were applied to compare continuous and categorical variables, respectively. Survival curves were estimated using the Kaplan–Meier method to calculate cumulative disease-free survival and disease-specific survival rates. Statistical analyses were performed using SPSS 20.0 for Windows (SPSS Inc., Chicago, IL). All *P* values < 0.05 were considered statistically significant.

**RESULTS**

**Patient Characteristics**

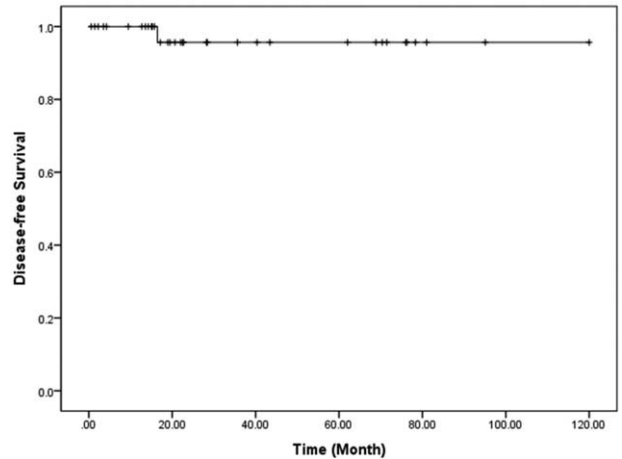
Throughout the study period, the incidence of pancreatectomy for NF NET-G1 of the pancreas increased (Figure 3). Thirty-five patients (14 males and 21 females), with a mean age of 55.9 ± 11.4 years, were identified with a pathologically confirmed diagnosis of grade 1 NF neuroendocrine (islet cell) tumor (NF NET-G1) of the left side of the pancreas. An incidental diagnosis was noted in most patients (29 out of 35 patients, 82.9%), and abdominal discomfort was the most common symptom. Five patients (14.3%) had NET in the neck portion of the pancreas, 17 (48.6%) in the body, and 13 (37.1%) in the tail, with a radiologic tumor size of 1.8 ± 0.9 cm. Tumors showed well demarcated margins, and there was no radiologic evidence of local tumor invasion.

Fifteen patients (42.8%) underwent spleen-preserving distal pancreatectomy, while distal pancreatectomy with splenectomy was performed in 6 patients (17.1%), enucleation in 10 patients (28.6%), and central pancreatectomy in 4 patients (11.4%, Table 2). Minimally invasive pancreatectomy was more frequently applied to treat NF NET-G1 of the distal pancreas

**TABLE 3.** Chronological Change of Surgical Mode to Treat G1 NF-NET of the Left-Sided Pancreas

		2005–2009	2010–2012	2013–2014	<i>P</i> Value
Surgical mode 1	MIS	7	6	15	0.025
	Open	4	3	0	
Surgical mode 2	LP	9	8	12	1.000
	DPS	2	1	3	

DPS = distal pancreatectomy; LP = limited pancreatectomy; NET = neuroendocrine tumor; NF = nonfunctioning.



**FIGURE 4.** Disease-free survival of resected NF NET-G1 of the left side of the pancreas. NET = neuroendocrine tumor; NF = nonfunctioning.

(*P* = 0.025); however, there was no difference in rate of limited pancreatectomy (*P* = 1.000, Table 3). Lymph node metastasis was not found in 6 patients with distal pancreatectomy with splenectomy; all others were regarded as Nx since lymph node retrieval was not attempted during limited pancreatectomy.

**Oncologic Outcomes Following Pancreatectomy for NF NET-G1 of the Left Side of the Pancreas**

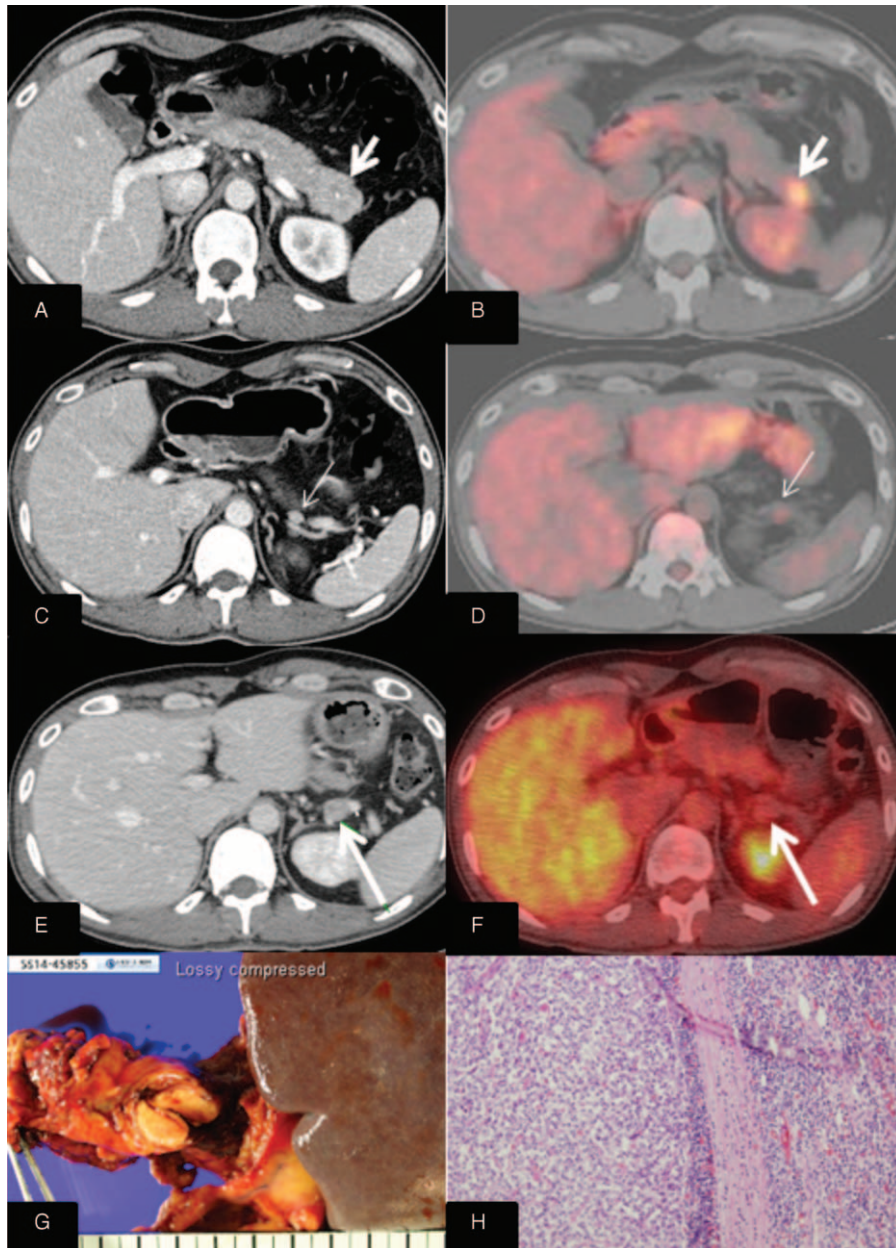
All patients were found to have margin-negative resection. During the follow-up period, a mean of 37.5 months (range, 0.6–120.0 months), disease-free survival was 36.5 months on average (95% confidence interval [CI]: 25.9–47.1) (Figure 4). Only 1 patient experienced local recurrence (Figure 5). Upon retrospective reevaluation of this recurrence, we noted suspicious regional lymph node metastasis before surgery (cN1) that was underestimated in the preoperative diagnostic stage. The patient subsequently underwent laparoscopic distal pancreatectomy with splenectomy. Pathologic examination of the lesion revealed NET-G1 lymph node metastasis. Excluding this patient, no systemic or local recurrence was noted. There was no disease-specific mortality during the follow-up period either.

**Oncologic Impact of Pathologic Characteristics and Limited Pancreatectomy in Resected NF NET-G1s of the Left Side of the Pancreas**

Radiologic tumor size (>2.5 cm) was closely associated with lymphovascular invasion (*P* = 0.014, Table 4). Disease-free survival was marginally significant according to lymphovascular invasion (*P* = 0.093, Figure 6). There was no significant survival differences between minimally invasive pancreatectomy and open pancreatectomy (*P* = 0.557, Figure 7A). In addition, no adverse oncologic impact of limited pancreatectomy was noted in treating NF NET-G1 of the left side of the pancreas (*P* = 0.758, Figure 7B).

**DISCUSSION**

Several studies suggest that regional lymph node metastasis is related to poor oncologic outcomes in treating NF NETs. Reporting on surgical outcomes for pancreatic NETs, Fisher



**FIGURE 5.** One case of recurrence following robotic spleen-preserving distal pancreatectomy.

et al<sup>7</sup> found grade 3, lymph node metastasis, and distant metastasis to be independent prognostic factors in patients with neuroendocrine neoplasms. Of note, they found that even small NET-G1s (median, 1.5 cm with range, 0.4–11 cm) accompanied lymph node metastasis in 16.7% of the patients (28 out of 168 patients). Hashim et al<sup>15</sup> observed that approximately 40% of their patients (50 out of 136 patients) had lymph node metastasis, which was associated with larger tumors, tumors of the pancreatic head, lymphovascular invasion, high Ki-67 (>20%), and poor disease-free survival. They concluded that regional lymphadenectomy should be included in patients undergoing pancreatic resection for pancreatic NETs. Tsutsumi et al<sup>16</sup> showed that NETs of more than 1.5 cm in size are

**TABLE 4.** Correlation Between Pathologic Characteristics and Radiologic Tumor Size

		Radiologic Tumor Size		P Value
		<2.5 cm	≥2.5 cm	
PNI	No	28	5	1.000
	Yes	2	0	
LVI	No	28	2	0.014
	Yes	2	3	

LVI = lymphovascular invasion; PNI = perineural invasion.

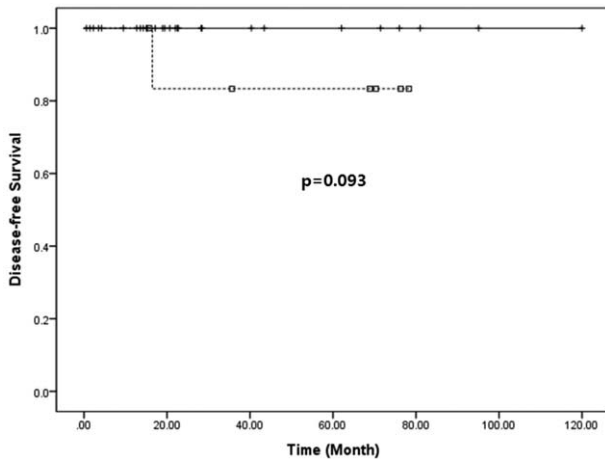


FIGURE 6. Survival differences according to lymphovascular invasion.

associated with a high incidence of lymph node metastasis (25%, 10 out of 40 patients), suggesting that lymph node dissection should be recommended in NETs larger than 1.5 cm. In resectable PNETs, Han et al<sup>17</sup> also found that CK-19 and KIT expression could predict clinical behavior, advanced stage, and regional lymph node metastasis.

Although important data support the adverse oncologic impact of lymph node metastasis and rationale for lymph node dissection, the proportion of NF NETs in these studies is limited,<sup>16</sup> and no subgroup analysis has focused on NF NET-G1.<sup>7,15,16</sup> In addition, none have attempted to delineate recurrence patterns.<sup>7,15</sup> In order to suggest the importance of lymph node dissection in NF-NET of the pancreas, it should be clearly shown that loco-regional recurrence is much higher in cases of omitting lymph node dissection. However, the literature does not support this expectation.<sup>18</sup> Recently, Tsutsumi et al<sup>19</sup> evaluated risk factors for recurrence after curative resection of well-differentiated pancreatic NET based on the new grading classification. While their univariate analysis demonstrated lymph node metastasis as a significant risk factor for tumor recurrence ( $P = 0.0004$ ), multivariate analysis did not (hazard ratio = 0.32 [95% CI: 0.01–7.98],  $P = 0.4948$ ). Brinbaum et al<sup>20</sup> also

investigated clinicopathological factors influencing survival of NET of the pancreas and showed that lymph node metastasis is not associated with poor disease-free survival (hazard ratio = 1.11 [95% CI: 0.57–2.16],  $P = 0.74$ ). Instead, they concluded synchronous liver metastasis (hazard ratio = 3.11 [95% CI: 1.15–8.39],  $P = 0.025$ ) and portal vein resection (hazard ratio = 15.8 [95% CI: 2.60–96.40],  $P = 0.002$ ) were found to be independent prognostic factors for predicting tumor recurrence. Moreover, Gratian et al<sup>21</sup> attempted to determine whether extent of surgery or lymph node dissection is associated with overall survival in 1854 patients with NF NETs <2 cm. Surprisingly, multivariate analysis demonstrated that type of surgery and lymphadenectomy were not associated with overall survival. Bilimoria et al<sup>22</sup> also performed an analysis of a large cohort of patients from the National Cancer Database (N = 3851). They observed lymph node metastasis in 1384 patients (52.8%); however, lymph node status did not impact survival in multivariate analysis (hazard ratio = 1.18 [95% CI: 0.96–1.45],  $P = 0.12$ ). These all suggest that the oncologic impact of regional lymph node metastasis is still debatable in NETs of the pancreas and put into question the rationale of routine regional lymph node dissection for treating NF-NET of the pancreas.

According to our results, excluding only 1 patient whose preoperative lymph node metastasis was underestimated on preoperative computed tomography scan, no patients with function-preserving limited pancreatectomy and minimally invasive pancreatectomy experienced tumor recurrence during the follow-up period (mean 37.5 months; range of 0.6–120.0 months). Partelli et al<sup>23</sup> investigated clinical predictors of lymph node involvement in NF NET of the pancreas. They concluded that NF NET-G1 has a very low risk of lymph node metastasis in the absence of radiological signs of node involvement. Therefore, careful preoperative radiologic evaluation for regional lymph node metastasis should be important in choosing surgical option for treating NF NET-G1 of the pancreas.

Our data further discredit the oncologic role of lymph node retrieval in NF NET-G1s of the left side of the pancreas. No survival difference between distal pancreatectomy and limited pancreatectomy (Nx-pancreatectomy) posits the following points: the incidence of lymph node metastasis in NF NET-G1s of the left side of the pancreas may be very low, and the oncologic impact of lymph node metastasis may be overestimated in NF NET-G1. In our data, Nx-pancreatectomy (limited

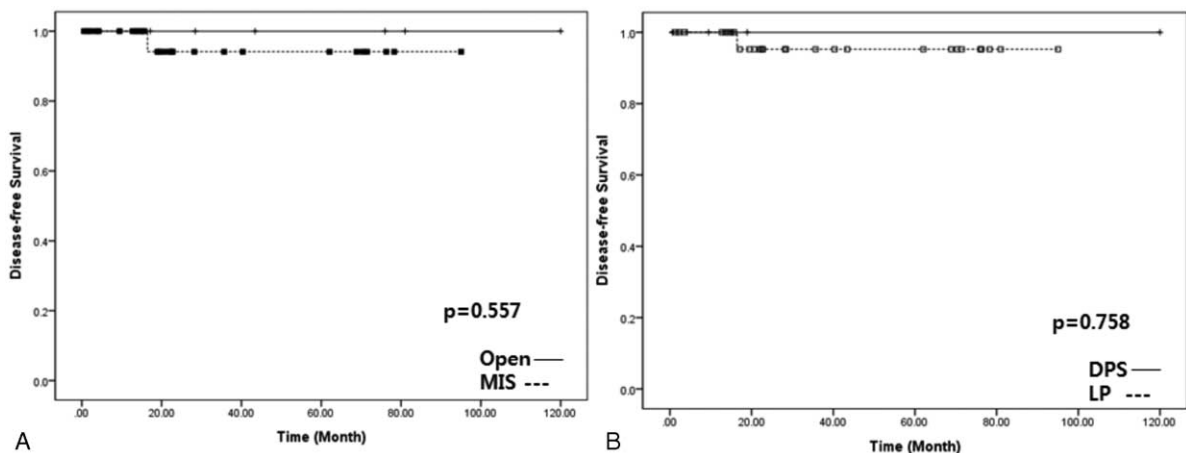


FIGURE 7. Oncologic impact of minimally invasive and limited pancreatectomy.

pancreatectomy) was undertaken in 29 patients (82.9%). During long-term follow-up, tumor recurrence was found in only 1 patient in whom lymph node metastasis was preoperatively underestimated. Interestingly, even the patient with regional lymph node metastasis (recurred case, Figure 5) showed a Ki-67 index of <1%, raising doubts about the oncologic impact of lymph node metastasis. In addition, presuming that lymph node dissection in NF NET-G1s plays a therapeutic role, it would be expected that oncologic outcomes for patients undergoing regional lymphadenectomy with lymph node metastasis would be similar to those for patients undergoing the same treatment without lymph node metastasis. However, as the literature suggests,<sup>21,22</sup> poor oncologic outcomes even after regional lymph node dissection suggest that lymph node metastasis is associated more with aggressive tumor biology than extent of treatment. Accordingly, the oncologic impact of lymph node metastasis may not be a correctable by regional lymph node dissection.

As an important practical issue, it is impossible to know exact histologic grades without pathological examination in treating NF NETs of the pancreas. However, thanks to advanced radiologic techniques, we may be able to predict not only the status of lymph node metastasis but also tumor grade in preoperative settings. Kim et al<sup>24</sup> reported that NET-G1 could be differentiated from NET-G2 or pancreatic NEC based on preoperative magnetic resonance imaging images. They demonstrated that NET-G2 and NEC exhibit specific findings, such as ill-defined borders ( $P=0.001$ ) and hypo-signal intensity on venous- and delayed-phase ( $P=0.016$ ), with high predictive value for discriminating NET-G1 from G2 ( $P=0.007$ ).

It is well known that most NF NET-G1s <2 cm are not eligible for surgery if they are asymptomatic and incidental. However, according to the 2010 WHO classification of tumors, even the smallest of tumors are given a cancer code.<sup>9</sup> Clinical guidelines for gastroenteropancreatic NETs in Japan indicate surgical resection should be performed even in tumors <2 cm in size.<sup>25</sup> Bettini et al<sup>26</sup> also reported that NF-NETs larger than 2 cm increased the chances of malignancy, and it was also suggested that tumors smaller than 1 cm in size could be malignant.<sup>27</sup> Gratian et al<sup>21</sup> further showed that 11% of tumors smaller than 0.5 cm exhibit distant metastasis. Accordingly, size is not an accurate predictor of malignancy. Nevertheless, although several studies have failed to reveal any association between tumor size and prognosis,<sup>28,29</sup> tumor size is thought to be an important clinical parameter in choosing between surgical modalities in treating NF NET of the pancreas. We previously reported that malignant behavior of NF NET of the pancreas is associated with tumor size  $\geq 3$  cm.<sup>30</sup> Our current observation showed that larger tumors (>2.5 cm) are marginally associated with tumor recurrence ( $P=0.075$ ) and lymphovascular invasion in NF NET-G1 of the left side of the pancreas ( $P=0.014$ ). Additionally, radiologic tumor size, with a cut-off value of 2.5 cm, predicted future tumor recurrence with 100% sensitivity and a false positive rate of 11.8% (data not shown), requiring future validation study in larger number of patients. All together, these suggest that routine lymph node dissection is not recommended and that lymph node dissection should be selected upon preoperative imaging. Tailor-made surgical approaches also need to be considered.

Based on our experiences and the following rationale, we concluded that the oncologic impact of lymph node metastasis in NF NET-G1 of the left side of the pancreas may be overestimated: Most NET-G1s are relatively small. Less frequent lymph node metastasis is noted in NF NET of the left side of the pancreas, especially in the absence of radiologic signs of node

involvement.<sup>23</sup> The oncologic impact of lymph node metastasis is still controversial.<sup>22,31</sup> Except for 1 patient with underestimated lymph node metastasis, no regional recurrence was noted even after limited pancreatectomy (current observation). Recent studies suggest that incidental pancreatic NETs are relatively small and nonaggressive<sup>32,33</sup>: small asymptomatic NETs usually exhibit minimal or no growth over many years; therefore, a nonoperative follow-up policy may be useful in some cases.<sup>34</sup> Minimally invasive enucleation, central pancreatectomy, and left-sided pancreatectomy are feasible and safe.<sup>35–37</sup> Notwithstanding, large volume-based studies are needed to validate the current suggestion and clinical observations. In addition, considering the low proliferative power of NF NET-G1 (Ki67 index <1%), more long-term follow-up study should be conducted to reach a concrete conclusion.

In conclusion, our results further put into doubt the oncologic impact of lymph node metastasis in NF NET-G1 of the left side of the pancreas. Therefore, routine conventional distal pancreatectomy with splenectomy for retrieving regional lymph nodes may be too extensive in NF NET-G1. Minimally invasive and function-preserving pancreatectomy is recommended in well-selected NF NET-G1 as long as there are relevant predicting models to predict tumor grade before surgery. Future studies to help realize tailored surgical approaches for use in treating NF NET of the left side of the pancreas are warranted.

## REFERENCES

1. Fesinmeyer MD, Austin MA, Li CI, et al. Differences in survival by histologic type of pancreatic cancer. *Cancer Epidemiol Biomarkers Prev.* 2005;14:1766–1773.
2. Luttgens J. What's new? The 2010 WHO classification for tumours of the pancreas. *Pathologe.* 2011;32(Suppl 2):332–336.
3. Davies K, Conlon KC. Neuroendocrine tumors of the pancreas. *Curr Gastroenterol Rep.* 2009;11:119–127.
4. Oberg K, Knigge U, Kwekkeboom D, et al. Neuroendocrine gastroenteropancreatic tumors: ESMO Clinical Practice Guidelines for diagnosis, treatment and follow-up. *Ann Oncol.* 2012;23(Suppl 7):vii124–vii130.
5. Dralle H, Krohn SL, Karges W, et al. Surgery of resectable nonfunctioning neuroendocrine pancreatic tumors. *World J Surg.* 2004;28:1248–1260.
6. Klimstra DS, Modlin IR, Coppola D, et al. The pathologic classification of neuroendocrine tumors: a review of nomenclature, grading, and staging systems. *Pancreas.* 2010;39:707–712.
7. Fischer L, Bergmann F, Schimmack S, et al. Outcome of surgery for pancreatic neuroendocrine neoplasms. *Br J Surg.* 2014;101:1405–1412.
8. Boninsegna L, Panzuto F, Partelli S, et al. Malignant pancreatic neuroendocrine tumour: lymph node ratio and Ki67 are predictors of recurrence after curative resections. *Eur J Cancer.* 2012;48:1608–1615.
9. Bosman FT, Carneiro F, Hruban RH, et al. WHO classification of tumours of the digestive system. Geneva: World Health Organization; 2010.
10. Mignon M, Colombel JF. Recent advances in the pathophysiology and management of inflammatory bowel diseases and digestive endocrine tumors: postgraduate course 1999, Paris, July 2–3. John Libbey Eurotext; 1999.
11. Fraenkel M, Kim MK, Faggiano A, et al. Epidemiology of gastroenteropancreatic neuroendocrine tumours. *Best Pract Res Clin Gastroenterol.* 2012;26:691–703.
12. Lawrence B, Gustafsson BI, Chan A, et al. The epidemiology of gastroenteropancreatic neuroendocrine tumors. *Endocrinol Metab Clin North Am.* 2011;40:1–18vii.

13. Cherenfant J, Stocker SJ, Gage MK, et al. Predicting aggressive behavior in nonfunctioning pancreatic neuroendocrine tumors. *Surgery*. 2013;154:785–791discussion 791–783.
14. Watzka FM, Laumen C, Fottner C, et al. Resection strategies for neuroendocrine pancreatic neoplasms. *Langenbecks Arch Surg*. 2013;398:431–440.
15. Hashim YM, Trinkaus KM, Linehan DC, et al. Regional lymphadenectomy is indicated in the surgical treatment of pancreatic neuroendocrine tumors (PNETs). *Ann Surg*. 2014;259:197–203.
16. Tsutsumi K, Ohtsuka T, Mori Y, et al. Analysis of lymph node metastasis in pancreatic neuroendocrine tumors (PNETs) based on the tumor size and hormonal production. *J Gastroenterol*. 2012;47:678–685.
17. Han X, Zhao J, Ji Y, et al. Expression of CK19 and KIT in resectable pancreatic neuroendocrine tumors. *Tumour Biol*. 2013;34:2881–2889.
18. Furukori M, Imai K, Karasaki H, et al. Clinicopathological features of small nonfunctioning pancreatic neuroendocrine tumors. *World J Gastroenterol*. 2014;20:17949–17954.
19. Tsutsumi K, Ohtsuka T, Fujino M, et al. Analysis of risk factors for recurrence after curative resection of well-differentiated pancreatic neuroendocrine tumors based on the new grading classification. *J Hepatobiliary Pancreat Sci*. 2014;21:418–425.
20. Birnbaum DJ, Turrini O, Ewald J, et al. Pancreatic neuroendocrine tumor: a multivariate analysis of factors influencing survival. *Eur J Surg Oncol*. 2014;40:1564–1571.
21. Gratian L, Pura J, Dinan M, et al. Impact of extent of surgery on survival in patients with small nonfunctional pancreatic neuroendocrine tumors in the United States. *Ann Surg Oncol*. 2014;21:3515–3521.
22. Bilimoria KY, Talamonti MS, Tomlinson JS, et al. Prognostic score predicting survival after resection of pancreatic neuroendocrine tumors: analysis of 3851 patients. *Ann Surg*. 2008;247:490–500.
23. Partelli S, Gaujoux S, Boninsegna L, et al. Pattern and clinical predictors of lymph node involvement in nonfunctioning pancreatic neuroendocrine tumors (NF-PanNETs). *JAMA Surg*. 2013;148:932–939.
24. Kim J, Eun H, Kim Y, et al. Staging accuracy of MR for pancreatic neuroendocrine tumor and imaging findings according to the tumor grade. *Abdom Imaging*. 2013;38:1106–1114.
25. Society. TGCotJNT. *The Clinical Guidelines for Gastroenteropancreatic Neuroendocrine Tumors in Japan (in Japanese)*; 2015.
26. Bettini R, Partelli S, Boninsegna L, et al. Tumor size correlates with malignancy in nonfunctioning pancreatic endocrine tumor. *Surgery*. 2011;150:75–82.
27. Ikenaga N, Yamaguchi K, Konomi H, et al. A minute nonfunctioning islet cell tumor demonstrating malignant features. *J Hepatobiliary Pancreat Surg*. 2005;12:84–87.
28. Tomassetti P, Campana D, Piscitelli L, et al. Endocrine pancreatic tumors: factors correlated with survival. *Ann Oncol*. 2005;16:1806–1810.
29. Fendrich V, Waldmann J, Bartsch DK, et al. Surgical management of pancreatic endocrine tumors. *Nat Rev Clin Oncol*. 2009;6:419–428.
30. Kang CM, Kim KS, Choi JS, et al. Experiences with nonfunctioning neuroendocrine neoplasms of the pancreas. *Dig Surg*. 2005;22:453–458.
31. Wong J, Fulp WJ, Strosberg JR, et al. Predictors of lymph node metastases and impact on survival in resected pancreatic neuroendocrine tumors: a single-center experience. *Am J Surg*. 2014;208:775–780.
32. Doi R. Determinants of surgical resection for pancreatic neuroendocrine tumors. *J Hepatobiliary Pancreat Sci*. 2015.
33. Birnbaum DJ, Gaujoux S, Cherif R, et al. Sporadic nonfunctioning pancreatic neuroendocrine tumors: prognostic significance of incidental diagnosis. *Surgery*. 2014;155:13–21.
34. Lee LC, Grant CS, Salomao DR, et al. Small, nonfunctioning, asymptomatic pancreatic neuroendocrine tumors (PNETs): role for nonoperative management. *Surgery*. 2012;152:965–974.
35. Kang CM, Lee JH, Lee WJ. Minimally invasive central pancreatectomy: current status and future directions. *J Hepatobiliary Pancreat Sci*. 2014;21:831–840.
36. Asbun JASHJ. Minimally invasive pancreatic surgery. *Semin Oncol*. 2015;42:A3–A4.
37. Kang CM, Lee KG, Pyo JY, et al. Laparoscopic enucleation of a nonfunctioning neuroendocrine tumor of the pancreas. *Yonsei Med J*. 2008;49:864–868.