Original Article

pISSN 2383-5389 / eISSN 2383-8116

Journal of International Society for Simulation Surgery 2014;1(2):71-74

# Evaluation of Masseter Muscle Volume after Contouring of Prominent Mandible Angle by Measurement of CT Scan Image

Yong Oock Kim, M.D., Ph.D.[1], Jong Woo Choi, M.D., Ph.D.[2]

[1]Department of Plastic & Reconstructive Surgery, Yonsei University College of Medicine, Seoul, Korea
[2]Department of Plastic & Reconstructive Surgery, Ulsan Medical College of Medicine, Seoul, Korea

**Purpose** The prominent mandible angle, otherwise known as "square face", has been recognized as an aesthetic problem that needs correction by many in the Asian community. Many surgeons considered that mandible angle ostectomy alone, brings about hypotrophy of the masseter muscle. However, it was only proven indirectly (by clinical experience and histological animal experiments) and not objectively. In this study, we evaluated the volume of masseter muscle to prove the effect, objectively.

**Materials and method** Computed tomography (CT) images were used to measure the masseter muscle volume of normal female group (n=6), and of female patient group n=8, preoperative and early & late postoperative volumes) presenting the symptom of prominent mandible angle. The data was analyzed statistically by two-sample t-test and paired t-test using SAS (version 8.2).

**Results** In normal female group, volume average was 16,142±2,829.8mm$^3$. In patient group, preoperative volume averaged 24,447±4,544.5mm$^3$ ($p<0.0001$) , early postoperative volume measured average of 31,966±50,421mm$^3$ which is a 30% increase from the preoperative volume ($p<0.0001$). Late postoperative measurement was 20,202±4,092.3mm$^3$, which is a 20% decrease from the preoperative volume ($p<0.0006$).

**Conclusion** The bone reduction of prominent mandible angle induce the hypotrophic effect of masseter muscle after long term follow up (5 more months). This result mean that the result of mandible angle contouring surgery can be considered as combined effect of bony angle reduction and subsequent masseter muscle hypotrophy.

**Key Words** Prominent mandible angle · Masseter muscle · Computed tomography.

**Received:** November 17, 2014 / **Revised:** November 18, 2014 / **Accepted:** December 8, 2014
**Address for correspondence:** Yong Oock Kim, M.D., Ph.D.
Department of Plastic & Reconstructive Surgery, Yonsei University College of Medicine, 50 Yonsei-ro, Seodaemoon-gu, Seoul 120-752, Korea
**Tel:** 82-2-2228-2218, **Fax:** 82-2-362-5680, **E-mail:** sgm625@yuhs.ac

## Introduction

Since the developement of computed tomography by G.N. Hounsfield in 1972, digital imaging technique has shown an eye opening progress through the last decade. In 1984 Robert et. al. used 3-dimmensional computed tomography in analyzing normal mandibular joint structures, and thus, 3-dimensional imaging of the human anatomy became possible (1-3). The progress of imaging technique has made quantitative analysis of preoperative and postoperative states possible, enabling objective verification of the anatomical changes.

Prominent mandible angle, which is commonly seen in Asians, was first reported by Legg in 1880, as masseter muscle hypertrophy. Since then, masseter muscle resection was done by Gurney in 1947. Adams4 who thought the cause of prominent angle was due to the prominence of the mandible bone as well as muscle hypertrophy, reported surgical correction through angle ostectomy in addition to masseter muscle resection. In 1977, after Converse, mandible angle ostectomy with resection of masseter muscle by the intraoral approach was performed simultaneously. Recently, the phenomenon of reduction of masseter muscle by mandible angle ostectomy alone, was clinically experienced (5-9). Maxwell (10) explained it as the hypotrophy caused by loss of tension of the masseter muscle. However, it

**Table 1.** Normal Female and Female Patient Masseter Muscle Volume ($mm^3$)

| Nl.No. | Sex/Age | Rt. ($mm^3$) | Lt. ($mm^3$) | Pt. No. | Sex/Age | Rt. ($mm^3$) | Lt. ($mm^3$) |
|---|---|---|---|---|---|---|---|
| 1 | F/36 | 15942.88 | 20606.38 | 1 | F/46 | 17613.00 | 17211.25 |
| 2 | F/33 | 15215.25 | 15657.63 | 2 | F/41 | 23389.38 | 21671.00 |
| 3 | F/37 | 18186.50 | 17931.50 | 3 | F/30 | 30807.75 | 26116.88 |
| 4 | F/17 | 20105.00 | 18002.25 | 4 | F/28 | 31472.25 | 29837.13 |
| 5 | F/13 | 12824.00 | 12403.00 | 5 | F/26 | 28486.38 | 26470.38 |
| 6 | F/23 | 13951.88 | 12873.25 | 6 | F/24 | 21722.25 | - |
| | | | | 7 | F/18 | 21957.50 | - |
| | | | | 8 | F/23 | 22464.38 | 23452.13 |
| Mean±SD | | 16142±2829.8 | | | | 24477±4544.5 | |
| p-value* | | | | <0.0001 | | | |

*statistical analysis between normal female masseter volume and female patient masseter volume, Nl. No.: normal female number, Pt. No.: female patient number

**Table 2.** Sequential Masseter Muscle Volume ($mm^3$) in Female Patients

| Pt. No. | Sex/Age | Pre Op | | Early Post Op | | Late Post Op | | Follow Up Time (early/late) |
|---|---|---|---|---|---|---|---|---|
| | | Rt. ($mm^3$) | Lt. ($mm^3$) | Rt. ($mm^3$) | Lt. ($mm^3$) | Rt. ($mm^3$) | Lt. ($mm^3$) | |
| 1 | F/46 | 17613.00 | 17211.25 | 23521.25 | 23583.75 | - | - | 5days/- |
| 2 | F/41 | 23389.38 | 21671.00 | 30653.25 | 30295.88 | 20469.38 | 18909.75 | 4months/9months |
| 3 | F/30 | 30807.75 | 26116.88 | 39349.50 | 34875.13 | 27225.00 | 22144.25 | 1months/5months |
| 4 | F/28 | 31472.25 | 29837.13 | 34770.38 | 35180.75 | 22877.13 | 20085.63 | 2months/8months |
| 5 | F/26 | 28486.38 | 26470.38 | 36429.88 | 33293.25 | - | - | 1months/- |
| 6 | F/24 | 21722.25 | - | 29670.75 | - | 14729.50 | - | 15days/7months |
| 7 | F/18 | 21957.50 | - | - | - | 15174.88 | - | -/7months |
| 8 | F/23 | 22464.38 | 23452.13 | - | - | - | - | -/- |
| Mean±SD | | 24477±4544.5 | | 31966±5042.1 | | 20202±4092.3 | | |
| p-value* | | <0.0001 (30 % increase) | | | | | | |
| p-value† | | 0.0006 (20% decrease) | | | | | | |

*statistical analysis between pre op and early post op, †statistical analysis between pre op and late post op

was not proven objectively by enumeration. In this study, we measured and analyzed the change of volume of masseter muscle before and after mandible angle ostectomy based on computed tomography image information, and thus the method and results are reported here.

## Materials and Methods

The volume of masseter muscle of 6 normal individuals(aged from 13 to 37 years) and 8 patients(aged from 18 to 46 years, 6 bilateral and 2 unilateral cases) who visited our hospital from January 2002 to June 2004 was measured (Table 1). The patient group data includes presurgical volumes, early postsurgical volumes (within 5 months after surgery) and of late postsurgical volumes (5 up to 9 months after surgery)(Table 2). The surgery was performed under general anesthesia and only mandible angle ostectomy by the intraoral approach was performed. To measure the volume, tomographic images were taken by 2 mm thickness with 1 mm interpolation, 12 bit, and 512×512 pixels and transmitted subsequently from the hard disk of computed tomography scanner to an IBM personal computer by the interface π-Viewer (Mediface, Seoul, Korea). All axial image information was stored as DICOM format. Then by using Analyze AVW 5.0 (Analyze AVW, Inc. 11425 Strang Line Road Lenexa, KS, 66215 USA) program, division of the area to be analyzed, 3 dimensional reconstruction of the divided image data, and measurement of the volume were performed (Fig. 1 and 2). The obtained data was analyzed by two sample t-test and paired t-test using SAS (version 8.2) program.

## Results

In normal female group, volume average was 16,142±2,829.8 $mm^3$. In patient group, preoperative volume averaged 24,447±4,544.5$mm^3$ ($p<0.0001$) , early postoperative volume measured average of 31,966±50,421$mm^3$ which is a 30% increase from the preoperative volume ($p<0.0001$). Late postoperative measurement was 20,202±4,092.3 $mm^3$, which is a 20% decrease from the preoperative volume ($p<0.0006$)(Table 2).

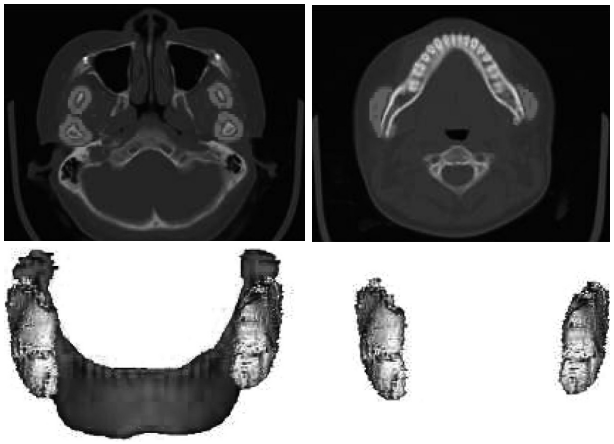

**Fig. 1.** Image Segmentation Procedures. (Above) 2mm thickness, 512x512 pixels, axial CT image (Above, left) segmentation of mandible area from axial images including mandible bone (Above, right) segmentation of masseter area from axial images including masseter muscle (Below, left) 3D reconstructed mandible bone and masseter muscles image (Below, right) 3D reconstructed image of masseter muscles.

**Fig. 2.** Sequential Images of Patient No. 2. Segmented and 3D reconstructed image (Left) preoperative image (Center) early postoperative image (Right) late postoperative image: note the volumetric changes following the time intervals.

## Discussion

The external appearance of prominent mandible angle is considered as an appearance with the combined effect of masseter muscle and mandible angle. Therefore, the contouring of prominent mandible angle was treated by bony contouring and/or resection of masseter muscle. However, masseter muscle resection has the risk of injuring the major blood vessel and nerves, and sometimes it may cause trismus. In addition, the hypotrophy of masseter muscle was reported only after mandible angle ostectomy, so, the necessity of masseter muscle resection has been under discussion (4-9). The result of our study shows that patient group displays statistically significant larger volume than in normal group. This result is considered as same as generally known concept in prominent mandible angle. In other word, the final appearance of prominent mandible angle is the result of not only bony prominence of the mandible angle, but also normal masseter hypertrophy.

In comparison between the preoperative measurement and early postoperative measurement, a statistically significant increase in masseter muscle volume was seen ($p<0.0001$). This is believed to be because of the edema after all the dissection and traction during operation, the loss of muscle tension, and accumulation of connective tissues and adipocytes within the masseter muscle (11, 12). However, additional researches are required. Significant decrease was noted in comparision between preoperative and late postoperative volumes ($p<0.0006$). Masseter volume decreased despite the regular oral food uptake, and thus it is considered to be a continuous result rather than a temporary one, because the follow up duration of late post-op. is from 5months to 9months.

In 1994, Hong et al. (11) reported an experiment performed on rabbits. After curved angle ostectomy, gradual histological volume decrease of masseter muscle was observed. The causality was reported to be the loss of normal function by disinsertion of the muscle attachment area, reduction of muscle tension or the change of contraction direction of the masticatory muscle. In addition, in 2004, Gerber (12) reported that after tenotomy of the rotator cuff in sheeps, muscle atropy was brought about and confirmed by CT. Also, in this study, accumulation of adipocytes was detected in histologic and electron microscopic examination. Such muscle atrophy has been reported to be irreversible. Elevation of periosteum surrounding the mandible seems to decrease the tension of the masseter muscle, similar to tenotomy. Also, ostectomy of the mandible angle decreases the masseter's attachment area to the mandible, decreasing the tension even more, inhibiting quantitative recovery of muscle volume.

In our study, mandible angle ostectomy was done by resection of mandible angle only. However, numerous studies report that resection of mandible body including the mandible angle induces even more decrease in masseter muscle volume after surgery (4-9). Therefore, difference of muscle atrophy amount seems to depend on surgical technique, but conclusion requires additional comparative studies.

Even though, this study can confirm the hypotrophic effect of masseter muscle after bony angle resection, objectively, we have to study more to clarify how much bony resection result how much reduction of masseter muscle volume.

## Conclusion

The bone reduction of prominent mandible angle induce the hypotrophic effect of masseter muscle after long term follow up (5 more months). This result mean that the result of mandible angle contouring surgery can be considered as combined effect of bony angle reduction and subsequent masseter muscle hypotrophy.

## Acknowledgements

This work was supported by the Technology Innovation Program (10045651, Development of continuous automatic craniomaxillofacial distraction osteogenesis device for minimal invasive surgery and acceleration bone healing), funded By the Ministry of Trade, industry & Energy (MI, Korea).

## REFERENCES

1. Donlon WC, Young P, Vassiliadis A. Three dimensional computed tomography for maxillofacial surgery. J Oral Maxillofac Surg 1998; 46:142-147
2. Salyer KE, Taylor DP, Billmire DE. Three dimensional CAT scan reconstruction-Pediatirc patients. Clin Plast Surg 1986;13(3):463-474
3. Vannier MW, March JL, Warren JO. Three dimensional CT reconstruction images for craniofacial surgical planning and evaluation. Radiology 1984;150(1):179-184
4. Adams WM. Bilateral hypertrophy of the masseter muscle: An operation for correction (Case Report). Br J Plast Surg 1949;2:78-81
5. Yang DB, Park CG. Mandibular contouring surgery for purely aesthetic reasons. Aesth Plast Surg 1991;15(1):53-60
6. Baek SM, Baek RM, Shin MS. Refinement in aesthetic contouring of the prominent mandibular angle. Aesth Plast Surg1994;18(3): 283-289
7. Yang DB, Song HS, Park CG. Unfavorable results and their resolution in mandibular contouring surgery. Aesthetic Plast Surg 1995; 19(1):93-102
8. Satoh K. Mandibular contouring surgery by angular contouring combined with genioplasty in Orientals. Plast Reconstr Surg 1998;101(2): 461-472
9. Han KH, Kim JH. Reduction mandibuloplasty: Ostectomy of the lateral cortex around the mandibular angle. J Craniofac Surg 2001;12(4): 314-325
10. Maxwell LC, Carlson DS, McNamara JA Jr, et al. Adaptation of the masseter and temporalis muscles following alteration in length, with or without surgical detachment. Anat Rec 1981;200(2):127-137
11. Hong JW, Choi J, Baek SM. Pathohistological and radiological changes of masseter muscle and ostectomized bony surface following mandibular angle ostectomy in rabbits. J Korean Soc Plast Reconstr Surg 1994;21(5):857-864
12. Gerber C, Meyer DC, Schneeberger AG, et al. Effect of tendon release and delayed repair on the structure of the muscles of the rotator cuff: an experimental study in sheep. J Bone Joint Surg Am 2004;86-A(9):1973-1982