Treatment outcome of Intrabony Defects with Guided Tissue Regeneration using Space-Providing Suturing Technique

Eun-Young Lee

The Graduate School

Yonsei University

Department of Dental Science

Treatment outcome of Intrabony Defects with Guided Tissue Regeneration using Space-Providing Suturing Technique

Submitted to the Department of Dental Science
and the Graduate School of Yonsei University
In partial fulfillment of the
Requirements for the degree of
Master of Philosophy of Dental Science

Eun-Young Lee

June 2005

This certifies that the dissertation thesis

of Eun-Young Lee is approved

_____

Thesis Supervisor : Chang-Sung Kim

_____

_____

The Graduate School

Yonsei University

June 2005

감사의 글

본 논문이 완성되기까지 부족한 저를 항상 격려해 주시고 사랑과 관심으로 이끌어 주신 김창성 교수님께 깊은 감사를 드립니다. 그리고, 많은 조언과 따뜻한 관심으로 지켜봐 주신 김종관 교수님, 채중규 교수님, 조규성 교수님, 최성호 교수님, 김형준 교수님, 정의원 교수님께 진심으로 감사 드립니다.

연구 내내 많은 도움을 주신 치주과 교실원 여러분들께 고마움을 전합니다.

그리고, 늘 아낌 없는 사랑과 헌신적인 도움으로 든든하고 따뜻한 버팀목이 되어준 사랑하는 나의 가족과 항상 한없는 따뜻함이 되어준 사랑하는 독수리 5자매(유미, 민경, 상희, 정현), 건강 계원들(영아, 연희, 희영, 정은, 지윤, 주희, 민영, 현옥, 미애), 배구 천재들(용준, 일환, 성연, 진학, 하용, 지선, 민석)에게 진정으로 사랑과 고마움의 마음을 전합니다. 특히 지난 2년간 도와주신 소아치과 채문희 선생님께 깊은 감사를 드립니다. 모든 분들께 진심으로 감사 드립니다.

2005년 6월

저자 씀

Table of Contents

List of Figures

List of Tables

Abstract

Treatment outcome of Intrabony Defects with Guided Tissue Regeneration using Space-Providing Suturing Technique.

The purpose of this clinical trial was to demonstrate how the specially designed suturing technique enhanced space-provision by the conventional GTR membrane and evaluate the healing of intrabony defect with GTR procedures using this technique 1year after surgery.

Thirty-four (34) defects in 25 patients were randomly assigned to 1 of 2 treatment groups. The test group was treated with expanded polytetrafluoroethylene (ePTFE) membranes and space-providing suturing technique; the second group was treated with an access flap procedure only. During the 1-year observation period, patients were subjected to a stringent infection control program including professional tooth cleaning every week for the first 6 weeks (two groups) and then checked every 3 months for 12 months (two groups).

The results indicated that; 1) treatment modalities of the two groups resulted in clinically and statistically significant improvement in clinical attachment level (CAL) and probing depth (PD) at 1year; 2) a significantly greater amount of CAL gain ($P<0.0174$) was observed in the test group (4.06±1.60 mm) with respect to the control group (2.53±1.94mm); 3) a significantly greater amount of PD reduction ($P<0.0005$)

was observed in the test group (4.35±1.46 mm) with respect to the control group (2.53±1.28mm)

It can be concluded that the combination of space-providing suturing technique with expanded polytetrafluoroethylene (ePTFE) membranes resulted in significantly greater CAL and PD improvement than access flaps

Key Words: Guided Tissue Regeneration; polytetrafluoroethylene (ePTFE) membrane; intrabony defect; space-providing suture

Treatment of Intrabony Defects with Guided Tissue Regeneration using Space-Providing Suturing Technique.

Eun-Young Lee**, D.D.S., M.S.D.**

Department of Dental Science

Graduate School, Yonsei University

(Directed by Prof. Chang-Sung Kim, D.D.S., M.S.D., PhD.)

I. Introduction

The ultimate goal of periodontal therapy for destructive periodontal disease is regeneration of attachment apparatus. Among various surgical procedures to achieve these goals, guided tissue regeneration (GTR) procedures have been reported to have somewhat more favorable healing potential. Clinical outcome, however, was dependent on the several factors including defect morphology, patient characteristics and surgical technique. There is also evidence to suggest that space-provision by GTR membrane influences the total amount of new bone formation (Haney et al 1993, Sigurdsson et al 1994). Thus, Membrane should be positioned and maintain more coronally, enhancing the space available for regeneration since the position of the membrane physically limits the extent of the regeneration. To obtain space-provision

under the GTR devices, bone graft as well as bone graft substitute has been used. (Kim et al. 1996, Kim et al 1998). It was also reported that self-supporting titanium reinforced membrane resulted in significantly greater CAL improvement than conventional GTR procedures membrane. (Cortellini et al 1995).

The purpose of this clinical study was to 1) demonstrate how the specially designed suturing technique enhances space-provision by the conventional GTR membrane and 2) evaluate the healing of intrabony defect with GTR procedures using this technique 1year after surgery.

II. Materials & methods

A. Materials

1. Patient and site selection

25 patients (14 males and 11 females) ranging in age from 28 to 64 with generalized chronic advanced periodontitis took part in the present study and gave informed consent to participate in this clinical trial. Preoperative clinical and radiographic examination revealed deep intrabony defects in all patients. 34 interproximal intrabony defects were selected which met the following criteria:

1. No history of systemic disease and no pharmacological therapy within last 12months.
2. Clinical and radiographic evidence of interproximal periodontal defects.
3. Preoperative probing pocket depth equal to or greater than 6mm
4. Preoperative clinical attachment level equal to or greater than 6mm

Prior to surgery, all the patients had received a hygienic phase including oral hygiene instruction, scaling and root planning. The patients were randomly distributed into two treatment groups. The treatments included 1) gingival flap surgery alone; GFS (15 patients, 17 sites) 2) GTR using space-providing suture; GTRs (15patients, 17sites). Table 1 presents distribution and clinical characterization of patients and selected sites

2. Parameters

Clinical parameters were recorded immediately prior to surgery and after 12months using a conventional periodontal probe (CP15UNC, Hu Friedy, Chicago, IL). Probing pocket depth (PD), gingival recession (GR), and clinical attachment level (CAL) were recorded at the deepest probing point of the defects with the cemento-enamel junction (CEJ) as a reference point.

The gingival index (GI) and plaque index (PI) were assessed at 6 standardized sites (mesiobuccal, midbuccal, distobuccal, mesiolingual, midlingual, and distoligual) of defect-associated teeth.

All clinical recordings were made by two examiners (LEY and KCS).

B. Procedures

1. Surgical Procedures

All defects were treated with gingival flap surgery following local anesthesia (2% lidocaine, 1:100,000 epinephrine, Kwangmyung Pharm., Seoul, Korea), including sulcular incision, reflection of mucoperiosteal flaps, removal of granulation tissue, and meticulous root planning (Fig 2). In order to preserve maximum gingival soft tissue for primary coverage, simplified or modified papilla preservation technique was performed. For the GTR treatment, specially designed suturing technique (space-

providing suture) to enhance space-provision was applied on conventional interproximal type e-PTFE membrane (Gore-Tex periodontal material, W.L. Gore&Associates Inc., Flagstaff, AZ.) prior to adaptation to the defect (Fig 3). And then, e-PTFE membrane was adapted above the alveolar crest with approximately 3 mm extension over the buccal and lingual bony defect margins and secured by space-providing suture as tightly as possible (Fig 4). The knot was made on the adjacent tooth. Gingival flaps were coronally repositioned to cover the membrane and sutured with e-PTFE or Ethylene suture materials using a vertical mattress suturing technique. Periodontal dressing was not used.

2. Post-surgical Infection Control

Mechanical plaque control was abandoned until the removal of the membrane. Rather, plaque control was maintained by using a chlorhexidine mouthwash 3 times daily. Antibiotic regimens were prescribed for 7days. Gingival sutures and space-providing suture were removed 10days after surgery. In case of membrane exposure, professional cleaning including chlorhexidine irrigation and topical antibiotics was carried out every week. Professional tooth cleaning was carried out every 1 or 2 weeks for the first 6weeks in both groups. The patients were checked every 3 months for the following 12 months, and so far they have been followed up for over 1 year post surgically (Fig 5. 6).

In the present study, e-PTFE membrane was surgically removed at average 5.2 weeks post surgically (ranging 4 ~ 10 weeks). The presence of membrane exposure (MEx) at the time of surgical removal was recorded. The inner aspect of the flap was excised and the flap was re-adapted and sutured.

3. Statistical Analysis

Data were expressed as means±standard deviations (m±SD). Comparisons between experimental and control treatments were made using Mann-Whitney U test. The significance of mean difference between pre- and post surgery clinical parameters was analyzed using Wilcoxon signed-rank test. The level of statistical difference was defined as $P < 0.05$.

III. Results

1. Clinical observations

Healing was uneventful in all treatment groups. Limited signs of inflammation, swelling, or redness could be observed. Radiographic examinations revealed limited changes in crestal bone level and radiodensity for the control group. In contrast, for the GTR group, increased crestal bone level and radiodensity was observed in the treatment sites.

2. Treatment outcome

Pre-surgery defect characteristics were similar between control and GTR group (Table 1). At 1 year, oral hygiene and gingival health improved significantly and significant probing depth reductions were observed for both treatment groups (control: 2.59±0.28mm and GTR: 4.35±1.46mm). The GTR group exhibited significantly greater reduction of PD compared to control group. (Table 2)

Significant clinical attachment gains were also observed for both groups (control: 2.53±1.94mm and GTR: 4.03±1.60mm). The GTR group exhibited significantly greater gains compared to control group.

GTR group exhibited a significant increase in gingival recession compared to pre surgery. Table 4 shows the frequency distribution of CAL gains for the two-treatment

group. 100% of GTR group displayed a CAL gain of 2 to 8mm.

Table 1. Pre-surgery characteristics for intrabony defect (mm, n=)

	GFS (n=17)	GTR (n=17)	p (0.05)
Male/Female	10/5	7/8	
Age (Range)	28~64	33~54	
Site*	1/0/6/6/4	2/1/5/5/4	
CAL	7.29±1.05	7.94±1.60	NS
PD	6.82±1.01	7.35±1.46	NS
GR	0.47±0.80	0.59±0.87	NS
GI	1.12±0.54	1.23±1.13	NS
PI	0.61±0.72	0.81±1.08	NS

*; incisor / canine /premolar / mandibular molar / maxillary molar

PD: probing depth; CAL: clinical attachment level; GR: gingival recession; GI: gingival index; PI: plaque index

Table 2. Changes in clinical parameters of healing response between baseline and 12 months post-surgery (mm)

	GTR			GFS		
	Mean	S.D	Range	Mean	S.D	Range
PD reduction (mm)	4.35*†	1.46	1~9	2.59*†	0.28	0~5
GR increase (mm)	0.65*	1.06	(-1)~3	0.06*	0.43	(-3)~2
CAL gain (mm)	4.03*†	1.60	1~8	2.53*†	1.94	(-1)~5

PD: probing depth; CAL: clinical attachment level; GR: gingival recession

*: Statistically significantly different from group (P<0.05)

†; Statistically significantly different between groups (P<0.05)

Table 3. Frequency distribution of CAL gains at 1 year

PAL gain (mm)	GTR		GFS	
	N	%	N	%
<2	0	0.00	6	35.29
≥2-<4	6	35.29	4	23.52
≥4-<6	8	47.05	7	41.17
≥6	3	17.64	0	0.00
Sum	17	100	17	100

PD: probing depth; CAL: clinical attachment level; GR: gingival recession

3. Membrane exposure

At the surgical removal of the membrane, membrane exposure was observed in 9 defects (53%). When membrane exposure occurred, it was observed initial healing period of 1 or 2 weeks postoperatively. Gingival inflammation was minimal and limited at the exposure margin. At 1 year, PD reduction and CAL gain were greater in patients without membrane exposure (4.44mm, 4.22mm respectively) than in patients with membrane exposure (4.25mm, 3.88mm respectively). However, there were no statistical differences. In terms of GR, there were also no statistical differences. (Table 4)

Table 4. Post-surgery change in clinical parameters of healing response in exposure and no-exposure

	Exposure (n=9)	No exposure (n=8)	p
PD reduction (mm)	4.25±0.71	4.44± 1.94	NS
GR increase (mm)	0.89±1.23	0.38±0.74	NS
CAL gain (mm)	3.88±1.25	4.22±1.92	NS

PD: probing depth; CAL: clinical attachment level; GR: gingival recession

IV. Discussion

In the present clinical study, we demonstrated “space-providing suturing technique” specially designed for space-provision by the conventional GTR membrane and evaluated the healing of the intrabony defect with GTR procedures using this technique. At 1year after surgery, the results showed that GTR procedure using space-providing suturing technique resulted in significantly reduced probing pocket depth and improved clinical attachment. This clinical study did not include GTR group using conventional sling suture for membrane stabilization. Thus, the effects of the suturing technique on the space-provision of the membrane and clinical healing outcomes could not be compared. However, when compared to previous reports, GTR procedure using this technique appeared to have beneficial effect for the space-provision and thus showed improvement of the clinical results.

The concept of using GTR device for treatment of periodontal defects is not only to prevent the gingival connective tissue and epithelium from ingrowths into a periodontal defect but also to provide space for periodontal regeneration. Evidences have shown that space-provision is a critical determinant factor for the amount of tissue regeneration. Even if GTR membrane is used, compromised space provision resulted in limited alveolar and cementum regeneration. Thus, clinical trials for the supporting and protection of the space by the GTR devices have been proposed.

Space provision by the membrane could be obtained either by placement of bone graft or bone substitutes into the space beneath the membrane or by using titanium reinforced membrane.

Space-provision could be significantly enhanced following use of the bone graft or substitutes. Polimeni et al. evaluated the effect of a space-providing coral derived biomaterial on the bone regeneration in conjunction with GTR using critical size, supra-alveolar periodontal defects in dogs. Histometric analysis showed that the coral biomaterials effectively enhanced space-provision (wound area). Wikesjo et al also reported that average defect area was increased almost 3 times in sites using the coral implant in conjunction with GTR compared to sites treated with GTR only.

In addition to supporting space provision, it appears to be significant that resorption of the bone materials beneath membrane should be accord with bone regeneration since residual implant particles have been suggested to potentially obstruct the room for tissue regeneration and thus interfere with rather than accelerate natural bone healing. However, several studies reported that residual implant particles could be observed in histological findings.

Stavropoulos et al. in their series of studies evaluated the influence of bone substitutes on the bone formation when used as an adjunct to GTR in the rat using "capsule model.” Histological results obtained 4 months post surgery revealed that the newly formed bone in the capsule was significantly greater in the control GTR group

without graft than in the GTR group grafted with bone substitutes. Most of the graft particles in the GTR group grafted with bone substitutes were embedded in connective tissue. Similar results were obtained even with prolonged periods of healing. 1 year histological results revealed that the newly formed bone occupied more area in the control GTR group (88.2%) than in the GTR group grafted with bone substitutes (23%). Furthermore, volumetric changes of the new bone did not occur at further extended healing periods of 6months. It was also significant in their studies that the amount of the implant particles embedded in connective tissue did not differ significantly even with extended longer observation periods. In addition, histological findings of the osteoclastic activity adjacent to the implant particles were rare. Poor resorption rate of the implant particles were also indicated in several including human studies. Therefore, it could be suggested that implants particle under the membrane could significantly enhance the space-provision. However, implants particle remnant in the defect potentially interferes with normal bone healing. Thus, the use of bone grafts or substitutes beneath membrane for the space-provision is enough ground for controversy in terms of qualitative outcome.

Improvement of the space provision without bone graft could be also achieved by titanium (Ti)-reinforced membrane. This ‘rigid’ membrane could provide enhanced space for regeneration and be resistant to membrane collapse due to tissue compression during the healing periods. Cortellini et al., in their controlled clinical

study, reported that self-supporting Ti-reinforced GTR membranes placed more coronally than conventional GTR approach in clinically and statistically significant improvement.

In the present study, we demonstrated specially designed suturing technique for supporting membrane. Several advantages using space-providing suturing technique could be proposed from clinical point of view: 1) Due to characteristics of this suturing technique, the more sutures are knotted tight, the more the membrane is secured firmly and coronally. Thus, firm space-provision could be possible without bone graft until the removal of the membrane, 2) Membrane tearing by tight suture could be preventable 3) It could prevent membrane from being collapsed by tissue compression induced during gingival flap closure using mattress suture, and 3) splinting effect for mobile tooth is expected.

Membrane exposure has been reported with varying proportion. In the present study, most membrane exposure could be found within 2weeks after the GTR procedure. When exposure occurred, plaque accumulation on the exposed membrane and slightly red and swollen marginal gingival tissue along the exposed portion were observed. However, marked gingival inflammation or infection was not induced by the membrane exposure. At membrane removal, red, immature and bleeding tendency tissue could be observed. However, tissue integration was evident under the no-exposure portion of the membrane. Whitish and scarcely bleeding tissues were

common finding under the no-exposed sites.

In the present study, membrane exposure sites tended to show reduced CAL gain 1 year after GTR procedure although difference was not statistically significant compared to no-exposed sites. These results are in agreement with previous studies. Sander and Karring reported that reduced CAL gain on the membrane exposure sites (30~59%) compared to non-exposure sites (75~100%) after GTR procedure. Moreover, it was reported that membrane exposed site harbor much more amount of periodontal pathogen and negative correlation between the amount of periodontal pathogen and clinical outcome of GTR was also reported. Thus, it could be suggested that membrane exposure after GTR procedure is the critical factor to influence the outcome of GTR.

The use of specially designed suture technique was significantly better than conventional approach for space provision by membrane and this surgical approach resulted in enhanced clinical outcome. Thus, the GTR procedure using this technique can be used to successfully treat the periodontal defect.

V. Conclusion

The purpose of this study was to compare the clinical efficacy of 2 treatment modalities in the treatment of deep interproximal intrabony defects. Thirty-four (34) defects were randomly assigned to 1 of 2 treatment groups. The test group was treated with expanded polytetrafluoroethylene (ePTFE) membranes and space-providing suture technique. The control group was treated with an access flap procedure only.

1 year after surgery, clinical outcome of the specially designed suturing technique to enhance space-provision was evaluated. The results indicated that; 1) treatment modalities of the two groups resulted in clinically and statistically significant improvement in clinical attachment level (CAL) and probing depth (PD) at 1year; 2) a significantly greater amount of CAL gain ($P<0.0174$) and PD reduction ($P<0.0005$) was observed in the test group with respect to the control group

In the present study, we demonstrated specially designed suturing technique for supporting membrane. Several advantages using space-providing suturing technique could be proposed from clinical point of view: 1) Due to characteristics of this suturing technique, the more sutures are knotted tight, the more the membrane is secured firmly and coronally. Thus, firm space-provision could be possible without bone graft until the removal of the membrane, 2) Membrane tearing by tight suture could be preventable 3) It could prevent membrane from being collapsed by tissue

compression induced during gingival flap closure using mattress suture, and 3) splinting effect for mobile tooth is expected. Thus, the GTR procedure using this technique can be used to successfully treat the periodontal defect.

It can be concluded that the combination of space-providing suture technique with expanded polytetrafluoroethylene (ePTFE) membranes resulted in significantly greater CAL and PD improvement than access flaps. Thus, the GTR procedure using this technique can be used to successfully treat the periodontal defect.

.

REFERENCES

1. Becker W, Becker BE, Berg L, Prichard J, Caffesse R, Rosenberg E. New attachment after treatment with root isolation procedures: report for treated Class Ⅲ and Class Ⅱ furcations and vertical osseous defects. *Int J Periodontics Restorative Dent.* 1988;8(3):8-23

2. Chong- Kwan Kim, Eun-Jeong Choik Kyoo- Sung Cho, Jung-Kiu Chai, and Ulf M.E, Wikesjo. Periodontal repair in intrabony defects treated with a calcium carbonate implant and guided tissue regeneration. *J Periodontol*. 1996 67:1301-1306

3. Cortellini P, Bowers G. M. Periodontal regeneration of intrabony defects: an evidence-based treatment approach. *Int J Periodontal Rest Dent* 1995;15:128-145

4. Cortellini P, Pini Prato G, Tonetti MS. Periodontal regeneration of human intrabony defects with titanium reinforced membranes. A controlled clinical trial. *J Periodontol*. 1995;66:797-803

5. Cortellini P, Pini Prato G, Tonetti MS. Periodontal regeneration of human infrabony defects. Ⅰ. Clinical measures. *J Periodontol*. 1993 Apr;64(4):254-60

6. Cortellini P, Pini Prato G, Tonetti MS. Periodontal regeneration of human infrabony defects. Ⅱ. Re-entry procedures and bone measures. *J Periodontol*. 1993 ;64:261-268

7. Cortellini P, Pini Prato G, Tonetti MS. Periodontal regeneration of human infrabony defects. Ⅳ. Determinants healing response. *J Periodontol*. 1993 ;64:934-940

8. Cortellini P. Pini Prato G, Tonetti MS. Periodontal regeneration of human intrabony defects with bioresorbable membranes, a controlled clinical trial. *J Periodontol*. 1996 Mar;67(3)217-23

9. Cortellini P, Pini Prato G, Tonetti MS. Periodontal regeneration of human infrabony defects (Ⅴ). Effect of oral hygiene on long-term stability. *J Clin Periodontol*. 1994 Oct;21(9):606-10

10. F. Mora, D, Etienne& J. P. Ouhayoun. Treatment of interproximal angular defects by guided tissue regeneration: 1-year follow-up. *J of oral rehabilitation* 1996 23;599-606

11. Gottlow J, Nyman S, Lindhe J, Karring T, Wennstrom J. New attachment formation in the human periodontium by guided tissue regeneration. Case reports. *J Clin Periodontol*. 1986 Jul;13(6):604-16

12. Kim CK, Chai JK, Cho KS, Moon IS, Choi SH, Sottosanti JS, Wikesjo UM. Periodontal repair in intrabony defects treated with a calcium sulfate implant and calcium sulfate barrier. *J Periodontol*. 1998 Dec;69(12):1317-24

13. Kunt A. Selvig, Betty G. Kersten, Ulf M. E. Wikesjo. Surgical treatment of intrabony periodontal defects using expanded polytetrafluoroethylene barrier membranes: influence of defect configuration on healing response. *J Periodontol*. 1993Aug;64(8):730-733

14. Laurell L. Gottlow J. Guided tissue regeneration update. *Int Dental Journal* 1998;48:386-398

15. Mellado JR, Sanlkin LM, Freedman AL, Stein MD. A comparative study of e-PTFE membranes with and without decalcified freeze-dried bone allograft for the

regeneration of interproximal intraosseous defects. *J Periodontol*. 1995 Sep; 66(9):751-5

16. Nielsen IM, Glavind L, Karring T. Interproximal periodontal intrabony defects. Prevalence, localization and etiological factors. *J Clin Periodontol*. 1980 Jun;7(3):187-98

17. Nygaard-Østby P, Tellegsen G, Sigurdsson TJ, Zimmerman GJ, Wikesjo UME. Periodontal healing following reconstructive surgery: effect of guided tissue regeneration. *J Clin Periodontol*. 1996;23:1073-1079

18. Polimeni G, Koo K-T, Qahash M, Xiropaidis AV, Albandar JM, Wikesjo UME. Prognotic factors for alveolar regeneration: effect of a space-providing biomaterial on guided tissue regeneration. *J Clin Periodontol*. 2004;31:725-729

19. Proestakis G, Bratthall G, Soderholm G, Kullendorff B, Grondahl K, Rohlin M and Attstrom R. Guided tissue regeneration in the treatment of infrabony defects on maxillary premolars. *J Clin Periodontol*. 1992;19:766-773

20. Rosling B, Nyman S, Lindhe J. The effect of systematic plaque control on bone regeneration in infrabony pockets. *J Clin Periodontol*. 1976 Feb;3(1):38-53

21. Schallhorn RG, McClain PK. Clinical and radiographic healing pattern observations with combined regenerative techniques. *Int J Periodontics Restorative Dent.* 1994 Oct;14(5):391-403

22. Selvig KA, Kersten BG, Chamberlain AD, Wikesjo UM, Nilveus RE. Regenerative surgery of intrabony periodontal defects using e-PTFE barrier membranes: scanning electron microscopic evaluation of retrieved membranes versus clinical healing. *J Periodontol*. 1992 Dec;63(12):974-8

23. Selvig KA, Kersten BG, Wikesjo UM. Surgical treatment of intrabony periodontal defects using expanded polytetrafluoroethylene barrier membranes: influence of defect configuration on healing response. *J Periodontol*. 1993 Aug;64(8):730-3

24. Silvestri M, Ricci G, Rasperini G, Sartori S, Cattaneo V. Comparison of treatments of infrabony defects with enamel matrix derivative, guided tissue regeneration with a nonresorbable membrane and Widman modified flap. *J Clin Periodontol*. 2000;27:603-610

25. Stavropoulos A, Kostopoulos L, Nyengaard J R, Karring T: Deproteinized bovine bone (Bio-Oss) and bioactive glass (Bio- Gran) arrest bone formation when used as an adjunct to guided tissue regeneration (GTR). An experimental study in the rat. *J Clin Periodontol*. 2003:30:636-643

26. Sture Nyman, Jan Lindhe, Thorkild Karring and Harald Rylander. New attachment following surgical treatment of human periodontal disease. *J Clin Periodontol*. 1982:9:290-296

27. Tonetti MS, Pini Prato G, Cortellini P. Factors affecting the healing response of intrabony defects following guided tissue regeneration and access flap surgery. *J Clin Periodontol*. 1996;23:548-556

28. Tonetti, M. S., Pini-Prato. G. P., Williams, R. C. & Cortellini. Periodontal regeneration of human infrabony defects. Ⅲ. Diagnostic strategies to detect bone gain. *J Periodontol.* 1993 ;64:269-277

29. Trombelli L, Kim CK, Zimmerman GJ, Wikesjo UM. Retrospective analysis of factors related to clinical outcome of guided tissue regeneration procedures in intrabony defects. *J Clin Periodontol*. 1997 Jun;24(6):366-71

30. Weltman R, Trejo PM, Morrison E, Caffesse R. Assessment of guided tissue regeneration procedures in intrabony defects with bioabsorbable and non-resorbable barriers. *J Periodontol*. 1997 Jun;68(6):582-90

31. William Becker, Burton E. Becker. Treatment of mandibular 3-wall intrabony defects by flap debridement and expanded polytetrafluoroethylene barrier membranes. Long-term evaluation of 32 treated patients. *J Periodontol*. 1993;64:1138-1144

Legends

Table 1. Pre-surgery characteristics for intrabony defect (mm, n=)
PD: probing depth; CAL: clinical attachment level; GR: gingival recession; GI: gingival index; PI: plaque index

Table 2. Changes in clinical parameters of healing response between baseline and 12 months post-surgery (mm)
PD: probing depth; CAL: clinical attachment level; GR: gingival recession

Table 3. Frequency distribution of CAL gains at 1 year
PD: probing depth; CAL: clinical attachment level; GR: gingival recession

Table 4. Post-surgery change in clinical parameters of healing response in exposure and no-exposure
PD: probing depth; CAL: clinical attachment level; GR: gingival recession

Figures

Fig 1. Radiograph taken prior to surgery

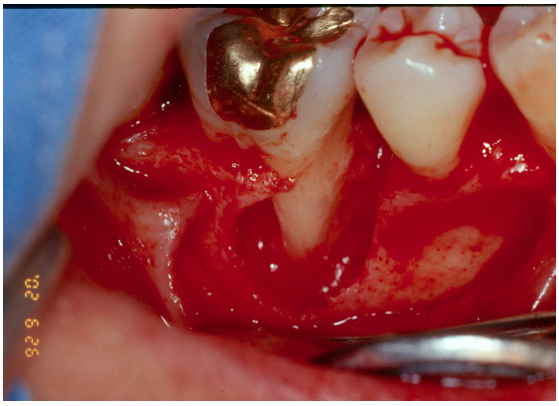

Fig 2. After removal of granulation tissue and root planning

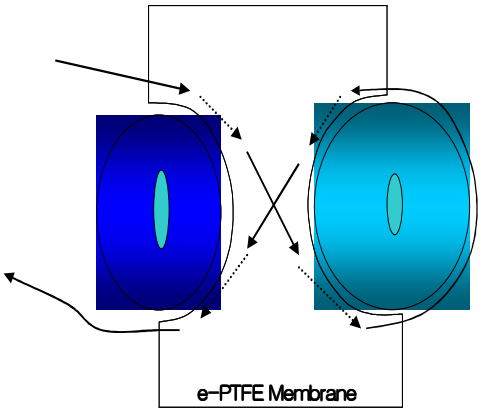

Fig 3. Schematic diagram of the specially designed space-providing suture.

Fig 4. Membrane adaptation

Fig 5. Radiograph taken at 1 year

Fig 6. 1-year follow-up

국문요약

Treatment outcome of Intrabony Defects with Guided Tissue Regeneration using Space-Providing Suturing Technique.

연세대학교 대학원 치의학과
지도 **김창성** 교수
이 은 영

이 연구의 목적은 특별히 고안된 suture technique을 기존 GTR membrane함께 사용했을 때 space-provision이 얼마나 개선 되는지 알아보고, intrabony defect에 사용했을 때의 1년 후 임상 결과를 평가하는 것이다. 28명의 환자에서 clinical attachment level (CAL)과 probing depth (PD)가 각각 6mm이상인 34개의 interproximal intrabony defect를 골라 무작위로 두 치료 그룹 중 하나로 분류하였다. 실험군은 인접면 결손부를 치은박리 소파 한 뒤 expanded polytetrafluoroethylene (ePTFE) membranes을 space-providing suture technique으로 치아에 고정하였다. 대조군은 치은 박리 소파술만을 사용하여 치료하였다. 1년간의 관찰기간동안 환자들은 infection control program을 받았고 술 후 첫 6주 간은 매주, 그리고 다음 12개월은 세 달에 한 번씩 전문적인 치면 세마를 받았다.

치료의 결과는 다음과 같다. 1) 실험군 대조군 모두에서 술 후 1년의

clinical attachment level (CAL)과 probing depth (PD)가 유의성 있게 개선되었다. 2) clinical attachment level (CAL)은 실험군이 대조군 보다 유의성 있게 더 큰 증가를 보였다. (실험군: 4.06mm±1.60mm, 대조군: 2.53mm±1.94mm, $p<0.0174$) 3) probing depth (PD)은 실험군이 대조군 보다 유의성 있게 더 큰 감소를 보였다. (실험군: 4.35± 1.46mm, 대조군: 2.53± 1.28mm, $p<0.0005$)

결론적으로 expanded polytetrafluoroethylene (ePTFE) membranes을 space-providing suture technique으로 고정시키는 방법은 술 후 1년의 clinical attachment level (CAL)과 probing depth (PD)에서 치은 박리소파술보다 임상적으로 더 우수한 결과를 보였다.

Key Words: Guided Tissue Regeneration; polytetrafluoroethylene (ePTFE) membranes; intrabony defect; space-providing suture