Change of lower facial contour with unilateral botulinum toxin injection in different facial asymmetry types using posteroanterior cephalogram

Ju Hyun Park

Department of Dental Science

The Graduate School, Yonsei University

Change of lower facial contour with unilateral botulinum toxin injection in different facial asymmetry types using posteroanterior cephalogram

Directed by Professor Seong Taek Kim, D.D.S., Ph.D.

The Doctoral Dissertation

submitted to the Department of Dental Science,

the Graduate School of Yonsei University

in partial fulfillment of the requirements for the degree of

Doctor of Philosophy in Dental Science

Ju Hyun Park

December 2013

This certifies that the doctoral dissertation

of Ju Hyun Park is approved.

Thesis Supervisor : Seong Taek Kim

Thesis Committee Member : Jong-Hoon Choi

Thesis Committee Member : Kee-Deog Kim

Thesis Committee Member : Hyung Seog Yu

Thesis Committee Member : Hyung Joon Ahn

The Graduate School

Yonsei University

December 2013

감사의 글

본 논문이 마무리되기까지 기나긴 학위 과정 동안 부족한 저를 이끌어주신 여러분께 지면으로나마 감사의 인사를 드리려 합니다.

박사과정을 무사히 마치고 논문의 시작부터 마무리에 이르기까지 세심한 지도와 아낌없는 격려로 이끌어주신 김성택 지도교수님께 먼저 깊은 감사를 드립니다. 그리고 소중한 조언과 관심으로 지속적으로 저를 사랑으로 이끌어 주신 최종훈 교수님께도 존경과 감사를 바칩니다. 또한 저의 논문 심사를 깊은 관심으로 맡아주시고, 연구에 대한 자세와 방향을 일깨워 주셨던 김기덕 교수님과 유형석 교수님, 줄곧 관심과 애정을 가지고 이끌어 주신 안형준 교수님께도 깊은 감사의 인사를 드립니다.

연구 결과를 정리하여 논문으로 만드는데 많은 도움을 준 후배 김지현 선생과 여러 가지로 바쁜 수련의 생활 중에도 싫은 내색 없이 실무적으로 많은 도움을 준 정아영 전공의와 다른 의국원 여러분에게도 감사드립니다.

생각만으로도 언제나 따뜻한 위안이 되어주는 사랑하는 동생들, 소현이, 재완이와, 마지막으로 무한한 사랑과 신뢰로 저를 보살펴 주시고 언제나 제 편이 되어 힘을 주시는 아버지와 어머니께 진심으로 감사와 사랑을 전합니다.

2013 년 12 월

저자 씀

TABLE OF CONTENTS

LIST OF FIGURES

LIST OF TABLES

Abstract

Change of lower facial contour with unilateral botulinum toxin injection in different facial asymmetry types using posteroanterior cephalogram

Ju Hyun Park

Department of Oral Medicine / Dental Science

The Graduate School, Yonsei University

(Directed by Professor Seong Taek Kim, D.D.S., Ph.D.)

Recently, interest of facial asymmetry has been considered increasingly, so people who want to correct that cosmetically visit hospital gradually. The awareness of them have been increased, even patients with mild facial asymmetry have been increased. With medical development, treatments of these facial asymmetry have been more various and simple gradually. Especially, botulinum toxin type A therapy is relatively simple and aesthetically effective for bilateral hypertrophy of masseters or unilateral hypertrophy of masseter muscle inducing facial asymmetry. It was known that the efficacy of botulinum toxin type A was evaluated using three dimensional (3D) laser scan, and it was effective for the facial asymmetry. We assumed that if the effect is different according to the facial asymmetry type after analysis, we can predict the proper effect of treatment. The purpose

of this study is to suggest a simple guideline for unilateral injection of botulinum toxin type A in facial asymmetry patients using posteroanterior cephalogram as a method for analysis.

The volume and bulkiest height of lower face of 16 facial asymmetry patients were measured with 3D laser scan before 25 units of botulinum toxin type A injected unilaterally. In same way, the volume and bulkiest height of lower face were measured 4, 8, 12 weeks after injection and superposed 3D laser scan of before injection, and then changed volume and bulkiest height were determined. We classified them into two types according the deviation of menton from midsagittal reference line in posteroanterior cephalogram. When the deviation was less than 3 mm, those subjects were classified into “Type I”. When the deviation was more than 3 mm, those subjects were classified into “Type II”.

The volume and bulkiest height of lower face of the injected sides were statistically decreased with time in both types. And there were statistically differences between the injected and noninjected sides at each time point. In type I, the volume and bulkiest height of lower face were more decreased significantly than type II. Considering the results of our study, it is thought that when the menton deviation is less than 3 mm, botulinum toxin type A as the treatment of facial asymmetry is more effective.

Keywords: botulinum toxin type A, facial asymmetry, posteroanterior cephalogram, menton deviation, three dimensional laser scan

Change of lower facial contour with unilateral botulinum toxin injection in different facial asymmetry types using posteroanterior cephalogram

Ju Hyun Park

Department of Dental Science

The Graduate School, Yonsei University

(Directed by Professor Seong Taek Kim, D.D.S., Ph.D.)

I. INTRODUCTION

Traditionally attention to appearance, aesthetic interest has been important matter for human. Especially Asian people reportedly tend to prefer oval and almond-shaped faces and dislike a square, wide-looking jaw (Satoh K, 1998). With ethnic characteristics (e.g., prominence of the gonial angle), contouring of lower facial area is a relatively common esthetic procedure among Asians. Interest of facial asymmetry has been considered increasingly, so people who want to correct that cosmetically visit hospital gradually. Previously most of them were severe cases, such as maxillofacial deformity or skeletal discrepancy. But recently the awareness of them have been

increased, patients with mild facial asymmetry have been increased. With medical development, treatments of these facial asymmetry have been more various and simple gradually.

Up to now, there have been two main categories for lower facial contouring treatment, surgery and conservative treatment. In the past, many clinicians focused on surgical interventions such as resection of the angle or body of the mandible, modeling ostectomy in the region of the mandibular gonial angle, and partial surgical resection of the masseter muscle bulk (Baek SM et al., 1989; Satoh K, 1998). However such surgical procedures had many risk, including postoperative pain, scarring, swelling, hematoma, and damaging the facial nerve and adjacent structures (Beckers HL, 1977). So increasingly patients and clinicians tend to approach to more safe and conservative therapies compared with surgical treatment. In the conservative approach, there are occlusal splints, the systemic administration of muscle relaxants or injection of botulinum toxin type A (BoNT-A) to reduce the muscular hyperactivity (von Lindern JJ, 2001; Kim NH et al., 2005).

Above all, BoNT-A therapy is relatively simple and aesthetically effective for bilateral hypertrophy of masseters or unilateral hypertrophy of masseter muscle inducing facial asymmetry. Since BoNT-A in treating masseteric hypertrophy for cosmetic use was first introduced in 1994, there have been many clinical studies about the efficacy of treatment using photography, ultrasonography, and computed tomography (CT) (Moore AP et al., 1994; von Lindern JJ et al., 2001; To EW et al., 2001; Kim HJ et al., 2003). Recently, newly developed tools, such as three-dimensional (3D) laser scan, have been used to evaluate the efficacy of BoNT-A by measuring changes in the external facial contours (Lee CJ et al., 2007). Shim et al (2012) reported the efficacy of BoNT-A on lower facial contouring using 3D laser scan. And also there are several studies about its efficacy to facial asymmetry. Sadiq et al (2012) injected BoNT-A into the normal contralateral smile muscles in facial nerve palsy to weaken them and the improvement in symmetry was observed by both patients and clinician. Also Cha et al (2013) reported that

unilateral BoNT-A injection appears to be an effective esthetic treatment for patients with muscle-induced facial asymmetry.

Meanwhile, various possible factors can be associated with characteristics of facial asymmetry (Bishara SE et al., 1994; Cohen MM, 1995). Common possible causes are asymmetric underlying jaw bone or hypertrophic masseter muscle, such as skeletal dysplasia of jaw or facial structures, mandibular retrognathia and masticatory muscle hyperactivity. Other causal factors are compensatory and stress hyperactivity by mandibular functional shift or deflective contacts. Trauma of jaw region, parafunctions influencing facial morphology and changes in the proprioceptors have been also considered. As these described different etiologic factors, there have been several analyses and classifications for facial asymmetry, and we assumed that the effect of BoNT-A would different according to different types of facial asymmetry.

There are various tools in diagnosis and classification on facial asymmetry (Bishara SE et al, 1994; Hwang HS et al., 2007). Among them, cephalometrics including posteroanterior cephalogram (PA cephalogram) are routine part of clinics and research in dentistry traditionally (Grummons DC et al., 2004). Especially, PA cephalograms inform important diagnostic structures and they are easily to take, so the cephalometric methods have been useful for diagnosis and treatment planning for facial asymmetry. Many studies have been conducted to examine and proved the reliability and validity of PA cephalograms. PA cephalometric analyses use horizontal and vertical reference lines for measuring dentofacial asymmetries. Various measurements have been suggested to determine the reference line and analyze the facial asymmetry, using PA cephalograms (Grummons DC et al., 1987; Ricketts RM et al., 2003). In common, the asymmetries are evaluated by comparing the measurements of corresponding structures from the right and left sides. Midline structures can also be used to assess asymmetry as deviation toward the right or the left side from the chosen reference line. According the degrees of deviation, we can analyze the facial asymmetry.

As mentioned earlier, it was known that the efficacy of BoNT-A was evaluated using 3D laser scan, and the BoNT-A therapy was effective for the facial asymmetry. We assumed that if the effect of BoNT-A is different according to the facial asymmetry type after analysis, we can predict the proper effect of treatment and better patient management. The purpose of this study is to suggest a simple guideline for unilateral injection of BoNT-A in facial asymmetry patients using PA cephalogram as a method for analysis.

II. SUBJECTS AND METHODS

1. Subjects

1.1. Subjects

16 subjects aged 17 to 38 (mean age 28.4 years, 6 male, 10 female) who complained of facial asymmetry were enrolled in this study. All subjects were registered voluntarily at a private practice. The subjects were given explanation and information about the established use and fundamental principles of botulinum toxin treatment and an information sheet describing its adverse effects. All subjects were free to withdraw from the treatment at any time. Exclusion criteria were pregnancy (or pregnancy attempt), a history of drug allergy or any other serious medical illnesses. Before the injection, all subjects were taken PA cephalograms for analysis and classification of facial asymmetry.

1.2. Classification of facial asymmetry using posteroanterior (PA) cephalogram

PA cephalograms were recorded with head fixed by ear rods and with the Frankfort horizontal plane in parallel to the floor. In this study, we established the skeletal midsagittal reference line (MSR) from crista galli (CG) vertically through anterior nasal spine (ANS) and extended inferiorly beneath the chin, which has been known as high reproducibility for identification (Grummon DC, 1987). Growth of mandible tends to have long duration than any other regions of maxillofacial area, and to be influenced more genetic, environmental factors. So asymmetries in mandible are common than in maxilla (Haraguchi et al., 2002). Especially menton (Me) is located at the most inferior area and it is known that perception of patients in facial asymmetry is likely to be high according to deviation of menton (Hewitt AB, 1975). So in this study, we selected menton as reference point of measurements for facial asymmetry.

We classified them into 2 types according the deviation of menton from MSR. When the deviation of menton was less than 3 mm, those subjects were classified into “Type I”. When the deviation of menton was more than 3 mm, those subjects were classified into “Type II” (Figure 1).

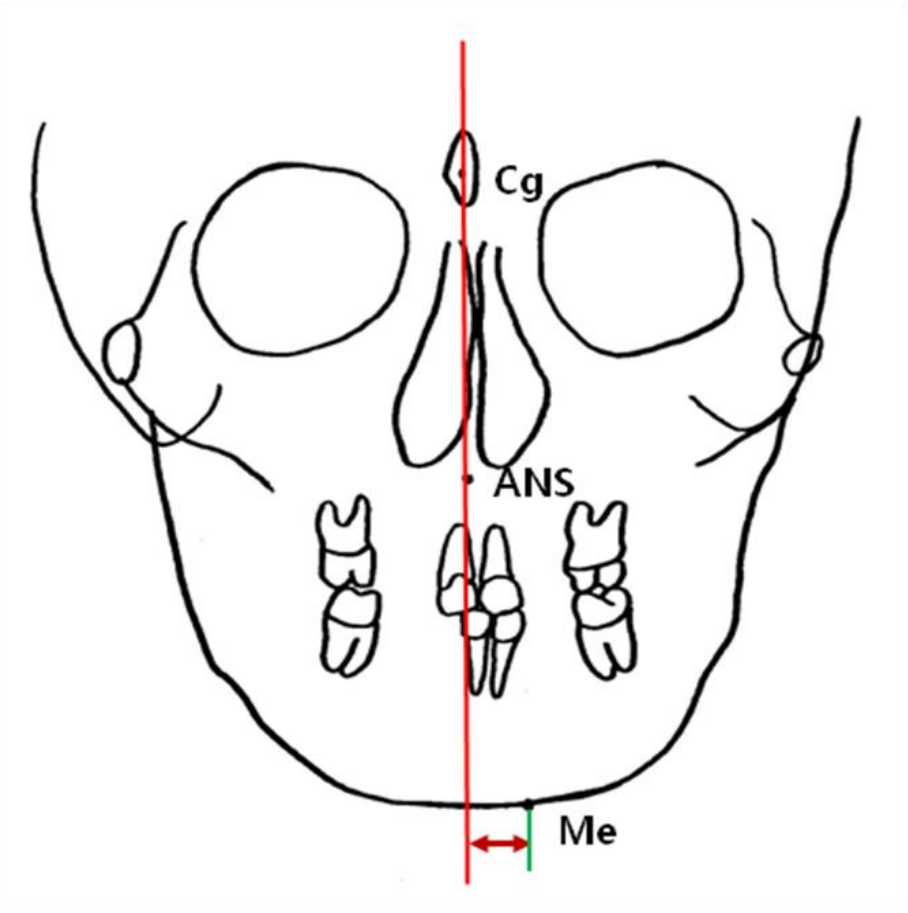

Figure 1. Landmarks in posteroanterior cephalogram

2. Methods

2.1. Injection of botulinum toxin type A

BoNT-A (Botulax® , Hugel Inc., Chuncheon, Republic of Korea) containing 100 units supplied as a freeze-dried powder was reconstituted with 2ml of a sterile saline to yield a concentration of 5 units per 0.1 ml. The reconstituted drug was used immediately.

A total of 25 units of BoNT-A was injected into prominent side of masseter muscle unilaterally by means of a 1-ml syringe with a 29-gauge, 1/2-inch-long needle. The most prominent area of masseter muscle was identified using palpation. It was injected into two points separated by 1 cm at the center of the lower one-third of the identified masseter muscle, which is the safest and the most efficient injection site for BoNT-A.

2.2. Three-dimensional (3D) laser scan

The effect of BoNT-A was evaluated by measuring differences of the volume and bulkiest height of lower face bilaterally, on the BoNT-A injected side and noninjected side, with 3D laser scan 4 times; before the injection and 4, 8, and 12 weeks after the injection. The taken scan images provide more objective measurements of the external facial contours than any other tools. In this study, we used Vivid 9i® laser scanner (Minolta, Tokyo, Japan), which emits a harmless Class I laser beam, rated its safe for the eyes by the U.S. Food and Drug Administration. A technical expert performed all of the scans, and all images were saved on a personal computer and merged into single 3D facial images using image analysis software (Rapidform® 2004, Inus Technology, Seoul, Korea). The border of lower face was delineated using the following reference points: ala, cheilion, labral inferior, soft-tissue pogonion, soft-tissue menton, soft-tissue gonion, and tragion (Figure 2). Difference of the volume and bulkiest height of lower face were measured by superposition of images (Figure 3, 4). At each time, photographs were also taken. In this study, 1 observer performed all measurements, because most studies reported that intraobserver error is smaller than interobserver error.



Figure 2. The border of lower face

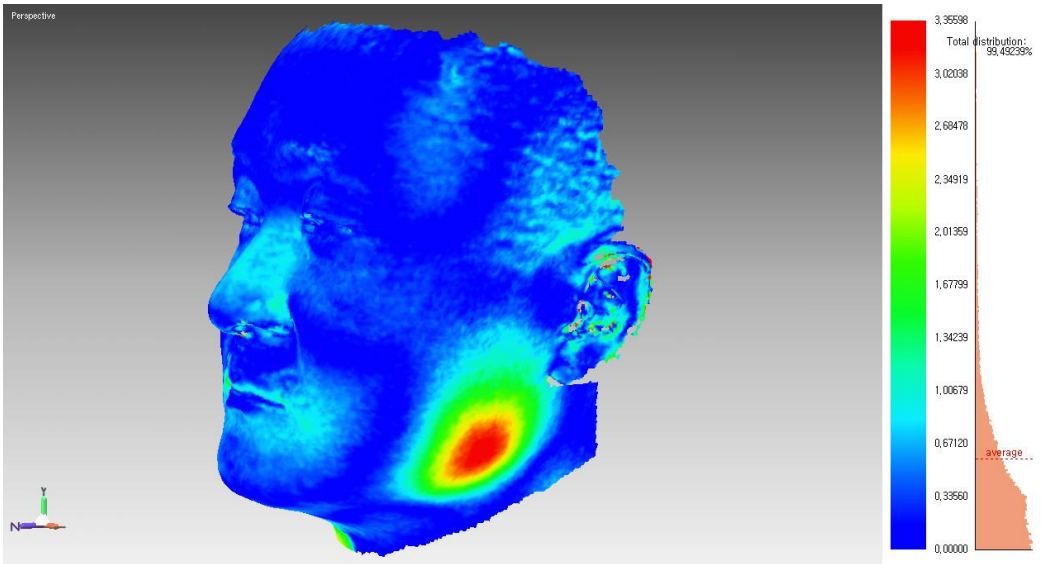

Figure 3. Difference of the volume and bulkiest height of lower face



Figure 4. Measurement of difference of the bulkiest height

2.3. Statistical analysis

Statistical analyses were performed to compare the differences of the volume and bulkiest height of lower face between the injected and noninjected sides. In this study, we used paired t test for comparison of mean change in volume and bulkiest height of the lower face at each time point in each type. The independent t test was used for comparison of mean change between the injected and noninjected sides at each time point. The other independent t test was used for comparison of mean change between two types, to compare which type is more effective to BoNT-A treatment. The difference was considered statistically significant if the p value was less than 0.05.

III. RESULTS

After analysis and classification of facial asymmetry using PA cephalograms, 7 subjects were included in type I and 9 subjects were included in type II.

Figure 5, 6 present the mean change of the volume and bulkiest height of lower face measured before injection, 4, 8, and 12 weeks after the injection. From the data, we found that the volume and bulkiest height in both types decreased with time in the injected side. There were significant differences at each time point in the injected side ($p < .05$). However in the noninjected side, no statistically significant difference was shown.

In Table 1, 2, they showed significant differences ($p < .05$) of the volume and bulkiest height of the lower face between the injected and noninjected sides at each time point in both types.

In type I, greater changes of the reduction in the volume and bulkiest height were seen than type II (Table 3). There was significant difference between two types ($p < .05$).

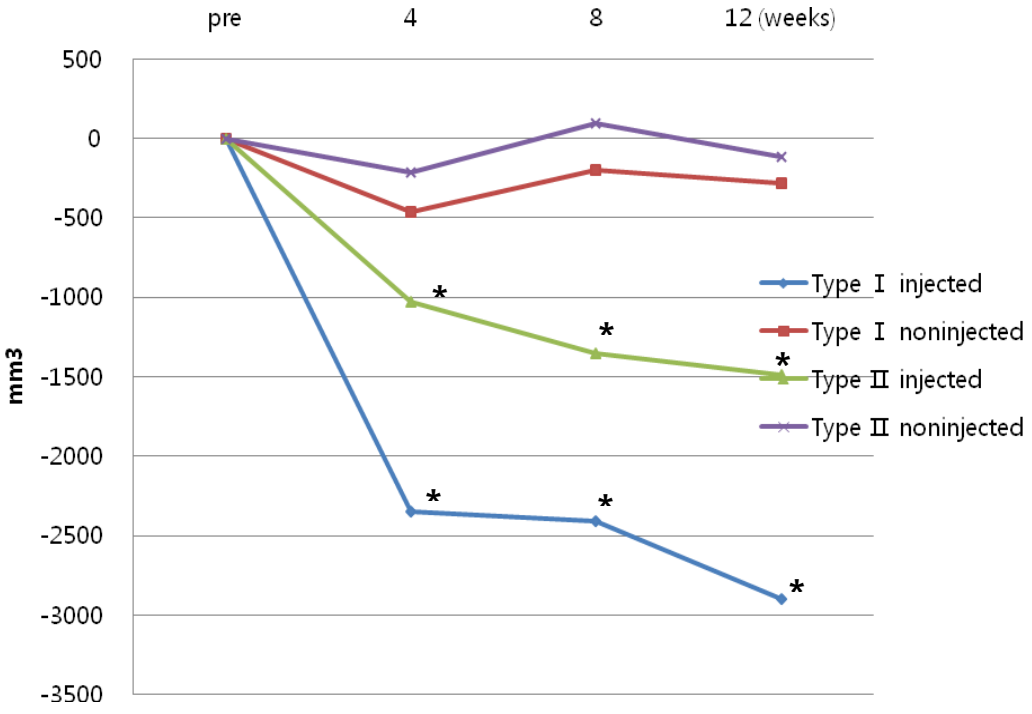

Figure 5. Mean change in the volume of lower face at each time point (*p < .05)

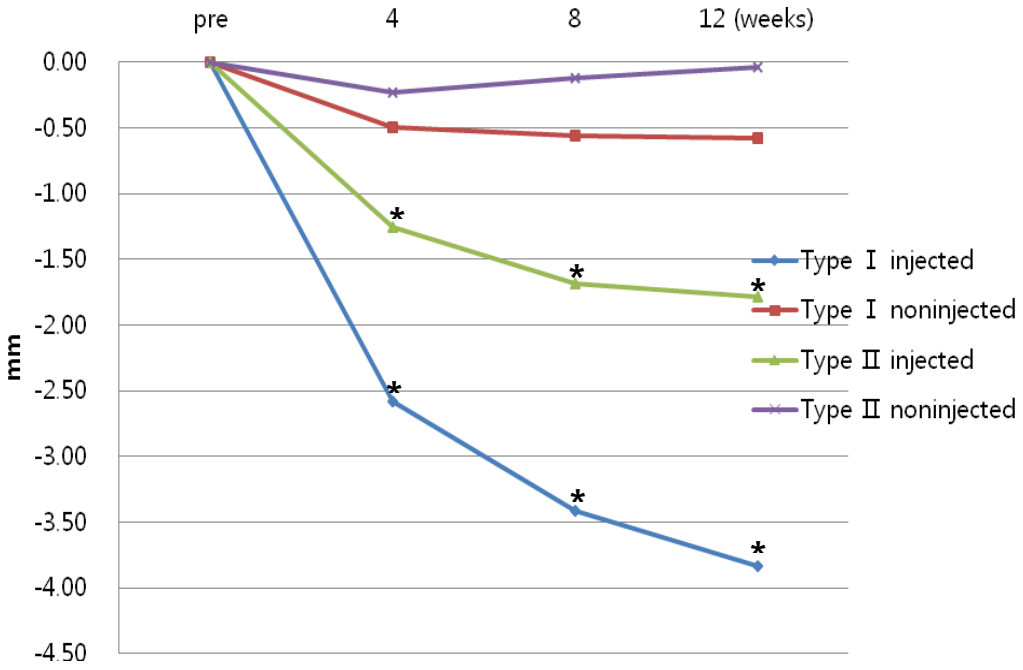

Figure 6. Mean change in the bulkiest height of lower face at each time point (*p < .05)

Table 1. Mean change of the volume and bulkiest height at each time point in type I

			4 weeks after	8 weeks after	12 weeks after
Volume (mm^3)	Mean Δ ± Std. Deviation	injected	-2351 ± 1304	-2411 ± 1020	-2898 ± 1355
		noninjected	-463 ± 653	-196 ± 609	-283 ± 736
	t-value		-3.42*	-4.93*	-4.49*
Bulkiest height (mm)	Mean Δ ± Std. Deviation	injected	-2.58 ± 1.07	-3.41 ± 1.08	-3.83 ± 0.70
		noninjected	-0.49 ± 0.52	-0.56 ± 0.46	-0.57 ± 0.63
	t-value		-4.64*	-6.44*	-9.12*

Independent t test: comparison of mean change between the injected and noninjected sides (*$p < .05$)

Table 2. Mean change of the volume and bulkiest height at each time point in type II

			4 weeks after	8 weeks after	12 weeks after
Volume (mm^3)	Mean Δ ± Std. Deviation	injected	-1032 ± 527	-1352 ± 669	-1490 ± 751
		noninjected	-216 ± 666	92 ± 1035	-119 ± 664
	t-value		-2.88*	-3.52*	-4.16*
Bulkiest height (mm)	Mean Δ ± Std. Deviation	injected	-1.25 ± 0.52	-1.69 ± 0.72	-1.79 ± 0.59
		noninjected	-0.23 ± 0.50	-0.12 ± 0.66	-0.04 ± 0.50
	t-value		-4.21*	-4.82*	-6.78*

Independent t test: Comparison of mean change between the injected and noninjected sides (*$p < .05$)

Table 3. Comparison of mean change in volume and bulkiest height between two types

		Type	4 weeks after	8 weeks after	12 weeks after
Volume (mm^3)	Mean Δ ± Std. Deviation	I	-2351 ± 1304	-2411 ± 1020	-2898 ± 1355
		II	-1032 ± 527	-1352 ± 669	-1490 ± 751
	t-value		-2.52*	-2.51*	-2.65*
Bulkiest height (mm)		I	-2.58 ± 1.07	-3.41 ± 1.08	-3.83 ± 0.70
		II	-1.25 ± 0.52	-1.69 ± 0.72	-1.79 ± 0.59
	t-value		-3.02*	-3.84*	-6.35*

Independent t test: Comparison of mean change between two types, to compare which type is more effective to BoNT-A treatment (*$p < .05$)

IV. DISCUSSION

In this study, we used BoNT-A as a treatment for the facial asymmetry. Botulinum toxins are exotoxins of *Clostridium botulinum*, a Gram-positive, anaerobic organism. The mechanism of toxin is the inhibition release of acetylcholine into the neuromuscular junction, leading to paralysis and temporary partial denervation in the area of the injection (dressler D et al., 2005). In general, BoNT-A has been used as a treatment in various neuromuscular disorders, such as strabismus, hemifacial spasm, and blepharospasm (Traba Lopez A et al., 2001). Most side effects of injecting BoNT-A into hypertrophic masseter muscles is muscle weakness, swelling, bruising, and xerostomia, but they are mild and transient. To avoid these side effects and establish the best injection site, we should have understanding of the location of anatomic structures near the masseter muscle, such as marginal mandibular branch of the facial nerve, facial artery, facial vein, and parotid gland (Hu KS et al., 2010). In this study, there were no complications with BoNT-A injection. Thus, the treatment of hypertrophy of the masseter muscle with BoNT-A represented a noninvasive and simple therapeutic method.

In assessing facial asymmetry with menton, different deviations were investigated. More than 2 mm deviation of menton from the midline was assumed to be asymmetric (Haraguchi et al., 2002). And a menton of more than 3 mm deviation was investigated as a value of facial asymmetry (Chbib et al., 1981). In several studies, menton of 4 mm deviation was employed as a critical distance to facial asymmetry (Van Keulen et al., 2004; Masuoka et al., 2007). They assumed that people were sensitive to about 4 mm in recognizing clinically significant facial asymmetry. Slight facial asymmetry would be common biological variation in normal subjects (Shah SM et al., 1978). In this study, we investigated for subjects who perceived facial

asymmetry themselves already. So we classified as a concept of mild or severe facial asymmetry with 3 mm of menton deviation.

According to the analysis and classification of facial asymmetry, the etiology and proper treatment would be different for each group. By 3 mm of menton deviation, we divided two types for facial asymmetry in this study. Subjects of type I tended to have mild facial asymmetry. They seemed to be within normal limits in skeletal pattern or have little dental asymmetry. Asymmetry in this type would be influenced by unilateral mastication. Or generally this type showed different volume or shape of mandibular body. If needed, plastic surgery or conservative treatments were suggested for this type of asymmetry. Subjects of type II were believed to have asymmetric mandibular or condylar growth (Bruce RA et al., 1968). For this type of asymmetry, it was suggested that growth modification with orthopedic appliances in growing stage, or surgical correction in adult would be helpful (Obwegeser HL et al., 1986; Vig PS et al., 1986). Asymmetry in this type also would be influenced by unilateral mastication. The different chewing force would affect the morphology of the jaw and face, so the marked masticatory muscle activity seemed to have shorter height of ramus (Tay DK., 1994). In this case, correction of unilateral mastication would be treatment. And it seemed to be resulted from the functional shift of the mandible at maximum intercuspation by occlusal interferences, such as an abnormal premature contact, crossbite or an anteriorly displaced disc without reduction of temporomandibular joint (Joondeph DR, 2000). Occlusal adjustment, orthodontic treatment, or occlusal splints would be needed for this type of asymmetry.

There were some limitations in this study. We analyzed the facial asymmetry with PA cehpalogram, that was two dimensional cephalometric radiography, but we measured the volume and bulkiest height of lower face with 3D laser scan. There would be difference between skeletal facial asymmetry and actual facial asymmetry, thus analysis of facial asymmetry with 3D tools is needed in future study. After muscle atrophy as the effect of BoNT-A, new neuromuscular

synapses can be formed by sprouting of presynaptic axons. And thus the recovery of muscle volume can be occurred (Smyth AG, 1994). For better understanding of the effect of BoNT-A, the follow-up results of change in volume and bulkiest height would be required for a minimum of 12 months. It could be investigated that in which type has more amount of recovery. In this study, the volume and bulkiest height of lower face were more decreased in type I. It was supposed that skeletal factors were more related to asymmetry pattern than muscular factors in type II, on the assumption that the amount of deviation was equal between two types. The measurement of muscle thickness using ultrasonography or computed tomography would be needed for another classification of asymmetry. And future studies would be needed to include more subjects for statistical difference of the results.

From the results of this study, it was recognized that the volume and bulkiest height of lower face of the injected sides were statistically decreased with time in both types. And there were statistically differences between the injected and noninjected sides at each time point as with earlier studies. In type I, when the menton deviation from MSR was less than 3 mm, the volume and bulkiest height of the lower face were more decreased significantly than type II. Considering the results of our study, it is thought that when the menton deviation from MSR is less than 3 mm, BoNT-A as the treatment of facial asymmetry is more effective.

V. CONCLUSION

The volume and bulkiest height of lower face in both types decreased with time in the injected side. There were significant differences at each time point in the injected side, but in the noninjected side, no statistically significant difference was shown. Significant differences of the volume and bulkiest height of lower face were shown between the injected and noninjected sides at each time point in both types. In type I, when the menton deviation from MSR was less than 3 mm, the volume and bulkiest height of lower face were more decreased significantly than type II.

Considering the results of our study, it is thought that when the menton deviation from MSR is less than 3 mm, BoNT-A as the treatment of facial asymmetry is more effective.

REFERENCES

Baek SM, Kim SS, Bindiger A: The prominent mandibular angle: preoperative management, operative technique, and results in 42 patients. *Plast Reconstr Surg* 83(2): 272-280, 1989.

Beckers HL: Masseteric muscle hypertrophy and its intraoral surgical correction. *J maxillofac Surg* 5(1): 28-35, 1977.

Bishara SE, Burkey PS, Kharouf JG: Dental and facial asymmetries: a review. *Angle Orthod* 64: 89-98, 1994.

Bruce RA, Hayward JR: Condylar hyperplasia and mandibular asymmetry: a review. *J Oral Surg* 26: 281-290, 1968.

Cha YR, Kim YG, Kim JH, Kim ST: Effect of unilateral injection of botulinum toxin on lower facial asymmetry as evaluated using three-dimensional laser scanning. *Dermatol Surg* 39(6): 900-906, 2013.

Chebib FS, Chamma AM: Indices of craniofacial asymmetry. *Angle Orthod* 51(3): 214-226, 1981.

Cohen MM: Perspectives on craniofacial asymmetry. III. Common and/or well-known causes of asymmetry. *Int J Oral Maxillofac Surg* 24(2): 127-233, 1995.

Dressler D, Saberi FA: Botulinum toxin: mechanisms of action. *Eur Neurol* 53: 3–9, 2005.

Grummons DC, Kappeyne van de coppello MA: A frontal asymmetry analysis. *J Clin Orthod* 21(7): 448-465, 1987.

Grummons DC, Ricketts RM: Frontal cephalometrics: practical applications, part 2. *World J Orthod* 5(2): 99-119, 2004.

Haraguchi S, Takada K, Yasuda Y: Facial asymmetry in subjects with skeletal Class III deformity. *Angle Orthod* 72(1): 28-35, 2002.

Hewitt AB: A radiographic study of facial asymmetry. *Br J Orthod* 2(1): 37-40, 1975.

Hu KS, Kim ST, Hur MS, Park JH, Song WC, Koh KS, Kim HJ: Topography of the masseter muscle in relation to treatment with botulinum toxin type A. *Oral Surg Oral Med Oral Pathol Oral Radiol Endod* 110(2): 167-171, 2010.

Hwang HS, Youn IS, Lee KH, Lim HJ: Classification of facial asymmetry by cluster analysis. *Am J Orthod Dentofacial Orthop* 132(3): 279.e1-6, 2007.

Joondeph DR: Mysteries of asymmetries. *Am J Orthod Dentofacial Orthop* 117(5): 577-579, 2000.

Kim HJ, Yum KW, Lee SS, Heo MS, Seo K: Effects of botulinum toxin type A on bilateral masseteric hypertrophy evaluated with computed tomographic measurement. *Dermatol Surg* 29(5): 484–489, 2003.

Kim NH, Chung JH, Park RH, Park JB: The use of botulinum toxin type A in aesthetic mandibular contouring. *Plast Reconstr Surg* 115(3): 919-930, 2005.

Lee CJ, Kim SG, Kim YJ, Han JY, Choi SH, Lee SI: Electrophysiologic change and facial contour following botulinum toxin A injection in square faces. *Plast Reconstr Surg* 120(3): 769–778, 2007.

Masuoka N, Muramatsu A, Ariji Y, Nawa H, Goto S, Ariji E: Discriminative thresholds of cephalometric indexes in the subjective evaluation of facial asymmetry. *Am J Orthod Dentofacial Orthop* 131(5): 609-613, 2007.

Moore AP, Wood GD: The medical management of masseteric hypertrophy with botulinum toxin type A. Br Oral *Maxillofac Surg* 32: 26–28, 1994.

Obwegeser HL, Makek MS: Hemimandibular hyperplasia—hemimandibular elongation. *J Maxillofac Surg* 14: 183-208, 1986.

Ricketts RM, Grummons D: Frontal cephalometrics: practical applications, part 1. *World J Orthod* 4: 297-316, 2003.

Sadiq SA, Khwaja S, Saeed SR: Botulinum toxin to improve lower facial symmetry in facial nerve palsy. *Eye* 26(11): 1431-1436, 2012.

Satoh K: Mandibular contouring surgery by angular contouring combined with genioplasty in orientals. *Plast Reconstr Surg* 101(2): 461-472, 1998.

Shah SM, Joshi MR: An assessment of asymmetry in the normal craniofacial complex. *Angle Orthod* 48:141-148, 1978.

Shim WH, Yoon SH, Park JH, Choi YC: Effect of botulinum toxin type A injection on lower facial contouring evaluated using a three-dimensional laser scan. *Dermatol* Surg 36(Suppl 4): 2161–2166, 2010.

Smyth AG: Botulinum toxin treatment of bilateral masseteric hypertrophy. *Br J Oral maxillofac Surg* 32(1): 29-33, 1994.

Tay DK: Physiognomy in the classification of individuals with a lateral preference in mastication. *J Orofac Pain* 8: 61-72, 1994.

To EW, Ahuja AT, Ho WS, King WW, Wong WK, Pang PC, Hui AC: A prospective study of the effect of botulinum toxin A on masseteric muscle hypertrophy with ultrasonographic and electromyographic measurement. *Br J Plast Surg* 54(3): 197–200, 2001.

Traba Lopez A, Esteban A: Botulinum toxin in motor disorders: practical considerations with emphasis on interventional neurophysiology. *Neurophysiol Clin* 31: 220–229, 2001.

van Keulen C, Martens G, Dermaut L: Unilateral posterior crossbite and chin deviation: is there a correlation? *Eur J Orthod* 26(3): 283-288, 2004.

Vig PS, Vig KW: Hybrid appliances: a component approach to dentofacial orthopedics. *Am J Orthod Dentofacial Orthop* 90:273-285, 1986.

von Lindern JJ, Niederhagen B, Appel T, Bergé S, Reich RH: Type A botulinum toxin for the treatment of hypertrophy of the masseter and temporal muscles: an alternative treatment. *Plast Reconstr Surg* 107(2): 327–332, 2001.

ABSTRACT (in Korean)

후전방 두부방사선 사진을 이용하여 분석한 비대칭 타입에 따른 편측 보툴리눔독소 주사에 의한 하안모 변화

<지도 김 성 택 교수>

연세대학교 대학원 치의학과

박 주 현

외모에 대한 관심이 증가함에 따라 안모비대칭을 주소로 내원하는 환자가 증가하고 있고, 경미한 비대칭도 해결하기를 원하는 경우도 많아지고 있다. 주로 수술적인 방법을 행하던 과거와는 달리, 교근에 주입하는 보툴리눔독소 주사가 덜 침습적이고 간단한 치료로 점점 많이 시행되고 있다. 기존 연구들을 통해 보툴리눔독소 주사가 안모비대칭의 개선에 도움이 되고, 이의 효과는 삼차원 레이저스캐너를 통하여 확인할 수 있음을 알 수 있었다. 안모비대칭을 분석하여 타입 별로 분류했을 경우, 보툴리눔독소의 효과가 타입 별로 효과가 다르다면 환자에게 그 효과를 미리 예측하여 설명할 수 있을 것이다. 이 연구의 목적은 후전방 두부방사선 사진을

분석하여 안모비대칭을 분류한 후, 안모비대칭 환자에서 보툴리눔독소를 편측으로 주입하고, 삼차원 레이저스캐너를 이용하여 안모의 부피와 두께의 변화를 측정하고자 하였다. 삼차원 레이저스캐너를 이용하여 술 전에 안모비대칭 환자 16명의 하안모의 부피와 두께를 측정한 후, 더 풍융한 쪽에 편측으로 보툴리눔 A형 독소 주사 25U이 주사되었다. 주사 4주, 8주, 12주 후 같은 방법으로 하안모의 부피와 두께를 측정한 뒤 술 전의 삼차원 사진과 중첩하여 변화된 부피와 두께를 비교하였다. 후전방 두부방사선 사진에서 수직기준선으로부터 멘톤의 거리를 기준으로 그 거리가 3 mm 미만일 경우 타입 I, 3 mm 이상일 경우 타입 II, 두 타입으로 분류하였다.

두 타입 모두 주사한 쪽의 부피와 두께는 술 전에 비해 보툴리눔독소 주사 4주, 8주, 12주 후 현저히 줄어들었으며 통계학적으로 유의미한 결과를 보였다. 반면 주사 안 한 쪽의 부피와 두께는 특기할 변화가 없었다. 두 타입을 비교했을 때, 타입 I 에서 타입 II 에 비해 부피와 두께가 유의성있게 더 큰 폭으로 감소하였다. 보툴리눔 독소 주사를 통한 안모비대칭 치료에서 멘톤의 변위가 3 mm 이상보다 3 mm 미만일 경우 좀 더 좋은 적응증으로 사료된다.

핵심되는 말: 보툴리눔독소, 안모비대칭, 후전방 두부방사선 사진, 멘톤의 변위, 삼차원 레이저스캐너