Evaluation of skeletal and dentoalveolar changes after miniscrew assisted rapid palatal expansion in adults using cone-beam computed tomography

Jung Jin Park

The Graduate School

Yonsei University

Department of Dental Science

Evaluation of skeletal and dentoalveolar changes after miniscrew assisted rapid palatal expansion in adults using cone-beam computed tomography

A Dissertation Thesis

Submitted to the Department of Dental Science

and the Graduate School of Yonsei University

in partial fulfillment of the

requirements for the degree of

Doctor of Philosophy of Dental Science

Jung Jin Park

December 2013

This certifies that the dissertation thesis of

Jung Jin Park is approved.

_____

Thesis Supervisor: Young Chel Park

_____

Kee Joon Lee

_____

Jung Yul Cha

_____

Sang Hwy Lee

_____

Chang Seo Park

The Graduate School

Yonsei University

December 2013

감사의 글

부족한 저를 지도해주신 교수님들의 많은 가르침이 있었기에 이 논문이 있을 수 있었습니다. 논문이 완성되기까지 따뜻한 배려와 함께 세심한 지도와 격려를 아끼지 않으신 박영철 지도 교수님께 진심으로 감사드립니다. 논문이 완성될 때까지 지속적인 관심과 도움을 주셨던 박창서 교수님, 이상휘 교수님, 이기준 교수님, 차정열 교수님께 깊은 감사의 말씀을 올립니다. 또한 교정학을 공부할 수 있도록 기회를 주시고 인도해주신 백형선 교수님, 황충주 교수님, 김경호 교수님, 유형석 교수님, 정주령 교수님, 최윤정교수님께도 깊이 감사드립니다.

박사과정 동안 많은 도움을 주었던 의국원들, 졸업 후에도 격려해주고 조언해주었던 동기들과 학업 때문에 들를 때 마다 항상 반갑게 맞이해주던 직원 여러분께도 감사의 마음을 전합니다.

항상 변함없는 사랑과 믿음으로 격려해주시는 부모님과 한결 같은 기도로 응원해주시는 시부모님, 그리고 든든하게 뒤에서 지원해준 언니 내외, 서방님 내외, 남동생, 그리고 조카들에게도 이 자리를 빌어 깊은 감사의 마음을 전합니다. 또한 늘 곁에서 힘이 되어주고 물심양면으로 지원해준 사랑하는 남편과 아들 승규, 뱃속의 둘째 아이에게 고마운 마음을 전합니다.

마지막으로 미처 언급하지는 못했지만 제 곁에 계시는 모든 분들께 고마움과 사랑의 마음을 올립니다. 감사합니다.

2013년 12 월

박 정 진

Table of Contents

List of Figures

List of Tables

ABSTRACT

Evaluation of skeletal and dentoalveolar changes after miniscrew assisted rapid palatal expansion in adults using cone-beam computed tomography

The aim of this study was to evaluate the facial bone and dentoalveolar changes in young adult patients immediately after miniscrew assisted rapid palatal expansion (MARPE) treatment using cone-beam computed tomography (CBCT).

Experimental group was consisted of 14 adult patients (9 females, 5 males; mean age, 20.1±2.4 years; range, 16-26 years) with maxillary transverse deficiency and treated with MARPE. CBCT images were taken at pre-expansion (T1) and post expansion (T2).

1. After expansion (T2), there were statistically significant increases of skeletal and dentoalveolar measurements (zygoma width, nasal width, maxillary width, middle alveolus width, and cervical width) ($P<0.05$).

2. After expansion (T2), there were statistically significant increases in the width of the nasal cavity and basal bone of maxilla ($P<0.001$). Changes in 1st premolar area were higher than those in 1st molar area in both nasal cavity and basal bone of maxilla.

3. After expansion (T2), the amount of transverse changes was decreasing from the molar cervical width (C6−C6) to the zygoma width (Z−Z).

4. By MARPE expansion, midpalatal suture was opened in all subjects and expanded significantly combined with forward movement of the maxilla complex ($P < 0.05$).

5. There were significant increases in all transverse landmarks in maxillofacial complex except for spina nasalis. At the level of the alveolar bone crest, there was greater change at the ectomolare than at the ectocanine ($P < 0.01$).

The findings of this study suggested that MARPE is an effective method for correcting the insufficient transverse dimension of the dentition and the maxillary basal bone in young adults. Additional prospective studies with a greater number of subjects and long term stability of MARPE treatment should be followed.

Key words: maxillary transverse discrepancy, adult, miniscrew, RPE, midpalatal suture, 3D superimposition, CBCT

Evaluation of skeletal and dentoalveolar changes after miniscrew assisted rapid palatal expansion in adults using cone-beam computed tomography

Jung Jin Park

The Graduate School Yonsei University
Department of Dental Science
(Directed by Professor Young Chel Park, D.D.S., M.S.D., Ph.D)

I. Introduction

Rapid palatal expansion (RPE) has been widely used in orthodontics to increase the transverse dimension of maxilla in children since the mid 1960s.(da Silva Filho et al., 1995) RPE is routinely used to separate midpalatal suture and create skeletal orthopedic expansion.(Haas, 1970) Surgically assisted RPE (SARPE) is often used in adults, because of the increased resistance from the bony palate and zygomatic buttress.(Kokich, 1976; Shetty et al., 1994) However, SARPE has several limitations, including high cost, a complex treatment process, and surgical morbidity.(Alpern and Yurosko, 1987; Bays and Greco, 1992; Williams et al., 2012) Therefore, many efforts have been made to reduce the surgical risks and limitations.

Midpalatal suture may show obliteration during the juvenile period, but a marked degree of closure is rarely found until the third decade of life in histological studies.(Persson and Thilander, 1977; Stuart and Wiltshire, 2003) Conventional RPE would be totally successful in patients under 25 years, and 77.3% successful in patients over 25 years of age.(Knaup et al., 2004)

Conventional RPE can produce unwanted effects in adults, such as buccal crown tipping, root resorption, reduction of buccal bone thickness, inability of expansion, and marginal bone loss.(Langford and Sims, 1982; Odenrick et al., 1991; Rungcharassaeng et al., 2007) To minimize these unwanted effects, orthopedic expansion of basal bone would be needed.(Baysal et al., 2012; Capelozza Filho et al., 1996; Gurel et al., 2010; Thilander et al., 1983)

Nonsurgical RPE can be achieved through conventional, bone-anchored, and combination-type RPEs. Bone-anchored devices have been shown to result in successful expansion of maxilla.(Gerlach and Zahl, 2003; Ramieri et al., 2005) To ensure expansion of basal bone and maintain the separated bone in consolidation, Lee introduced a miniscrew-assisted RPE (MARPE).(Lee et al., 2010) Some bone-anchored RPE has been reported to do lateral osteotomy to facilitate the skeletal expansion.(Harzer et al., 2006; Ramieri et al., 2005; Tausche et al., 2007) MARPE required a placement of miniscrew under local infiltration anesthesia, and did not need to do osteotomy. MARPE could be an effective appliance to achieve adequate nonsurgical expansion for correcting of transverse maxillary deficiency in young adults.(Lee et al., 2010)

The treatment effect of RPE have been studied through various methods including finite element analysis(FEM)(Lee et al., 2009; Yu et al., 2007), laser holography(Pavlin and Vukicevic, 1984), photoelastic analysis(Lima et al., 2011), and a conventional radiographic examination.(Chamberland and Proffit, 2011; Lima Filho and de Oliveira Ruellas, 2008) Nevertheless the

skeletal and dentoalveolar effects of RPEs, including traditional RPE, bone-anchored RPE, and MARPE are not yet clearly understood in young adults.

Common ways of orthodontic treatment results are commonly analyzed with cephalometric radiographs (posteroanterior and lateral), occlusal radiographs, and dental casts. However there are some limitations with 3-dimensional subjects.

Cone-beam computed tomography (CBCT) has made it possible to examine the various aspects of the maxillofacial complex. CBCT have relatively low radiation dosages, and present a clear view of bony structures with minimal image distortion.(Mah et al., 2003) Additionally, structures or landmarks of maxillofacial complex which are not easily available on traditional two-dimensional (2D) imaging might now be identified.(Park et al., 2006) CBCT can be used to assess buccal bone height and buccal bone thickness with high accuracy and precision.(Timock et al., 2011) In this study, image registration and superimposition of the preoperative and postoperative 3D skull models were done with a point to point registration and a volumetric registration method for quantitative 3-dimensional assessment of skeletal and dentoalveolar changes after expansion with MARPE. (Cevidanes et al., 2011; Lagravere et al., 2010b; Lagravere et al., 2011)

The aim of this study was to evaluate the skeletal and dentoalveolar changes in young adult patients immediately after expansion with MARPE treatment using 3D images from CBCT.

II. Materials and methods

A. Subjects of study

The CBCT records of 14 subjects were obtained from the archives of the Orthodontic Department, Yonsei University (Seoul, Korea). The study sample was formed retrospectively using the records of 14 patients(9 females, 5 males; mean age, 20.1±2.4 years; range, 16-26 years) who required maxillary expansion as a part of orthodontic treatment and had a complete set of CBCT images taken at specific time(pre-expansion, post expansion). The mean interval between pre-expansion and completion of MARPE was 27days (range, 18-35 days). The mean expansion of expander was 6.7mm (range, 4.5-8.7 mm). After expansion, post expansion CBCT was taken within 5 weeks (mean, 10.7 days; range, 1-35 days). Patients with craniofacial anomalies or psychological limitations were excluded. Patients with previous orthodontic treatment history were also excluded. Each patient had CBCT images available at pre-expansion (T1) and post expansion (T2). (Table 1)

Table 1. Characteristics of sample

	Sample (n=14)
Sample size	F:9, M:5
Mean age (T1) year	20.1±2.4
Range year	16-26

Values are presented as number or mean ± standard deviation.

B. Method of study

1. Clinical application of MARPE

The MARPE was modified with 4-banded (supported by bilateral maxillary first premolars and first molars) conventional hyrax type RPE. Four rigid connectors of 0.8 mm stainless steel wire with helical hooks were soldered on the base of traditional hyrax screw body (Hyrax® Click, Dentaurum, Germany). Two anterior hooks were positioned on the rugae area and two posterior hooks were positioned on the parasagittal area. MARPE had passive contact with the underlying tissue. After cementation of MARPE, orthodontic miniscrews (Orlus, Ortholution, Seoul, Korea) with a 1.8 mm collar diameter and 7 mm length were placed in the center of helical hooks. During miniscrew placement, 2% lidocaine HCl containing 1: 100,000 epinephrine was infiltrated into the implantation area. NSAIDs (nonsteroidal anti-inflammatory drugs) could be prescribed for pain control. (Lee et al., 2010)

Maxillary expansion was started at the next day of placement of MARPE and the appliance was activated by once a day (1/4mm/turn) until the required expansion was achieved.

Fig. 1. Miniscrew assisted rapid palatal expander (MARPE)

2. Data collection

Study group had taken CBCT images available at pre-expansion (T1) and post expansion (T2) to evaluate the skeletal and dentoalveolar changes of maxilla. A pre-expansion CBCT image (T1) was taken as an initial record for all patients before the placement of the appliance. A post expansion CBCT image (T2) was taken directly after the required expansion was achieved.

The CBCT (Alphard VEGA, ASAHI Roentgen IND, Japan) imaging system was used in the study by the radiologist at the following settings: exposures were made at 5.0 mA and 80 kV for 17 seconds, and the slice thickness was 300 ㎛, using P-mode(width about 154mm x height about 154mm). In the lateral view, patients were scanned in the up-righting position with the Frankfort Horizontal plane (FH plane) parallel to the ground and their midlines were aligned with the vertical axis of the machine. In the frontal view the head was oriented with floor of orbits parallel to the floor.

The raw data obtained from the CBCTs were imported to the imaging software INFINITT (INFINITT healthcare, Seoul, Korea) and InVivo5® software (Anatomage, San Jose, CA) which was used to visualize the slices and 3D images that are obtained from a CBCT. This is where the 3D reconstruction of the DICOM (Digital Imaging and Communications in Medicine) images is made. Landmarks were defined on each of the three spatial planes (X, Y, Z). The procedure for localizing each point requires the selection of the most appropriate view (sagittal, coronal, axial) and then adjusting that point on the other views for better accuracy. All the spatial positions of each point have been pinpointed on each of these axes as numerical values. An Excel® sheet, version 12.0 for Windows (Microsoft Corporation) was created to introduce all the variables and measurements.

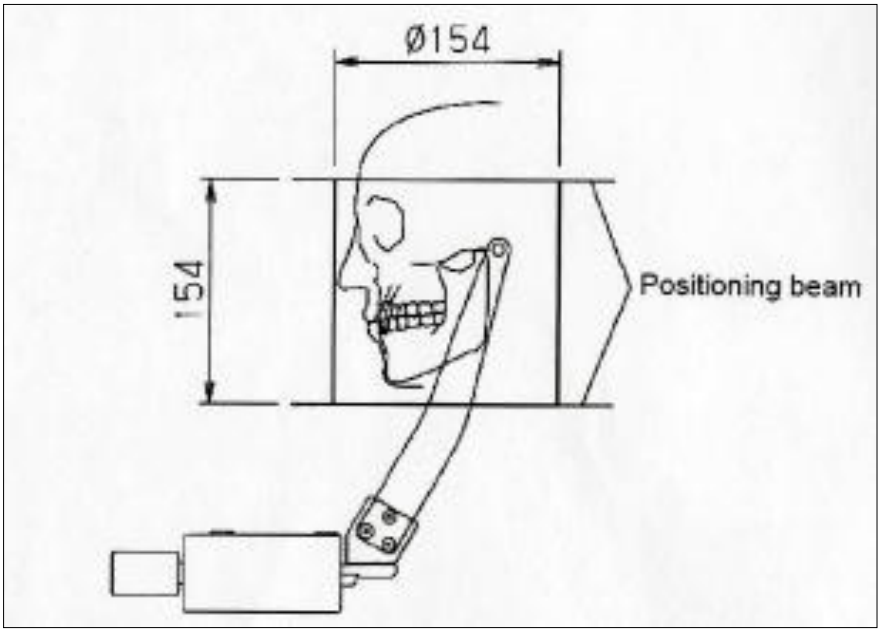

Fig. 2. Standardization of head position

3. Landmarks, linear and angular measurements

Landmarks and linear measurements was evaluated on the INFINITT (INFINITT healthcare, Seoul, Korea) and InVivo5® software (Anatomage, San Jose, CA) software program according to the method described by (Akyalcin et al., 2013; Baysal et al., 2013; Cameron et al., 2002; Chamberland and Proffit, 2008; Christie et al., 2010; Evangelista et al., 2010; Garib et al., 2006; Garrett et al., 2008; Handelman et al., 2000; Lagravere et al., 2010a; Magnusson et al., 2012).(Figures 3-9)

3.1 Landmarks and linear measurements of 3-dimensional images

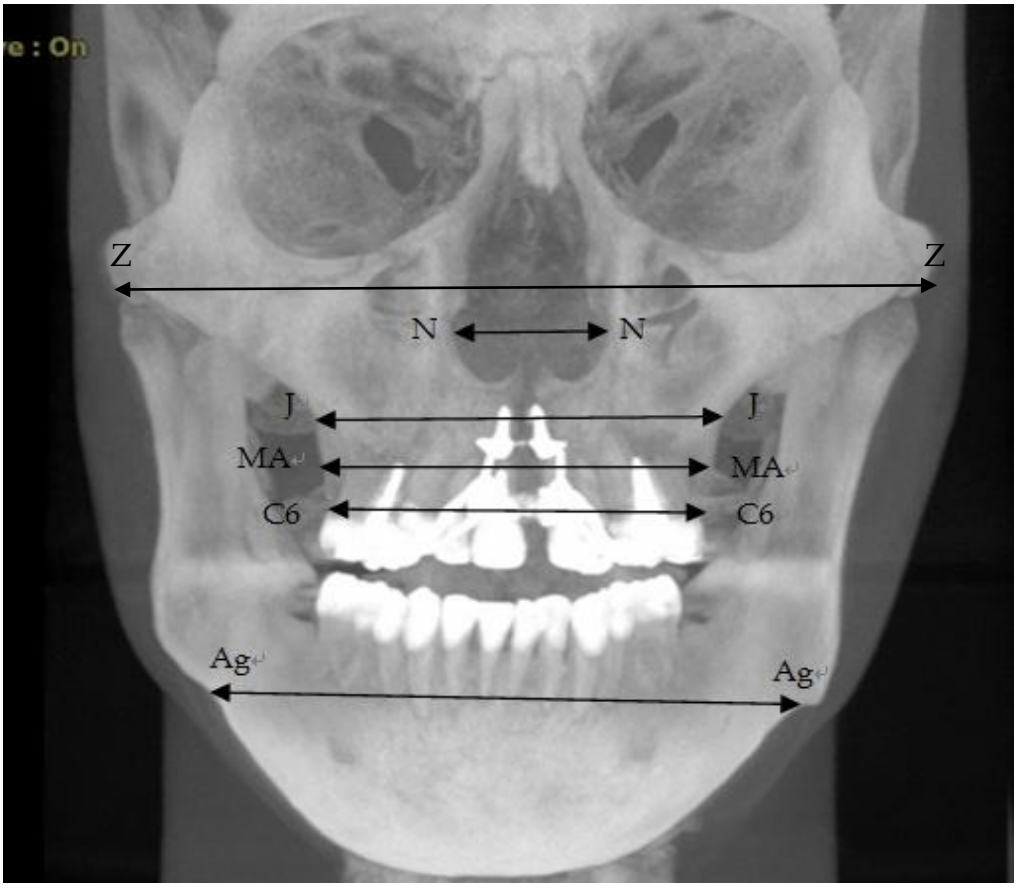

Fig. 3. Landmarks and linear measurements representing postero-anterior cephalogram of 3-dimensional image

Z: zygomatic process, N: the most lateral wall of nasal cavity, J (Juglare): the intersection of the outline of the maxillary tuberosity and the zygomatic buttress, MA: middle alveolus, C6: cervical point of maxillary 1st molar, Ag: antegonial notch

a) Z-Z: zygomatic width (mm), linear measurements from the right zygomatic process to left zygomatic process

b) N-N: nasal cavity width (mm), maximum width of nasal cavity

c) J-J: maxillary width (mm), maximum width between the right and the left J point

d) MA-MA: middle alveolus width (mm), maximum width of middle alveolus of maxillary molar

e) C6-C6: cervical width (mm), maximum width of cervical point of maxillary 1st molar

f) Ag-Ag: mandibular width (mm), linear measurements from the right antegonial notch to the left antegonial notch

3.2 Linear and angular measurements of two-dimensional coronal images.

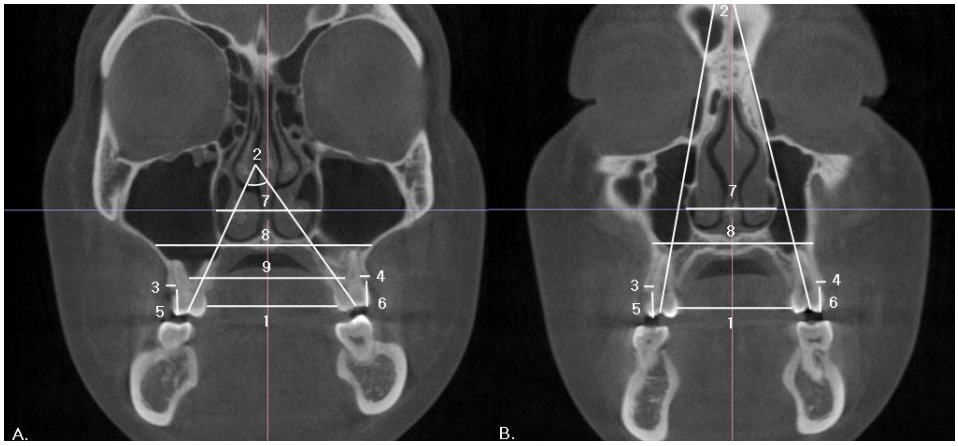

Fig. 4. Linear and angular measurements of two-dimensional coronal images perpendicular to the midsagittal plane

A: measurements at the level of maxillary first molar: intermolar width(1), maxillary first molar axial angulation(2), right(3) and left(4) maxillary first molar buccal bone thickness, right(5) and left(6) maxillary first molar buccal alveolar height, the maxillary first molar nasal width(7), the maxillary first molar basal bone width(8), and the maxillary first molar furcation width (9).

B: measurements at the level of maxillary first premolar: interpremolar width(1), maxillary first premolar axial angulation(2), right(3) and left(4) maxillary first premolar buccal bone thickness, right(5) and left(6) maxillary first premolar buccal alveolar height, the maxillary first premolar nasal width(7), and the maxillary first premolar basal bone width(8).

- Intermolar width (mm): linear distance between the most convex point of the palatal surface of the left maxillary 1st molar and the most convex point of the palatal surface of the right maxillary 1st molar.
- Interpremolar width (mm): linear distance between the most convex point of the palatal surface of the left maxillary 1st premolar and the most convex point of the palatal surface of the right maxillary 1st premolar.
- Maxillary 1st molar axial angulation(°): angulation was measured between the longitudinal axis of the palatal root of the right maxillary 1st molar and the longitudinal axis of the palatal root of the left maxillary 1st molar.
- Maxillary 1st premolar axial angulation(°): angulation was measured between the longitudinal axis of the palatal root of the right maxillary 1st premolar and the longitudinal axis of the palatal root of the left maxillary 1st premolar.
- Maxillary 1st molar buccal bone width (mm): linear distance from the root of the maxillary 1st molar at the level of trifurcation to the outermost point of the buccal plate.

- Maxillary 1st premolar buccal bone width (mm): linear distance from the root of the maxillary 1st premolar at the level of bifurcation to the outermost point of the buccal plate.
- Buccal alveolar height (mm): linear distance from the cusp tip to the buccal alveolar crest, measured for both right and left sides. For 1st molar, the buccal crest level was determined from mesiobuccal and distobuccal aspects of the teeth. For 1st and 2nd premolar, the buccal crest level was determined from middle aspects of the teeth.
- Basal bone width (mm): linear measurement of the maxillary basal width at the level of the maxillary 1st molar, 2nd premolar and 1st premolar.
- Nasal cavity width (mm): linear measurement of the nasal cavity width at the level of the maxillary 1st molar, 2nd premolar and 1st premolar.
- 1st molar furcation width (mm): linear distance between the furcation of the right maxillary 1st molar and those of left maxillary 1st molar.

3.3 Linear measurements of two-dimensional axial images

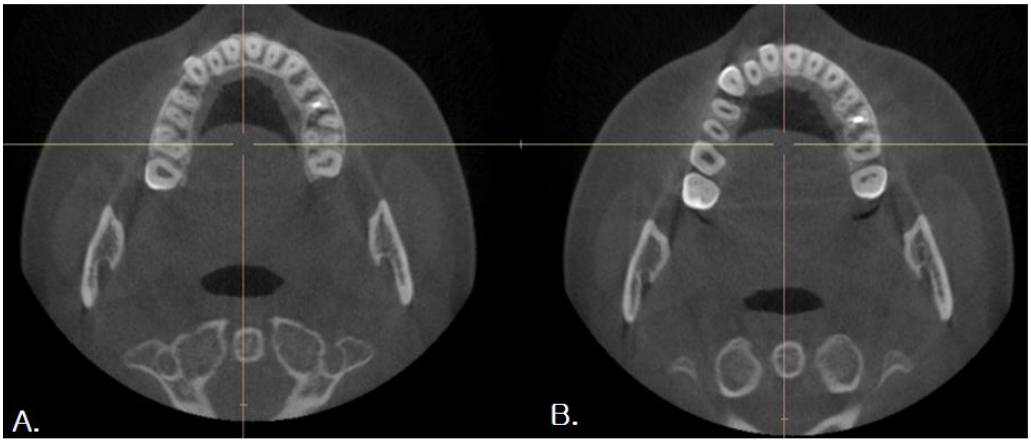

Fig. 5. Linear measurements of two-dimensional axial images

A: buccal cortical bone thickness (BCBT) and palatal cortical bone thickness (PCBT) at the level of the trifurcation of the first molar.

B: buccal cortical bone thickness (BCBT) and palatal cortical bone thickness (PCBT) at the level of the bifurcation of the premolar.

- Buccal cortical bone thickness (BCBT): the distance between the outer border of the cortical bone and the teeth were measured bucally.
- Palatal cortical bone thickness (PCBT): the distance between the outer border of the cortical bone and the teeth were measured palatally.

- To measure the cortical bone thickness at 2 different levels, cross-sections parallel to the Frankfort horizontal line were obtained at the trifurcation of the first molar and the bifurcation of the first premolar. However, the method was modified in the following situations; In case of tooth rotation, the thickness was evaluated using the nearest point of the root to the cortical plate. When the maxillary sinuses found around the roots of tooth, the distance was noted as zero.

3.4 Landmarks and linear measurements of 3D reconstruction image

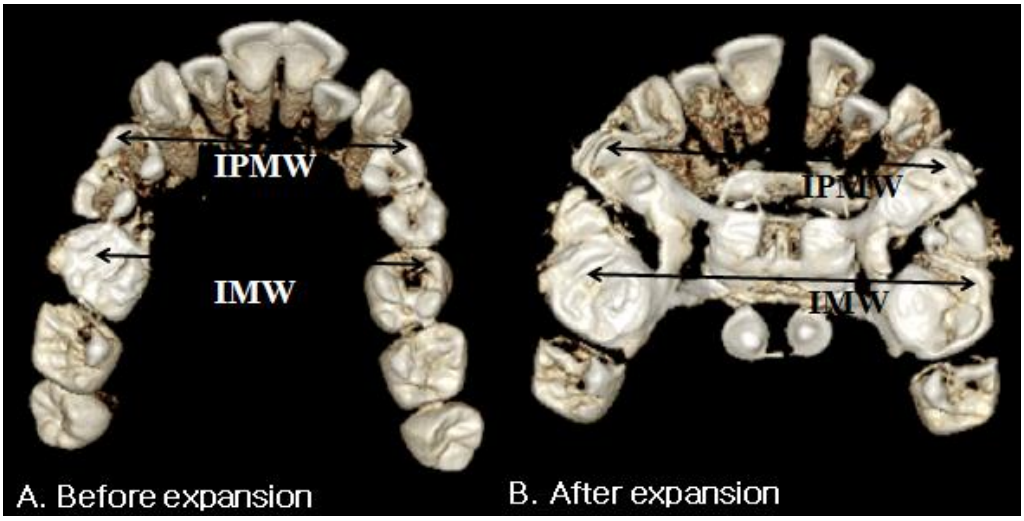

Fig. 6. Landmarks and linear measurements representing dimensions of IPMW and IMW (3-dimensional reconstruction image)

A: before expansion

B: after expansion

a) IPMW: interpremolar width (mm): linear measurements from the buccal cusp tip of the right 1st premolar to the buccal cusp tip of the left 1st premolar.

b) IMW: intermolar width (mm): linear measurements from the mesiobuccal cusp tip of the right 1st molar to the mesiobuccal cusp tip of the left 1st molar.

3.5 The presence of dehiscence and fenestration

The presence of dehiscence and fenestration was evaluated on the INFINITT (INFINITT healthcare, Seoul, Korea) and InVivo5® software (Anatomage, San Jose, CA) software program according to the method described by Evangelista et al.(Evangelista et al., 2010)(Fig. 7 and 8) The axial inclination of the tooth was placed perpendicular to the horizontal plane, and the total tooth length was evaluated in cross-sectional slices at the buccal and palatal surfaces. Images that showed no cortical bone around at least 3 consecutive views were recorded as dehiscence or fenestration. When the alveolar crest was more than 2 mm from CEJ (cement-enamel junction), dehiscence was recorded.(Baysal et al., 2013) When the defect did not involve the alveolar crest, fenestration was recorded.(Persson et al., 1998)

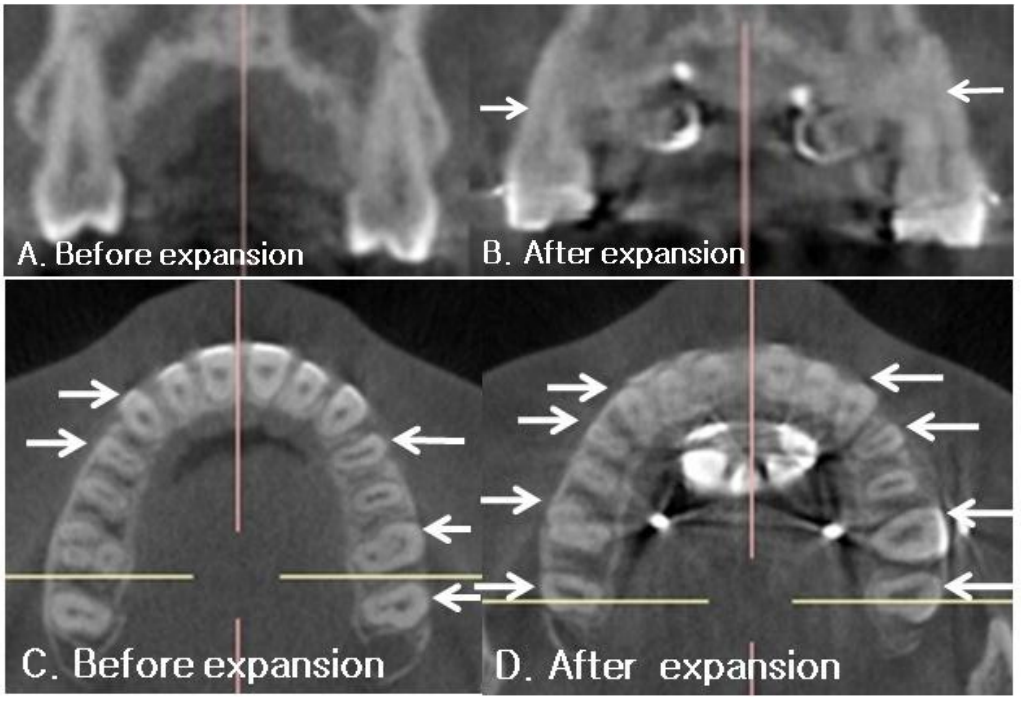

Fig. 7. An example of dehiscence before and after MARPE expansion

A: before expansion (coronal slice)

B: an example of dehiscence after expansion (coronal slice)

C: an example of dehiscence before expansion (axial slice)

D: an example of dehiscence after expansion (axial slice)

- Dehiscence: the lack of facial or lingual cortical plate, which resulted in exposing the cervical root surface and affecting the marginal bone.
- The arrow was pointing to the dehiscence.

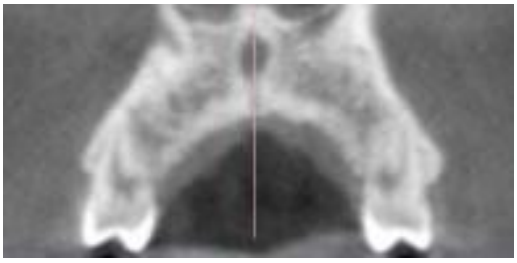

Fig. 8. An example of fenestration before expansion

- Fenestration: the lack of facial or lingual cortical plate, which resulted in exposing the root surface and affecting the bone. When there is still some bone in the cervical region, the defect is called fenestration.

3.6. 3D landmarks changes before and after MARPE expansion

3D landmarks were evaluated on the InVivo5® software (Anatomage, San Jose, CA) software program. The image registration and superimposition of the preoperative and postoperative 3D skull models were done with a point to point registration and a volumetric registration method, specifically normalized mutual information, based on the anterior cranial base. The cranial fossa and the ethmoid bone were regarded as stable areas, with growth completed before puberty.(Melsen, 1969) After volume registration, preoperative and postoperative images share the same coordinate system, which compensates for discrepancies, and diminishes the risks of measurement errors. Seven pairs of bony landmarks according to the study Magnusson et al.(Magnusson et al., 2012) were selected for measurements. Alare, ectocanine, processus zygomaticus, and ectomolare were real

corresponding landmarks, but spina nasalis anterior, A-point, and prosthion were constructed in pairs of left and right to estimate transverse measurement in the midline of the maxilla. Pre-expansion (T1) image was indicated in white color of the skull and post expansion (T2) image was indicated in blue color of the skull. (Fig. 9)

It consists of a horizontal axis called the X axis, a perpendicular line to the x axis called the Y axis and a vertical axis called the Z axis. The X, Y, Z coordinates of each landmark was used for standardizing the anatomical identification in the three planes and for guiding of location on sagittal, axial and coronal views.

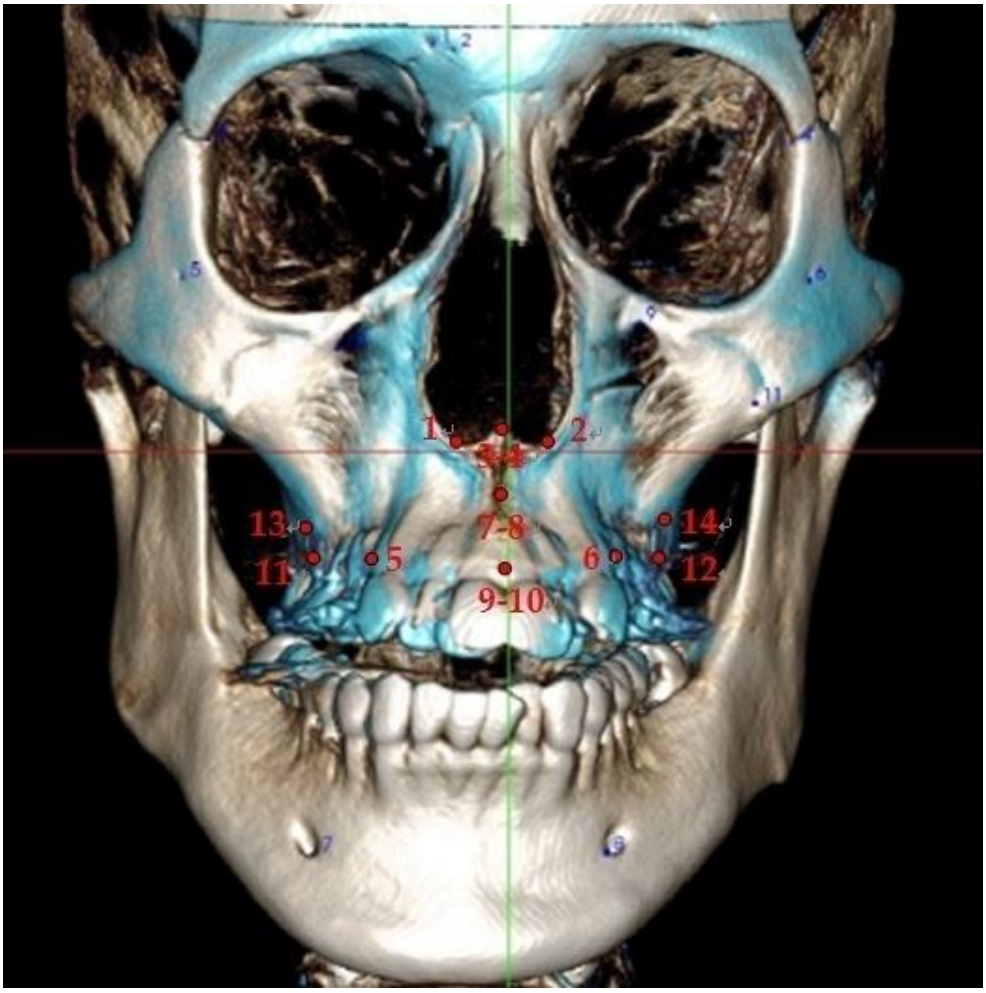

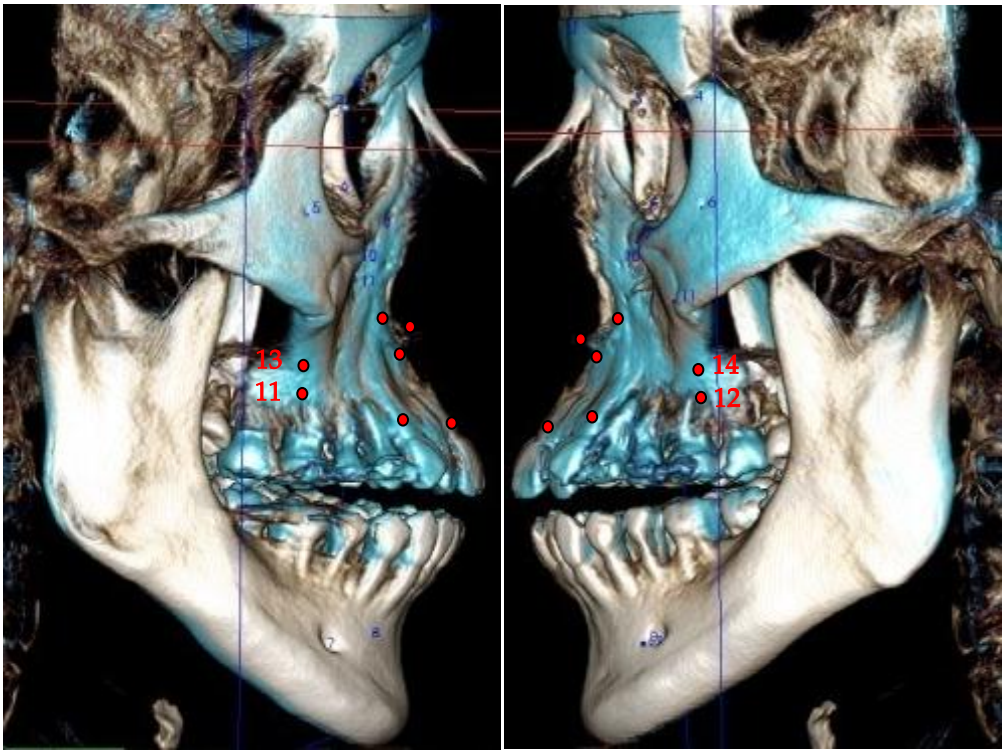

Fig.9. An example of 3D superimposition before and after MARPE expansion

Right(1) and left(2) alare, right(3) and left(4) spina nasalis anterior, right(5) and left(6) ectocanine, right(7) and left(8) A-point, right(9) and left(10) prosthion, right(11) and left(12) ectomolare, and right(13) and left(14) process zygomaticus

- alare: the most lateral and inferior point of the nasal aperture in a transverse plane
- spina nasalis anterior: the tip of the anterior nasal spine
- ectocanine: the most lateral and inferior point on the alveolar ridge opposite the center of maxillary canine
- A-point: the most posterior and deepest point on the anterior contour of the maxillary alveolar process in the midsagittal plane
- prosthion: the most anteroinferior point on the maxillary alveolar margin in the midsagittal plane
- ectomolare: the most lateral and inferior point on the alveolar ridge opposite the center of the maxillary first molar
- processus zygomaticus: the most inferior and lateral point of the processus zygomaticus
- transverse landmark displacements in maxilla between T1 and T2: the difference between the pre-expansion and post-expansion registrations

- total transverse landmark displacements in the maxilla, measured at 7 pairs of corresponding landmarks: the total change in the maxilla was calculated as the sum of the transverse displacement of the 7 pairs of corresponding landmarks on left and right sides

C. Statistical analysis

To test intra-examiner reproducibility, 7 images selected randomly were repeated by the same examiner a minimum of 1 week later and compared using the paired T test and the Spearman's correlation coefficients. The Shapiro-Wilk tests were used to determine the normality of data. $P < 0.05$ was considered to be the level of statistical significance. The arithmetic mean and standard deviation were calculated for all measurements. SPSS version 15.0 (SPSS Inc., Illinois, USA) was used for statistical analysis.

① The intra-examiner reliability was tested using the paired T test and the Spearman' s correlation analysis.

② Skeletal and dentoalveolar changes before and after MARPE expansion in 3-dimensional images were tested using the paired T test

③ Skeletal changes before and after MARPE expansion in coronal images were tested using the paired T test

i. Changes in nasal cavity and basal bone of maxilla between T1 and T2

④ Dentoalveolar changes before and after MARPE expansion in coronal images were tested using the paired T test and the Wilcoxon signed rank test.

i. Changes in intermolar and interpremolar width between T1 and T2

ii. Changes in axial angulation of maxillary first molar and premolar between T1 and T2

iii. Changes in buccal bone thickness of maxillary first molar and

premolar between T1 and T2

iv. Changes in buccal alveolar height measurements between T1 and T2

⑤ Dentoalveolar changes before and after MARPE expansion in axial images were tested using the paired T test.

i. Changes in BCBT and PCBT measurements between T1 and T2

⑥ Incidence of alveolar dehiscence and fenestration in axial and coronal images

i. Incidence of alveolar dehiscence and fenestration in MARPE expansion group

⑦ 3D landmarks changes before and after MARPE expansion were tested using the Wilcoxon signed rank test

i. Changes in X, Y, Z coordinates of landmark between T1 and T2

ii. Transverse landmark displacements in maxilla between T1 and T2

iii. Total transverse landmark displacements in the maxilla, measured at 7 pairs of corresponding landmarks

III. Results

A. Characteristics of sample

The study sample was formed retrospectively using the records of 14 patients (9 females, 5 males), the mean age of patients was 20.1±2.4years, and the range of patients was 16−26 years.

B. The intra−examiner reliability

All images measured by the same examiner. For determining the errors associated with CBCT measurements, 7 tomograms were selected randomly, and their measurements were repeated a minimum of 1 week after the first measurements and compared with the first measurements by the same examiner. The intra−examiner reliability test showed no significant differences ($p<0.05$) and the magnitudes of difference were 0.45 mm and 0.65° , respectively. Intra−class correlation coefficients were found to be higher than 0.90.

C. Statistical analysis

I. Skeletal and dentoalveolar changes before and after MARPE expansion

1. Skeletal and dentoalveolar changes before and after MARPE expansion in 3 dimensional reconstruction images (Table 2, Fig. 3,6,10)

A comparison of before and after measurements is shown Table 2. With exception of Ag-Ag (mandibular width), all measurements showed statistically significant increase after MARPE expansion. Both skeletal and dentoalveolar expansion were achieved after MARPE treatment (Table 2).

Table 2. Changes in skeleletal and dentoalveolar measurements between T1 and T2 in MARPE (3 dimensional reconstruction images, mm)

Measurement Region	Expansion (n=14)						
	Before expansion(T1)		After expansion(T2)		⊿T2-T1		
	Mean	SD	Mean	SD	Mean	SD	Sig.
IPMW	39.4	3.3	44.3	3.8	4.9	2.9	***
IMW	50.8	4.5	56.0	4.3	5.2	3.1	***
Z-Z	124.9	3.5	125.7	3.6	0.8	0.8	*
N-N	23.8	1.8	25.2	1.4	1.4	1.0	***
J-J	65.0	4.4	67.0	4.7	2.0	1.5	***
MA-MA	62.3	4.8	64.7	4.6	2.4	1.4	***
C6-C6	59.7	4.3	62.9	4.5	3.2	1.5	***
Ag-Ag	89.1	6.4	89.0	6.5	0.02	5.7	NS
J-J/Ag-Ag (%)	73.1	4.4	75.8	4.8	2.6	2.1	***

SD: standard deviation, Sig.: significance

T1: before expansion, T2: after expansion

IPMW: interpremolar width, IMW: intermolar width

Z-Z : zygoma width, N-N: nasal width, J-J: maxillary width, MA-MA: middle alveolus width, C6-C6: cervical width, Ag-Ag: mandibular width

The significant difference was defined by Paired t-test.

* $P < 0.05$, ** $P < 0.01$. *** $P < 0.001$, NS, not significant

2. Skeletal and dentoalveolar changes before and after MARPE expansion in coronal images (Table 3-7, Fig. 4)

2-1. Skeletal changes before and after MARPE expansion in coronal images (Table 3, Fig. 4)

Table 3 showed statistically significant increase in the width of the nasal cavity and basal bone of maxilla at the level of the maxillary 1st molar, and premolars level (P<0.001). Changes in 1st premolar area were higher than those in 1st molar area in both nasal cavity and basal bone of maxilla. Skeletal expansion was achieved after MARPE treatment (Table 3).

Table 3. Changes in nasal cavity and basal bone of maxilla between T1 and T2 (coronal images, mm)

Measurement Region	Width of nasal cavity and basal bone (n=14)						Sig.
	Before expansion(T1)		After expansion(T2)		⊿T2-T1		
	Mean	SD	Mean	SD	Mean	SD	
Nasal cavity width							
1st molar	29.5	2.6	30.2	2.7	0.7	1.2	***
2nd premolar	27.0	3.0	28.4	2.9	1.5	1.2	***
1st premolar	24.5	3.2	26.1	2.9	1.6	1.8	***
Basal bone width of maxilla							
1st molar	64.5	5.5	66.2	5.0	1.7	1.8	***
2nd premolar	54.2	8.0	55.9	7.6	1.8	2.1	***
1st premolar	40.1	8.1	42.0	7.6	1.9	3.4	***

SD: standard deviation, Sig.: significance

The significant difference was defined by Paired t-test.

* $P < 0.05$, ** $P < 0.01$. *** $P < 0.001$, NS, not significant

2-2. Dentoalveolar changes before and after MARPE expansion in coronal images (Table 4-7, Fig. 4)

The transversal arch width measurement for the maxillary first molar increased an average of 4.6 mm after expansion with $P < .001$. The arch width measurement for the maxillary first premolar increased an average of 4.6 mm after following expansion with $P < .001$ (Table 4).

Table 4. Changes in the first molar furcation width, intermolar and interpremolar width between T1 and T2 (coronal images, mm)

Measurement Region	Intermolar and interpremolar width (n=14)						Sig.
	Before expansion(T1)		After expansion(T2)		⊿T2-T1		
	Mean	SD	Mean	SD	Mean	SD	
1st molar furcation width	44.3	2.6	46.6	2.8	2.2	1.1	***
Intermolar width	34.4	3.8	39.0	3.6	4.6	1.9	***
Interpremolar width	26.1	4.2	30.8	3.5	4.6	1.6	***

SD: standard deviation, Sig.: significance

T1: before expansion, T2: after expansion

1st molar furcation width : linear distance between the furcation of the left maxillary 1st molar and those of the right maxillary 1st molar.

Intermolar width (mm): linear distance between the most convex point of the palatal surface of the left maxillary 1st molar and those of the right maxillary 1st molar.

Interpremolar width (mm): linear distance between the most convex point of the palatal surface of the left maxillary 1st premolar and those of the right maxillary 1st premolar.

The significant difference was defined by Paired t-test.

* $P < 0.05$, ** $P < 0.01$. *** $P < 0.001$, NS, not significant

With regard to changes in the axial angulation of the 1st molars and 1st premolars (Table 5), increases were recorded all premolars and molars. Statistically significant increases were observed in the axial angulation of the maxillary 1st molars after MARPE expansion, with 5.7±5.2° . The axial angulation change of 1st molar was higher than those of 1st premolar (Table 5).

Table 5. Changes in axial angulation of the left and right maxillary first molar and premolars between T1 and T2 (coronal images, °)

Measurement Region	Buccal-lingual angulation (E, n=14)						Sig.
	Before expansion(T1)		After expansion(T2)		⊿T2-T1		
	Mean	SD	Mean	SD	Mean	SD	
1st molar	40.3	9.6	46.0	9.1	5.7	5.2	**
1st premolar	0.4	11.4	2.7	10.7	2.2	10.6	NS

SD: standard deviation, Sig.: significance

T1: before expansion, T2: after expansion

The significant difference was defined by Paired t-test.

* $P < 0.05$, ** $P < 0.01$. *** $P < 0.001$, NS, not significant

When comparing the effect of maxillary expansion on the buccal plate of the maxillary 1st molars and 1st premolars, statistically significant decrease in buccal plate thickness was observed for all teeth. Changes in 1st premolar area were higher than those in 1st molar area in buccal bone thickness. (Table 6)

Table 6. Changes in buccal bone thickness (coronal images, mm)

Measurement Region	Buccal bone thickness (n=14)						Sig.
	Before expansion(T1)		After expansion(T2)		⊿T2-T1		
	Mean	SD	Mean	SD	Mean	SD	
UR6	2.7	1.1	2.4	1.4	0.3	1.1	*
UL6	3.0	0.9	2.2	1.4	0.8	1.0	*
UR4	2.2	1.1	0.9	0.9	1.3	0.9	*
UL4	2.0	0.9	1.0	1.1	1.0	0.8	*

SD: standard deviation, Sig.: significance

T1: before expansion, T2: after expansion

UR: upper right, UL: upper left, 4: first premolar, 6: first molar

The significant difference was defined by Paired t-test.

* $P < 0.05$, ** $P < 0.01$. *** $P < 0.001$, NS, not significant

A comparison of the buccal alveolar height before and after MARPE is shown in Table 7. With exception of the left 1st premolar bifurcation level and 1st molar distobuccal level, these measurements were increased with statistically significant, indicating the vertical alveolar height decreased immediately after MARPE expansion (Table 7).

Table 7. Changes in buccal alveolar height measurements (coronal images, mm)

Measurement Region	Right segment					Left segment				
	Before expansion(T1)		After expansion(T2)		Sig.	Before expansion(T1)		After expansion(T2)		Sig.
	Mean	SD	Mean	SD		Mean	SD	Mean	SD	
1st premolar	8.3	1.0	10.0	2.3	*	8.8	1.0	11.4	3.8	NS
2nd premolar	8.0	0.9	8.8	1.5	*	8.3	1.0	9.5	2.2	*
1st molar										
Distobuccal	8.2	0.6	8.5	0.7	NS	8.2	0.7	8.8	1.2	NS
Mesiobuccal	8.2	0.6	9.3	2.2	*	8.2	0.8	10.5	2.9	**

Values are presented as number or mean±standard deviation.

SD: standard deviation, Sig.: significance

The significant difference was defined by the Wilcoxon signed rank test.

* $P < 0.05$, ** $P < 0.01$. *** $P < 0.001$, NS, not significant

3. Dentoalveolar changes before and after MARPE expansion in axial images (Table 8, Fig. 5)

There was no difference between left and right segment. Except the section A area of canine, all measurements of BCBT (buccal cortical bone thickness) were statistically significant decreased. After MARPE, all measurements of the PCBT (palatal cortical bone thickness) were increased, but there was no significant difference in 2nd premolar and the section B area of canine (Table 8).

Table 8. Changes in BCBT (buccal cortical bone thickness) and PCBT (palatal cortical bone thickness) measurements (axial images, mm)

Measurement region	Before expansion(T1)		After expansion(T2)		Sig.
	Mean	SD	Mean	SD	
BCBT					
Canine					
Section A	0.2	0.3	0.1	0.2	NS
Section B	0.5	0.6	0.2	0.4	**
1st premolar					
Section A	0.7	0.6	0.1	0.2	***
Section B	0.8	0.6	0.3	0.4	***
2nd premolar					
Section A	1.1	0.8	0.6	0.7	**
Section B	1.8	0.8	1.3	0.8	**
1st molar					
Section A	0.9	0.6	0.3	0.5	**
Section B	1.5	0.9	0.9	0.9	***
PCBT					
Canine					
Section A	1.6	1.4	2.1	1.3	***
Section B	2.4	1.2	2.3	1.1	NS
1st premolar					
Section A	1.3	0.4	2.2	1.1	***
Section B	2.1	1.1	2.5	1.2	*
2nd premolar					
Section A	1.7	0.6	2.0	0.7	NS
Section B	2.2	0.9	2.2	0.7	NS
1st molar					
Section A	1.4	0.6	2.0	0.8	**
Section B	1.3	0.5	1.5	0.5	*

SD: standard deviation, Sig.: significance

The significant difference was defined by Paired t-test.

* $P < 0.05$, ** $P < 0.01$. *** $P < 0.001$, NS, not significant

* BCBT, buccal cortical bone thickness; PCBT, palatal cortical bone thickness

*Section A: at the level of bifurcation of the 1st premolar

*Section B: at the level of trifurcation of the 1st molar

II. Incidence of alveolar dehiscence and fenestration in MARPE expansion

1. Incidence of alveolar dehiscence and fenestration in MARPE expansion (Table 9, Fig. 7,8)

The incidence of alveolar dehiscence and fenestration before and after MARPE was shown in Table 9. In general, the incidence of dehiscence was greater for the T2 (after expansion) period than for the T1 (before expansion) period. The percentage of fenestrations decreased after expansion (Table 9).

Table 9. Incidence of alveolar dehiscence and fenestration before and after MARPE (axial and coronal images)

Measurement region	Total surface number	Before expansion(T1) (n=14)		After expansion (T2) (n=14)	
		Dehiscence	Fenestration	Dehiscence	Fenestration
Canine					
Buccal	28	7(25.0)	18(64.3)	8(28.6)	17(60.7)
Palatal	28	0(0.0)	10(35.7)	0(0.0)	11(39.3)
1st premolar					
Buccal	28	5(17.9)	11(39.3)	24(85.7)	3(10.7)
Palatal	28	1(3.6)	0(0.0)	2(7.1)	1(3.6)
2nd premolar					
Buccal	28	0(0.0)	2(7.1)	10(35.7)	0(0.0)
Palatal	28	0(0.0)	0(0.0)	1(3.6)	0(0.0)
1st molar					
Buccal	28	0(0.0)	4(14.3)	9(32.1)	3(10.7)
Palatal	28	1(3.6)	1(3.6)	2(7.1)	1(3.6)

Values are presented as number or percentage (%).

III. 3D landmarks changes before and after MARPE expansion

1. X, Y, Z coordinates changes before and after MARPE expansion in 3D superimposition image(Table 10, Fig. 9)

X coordinates of alare, ectocanine, A-point, prosthion, ectomolare, and procesus zygomaticus (left and right) were showed statistically significant changes. Except spina nasalis, all of landmarks showed significant transverse changes. Y coordinate of alare, ectocanine, and left A point, Z coordinates of left prosthion, ectomolare, and procesus zygomaticus show statistically significant changes. (Table 10)

Table 10. Changes in X, Y, Z coordinates of landmarks between T1 and T2

Landmark	T2-T1					
	Mean	Median	Minimum	Maximum	SD	Sig
Alare, right(1)						
X	-1.0	-1.6	-2.4	0.2	0.7	**
Y	-0.6	-2.1	-2.1	0.1	0.7	*
Z	-0.1	-0.4	-1.7	1.1	0.9	NS
Alare, left(2)						
X	0.5	-0.01	-1.3	2.1	0.9	*
Y	-0.8	-0.7	-3.1	0.3	0.9	**
Z	-0.1	-0.6	-1.7	1.6	1.0	NS
Spina nasalis, right(3)						
X	-0.6	-0.4	-2.8	1.3	1.1	NS
Y	-1.2	0.6	-5.8	1.7	2.1	NS
Z	0.5	0.7	-1.6	3.3	1.3	NS
Spina nasalis, left(4)						
X	0.6	0.3	-1.3	4.1	1.3	NS
Y	-0.6	3.2	-5.5	3.6	2.4	NS
Z	0.2	1.7	-1.9	2.4	1.2	NS
Ectocanine, right(5)						
X	-1.5	-2.0	-3.7	0.1	1.3	**
Y	-0.6	-0.8	-1.9	0.5	0.8	*
Z	0.4	0.2	-1.5	3.0	1.2	NS

Ectocanine, left(6)						
X	0.6	−0.4	−0.6	1.7	0.7	**
Y	−1.0	−2.2	−3.3	0.4	1.2	**
Z	0.2	−0.3	−1.7	2.6	1.2	NS
A−point, right(7)						
X	−1.7	−1.6	−3.7	1.1	1.5	**
Y	−0.2	0.7	−1.9	2.0	1.2	NS
Z	−0.1	−0.1	−2.3	2.0	1.2	NS
A−point, left(8)						
X	1.2	0.4	−0.8	4.2	1.3	**
Y	−0.4	−0.2	−1.9	1.4	0.9	*
Z	−0.5	−0.5	−2.5	2.1	1.4	NS
Prosthion, right(9)						
X	−1.8	−2.0	−3.3	0.3	1.1	**
Y	0.1	0.3	−2.2	2.4	1.0	NS
Z	0.8	0.3	−0.8	3.9	1.3	NS
Prosthion, left(10)						
X	1.3	1.0	−1.3	4.8	1.8	*
Y	0.3	0.5	−1.2	4.3	1.4	NS
Z	0.8	0.6	−0.9	4.7	1.5	*
Ectomolare, right(11)						
X	−1.6	−2.7	−2.9	−0.2	0.9	**
Y	0.1	1.3	−0.7	1.5	0.7	NS
Z	2.5	1.6	−1.5	6.7	2.3	**
Ectomolare, left(12)						
X	1.2	1.3	−0.4	2.5	1.0	**
Y	0.1	1.1	−1.3	1.6	0.9	NS
Z	2.1	1.6	−0.9	7.1	2.3	*
Procesus zygomaticus, right(13)						
X	−1.9	−1.2	−5.2	1.1	1.7	**
Y	0.1	1.5	−1.5	3.1	1.6	NS
Z	1.2	4.0	−4.4	5.2	2.3	*
Procesus zygomaticus, left(14)						
X	1.7	1.5	−2.0	5.4	1.7	*
Y	0.2	−0.4	−2.5	2.9	1.6	NS
Z	1.1	−1.8	−3.6	4.9	2.5	NS

Values are presented as number or mean±standard deviation.

SD: standard deviation, Sig.: significance

The significant difference was defined by the Wilcoxon signed rank test.

* $P < 0.05$, ** $P < 0.01$. *** $P < 0.001$, NS, not significant

2. Transverse landmark displacements before and after MARPE expansion in 3D superimposition image(Table11, Fig. 9)

Table 11 shows statistically significant increase in the alare, ectocanine, ectomolare, and procesus zygomaticus. There was greater changes at the ectomolare and procesus zygomaticus than at the alare and ectocanine. (Table 11)

Table 11. Transverse landmark displacements in maxilla between T1 and T2

Landmark	⊿T2−T1					
	Mean	Median	Minimum	Maximum	SD	Sig
Alare, right(1)	1.5	0.7	0.7	3.0	0.8	**
Alare, left(2)	1.6	1.6	0.4	3.4	0.6	**
Spina nasalis, right(3)	2.5	2.1	0.4	5.8	1.6	NS
Spina nasalis, left(4)	2.5	1.8	0.6	5.8	1.7	NS
Ectocanine, right(5)	2.4	2.4	0.6	3.9	0.8	*
Ectocanine, left(6)	1.9	1.7	0.8	3.4	0.9	*
A−point, right(7)	2.5	2.5	1.0	4.4	1.1	NS
A−point, left(8)	2.2	2.2	0.3	4.7	1.3	NS
Prosthion, right(9)	2.4	2.0	1.1	4.9	1.5	NS
Prosthion, left(10)	2.4	1.80	0.1	6.5	1.9	NS
Ectomolare, right(11)	3.5	3.6	0.5	6.9	1.7	*
Ectomolare, left(12)	3.1	3.2	0.7	7.1	1.8	*
Procesus zygomaticus, right(13)	3.5	3.4	1.2	7.9	1.8	**
Procesus zygomaticus, left(14)	3.4	3.1	1.4	7.9	1.9	*

Values are presented as number or mean±standard deviation.

SD: standard deviation, Sig.: significance

The significant difference was defined by the Wilcoxon signed rank test.

* $P < 0.05$, ** $P < 0.01$. *** $P < 0.001$, NS, not significant

3. Total transverse landmark displacements before and after MARPE expansion in 3D superimposition image(Table 12, Fig. 9)

Table 12 shows that there were statistically significant increases in all transverse landmarks except spina nasalis. Inferiorly, at the level of the alveolar bone crest, there was greater change at the ectomolare than at the ectocanine ($P < 0.01$). (Table 12)

Table 12. Total transverse landmark displacements in the maxilla between T1 and T2, measured at 7 pairs of corresponding landmarks

Landmark	⊿T2−T1			
	Mean	Median	SD	Sig
Alare, right/left(1−2)	1.4	1.4	1.0	**
Spina nasalis, right/left(3−4)	1.1	1.9	1.7	NS
Ectocanine, right/left(5−6)	2.1	2.1	1.6	**
A−point, right/left(7−8)	2.8	2.7	2.2	**
Prosthion, right/left(9−10)	3.1	3.0	2.5	**
Ectomolare, right/left(11−12)	2.9	3.1	1.5	**
Procesus zygomaticus, right/left(13−14)	3.7	3.3	3.0	**

Values are presented as number or mean±standard deviation.

SD: standard deviation, Sig.: significance

The significant difference was defined by the Wilcoxon signed rank test.

* $P < 0.05$, ** $P < 0.01$. *** $P < 0.001$, NS, not significant

IV. Discussion

The conventional RPE (rapid palatal expansion) could lead to limited skeletal movement(Shapiro and Kokich, 1988), potential for undesirable dental tipping, root resorption (Baysal et al., 2012), detrimental periodontal effect(Garib et al., 2006; Thilander et al., 1983), and the lack of firm anchorage to retain long time(Berger et al., 1998; Gurel et al., 2010).

Skeletal anchorage by means of temporary anchorage devices (TADs) has proven useful(Nanda and Uribe, 2009) and the application of miniscrews in orthodontic treatment facilitates maximum anchorage and precise tooth movement, thus extending the spectrum of treatment options.

SARPE could establish more orthopedic expansion of basal bone rather than dentoalveolar tipping in adult patients but it requires surgery. Bone anchored rapid palatal expansion has shown to result in successful RPE in young adults (Deeb et al., 2010; Gerlach and Zahl, 2003; Lagravere et al., 2010a; Lee et al., 2010; Ramieri et al., 2005; Tausche et al., 2007; Wilmes et al., 2010). MARPE (miniscrew assisted rapid palatal expansion) is less invasive treatment modality than SARPE since its introduced by Lee et al. in 2010(Lee et al., 2010). Therefore the purpose of this study was to evaluate the skeletal and dentoalveolar changes in young adults after MARPE as an effective alternative to SARPE without surgery.

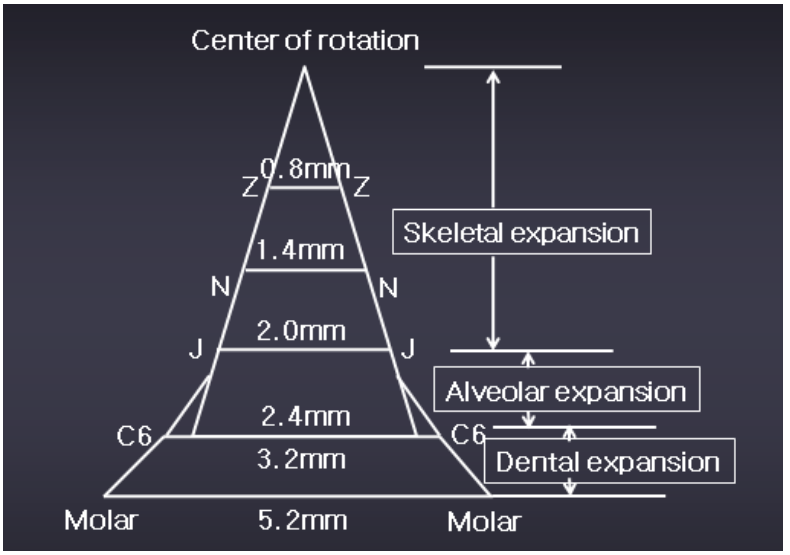

Fig.10. The diagram of dentoalveolar and skeletal expansion before and after MARPE.

Z: zygomatic process, N: the most lateral wall of nasal cavity, J (Juglare): the intersection of the outline of the maxillary tuberosity and the zygomatic buttress, MA: middle alveolus, C6: cervical point of maxillary 1st molar, Ag: antegonial notch

Z-Z: zygomatic width (mm), N-N: nasal cavity width (mm), J-J: maxillary width (mm), MA-MA: middle alveolus width (mm), C6-C6: cervical width (mm), Ag-Ag: mandibular width (mm)

With exception of Ag-Ag (mandibular width), all measurements were showed statistically significant increase after MARPE expansion in 3-dimensional reconstruction images (Table 2). Both skeletal and dentoalveolar expansion were achieved after MARPE treatment. The amount of transverse changes was decreasing from the molar cervical width (C6-C6) to the zygoma width (Z-Z) (Fig.10). The increase in transversal dental width measurements following expansion agreed with the results of previous studies (Corbridge et al., 2011; Garib et al., 2006; Mah et al., 2003; Palomo et al., 2006; Podesser et al., 2004; Rungcharassaeng et al., 2007).

The nasal cavity showed significant increases at the level of 1st molars, 1st and 2nd premolars. Changes in 1st premolar area were higher than those in 1st molar area in both nasal cavity and basal bone of maxilla (Table 3). There

was no data of nasal cavity and basal bone width at the level of canine because of distortion of coronal images, and the coronal slice was taken more anterior. Garib et al. reported transverse increase at the level of nasal floor (Garib et al., 2005). These finding might support that the maxillary expansion increases the air flow and improves nasal breathing (Ciambotti et al., 2001; Haas, 1965, 1970).

Different from the 2-dimensional images, CBCT visualize and quantify the changes of basal bone of maxilla.(Cameron et al., 2002; Chamberland and Proffit, 2008; Handelman et al., 2000) In this study, all levels of maxillary basal bone width showed significant increase (Table 3).

The activation force of RPE initially leads to compression of the PDL (periodontal ligament), bending of alveolar bone, and tipping of the anchored teeth(Haas, 1970). After RPE expansion, the angulation of molars increased from 1° to 24° (Hicks, 1978; Lione et al., 2013) due to alveolar bending and tipping of posterior teeth. By contrast, the other study showed no statistically significant amount of dental tipping after RPE treatment but significant alveolar tipping compared with the controls(Kartalian et al., 2010). In this study, MARPE might result in the tipping of maxillary posterior teeth and the level of the buccal alveolar crest was lowered in all posterior teeth after MARPE (Table 5, 7). These changes might be attributed to the tipping of anchored teeth, and the tipping of teeth might lead to changes of the alveolar crest (Thilander et al., 1983). Clinically, this finding is important, because clinicians determine the appropriate amount of over expansion. In this study, the mean amounts of axial angulation of 1st molar was 5.7±5.2° (Table 5). These are clinically acceptable amounts, in comparison to those found by Christie et al. of 5.91±2.55° (using bonded RPE, mean age: 9.9 years), Ciambotti et al. of 6.08±6.25° (using RPE, mean age: 11.1 years) , Kilic et al. of 6.9° (using RPE, mean age: 13.8 years, range: 11-16 years), and Gurgel et al. of 4.95±2.67° (using SARPE, mean age: 25.4 ages, range: 17.4-41.8

years)(Christie et al., 2010; Ciambotti et al., 2001; Gurgel et al., 2013; Kilic et al., 2008). Garib et al. reported more dental inclination changes at the molars than at the premolars(Garib et al., 2005), their findings were similar to our study(Table 5). Tooth inclination changes associated with expansion devices should be considered during treatment planning.

When comparing the effect of MARPE expansion on the buccal plate, significant reduction of buccal plate thickness (range: 0.3−0.6mm) was observed (Table 8). Changes in 1st premolar area were higher than those in 1st molar area in buccal bone thickness (Table 6). Gauthier et al. reported that a significant decrease in the thickness of the alveolar bone on the buccal aspect of all premolars and molars especially on the mesial aspect of the left 1st molar, with a mean of 0.6±0.5mm, which is up to 55% of the initial thickness and a significant increase on the palatal aspect (Gauthier et al., 2011). Corbridge et al. reported that the teeth moved through the alveolus, leading to decrease in buccal bone thickness and increase in lingual bone thickness (Corbridge et al., 2011). And Garib et al. found that RPE reduced the buccal bone plate thickness of supporting teeth 0.6 to 0.9mm (Garib et al., 2006).

In this study, all measurements of PCBT (palatal cortical bone thickness) after expansion were increased (range: 0.2−0.9mm), but there was no statistically significant in 2nd premolar and section B area of canine (Table 8). Because of buccal tipping of the posterior teeth, the distance between the palatal cortical plate and the root surface could be increased (Baysal et al., 2013). Garib et al. found that RPE increased the lingual bone plate thickness 0.8 to 1.3mm. (Garib et al., 2006)

Because of the considerable force needed to break the midpalatal suture, an evaluation of the periodontal tissue, including alveolar bone defects and gingival biotype, is necessary (Evangelista et al., 2010). Garib et al. reported that RPE reduced the buccal bone thickness of supporting teeth and induced

the bone dehiscence (Garib et al., 2006). The prevalence of dehiscence and fenestration has shown different results among various ethnic groups (Ezawa et al., 1987; Rupprecht et al., 2001; Urbani et al., 1991). Evangelista et al. found that the maxillary canines and 1st premolars showed a high prevalence of dehiscence in Class I and Class II division I malocclusion patients using CBCT (Evangelista et al., 2010). Dehiscence was associated with 51.09% of all teeth, and the fenestration with 36.51% (Evangelista et al., 2010). Rupprecht et al. reported that there was more dehiscence (51.09%) than fenestration (36.51%)(Rupprecht et al., 2001). In this study, the incidence of alveolar dehiscence was somewhat increased after MARPE expansion (range: 0.0-85.7%). Dental tipping and decreasing in alveolar bone height could attribute to these alveolar bone dehiscence and fenestration. The occurrence of dehiscence and fenestration during orthodontic treatment depends on the direction of movement, the frequency and magnititude of orthodontic forces, and the volume and anatomic integrity of the periodontal tissues (Wehrbein et al., 1996). Before MARPE treatment, these dentoalveolar changes should be considered.

In this study, point to point and volumetric registration 3D superimposition was used to measure the transverse skeletal and dentoalveolar effects of MARPE. X coordinates of alare, ectocanine, A-point, prosthion, ectomolare, and procesus zygomaticus (left and right) were showed statistically significant changes. The effect was not uniform, significant transverse expansion was observed especially in X coordinates. Y coordinate of alare, ectocanine, and left A point showed statistically significant decreases, except prosthion, ectomolare, precesus zygomaticus (Table 10). There was forward movement of the maxilla as a result of MARPE expansion.(Chung and Font, 2004; Farronato et al., 2011) Inferiorly, at the level of the alveolar bone crest, there was greater expansion at the first molars because of posterior tipping. (Table 11, 12) (Chung and Font, 2004)

Although the accuracy of CBCT imaging had been well documented, tracing error was realistically inevitable. Despite the clarity of the images obtained in our study, CBCT image including metallic objects like MARPE and metal crown suffers from annoying metal artifacts such as shades and streaks. Spatial resolution which is the ability to differentiate between two distinct objects close to each other can be affected by variations in shading, field of view, and voxel size.(Ballrick et al., 2008) Because of ethical problem, age matched controlled prospective study was not possible in this study. Another limitation of this study is the small sample size.

There were needs for improved transverse expansion modality to diminish the risk of fenestration, dehiscence, and decreasing of buccal bone thickness due to posterior tipping. Nevertheless the findings of this study confirmed that MARPE is an effective method for correcting the insufficient transverse dimension of the dentition and the maxillary basal bone in young adults. Additional prospective studies with a greater number of subjects and long term stability of MARPE treatment should be followed.

V. Conclusion

The aim of this study was to evaluate the skeletal and dentoalveolar changes in young adult patients immediately after miniscrew assisted rapid palatal expansion (MARPE) treatment using cone-beam computed tomography (CBCT).

Experimental group was composed of 14 adult patients with maxillary transverse deficiency and treated with MARPE. CBCT images were taken at specific time (pre-expansion, post expansion).

1. After expansion (T2), there were statistically significant increases of skeletal and dentoalveolar measurements (zygoma width, nasal width, maxillary width, middle alveolus width, and cervical width) ($P<0.05$).
2. After expansion (T2), there were statistically significant increases in the width of the nasal cavity and basal bone of maxilla ($P<0.001$). Changes in 1st premolar area were higher than those in 1st molar area in both nasal cavity and basal bone of maxilla.
3. After expansion (T2), the amount of transverse changes was decreasing from the molar cervical width (C6-C6) to the zygoma width (Z-Z).
4. By MARPE expansion, midpalatal suture was opened in all subjects and expanded significantly combined with forward movement of the maxilla complex ($P < 0.05$).
5. There were significant increases in all transverse landmarks in maxillofacial complex except for spina nasalis. At the level of the alveolar bone crest, there was greater change at the ectomolare than at the ectocanine ($P < 0.01$).

The findings of this study confirmed that MARPE is an effective method for correcting the insufficient transverse dimension of the dentition and the maxillary basal bone in young adults. Additional prospective studies with a greater number of subjects and long term stability of MARPE treatment should be followed.

References

Akyalcin S, Schaefer JS, English JD, Stephens CR, Winkelmann S (2013). A cone-beam computed tomography evaluation of buccal bone thickness following maxillary expansion. *Imaging Sci Dent* 43(2): 85-90.

Alpern MC, Yurosko JJ (1987). Rapid palatal expansion in adults with and without surgery. *Angle Orthod* 57(3): 245-263.

Ballrick JW, Palomo JM, Ruch E, Amberman BD, Hans MG (2008). Image distortion and spatial resolution of a commercially available cone-beam computed tomography machine. *Am J Orthod Dentofacial Orthop* 134(4): 573-582.

Bays RA, Greco JM (1992). Surgically assisted rapid palatal expansion: an outpatient technique with long-term stability. *J Oral Maxillofac Surg* 50(2): 110-113; discussion 114-115.

Baysal A, Karadede I, Hekimoglu S, Ucar F, Ozer T, Veli I, et al. (2012). Evaluation of root resorption following rapid maxillary expansion using cone-beam computed tomography. *Angle Orthod* 82(3): 488-494.

Baysal A, Uysal T, Veli I, Ozer T, Karadede I, Hekimoglu S (2013). Evaluation of alveolar bone loss following rapid maxillary expansion using cone-beam computed tomography. *Korean J Orthod* 43(2): 83-95.

Berger JL, Pangrazio-Kulbersh V, Borgula T, Kaczynski R (1998). Stability of orthopedic and surgically assisted rapid palatal expansion over time. *Am J Orthod Dentofacial Orthop* 114(6): 638-645.

Cameron CG, Franchi L, Baccetti T, McNamara JA, Jr. (2002). Long-term effects of rapid maxillary expansion: a posteroanterior cephalometric evaluation. *Am J Orthod Dentofacial Orthop* 121(2): 129-135; quiz 193.

Capelozza Filho L, Cardoso Neto J, da Silva Filho OG, Ursi WJ (1996). Non-surgically assisted rapid maxillary expansion in adults. *Int J Adult Orthodon Orthognath Surg* 11(1): 57-66; discussion 67-70.

Cevidanes LH, Oliveira AE, Grauer D, Styner M, Proffit WR (2011). Clinical application of 3D imaging for assessment of treatment outcomes. *Semin Orthod* 17(1): 72-80.

Chamberland S, Proffit WR (2008). Closer look at the stability of surgically assisted rapid palatal expansion. *J Oral Maxillofac Surg* 66(9): 1895-1900.

Chamberland S, Proffit WR (2011). Short-term and long-term stability of surgically assisted rapid palatal expansion revisited. *Am J Orthod Dentofacial Orthop* 139(6): 815-822.e811.

Christie KF, Boucher N, Chung CH (2010). Effects of bonded rapid palatal expansion on the transverse dimensions of the maxilla: a cone-beam

computed tomography study. *Am J Orthod Dentofacial Orthop* 137(4 Suppl): S79-85.

Chung CH, Font B (2004). Skeletal and dental changes in the sagittal, vertical, and transverse dimensions after rapid palatal expansion. *Am J Orthod Dentofacial Orthop* 126(5): 569-575.

Ciambotti C, Ngan P, Durkee M, Kohli K, Kim H (2001). A comparison of dental and dentoalveolar changes between rapid palatal expansion and nickel-titanium palatal expansion appliances. *Am J Orthod Dentofacial Orthop* 119(1): 11-20.

Corbridge JK, Campbell PM, Taylor R, Ceen RF, Buschang PH (2011). Transverse dentoalveolar changes after slow maxillary expansion. *Am J Orthod Dentofacial Orthop* 140(3): 317-325.

da Silva Filho OG, Montes LA, Torelly LF (1995). Rapid maxillary expansion in the deciduous and mixed dentition evaluated through posteroanterior cephalometric analysis. *Am J Orthod Dentofacial Orthop* 107(3): 268-275.

Deeb W, Hansen L, Hotan T, Hietschold V, Harzer W, Tausche E (2010). Changes in nasal volume after surgically assisted bone-borne rapid maxillary expansion. *Am J Orthod Dentofacial Orthop* 137(6): 782-789.

Evangelista K, Vasconcelos Kde F, Bumann A, Hirsch E, Nitka M, Silva MA (2010). Dehiscence and fenestration in patients with Class I and Class

II Division 1 malocclusion assessed with cone-beam computed tomography. *Am J Orthod Dentofacial Orthop* 138(2): 133.e131-137; discussion 133-135.

Ezawa T, Sano H, Kaneko K, Hiruma S, Fujikawa K, Murai S (1987). The correlation between the presence of dehiscence or fenestration and the severity of tooth attrition in contemporary dry Japanese adult skulls--Part I. *J Nihon Univ Sch Dent* 29(1): 27-34.

Farronato G, Giannini L, Galbiati G, Maspero C (2011). Sagittal and vertical effects of rapid maxillary expansion in Class I, II, and III occlusions. *Angle Orthod* 81(2): 298-303.

Garib DG, Henriques JF, Janson G, de Freitas MR, Fernandes AY (2006). Periodontal effects of rapid maxillary expansion with tooth-tissue-borne and tooth-borne expanders: a computed tomography evaluation. *Am J Orthod Dentofacial Orthop* 129(6): 749-758.

Garib DG, Henriques JF, Janson G, Freitas MR, Coelho RA (2005). Rapid maxillary expansion--tooth tissue-borne versus tooth-borne expanders: a computed tomography evaluation of dentoskeletal effects. *Angle Orthod* 75(4): 548-557.

Garrett BJ, Caruso JM, Rungcharassaeng K, Farrage JR, Kim JS, Taylor GD (2008). Skeletal effects to the maxilla after rapid maxillary expansion assessed with cone-beam computed tomography. *Am J Orthod Dentofacial Orthop* 134(1): 8-9.

Gauthier C, Voyer R, Paquette M, Rompre P, Papadakis A (2011). Periodontal effects of surgically assisted rapid palatal expansion evaluated clinically and with cone-beam computerized tomography: 6-month preliminary results. *Am J Orthod Dentofacial Orthop* 139(4 Suppl): S117-128.

Gerlach KL, Zahl C (2003). Transversal palatal expansion using a palatal distractor. *J Orofac Orthop* 64(6): 443-449.

Gurel HG, Memili B, Erkan M, Sukurica Y (2010). Long-term effects of rapid maxillary expansion followed by fixed appliances. *Angle Orthod* 80(1): 5-9.

Gurgel JA, Tiago CM, Normando D (2013). Transverse changes after surgically assisted rapid palatal expansion. *Int J Oral Maxillofac Surg*.

Haas AJ (1965). THE TREATMENT OF MAXILLARY DEFICIENCY BY OPENING THE MIDPALATAL SUTURE. *Angle Orthod* 35: 200-217.

Haas AJ (1970). Palatal expansion: just the beginning of dentofacial orthopedics. *Am J Orthod* 57(3): 219-255.

Handelman CS, Wang L, BeGole EA, Haas AJ (2000). Nonsurgical rapid maxillary expansion in adults: report on 47 cases using the Haas expander. *Angle Orthod* 70(2): 129-144.

Harzer W, Schneider M, Gedrange T, Tausche E (2006). Direct bone placement of the hyrax fixation screw for surgically assisted rapid palatal expansion (SARPE). *J Oral Maxillofac Surg* 64(8): 1313-1317.

Hicks EP (1978). Slow maxillary expansion. A clinical study of the skeletal versus dental response to low-magnitude force. *Am J Orthod* 73(2): 121-141.

Kartalian A, Gohl E, Adamian M, Enciso R (2010). Cone-beam computerized tomography evaluation of the maxillary dentoskeletal complex after rapid palatal expansion. *Am J Orthod Dentofacial Orthop* 138(4): 486-492.

Kilic N, Kiki A, Oktay H (2008). A comparison of dentoalveolar inclination treated by two palatal expanders. *Eur J Orthod* 30(1): 67-72.

Knaup B, Yildizhan F, Wehrbein H (2004). Age-related changes in the midpalatal suture. A histomorphometric study. *J Orofac Orthop* 65(6): 467-474.

Kokich VG (1976). Age changes in the human frontozygomatic suture from 20 to 95 years. *Am J Orthod* 69(4): 411-430.

Lagravere MO, Carey J, Heo G, Toogood RW, Major PW (2010a). Transverse, vertical, and anteroposterior changes from bone-anchored maxillary expansion vs traditional rapid maxillary expansion: a randomized clinical trial. *Am J Orthod Dentofacial Orthop* 137(3): 304.e301-312; discussion 304-305.

Lagravere MO, Major PW, Carey J (2010b). Sensitivity analysis for plane orientation in three-dimensional cephalometric analysis based on

superimposition of serial cone beam computed tomography images. *Dentomaxillofac Radiol* 39(7): 400-408.

Lagravere MO, Secanell M, Major PW, Carey JP (2011). Optimization analysis for plane orientation in 3-dimensional cephalometric analysis of serial cone-beam computerized tomography images. *Oral Surg Oral Med Oral Pathol Oral Radiol Endod* 111(6): 771-777.

Langford SR, Sims MR (1982). Root surface resorption, repair, and periodontal attachment following rapid maxillary expansion in man. *Am J Orthod* 81(2): 108-115.

Lee H, Ting K, Nelson M, Sun N, Sung SJ (2009). Maxillary expansion in customized finite element method models. *Am J Orthod Dentofacial Orthop* 136(3): 367-374.

Lee KJ, Park YC, Park JY, Hwang WS (2010). Miniscrew-assisted nonsurgical palatal expansion before orthognathic surgery for a patient with severe mandibular prognathism. *Am J Orthod Dentofacial Orthop* 137(6): 830-839.

Lima Filho RM, de Oliveira Ruellas AC (2008). Long-term maxillary changes in patients with skeletal Class II malocclusion treated with slow and rapid palatal expansion. *Am J Orthod Dentofacial Orthop* 134(3): 383-388.

Lima SM, Jr., de Moraes M, Asprino L (2011). Photoelastic analysis of stress distribution of surgically assisted rapid maxillary expansion with and

without separation of the pterygomaxillary suture. *J Oral Maxillofac Surg* 69(6): 1771-1775.

Lione R, Franchi L, Cozza P (2013). Does rapid maxillary expansion induce adverse effects in growing subjects? *Angle Orthod* 83(1): 172-182.

Magnusson A, Bjerklin K, Kim H, Nilsson P, Marcusson A (2012). Three-dimensional assessment of transverse skeletal changes after surgically assisted rapid maxillary expansion and orthodontic treatment: a prospective computerized tomography study. *Am J Orthod Dentofacial Orthop* 142(6): 825-833.

Mah JK, Danforth RA, Bumann A, Hatcher D (2003). Radiation absorbed in maxillofacial imaging with a new dental computed tomography device. *Oral Surg Oral Med Oral Pathol Oral Radiol Endod* 96(4): 508-513.

Melsen B (1969). Time of closure of the spheno-occipital synchondrosis determined on dry skulls. A radiographic craniometric study. *Acta Odontol Scand* 27(1): 73-90.

Nanda R, Uribe FA (2009). Temporary anchorage devices in orthodontics. Mosby, St. Louis, Missouri.

Odenrick L, Karlander EL, Pierce A, Kretschmar U (1991). Surface resorption following two forms of rapid maxillary expansion. *Eur J Orthod* 13(4): 264-270.

Palomo JM, Kau CH, Palomo LB, Hans MG (2006). Three-dimensional cone beam computerized tomography in dentistry. *Dent Today* 25(11): 130, 132-135.

Park SH, Yu HS, Kim KD, Lee KJ, Baik HS (2006). A proposal for a new analysis of craniofacial morphology by 3-dimensional computed tomography. *Am J Orthod Dentofacial Orthop* 129(5): 600.e623-634.

Pavlin D, Vukicevic D (1984). Mechanical reactions of facial skeleton to maxillary expansion determined by laser holography. *Am J Orthod* 85(6): 498-507.

Persson M, Thilander B (1977). Palatal suture closure in man from 15 to 35 years of age. *Am J Orthod* 72(1): 42-52.

Persson RE, Hollender LG, Laurell L, Persson GR (1998). Horizontal alveolar bone loss and vertical bone defects in an adult patient population. *J Periodontol* 69(3): 348-356.

Podesser B, Williams S, Bantleon HP, Imhof H (2004). Quantitation of transverse maxillary dimensions using computed tomography: a methodological and reproducibility study. *Eur J Orthod* 26(2): 209-215.

Ramieri GA, Spada MC, Austa M, Bianchi SD, Berrone S (2005). Transverse maxillary distraction with a bone-anchored appliance: dento-periodontal effects and clinical and radiological results. *Int J Oral Maxillofac Surg* 34(4): 357-363.

Rungcharassaeng K, Caruso JM, Kan JY, Kim J, Taylor G (2007). Factors affecting buccal bone changes of maxillary posterior teeth after rapid maxillary expansion. *Am J Orthod Dentofacial Orthop* 132(4): 428.e421-428.

Rupprecht RD, Horning GM, Nicoll BK, Cohen ME (2001). Prevalence of dehiscences and fenestrations in modern American skulls. *J Periodontol* 72(6): 722-729.

Shapiro PA, Kokich VG (1988). Uses of implants in orthodontics. *Dent Clin North Am* 32(3): 539-550.

Shetty V, Caridad JM, Caputo AA, Chaconas SJ (1994). Biomechanical rationale for surgical-orthodontic expansion of the adult maxilla. *J Oral Maxillofac Surg* 52(7): 742-749; discussion 750-741.

Stuart DA, Wiltshire WA (2003). Rapid palatal expansion in the young adult: time for a paradigm shift? *J Can Dent Assoc* 69(6): 374-377.

Tausche E, Hansen L, Hietschold V, Lagravere MO, Harzer W (2007). Three-dimensional evaluation of surgically assisted implant bone-borne rapid maxillary expansion: a pilot study. *Am J Orthod Dentofacial Orthop* 131(4 Suppl): S92-99.

Thilander B, Nyman S, Karring T, Magnusson I (1983). Bone regeneration in alveolar bone dehiscences related to orthodontic tooth movements. *Eur J Orthod* 5(2): 105-114.

Timock AM, Cook V, McDonald T, Leo MC, Crowe J, Benninger BL, et al. (2011). Accuracy and reliability of buccal bone height and thickness measurements from cone-beam computed tomography imaging. *Am J Orthod Dentofacial Orthop* 140(5): 734-744.

Urbani G, Lombardo G, Filippini P, Nocini FP (1991). [Dehiscence and fenestration: study of distribution and incidence in a homogeneous population model]. *Stomatol Mediterr* 11(2): 113-118.

Wehrbein H, Bauer W, Diedrich P (1996). Mandibular incisors, alveolar bone, and symphysis after orthodontic treatment. A retrospective study. *Am J Orthod Dentofacial Orthop* 110(3): 239-246.

Williams BJ, Currimbhoy S, Silva A, O'Ryan FS (2012). Complications following surgically assisted rapid palatal expansion: a retrospective cohort study. *J Oral Maxillofac Surg* 70(10): 2394-2402.

Wilmes B, Nienkemper M, Drescher D (2010). Application and effectiveness of a mini-implant- and tooth-borne rapid palatal expansion device: the hybrid hyrax. *World J Orthod* 11(4): 323-330.

Yu HS, Baik HS, Sung SJ, Kim KD, Cho YS (2007). Three-dimensional finite-element analysis of maxillary protraction with and without rapid palatal expansion. *Eur J Orthod* 29(2): 118-125.

국 문 요 약

Cone-beam CT를 이용한 성인에서 미니스크류 보강형 급속 구개 확장 장치의 효과

박정진
연세대학교 대학원 치의학과
(지도교수 박영철)

이 연구의 목적은 cone-beam CT 를 이용하여 미니스크류 보강형 RPE (miniscrew assisted rapid palatal expansion, MARPE)를 시행한 확장 전, 후에서의 골격성 치아치조성 변화를 악골의 횡적 부조화를 지닌 성인 교정환자에서 평가하는 것이다.

14 명(여성: 9 명, 남성: 5 명; 평균 나이: 20.1±2.4 세; 범위: 16-26 세)의 성인 환자를 대상으로 하여 MARPE 의 확장 전후에 촬영한 CBCT 영상을 이용하여 연구하였다.

1. 확장 후(T2), 3D 재구성 영상에서 하악골의 mandibular width(Ag-Ag)를 제외한 모든 골격적 치아치조성 측정치(zygoma width, nasal width, maxillary width, middle alveolus width, cervical width)에서 통계적으로 유의성있는 증가가 관찰되었다($P<0.05$).

2. 확장 후(T2), 제1대구치와 소구치의 치근이개 부위에서 nasal cavity width 와 상악의 기저골 폭의 유의성 있는 증가가 관상면에서 관찰되었으며 ($P<0.001$), 제1소구치 부위에서의 변화량이 제1대구치 부위에서의 변화량 보다 크게 나타났다.

3. 확장 후(T2), molar cervical width(C6-C6)에서 zygoma width(Z-Z)까지 상방으로 올라가며, 확장량이 감소되었다.

4. 확장 후(T2), 정중구개봉합부위에서의 확장뿐만 아니라 상악골의 측방 확장 및 전방 이동이 관찰되었다($P < 0.05$).

5. 확장 후(T2), spina nasalis를 제외한 모든 측방 측정치에서 통계적으로 유의성있는 증가를 보였으며, 치조골부위에서 ectocanine의 변화량보다 ectomolare에서의 변화량이 더 컸다($P < 0.01$).

본 연구를 통하여 횡적 부조화를 보이는 성인에서 MARPE 를 이용한 확장치료는 횡적 부조화를 가진 환자에 있어 효과적으로 사용될 수 있음을 확인할 수 있었다. 향후 MARPE 를 이용한 확장치료의 보다 많은 증례에서 장기적인 안정성에 관한 추가연구가 필요하다.

핵심되는 말: 상악골 횡적 부조화, 성인, 미니스크류, RPE, 정중구개봉합, 3D 중첩, CBCT