Midterm observation of reverse reshaping in the heart after transcatheter closure of atrial septal defect and comparison between different age groups

Su-Jin Park

Department of Medicine

The Graduate School, Yonsei University

Midterm observation of reverse reshaping in the heart after transcatheter closure of atrial septal defect and comparison between different age groups

Directed by Professor Jae Young Choi

The Master's Thesis submitted to the Department of Medicine, the Graduate School of Yonsei University in partial fulfillment of the requirements for the degree of Master of Medical Science

Su-Jin Park

June 2013

This certifies that the Master's Thesis
of Su-Jin Park is approved.

Thesis Supervisor: Jae Young Choi

Thesis Committee Member #1: Ki Su Ha

Thesis Committee Member #2: Eu Young Choi

The Graduate School
Yonsei University

June 2013

ACKNOWLEDGEMENTS

It has taken me a long time to get this far and I am thankful for all the people who has helped me through this long and tedious journey. First of all, I thank my supervising professor Dr. Jae Young Choi for guiding me through this thesis and giving me this opportunity and I also thank all the other professors guiding me. I also thank Dr. Jo Won Jung and Dr. Nam Kyun Kim for not giving up on me. Finally, I am thankful to my family for supporting me through all my ups and downs and keeping me their prayers.

<TABLE OF CONTENTS>

ABSTRACT ····· 1

I. INTRODUCTION ····· 3
II. PATIENTS AND METHODS ····· 4
III. RESULTS ····· 7
1. Subjects ····· 7
2. Echocardiographic parameters ····· 8
3. Comparison of echocardiographic parameters ····· 11
IV. DISCUSSION ····· 14
V. CONCLUSION ····· 17

REFERENCES ····· 18
ABSTRACT (IN KOREAN) ····· 22

LIST OF FIGURES

Figure 1A. Measurement of right atrium (RA) and left atrium (LA) maximal dimensions at end-systole. 6
Figure 1B. Measurement of right ventricle (RV) and left ventricle (LV) maximal dimensions at end-diastole. 6
Figure 2A. Measurement of mitral valve regurgitation (MR) regurgitant jet flow area (1) and LA area (2) prior to the procedure. 6
Figure 2B. Measurement of MR regurgitant jet flow area (1) and LA area (2) 3 years after the procedure..... 6
Figure 3. Time course of age related changes in right ventricular end-diastolic diameter (RVEDD)..... 13
Figure 4. Time course of age related changes in mitral regurgitation (MR) area index 13

LIST OF TABLES

Table 1. Characteristics of Subjects ····· 8
Table 2. Echocardiographic measurements before the procedure and at 3 year follow-up in group I ····· 9
Table 3. Echocardiographic measurements before the procedure and at 3 year follow-up in group II. 11
Table 4. Changes between the cardiovascular parameters before the procedure and at 3 year follow-up, compared between group I and II. ····· 12

Midterm observation of reverse reshaping in the heart after transcatheter closure of atrial septal defect and comparison between different age groups

Su-Jin Park

Department of Medicine
The Graduate School of Yonsei University

(Directed by Professor Jae Young Choi)

Background: Comparison between children and adult group about reverse reshaping of cardiac chambers after percutaneous ASD closure has rarely been reported. The aim of this study was to evaluate and compare the cardiovascular geometric changes after percutaneous ASD closure in children and adults.

Methods and Results: Total of 166 ASD patients who underwent transcatheter occlusion with Amplatzer Septal occluder (AGA medical corporation, Plymouth, Minnesota, USA) from July, 2003 to July, 2005 were divided into 2 subgroups according to patients' age as group I (less than 18 years of age) and group II (18 years of age or older), and their echocardiographic parameters were retrospectively analyzed.

Right atrial diameter and right ventricle end diastolic diameter (RVEDD) showed statistically significant decrease ($p<0.01$) and left atrial diameter and left ventricular end diastolic diameter showed statistically significant increase ($p<0.01$) in both groups. The tricuspid regurgitation area index showed

statistically significant decrease ($p<0.01$) and mitral regurgitation area index (MRAI) showed statistically significant increase ($p=0.04$). The change in RVEDD before and after the procedure was significantly higher in group II than in group I ($p=0.048$) and the change in MRAI was also significantly higher in group II than in group I ($p=0.05$).

Conclusions: Therefore, patients who are considered for transcatheter closure of secundum ASD, MR should be carefully examined before and after the procedure.

Key words: atrial spetal defect, reverse remodeling, adult, transcather

Midterm observation of reverse reshaping in the heart after transcatheter closure of atrial septal defect and comparison between different age groups

Su-Jin Park

Department of Medicine
The Graduate School of Yonsei University

(Directed by Professor Jae Young Choi)

I. INTRODUCTION

Atrial septal defect (ASD) causes long-standing left to right shunt, which in result, causes volume overload of the right heart with potential of causing progressive right atrial and ventricular dilatation with dysfunction (remodeling).[1-7] Over time, it results in elevated pulmonary pressure and resistance, systemic embolism, development of atrial arrhythmia, right heart failure, and impairment of left ventricular function secondary to ventriculo-ventricular interactions.[8] As a result, the major aim of ASD closure is the unloading of cardiac volume overload and preventing the progressive cardiac enlargement and the consequent complications.[1-5,9-12]

For quite a while, surgery has been the gold standard for closure of ASD with very low mortality and complication rates. However, percutaneous closure of ASD evolved as an attractive alternative to surgery in pediatric and

adult patients, ascribed to the fact that it is safer and more physiologic.[13]

The geometric changes after the percutaneous ASD closure were sporadically reported in the past, but the comparison between children and adult group on the reverse reshaping of cardiac chambers has rarely been reported.[4,5,9] The right heart volume overload may cause significant tricuspid regurgitation (TR) as well as mitral regurgitation (MR) associated with prolapse of anterior mitral leaflet (AML). However, in spite of the relationship between volume overload and atrio-ventricular (AV) incompetence, it is unclear whether the volume reducing effect after ASD closure may differ according to age. One can hypothesize that the longer the volume overload, the longer reverse reshaping after ASD will take. Therefore it will take longer, or the process maybe incomplete for adults in cardiac reshaping than for children. The aim of this study was to evaluate and compare the cardiovascular geometric changes and AV valve function after percutaneous ASD closure in children and adults.

II. PATIENTS AND METHODS

Subjects

Total of 166 ASD patients who underwent transcatheter occlusion with Amplatzer Septal occluder (AGA medical corporation, Plymouth, Minnesota, USA) during 2 year period of study, from July, 2003 to June, 2005, who

completed at least 3 year follow-up, were retrospectively analyzed. They were divided into 2 subgroups, according to patients' age at the time of the procedure, as group I (less than 18 years of age) and group II (18 years of age or older). Standard transthoracic echocardiographic (TTE) studies were performed according to the recommendations of American Society of Echocardiography[14]. Retrospective analysis of TTE performed prior to the procedure and serially for 3 years after the procedure were performed.

Echocardiographic parameters

Echocardiographic studies were performed by experienced physicians and images were acquired and digitally stored for offline analysis with each study. The maximal transverse diameters of both right and left atrium (RA, LA) were measured during the end systolic phase (Fig. 1A), and both the right and left ventricle (RV, LV) diameters were measured during the end diastolic phase, shown on the apical 4 chamber view (Fig.1B). Tricuspid and mitral regurgitation (TR, MR) were investigated by color Doppler echocardiography and left ventricular ejection fraction (LVEF) was also measured. The severity of MR and TR was assessed by determining the distribution of regurgitant jet flow. Hence, maximal MR jet area and LA area were measured in the same frame, and the TR jet area and RA area were also measured in another same frame (Fig.2). After calculating the color jet flow

area of both MR and TR, the values were indexed by the individual body surface area (BSA, kg/m^2) and these values were defined as MR and TR area index (MRAI and TRAI).

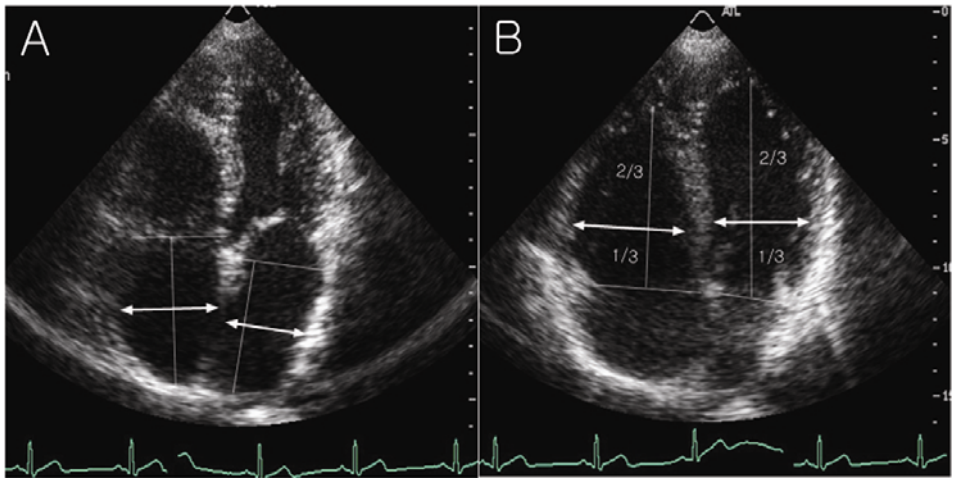

Fig. 1A. Measurement of right atrium (RA) and left atrium (LA) maximal dimensions at end-systole.

Fig. 1B. Measurement of right ventricle (RV) and left ventricle (LV) maximal dimensions at end-diastole.

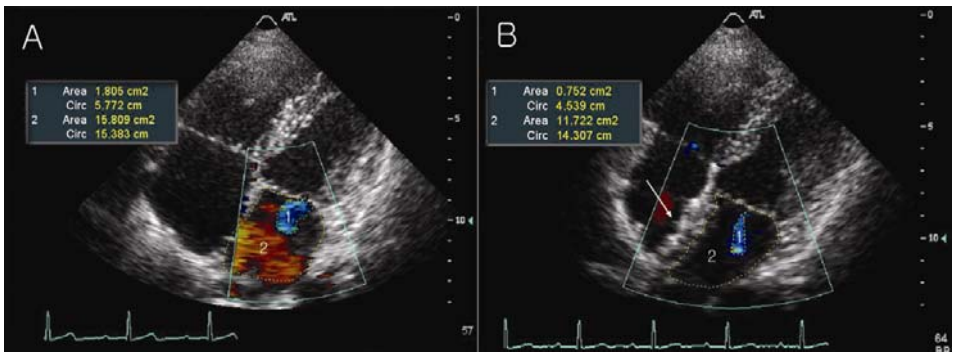

Fig. 2A.. Measurement of mitral valve regurgitation (MR) regurgitant jet flow area (1) and LA area (2) prior to the procedure.

Fig 2B. Measurement of MR regurgitant jet flow area (1) and LA area (2) 3 years after the procedure.

Statistical Analysis

The parametric data of the subjects were presented as mean and standard deviation. Comparison between parameters before the procedure and at 3 year follow-up was performed by paired t-test. Comparison between the two groups was also performed by paired t-test. P-value <0.05 was considered as statistically significant.

III. RESULTS

Subjects

Table 1 shows the characteristics and demographics of the enrolled patients. The mean age of patients in group I was 5.8 years (range 1.2-17), male and female ratio was 1:2.3, the mean weight was 21.9 kg (range 8.3-58), the mean height was 111.3 cm (range 76-178), and the mean BSA was 0.82 kg/m^2 (range 0.66-2.01). The mean age of patients in group II was 38.4 years (range 20-66), male and female ratio was 1:2.1, the mean weight was 59.2 kg (range 42-82), the mean height was 161.9 cm (range 142-182), and the mean BSA was 1.63 kg/m^2 (range 0.70-1.90). The mean balloon occlusive diameter (BOD) size in group I and II were 18.2 cm (range 9-38) and 26.6 cm (range 25-40), respectively. The mean device size in group I was 18.9 cm (range 10-38) and the mean device size in group II was 27.1 cm (range 22-38). The Qp/Qs in group I and II were 2.26 (range 1.54-4.7) and 2.59 (range 1.64-4.8).

Table 1. Characteristics of Subjects

	Group I (n=80)	Group II (n=86)	P-value
Age (years)	5.8±4.6 (1.2-17)	38.4±12.2 (20-66)	<0.01
Male:Female	24:56(1:2.3)	28:58(1:2.1)	NS
Weight (kg)	21.9±14.2 (8.2-58)	59.2±8.7 (42-82)	<0.01
Height (cm)	111.3±28.1 (76-178)	161.9±8.2 (142-182)	<0.01
BSA (kg/m^2)	0.82± 0.35(0.66-2.01)	1.63± 0.15(0.70-1.90)	<0.01
BOD (mm)	18.2±5.6 (9-38)	26.6±6.4 (25-40)	<0.01
Device (mm)	18.9±6.3 (10-38)	27.1±7.2 (22-38)	<0.01
Qp/Qs ratio	2.26±0.67 (1.54-4.7)	2.59±0.64 (1.64-4.8)	<0.01

BSA, body surface area; BOD, balloon occlusive diameter

Echocardiographic parameters of group I

Table 2 shows echocardiographic parameters before and after the procedure in group I. After the procedure, right atrial diameter (RAD) and right ventricular end-diastolic diameter (RVEDD) showed statistically significant decrease ($p<0.01$). The TRAI was also significantly decreased ($p<0.01$). Overall, the right side cardiovascular geometric parameters showed statistically significant decrease after the procedure. After the procedure, left atrial diameter (LAD) and left ventricular end-diastolic diameter (LVEDD) showed statistically significant increase ($p<0.01$) and the MRAI also showed significant increase ($p=0.04$). Overall, the left side cardiovascular geometric parameters showed significant increase after the procedure.

Table 2. Echocardiographic measurements before the procedure and at 3 year follow-up in group I.

	Before	After	P-value
RAD (mm)	36.6±7.0	30.3±5.6	<0.01
LAD (mm)	24.3±5.0	29.5±5.4	<0.01
RVEDD (mm)	36.3±7.5	30.9±5.2	<0.01
LVEDD (mm)	30.4±5.7	38.5±5.9	<0.01
TRAI (mm)	3.05±4.88	1.17±1.16	<0.01
MRAI (mm)	0.13±0.31	0.59±0.79	0.04

RAD, right atrial diameter; LAD, left atrial diameter; RVEDD, right ventricle

end-diastolic dimension; LVEDD, left ventricle end-diastolic dimension; TRAI, tricuspid regurgitation area index; MRAI, mitral regurgitation area index

Echocardiographic parameters of group II

The echocardiographic parameters of group II are shown in Table 3. Corresponding to group I, the RAD and RVEDD in group II showed statistically significant decrease ($p<0.01$), 3 years following the procedure. The TRAI also showed statistically significant decrease ($p<0.01$). For the left side cardiovascular parameters, LAD and LVEDD showed statistically significant increase ($p<0.01$), and MRAI also showed significant increase ($p=0.014$). Overall, the right side cardiovascular geometric parameters decreased and the left side cardiovascular geometric parameters increased after the procedure in the adult group.

Table 3. Echocardiographic measurments before the procedure and at 3 year follow-up in group II.

	Before	After	P-value
RAD (mm)	45.7±7.4	37.5±5.7	<0.01
LAD (mm)	32.7±4.3	36.7±4.7	<0.01
RVEDD (mm)	44.8±7.4	37.5±5.0	<0.01
LVEDD (mm)	39.1±6.4	46.3±5.3	<0.01
TRAI (mm)	2.36±1.85	0.89±1.15	<0.01
MRAI (mm)	0.22±0.54	1.01±0.88	0.014

RAD, right atrial diameter; LAD, left atrial diameter, RVEDD, right ventricle end-diastolic dimension; LVEDD, left ventricle end-diastolic dimension; TRAI, tricuspid regurgitation area index; MRAI, mitral regurgitation area index

Comparison of echocardiographic parameters between the 2 groups

The change between the cardiovascular geometric parameters before and after the transcatheter procedure was compared between group I and II and the parameters are described in Table 4.

Table 4. Changes between the cardiovascular parameters before the procedure and at 3 year follow-up, compared between group I and II.

	Group I (n=80)	Group II (n=86)	P-value
D-RAD (mm)	-6.33±4.89	-8.21±5.57	0.68
D-LAD (mm)	5.21±4.50	4.05±3.97	NS
D-RVEDD (mm)	-5.37±4.58	-7.27±5.20	0.048
D-LVEDD (mm)	8.09±4.09	7.14±5.09	NS
D-TRAI (mm)	-1.88±4.06	-1.47±1.42	NS
D-MRAI (mm)	0.47±0.77	0.79±0.87	0.04

D-RAD, difference of right atrial diameter; D-LAD, difference of left atrial diameter; D-RVEDD, difference of right ventricle end-diastolic dimension; D-LVEDD, difference of left ventricle end-diastolic dimension; D-TRAI, difference of tricuspid regurgitation area index; D-MRAI, difference of mitral regurgitation area index

The change in RVEDD was significantly higher in group II than in group I (Fig. 3, p=0.048). The change in MRAI was significantly higher in group II than in group I (Fig. 4, p=0.04). The remaining parameters did not show statistical significance between the 2 groups.

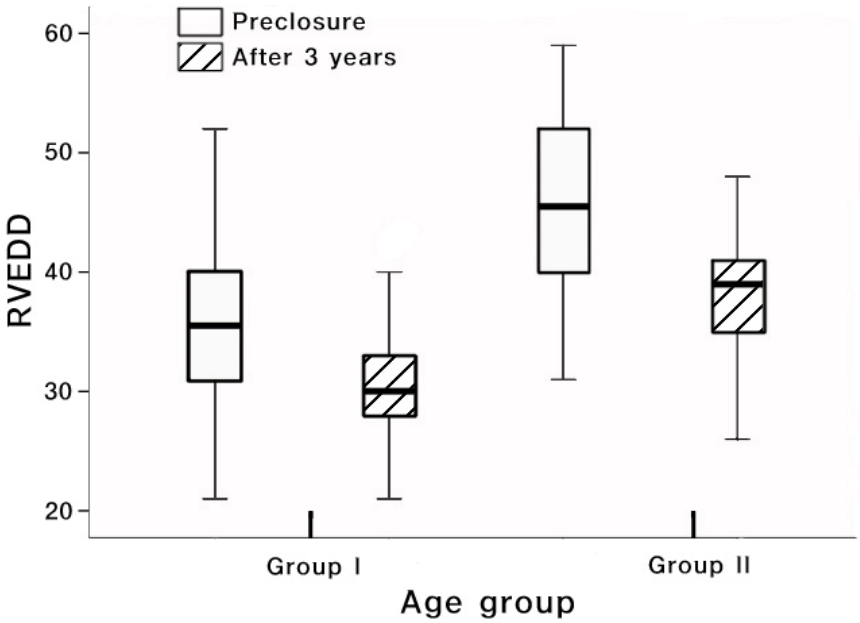

Fig. 3. Time course of age related changes in right ventricular end-diastolic diameter (RVEDD)

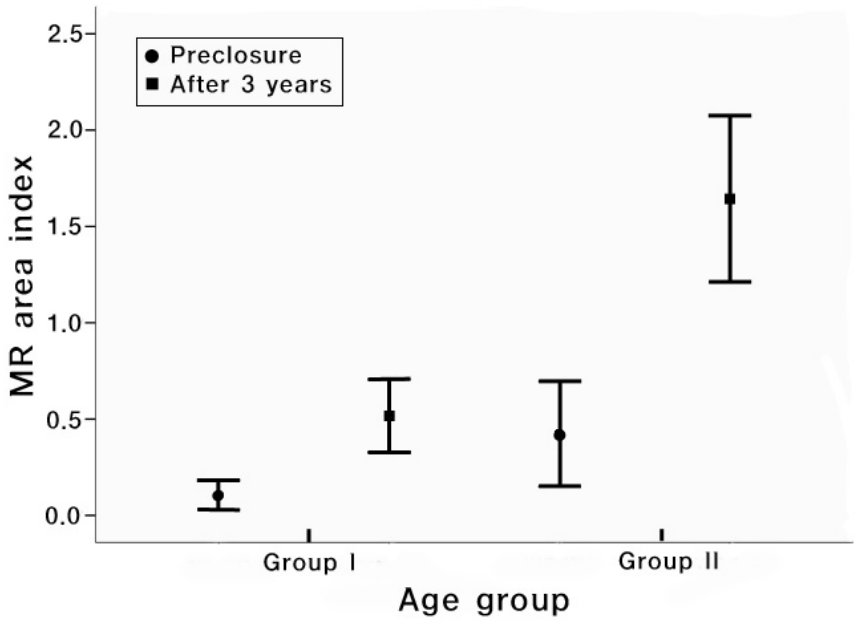

Fig. 4. Time course of age related changes in mitral regurgitation (MR) area index

IV. DISCUSSION

Compared to surgical correction of secundum ASD, transcatheter closure can be a more physiologic method for reversion of the already remodeled myocardium. Transcatheter closure is probably more physiologic because of avoiding ‘opening’ of the heart and ‘incisional’ scars. Therefore our study can be used to evaluate the relatively ‘natural’ course of the heart after correction of secundum ASD by excluding the variables and consequences involved in surgical correction.

Our results demonstrated a significant reduction in right heart size and a significant increase in left heart size following the transcatheter closure of secundum ASD. Our study also demonstrates that there is a statistically significant decrease in TRAI and increase in MRAI after percutaneous closure. We can presume the reason for the changes in the right heart as the removal of left-to-right shunt, resulting in decreased RV preload and right heart dilatation with consequent restoration of tricuspid annulus diameter and coaptation of leaflets. On the contrary, the left ventricle, which had been hemodynamically-underloaded before closure of the defect, encounters an opposite situation. Left heart volume is expanded by increased preload, and the configuration of the heart restores, which was physically-compressed during the diastolic phase before the procedure. Nevertheless, the structural damage to mitral valve and its apparatus might play a role in the persistence or worsening of preexisted MR, especially in adults with long-standing

distorted geometry of mitral annulus and valve apparatus. In previous literatures, it was reported that prolapse of anterior mitral leaflet is frequently accompanied by secundum ASD[15] and preoperative MR might be aggravated after closure of the defect [16]. Indeed, consistent with the previous reports, substantial numbers of our patients showed worsening of MRAI after the procedure, probably because of the irreversible structural damage to mitral valve and its apparatus[15,16].

In the comparison between the two groups categorized by age, the results show that the change of RVEDD and MRAI in adults is greater than in the younger group, reflecting a close relationship between RV dilatation and the long-standing left to right shunt. In spite of the larger and longer shunt in group II, established by a higher Qp/Qs ratio, the elimination of the shunt promotes reduction of the right heart volume to a greater extent.

Reverse reshaping after secundum ASD closure is believed to be related to the subject's age at the time of procedure[9]. Because the period of left to right shunt in adults are longer compared to the pediatric population, we can assume that there will be more severe structural change to mitral valve and its apparatus and possibly damage the myocardium (restriction), hence the adaptation of the new cardiac environment will take longer or will be incomplete after closing the defect. Since the disparity between both ventricle geometry and potential myocardial property will gradually be influenced as the time passes, and since the MR developed due to volume

overload will not improve, but rather worsen after the device insertion in the adult group, this can be another reason not to postpone the correction procedure until adulthood. Our data shows that whatever the reason for the development of MR, the grade of MR will be same or worsen in most of the patients, after the closure of the defect. Nonetheless, further investigation in search of the compound factors involved in the exacerbation of MR is called for.

There have been many studies on cardiac reverse remodeling in patients with stent insertion after an attack of myocardial infarction and after stem cell therapy, as well as patients with resynchronization therapy in heart failure.[17-20] However, the concept of reverse remodeling in patients who underwent device closure of secundum ASD has been scarcely reported. Since reverse reshaping, which maybe a sign of reverse remodeling, is evident in patients with device closure of secundum ASD, more intensive investigation in finding the related factors is pertinent. Our study can be the cornerstone for more intense and detailed research in this field and be the grounds for advancement in future techniques newly being researched. Yet, the current article only addresses the geometric change of the heart, whereas the reverse remodeling not only involves volumetric change, but also involves pressure, cardiac function, and arrhythmic changes. Our study limitation should be taken under consideration and further investigation with larger pool of patients and longer period of observation with more variables should follow in the future.

A more advanced technology in echocardiography such as tissue Doppler imaging, 2-dimensional speckle tracking, and 3-dimensional echocardiography can also help in the proper evaluation of the change in myocardium, in the future.[21]

V. CONCLUSION

Midterm follow-up of patients of all age group after transcatheter closure of secundum ASD demonstrates a statistically significant decrease in right heart size and severity of TR, whereas the left heart size and severity of MR increase. Furthermore, severity of MR in adults shows a greater increase than that of children.

In conclusion, midterm follow-up results show that transcatheter closure is an excellent and physiologic modality for the correction of secundum ASD, but in patients with MR, it can exacerbate the already existing regurgitation, especially in adult population. Therefore, patients with MR should be carefully examined before considering transcatheter closure of secundum ASD, and also should be thoroughly investigated after the procedure. In addition, further study should be undertaken to examine the variables involved in the worsening of MR after transcatheter closure and longer follow-up period with larger pool of patients should also be considered.

REFERENCES

1. Giardini A, Donti A, Formigari R, Specchia S, Prandstraller D, Bronzetti G, Bonvicini M, Picchio FM. Determinants of cardiopulmonary functional improvement after transcatheter atrial septal defect closure in asymptomatic adults. Journal of the American College of Cardiology 2004;43:1886-91.

2. Schoen SP, Kittner T, Bohl S, Braun MU, Simonis G, Schmeisser A, Strasser RH. Transcatheter closure of atrial septal defects improves right ventricular volume, mass, function, pulmonary pressure, and functional class: a magnetic resonance imaging study. Heart 2006;92:821-6.

3. Salehian O, Horlick E, Schwerzmann M, Haberer K, McLaughlin P, Siu SC, Webb G, Therrien J. Improvements in cardiac form and function after transcatheter closure of secundum atrial septal defects. Journal of the American College of Cardiology 2005;45:499-504.

4. Du ZD, Cao QL, Koenig P, Heitschmidt M, Hijazi ZM. Speed of normalization of right ventricular volume overload after transcatheter closure of atrial septal defect in children and adults. The American journal of cardiology 2001;88:1450-3, A1459.

5. Veldtman GR, Razack V, Siu S, El-Hajj H, Walker F, Webb GD, Benson LN, McLaughlin PR. Right ventricular form and function after percutaneous atrial septal defect device closure. Journal of the

American College of Cardiology 2001;37:2108-13.

6. Lam Y, Yu C. Improvement of biventricular function after transcatheter closure of atrial septal defect: a case report. Catheterization and cardiovascular interventions 2006;68:775-7.

7. Kort HW, Balzer DT, Johnson MC. Resolution of right heart enlargement after closure of secundum atrial septal defect with transcatheter technique. Journal of the American College of Cardiology 2001;38:1528-32.

8. Helber U, Baumann R, Seboldt H, Reinhard U, Hoffmeister HM. Atrial septal defect in adults: cardiopulmonary exercise capacity before and 4 months and 10 years after defect closure. Journal of the American College of Cardiology 1997;29:1345-50.

9. Kitano M, Yazaki S, Sugiyama H, Yamada O. The influence of morphological changes in amplatzer device on the atrial and aortic walls following transcatheter closure of atrial septal defects. Journal of interventional cardiology 2009;22:83-91.

10. Douglas PS, DeCara JM, Devereux RB, Duckworth S, Gardin JM, Jaber WA, Morehead AJ, Oh JK, Picard MH, Solomon SD, Wei K, Weissman NJ. Echocardiographic imaging in clinical trials: American Society of Echocardiography standards for echocardiography core laboratories: endorsed by the American College of Cardiology Foundation. Journal of the American Society of Echocardiography

2009;22:755-65.

11. Nagata S, Nimura Y, Sakakibara H, Beppu S, Park YD, Kawazoe K, Fujita T. Mitral valve lesion associated with secundum atrial septal defect. Analysis by real time two dimensional echocardiography. British heart journal 1983;49:51-58.

12. Speechly-Dick ME, John R, Pugsley WB, Sturridge MF, Swanton RH. Secundum atrial septal defect repair: long-term surgical outcome and the problem of late mitral regurgitation. Postgraduate Medical Journal 1993;69:912-15.

13. Ling X, Xiang-Hua F, Jun L, Xin-Wei J, Wei-Li W, Xin-Shun G, Chao D, Yun-Fa J, Guo-Zhen H, Wei-Ze F, Jing Z. Equilibrium radionuclide angiography for evaluating the effect of percutaneous coronary intervention on ventricular aneurysm formation and systolic synchrony in patients with acute myocardial infarction. Int J Cardiovasc Imaging 2009.

14. Magne J, Dubois M, Champagne J, Dumesnil JG, Pibarot P, Philippon F, O'Hara G, Senechal M. Usefulness of NT-pro BNP monitoring to identify echocardiographic responders following cardiac resynchronization therapy. Cardiovascular Ultrasound [NLM - MEDLINE] 2009;7:39.

15. Donal E, Tan K, Leclercq C, Ollivier R, Derumeaux G, Bernard M, de Place C, Mabo P, Daubert JC. Left Atrial Reverse Remodeling and

Cardiac Resynchronization Therapy for Chronic Heart Failure Patients in Sinus Rhythm. J Am Soc Echocardiogr 2009.

16. Scuteri L, Rordorf R, Marsan NA, Landolina M, Magrini G, Klersy C, Frattini F, Petracci B, Vicentini A, Campana C, Tavazzi L, Ghio S. Relevance of echocardiographic evaluation of right ventricular function in patients undergoing cardiac resynchronization therapy. Pacing and clinical electrophysiology 2009;32:1040-49.

17. Marcucci C, Lauer R, Mahajan A. New echocardiographic techniques for evaluating left ventricular myocardial function. Seminars in cardiothoracic and vascular anesthesia 2008;12:228-47.

ABSTRACT

이차공심방중격결손의 경피적폐쇄 후의 소아와 어른의 심장의 역재구도 변화 비교에 대한 중간보고

<지도교수 최재영>

연세대학교 대학원 의학과

박수진

Background: 이차공 심방중격결손의 경피적폐쇄 후 심장의 역재구도에 대해 어른과 소아에서의 비교에 대한 연구는 아직 연구된 것이 많지 않다. 본 연구의 목적은 심방중격결손의 경피적폐쇄 후 심장의 기하학적 변화에 대해 소아와 어른을 비교한 것이다.

Methods and Results: 심방중격결손을 진단 받고 경피적폐쇄를 시행한 전체 166명의 환자를 대상으로 진행하였다. 기간은 2003년 7월부터 2005년 7월까지의 2년간 Amplatzer septal occlude (AGA medical corporation, Plymouth, Minnesota, USA)를 사용하여 비수술적 폐쇄를 시행한 환자들로 18세 미만의 소아 환자를 group I, 18세 이상의 어른을 group II로 정의 하였다. 이들의 심초음파적 수치들과 의료기록을 후향적으로 연구하였다.

Discussion: 우심방의 지름과 우심실확장기의 지름은 통계학적으로 유의하게 저하된 ($p<0.01$) 결과를 보였으며 좌심방과 좌심실확장기

의 지름 또한 통계학적으로 유의하게 상승된 결과를 보였다 ($p<0.01$). 시술 전과 시술 후를 비교하였을 때 group II가 group I 보다 통계학적으로 유의하게 큰 변화를 보였으며, MRAI 또한 group II가 group I 보다 통계학적으로 유의하게 높았다.

Conclusions: 결론적으로 심방중격결손을 경피적으로 폐쇄할 계획이 있는 환자에서는 승모판역류에 대한 자세한 검사가 필요할 것으로 사료된다.

핵심되는 말: 심방중격결손증, 역재구도, 소아, 어른, 경피적폐쇄