Stand-Alone Cervical Cages versus Anterior Cervical Plate in Two Level Cervical Anterior Interbody Fusion Patients: Clinical Outcomes and Radiologic Changes

Jae Keun Oh

Department of Medicine

The Graduate School, Yonsei University

Stand-Alone Cervical Cages versus Anterior Cervical Plate in Two Level Cervical Anterior Interbody Fusion Patients: Clinical Outcomes and Radiologic Changes

Directed by Professor Keungnyun Kim

The Master's Thesissubmitted to the Department of Medicine
the Graduate School of Yonsei University
in partial fulfillment of the requirements for the degree
of Master of Medical Science

Jae Keun Oh

June 2011

This certifies that the Master's Thesis of

Jae Keun Oh is approved.

[Signature]

Thesis Supervisor : Keung Nyun Kim

[Signature]

[Sung Uk Kuh: Thesis Committee Member#1)

[Signature]

[Jin Woo Lee: Thesis Committee Member#2)

The Graduate School

Yonsei University

June 2011

ACKNOWLEDGEMENTS

I would like to express my gratitude to everyone who gave me the opportunity to complete this thesis. I want to thank Professor Keung Nyun Kim for his advise on the preparation, planning, and analysis of this thesis. I also thank Professor Sung Uk Kuh, Professor Jin Woo Lee, and all the staff members of neurosurgery department.

<TABLE OF CONTENTS>

LIST OF FIGURES

LIST OF TABLES

ABSTRACT

Stand-Alone Cervical Cages versus Anterior Cervical Plate in Two Level Cervical Anterior Interbody Fusion Patients: Clinical Outcomes and Radiologic Changes

Jae Keun Oh

Department of Medicine

The Graduate School, Yonsei University

(Directed by Professor Keung Nyun Kim)

Anterior cervical discectomy and fusion (ACDF) has become a standard surgical procedure for treating degenerative disc disease associated with radiculopathy or myelopathy. Relatively good results have been reported when performing ACDF with cage alone (ACDF-CA); however, controversy remains regarding the high incidence of complications such as cage subsidence, kyphotic deformity, and pseudoarthrosis. We compared and analyzed the radiologic and clinical outcomes of ACDF-CA and ACDF-CPC for the surgical treatment of two contiguous level degenerative disc disease of

the cervical spine to evaluate the efficacy of metal plate augmentation.

A total of 54 consecutive patients who underwent 2-level ACDF-CA or ACDF-CPC after suffering from cervical radiculopathy were divided into two groups; Group A (n=28) underwent ACDF-CA; Group B (n=26) underwent ACDF-CPC. Fusion rate, global and segmental kyphosis, disc height, and subsidence rate were assessed by radiolographs. Clinical outcomes were assessed using the Robinson`s criteria.

Solid fusion was achieved in 96.43% (27/28) in group A and in 96.15% (25/26) in group B. Fusion segmental kyphosis of more than 5° occurred in 14.29% (4/28) of group A and in 7.69% (2/26) of group B; however, there was no statistical difference between the two groups (P>0.05). Subsidene occurred in 35.71% (10/28) of group A as compared to 11.54% (3/26) of group B (P<0.05). Clinical outcomes were similar in the two treatment groups.

The use of cage and plate construct in 2-level ACDF results in shorter fusion duration, lower subsidence rate than that of cage alone; however, there is no significant difference in postoperative global and segmental alignment and clinical outcomes between groups.

Key words : Anterior cervical fusion, PEEK cage, plate construct, subsidence, fusion.

Stand-Alone Cervical Cages versus Anterior Cervical Plate in Two Level Cervical Anterior Interbody Fusion Patients: Clinical Outcomes and Radiologic Changes

Jae Keun Oh

Department of Medicine

The Graduate School, Yonsei University

(Directed by Professor Keung Nyun Kim)

I. INTRODUCTION

Anterior cervical discectomy and fusion (ACDF) has become a standard surgical procedure for treating degenerative disc disease associated with radiculopathy or myelopathy.[1-2] Many modifications of this technique have been reported since its original description by Smith and Robinson and the later report by Cloward.[1,3] Although ACDF for treatment of degenerative cervical disease is a highly successful procedure, its success rates decline in

multilevel discectomies as the number of levels increases.[4-5]

Relatively good results have been reported when performing ACDF with cage alone (ACDF-CA)[6]; however, controversy remains regarding the high incidence of complications such as cage subsidence, kyphotic deformity, and pseudoarthrosis.[7-8]

Long-term clinical and radiological outcomes of two level contiguous ACDF operations using polyetheretherketone (PEEK) cages have been examined in several previous studies.[9-10] We compared and analyzed the radiologic and clinical outcomes of ACDF-CA and ACDF-CPC for the surgical treatment of two contiguous level degenerative disc disease of the cervical spine to evaluate the efficacy of metal plate augmentation.

II. MATERIALS AND METHODS

1. Materials

Patients who presented at our hospital between March 2007 and March 2009 with degenerative cervical radiculopathy resistant to conservative treatment with no history of prior cervical surgery were included. Patients with trauma, infection, or neoplasms were excluded. Indications for surgery included intractable radiculopathy and myelopathy, or a combination of the two, due to nerve root or spinal cord compression and compatible magnetic resonance imaging findings. ACDF-CA was primarily performed during the first half of study, and ACDF-CPC was primarily performed during the latter half. No specific guidelines or indications were used in dividing the patients into these two groups. Group A consists of 28 subjects who underwent ACDF-CA. Group B consists of 26 subjects who underwent ACDF-CPC. Regarding surgical levels, in group A there were two at levels C3-C5, 15 at C4-C6, and 11 at C5-7. In group B there were three at levels C3-C5, nine at C4-C6, and 14 at C5-C7. The mean follow-up period was 23.4 (12-46) months for group A, and 20.6 (12-36) months for group B. The mean age was 57.9 (43-72) years in group A, and 54.3 (31-71) years in group B. Group A consisted of 13 males and 15 females, and group B consisted of 20 males and six females (Table 1).

Table 1. Patients Demographic Data

	Group A	Group B
Cases	28	26
Mean age (range)*	57.9 (43-72)	54.3 (31-71)
Male	13	20
Female	15	6
Mean F/U (range)†	23.4 (12-46)	20.6 (12-36)
*Units = years †Units = months		

2. Surgical Methods

The surgical procedure was performed as described by Smith and Robinson.[3] After discectomy was performed, the posterior longitudinal ligament with posterior bony spur or uncovertebral joint was removed when the surgical microscope revealed cervical spondlyosis or foraminal pathology. The endplate cartilage was also removed using a curette. The upper and lower endplates were prepared by removing the overlying cartilage, preserving the hardest subchondral bone. Vertebral bodies were distracted with a Caspar distractor and an optimal PEEK cage was selected (Solis® cage, Stryker Spine). The cage was horseshoe-shaped and contained a hollow cylinder that was filled with a bone graft. The cage also had retention teeth as well as bilateral titanium spikes on the superior and inferior surfaces. A PEEK cage packed with DBM was inserted into the disc space. In cases with plate augmentation, we used an anterior cervical plate (Zephir® anterior cervical system, Medronic

Sofamor Danek). All patients in both groups used a Philadelphia collar for 4 weeks.

3. Methods

Clinical and radiologic follow-up was performed immediately after surgery, and then one, three, six, twelve and 24 months after surgery. Spinal alignment and fusion status were assessed with anteroposterior and lateral (neutral, flexion, and extension) radiographs. An independent radiologist evaluated the radiographs without knowledge of the clinical outcome.

Fusion was defined as less than 2° movement on lateral flexion/extension views, the presence of bridging trabecular bone between the endplates on AP/lateral views, lack of implant failure signs of the anterior plate system, and less than 50% radiolucency in the perimeter surrounding the cage.

Cervical lordosis was measured using Cobb`s angle. Global alignment was measured by Cobb`s angle between the inferior endplate of the C2 vertebral body and the inferior endplate of the C7 vertebral body. Regional alignment was measured using Cobb`s angle between the upper endplate of the most cranial vertebral body and the lower endplate of the most caudal vertebral body (Figure 1).

Figure 1.

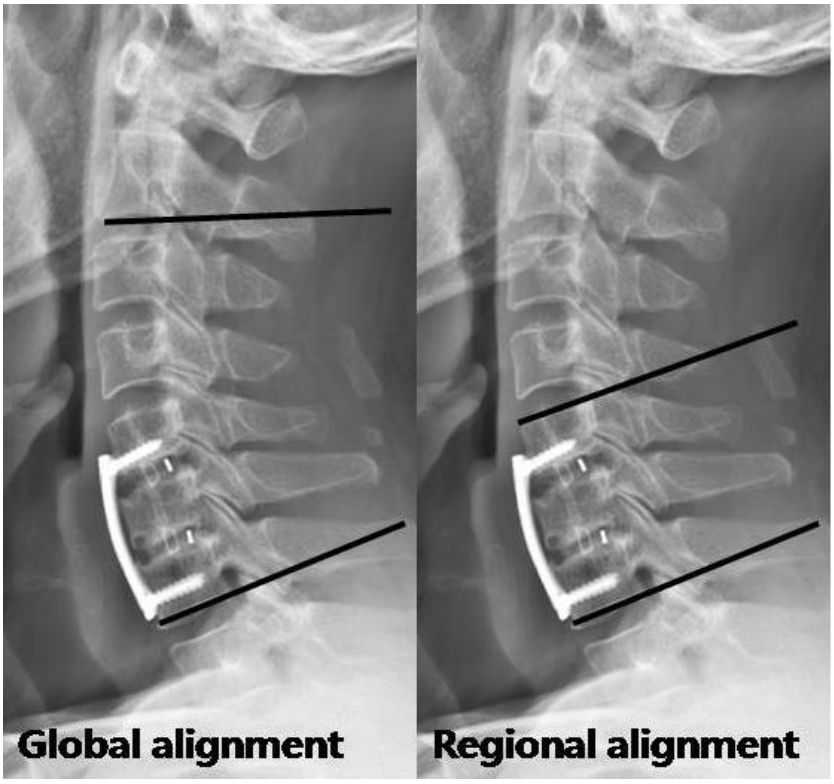

Cage subsidence was defined as greater than 6mm of distance between the midpoint of the upper margin of the upper vertebral body and the lower margin of the lower vertebral body (Figure 2).

Figure 2.

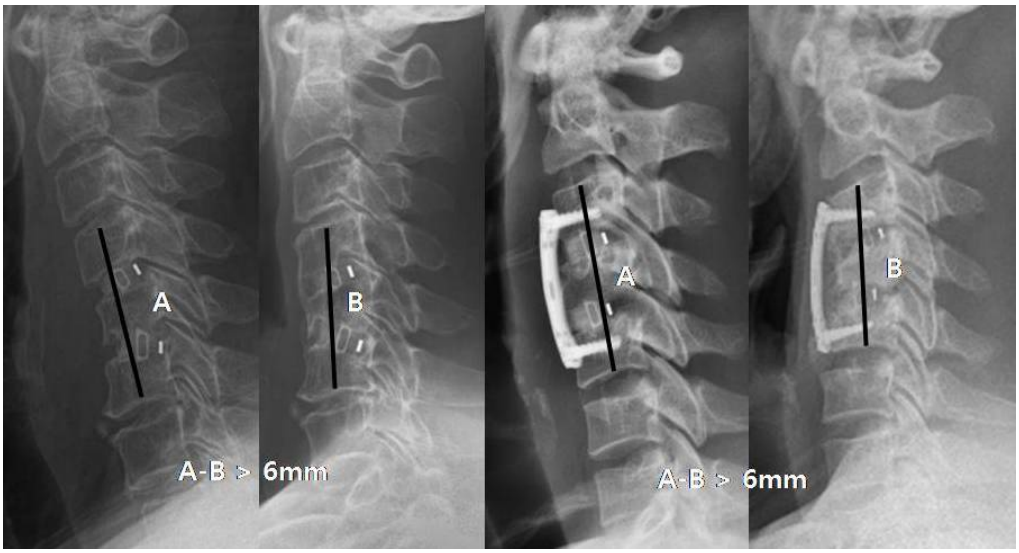

Clinical outcomes were assessed using Robinson`s criteria (Table 2).[11]

Table 2. Robinson`s criteria

Outcome	Pain	Medication	Activity	Work Status
Excellent	None	None	Normal	Normal
Good	Mild	Occasional NSAIDs	Normal	Normal
Fair	Moderate	Frequent NSAIDs	Restricted	Limited
Poor	Severe	Oral narcotics	Incapacitated	Disabled

4. Statistical Analysis

Statistical analysis was carried out using Kruskal-Wallis test and Mann-Whitney test with SPSS (Statistical Package for Social Science) for Windows Release 14.0 to analyze the differences in outcomes. A *p* value less than 0.05 was considered statistically significant.

III. RESULTS

1. Radiologic Results

At the final follow-up, the fusion rates were 100% in 96.43% (27/28) in group A and in 96.15% (25/26) in group B. However, the mean fusion time was 7.39 ± 2.67 in group A and 4.54 ± 2.86 in group B. This difference was statistically significant (Table 3, Mann Whitney test, $P < 0.001$).

Table 3. Fusion Rate and Mean Fusion Time

Group	A	B	P
Fusion rate	28(100%)	26(100%)	1.000
Mean fusion time*	7.39 ± 2.67	4.54 ± 2.86	<0.001
*Units = months			

In group A, the global lordotic angle was 11.99 ± 12.00 before the operation, 7.80 ± 10.95 immediately post-operation, and 8.74 ± 11.19 at final follow-up. The lordotic angle of the fusion segment in group A was 1.59 ± 8.81 before the operation, 2.04 ± 8.87 immediately post-operation, and -0.09 ± 8.26 at final follow-up. In group B, the global lordotic angle was 14.44 ± 8.29 before the operation, 10.53 ± 6.50 at immediately post-operation, and 9.61 ± 8.91 at final follow-up. The lordotic angle of the fusion segment in

group B was 1.98 ± 8.90 before the operation, 4.19 ± 6.29 immediately post-operation, and 1.50 ± 6.66 at final follow-up. However, there are not enough valid cases to perform the statistical analysis in the explanation of the meaning that lordotic angle was changed (Table 4).

Table 4. Mean lordotic angle of global and fusion segment

Group	A		B	
	Global	Segment	Global	Segment
Preop*	11.99 ± 12.00	1.59 ± 8.81	14.44 ± 8.29	1.98 ± 8.90
Postop immediately†	7.80 ± 10.95	2.04 ± 8.87	10.53 ± 6.50	4.19 ± 6.29
Postop final	8.74 ± 11.19	-0.09 ± 8.26	9.61 ± 8.91	1.50 ± 6.66
*Preoperative mean lordotic angle (°) †Postoperative mean lordotic angle (°)				
Kyphosis more than 5°(cases)	3/28 (10.71%)	4/28 (14.29%)	5/26 (19.23%)	2/26 (7.69%)

The degree of change in disc height of the fusion segments between the final disc height and the measurements taken immediately post-operation was 4.34 ± 2.49 in group A, 4.16 ± 2.24 in group B. Cage subsidence was observed in 10 cases in group A and in three cases in group B. There was a statistically significant difference not in disc height change but in cage subsidence between groups A and B (Table 5, Mann Whitney test, $P = 0.687$, $P = 0.038$).

Table 5. Change in Disc Height and Subsidence

	A	B	P
Postop Disc Height*	54.15 ± 4.30	57.02 ± 3.98	
Final Disc Height†	49.81 ± 4.20	52.95 ± 3.45	
Disc Height change	4.34 ± 2.49	4.16 ± 2.24	0.687
Cage subsidence‡	10/28 (35.71%)	3/26 (11.54%)	0.038

*Immedicate postoperative fusion segment height (mm)
†Final fusion segment height (mm)
‡Number

2. Clinical Outcomes

According to the method described by Robinson et al,[11] 82.14% (23/28) of cases in group A and 96.15% (25/26) in group B yielded outcomes with a grade higher than "good" (Table 5, Fisher`s exact test, P=0.2670).

Table 6. Robinson`s Clinical Outcome Assessment

	A	B	P
Excellent	15/28 (53.57%)	21/26 (80.77%)	
Good	8/28 (28.57%)	4/26 (15.38%)	
Fair	4/28 (14.29%)	1/26 (3.85%)	
Poor	1/28 (3.57%)	0/26 (0%)	
> Good	23/28 (82.14%)	25/26 (96.15%)	0.2670

3. Complication

There was only one case with a plate-related complication such as screw back-out or plate bending (Figure 3).

Figure 3.

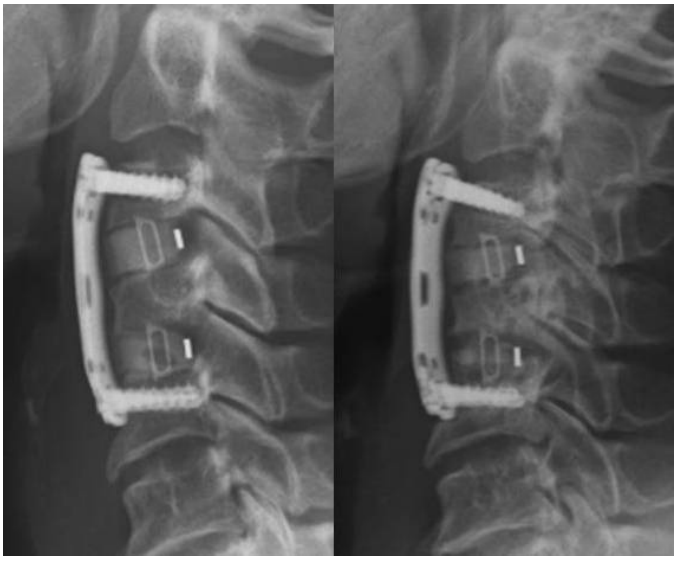

However, revision surgery was not indicated because the patient was asymptomatic. This case showed evidence of fusion in subsequent visits.

In group A, there was one revision surgery because of disease in the adjacent level. An upper level arthroplasty was done 36 months after the first operation.

IV. DISCUSSION

Anterior cervical decompression and fusion (ACDF) has been widely used as a surgical treatment for cervical spinal disorders, including spondlyosis, myelopathy, herniated discs, trauma, and degenerative disc disease. The consensus holds that the success of this procedure relies on thorough decompression and development of solid osseous fusion. According to the literature, the use of autologous bone grafts, allografts, bone substitutes, internal fixation, or any graft remains controversial.[12-14]

We compared and analyzed the radiologic and clinical outcomes of ACDF-CA and ACDF-CPC for the surgical treatment of two contiguous level degenerative disc disease of the cervical spine. In our study, no specific guidelines or indications were used to divide the patients among the two groups.

Some authors have reported that ACDF-CA has the advantages of shorter operation time, minimal blood loss, and relative simplicity as compared to ACDF-CPC. The plate complication rate varies from 2.2% to 24.0%, including screw pull-out; screw breakage; injury to the laryngeal nerve, esophagus, spinal cord, or root; vertebral artery injury; and wound infection.[4,15] In our study, there was one plate-related complication among the 26 cases (3.8%). In that case, revision surgery was not indicated because the patient was asymptomatic. This case showed evidence of fusion in subsequent

visits.

Some articles have shown that the use of a cage and plate construct in ACDF results in more lordotic alignment, increased disc height, higher fusion rates, lower subsidence rates, and lower complication rates than that of cage alone; however, there is no significant difference in clinical outcomes between groups.[16] The results of our study showed that ACDF-CPC had shorter fusion time and less subsidence than ACDF-CA. However, there were no significant differences in global and segment alignment and in clinical outcomes between the groups.

Initial stability is also important for reducing cage subsidence. In an *ex vivo* study using human cadaveric spine segments, the biomechanical results for the three cages and bone cement were compared.[17] The three cages acted as an alternative to bone cement in providing the primary stabilizing effect of cervical interbody fusion. In that study, the initial stability of stand-alone interbody cages was compared with that of the cortical bone or the plate system. In flexion and extension, the plate had a significantly smaller range of motion than the cage and the autograft, and the cage had a significantly greater range of motion than the intact spine. The results of another biomechanical study suggested that the cervical interbody cage should be supplemented with additional external or internal support to prevent excessive motion in flexion and extension.[18]

Maintenance of cervical alignment is an important factor, particularly in

multilevel disease, because misalignment after spinal fusion promotes degenerative changes in the intervertebral levels adjacent to the fused segment.[19-22] Katsuura et al. reported that local kyphosis at the fused segment was observed in only 13% of patients with single-level intervertebral fusion, but in 53% of patients with multiple-level fusion.[21] They also noted that the use of an anterior plate was effective in maintaining local lordosis in patients with anterior multiple-level fusion for degenerative disorders.[20] Wang et al. reported significantly less disc space collapse and kyphotic deformity with plated fusion than with non-plated fusion.[23] Fujibayashi et al. showed that 44% of patients treated with a stand-alone cage exhibited a loss of lordotic alignment of more than 5°. However, other groups have reported preservation of preoperative lordosis at final follow-up in patients who underwent multilevel ACDF-CA.[4,24-25] In our study, however, there was no significant difference in postoperative global and segmental alignment between the two groups. In both groups, the final postoperative kyphosis was higher than it was immediately post-operation. We believe that the reason for the increasing kyphosis is the natural aging process.

Many studies have corroborated the trend toward earlier development of adjacent segment disease with instrumentation following lumbar or lumbosacral fusion. The immediate rigidity produced by instrumentation causes greater stress, leading to accelerated degeneration in the neighboring levels.[26-27] In cervical fusion, we thought the same situation was occurring

after ACDF. Thus, in the future, it will be necessary to study adjacent segment diseas between ACDF-CA and ACDF-CPC.

The short follow-up period of this study does not allow for a thorough evaluation of the development of adjacent level degeneration. Therefore, long-term follow-up studies are necessary, which we plan to pursue in the future. Another limitation of this study is that it is retrospective. Thus, a prospective randomized study will be required in the future.

V. CONCLUSION

The use of a cage and plate construct in 2-level ACDF results in shorter fusion duration and lower subsidence rate than cage alone; however, there is no significant difference in postoperative global and segmental alignment and in clinical outcomes between the groups.

REFERENCES

1. Cloward RB. The anterior approach for removal of ruptured cervical disks. *J Neurosurg* 1958;15:602-17.
2. Gore DR, Sepic SB. Anterior cervical fusion for degenerated or protruded discs. A review of one hundred forty-six patients. *Spine (Phila Pa 1976)* 1984;9:667-71.
3. Smith GW, Robinson RA. The treatment of certain cervical-spine disorders by anterior removal of the intervertebral disc and interbody fusion. *J Bone Joint Surg Am* 1958;40-A:607-24.
4. Demircan MN, Kutlay AM, Colak A, et al. Multilevel cervical fusion without plates, screws or autogenous iliac crest bone graft. *J Clin Neurosci* 2007;14:723-8.
5. Heidecke V, Rainov NG, Marx T, et al. Outcome in Cloward anterior fusion for degenerative cervical spinal disease. *Acta Neurochir (Wien)* 2000;142:283-91.
6. Vavruch L, Hedlund R, Javid D, et al. A prospective randomized comparison between the cloward procedure and a carbon fiber cage in the cervical spine: a clinical and radiologic study. *Spine (Phila Pa 1976)* 2002;27:1694-701.
7. Hacker RJ. Threaded cages for degenerative cervical disease. *Clin Orthop Relat Res* 2002:39-46.
8. Majd ME, Vadhva M, Holt RT. Anterior cervical reconstruction using titanium cages with anterior plating. *Spine (Phila Pa 1976)* 1999;24:1604-10.
9. Barsa P, Suchomel P. Factors affecting sagittal malalignment due to cage subsidence in standalone cage assisted anterior cervical fusion. *Eur Spine J* 2007;16:1395-400.
10. Kulkarni AG, Hee HT, Wong HK. Solis cage (PEEK) for anterior cervical fusion: preliminary radiological results with emphasis on fusion and subsidence. *Spine J* 2007;7:205-9.
11. Riley LH, Jr., Robinson RA, Johnson KA, et al. The results of anterior interbody fusion of the cervical spine. Review of ninety-three consecutive cases. *J Neurosurg* 1969;30:127-33.
12. Walker AE, Robinson RA. [Anterior cervical fusion]. *Dia Med* 1962;34(Special):894-900.
13. Savolainen S, Rinne J, Hernesniemi J. A prospective randomized study of anterior single-level cervical disc operations with long-term follow-up: surgical fusion is unnecessary. *Neurosurgery* 1998;43:51-5.
14. Thalgott JS, Fritts K, Giuffre JM, et al. Anterior interbody fusion of the cervical spine with coralline hydroxyapatite. *Spine (Phila Pa 1976)* 1999;24:1295-9.
15. Kaiser MG, Haid RW, Jr., Subach BR, et al. Anterior cervical plating

enhances arthrodesis after discectomy and fusion with cortical allograft. *Neurosurgery* 2002;50:229-36; discussion 36-8.
16. Song KJ, Taghavi CE, Lee KB, et al. The efficacy of plate construct augmentation versus cage alone in anterior cervical fusion. *Spine (Phila Pa 1976)* 2009;34:2886-92.
17. Wilke HJ, Kettler A, Claes L. Primary stabilizing effect of interbody fusion devices for the cervical spine: an in vitro comparison between three different cage types and bone cement. *Eur Spine J* 2000;9:410-6.
18. Shimamoto N, Cunningham BW, Dmitriev AE, et al. Biomechanical evaluation of stand-alone interbody fusion cages in the cervical spine. *Spine (Phila Pa 1976)* 2001;26:E432-6.
19. Jackson RP, McManus AC. Radiographic analysis of sagittal plane alignment and balance in standing volunteers and patients with low back pain matched for age, sex, and size. A prospective controlled clinical study. *Spine (Phila Pa 1976)* 1994;19:1611-8.
20. Katsuura A, Hukuda S, Imanaka T, et al. Anterior cervical plate used in degenerative disease can maintain cervical lordosis. *J Spinal Disord* 1996;9:470-6.
21. Katsuura A, Hukuda S, Saruhashi Y, et al. Kyphotic malalignment after anterior cervical fusion is one of the factors promoting the degenerative process in adjacent intervertebral levels. *Eur Spine J* 2001;10:320-4.
22. Oda I, Cunningham BW, Buckley RA, et al. Does spinal kyphotic deformity influence the biomechanical characteristics of the adjacent motion segments? An in vivo animal model. *Spine (Phila Pa 1976)* 1999;24:2139-46.
23. Wang JC, McDonough PW, Endow KK, et al. Increased fusion rates with cervical plating for two-level anterior cervical discectomy and fusion. *Spine (Phila Pa 1976)* 2000;25:41-5.
24. Cho DY, Lee WY, Sheu PC. Treatment of multilevel cervical fusion with cages. *Surg Neurol* 2004;62:378-85, discussion 85-6.
25. Topuz K, Colak A, Kaya S, et al. Two-level contiguous cervical disc disease treated with peek cages packed with demineralized bone matrix: results of 3-year follow-up. *Eur Spine J* 2009;18:238-43.
26. Etebar S, Cahill DW. Risk factors for adjacent-segment failure following lumbar fixation with rigid instrumentation for degenerative instability. *J Neurosurg* 1999;90:163-9.
27. Kumar MN, Baklanov A, Chopin D. Correlation between sagittal plane changes and adjacent segment degeneration following lumbar spine fusion. *Eur Spine J* 2001;10:314-9.

ABSTRACT(IN KOREAN)

두마디 경추 유합술에서 환자의 예후와 방사선 사진 변화 비교: 단독 케이지 대 케이지와 전방 경추 플레이트

<지도교수 김긍년>

연세대학교 대학원 의학과

오 재 근

전방 경추 디스크 절제술 및 유합술은 방사통 또는 척수증이 있는 퇴행성 디스크 치료의 표준 수술 방법이다. 많은 논문이 단독 케이지를 이용하여 전방 경추 디스크 절제술 및 유합술을 시행하는 것이 좋은 결과를 보인다고 하였지만 케이지의 침하, 경추 후만, 가성 관절 등의 부작용을 보고 하는 논란도 있었다. 우리는 두마디 경추 유합술에서 단독 케이지 대 케이지와 전방 경추 플레이트를 사용한 환자들의 예후와 방사선 사진 변화를 비교함으로써 전방 경추 플에이트의 효과를 비교 분석 하였다.

두마디 전방 경추 유합술을 시행한 총 54명의 환자중 A

집단 (28명)은 단독 케이지를 사용한 경추 유합술을 시행하였고, B집단 (26명)은 케이지와 전방 경추 플레이트를 사용한 경추 유합술을 시행하였다. 유합률, 경추 전만, 디스크 높이와 케이지 침하율을 관찰하고 임상 결과는 로빈슨 기준을 사용하여 관찰 하였다.

골유합은 A 집단에서는 96.43% (27/28), B 집단에서는 96.15% (25/26) 으로 관찰되었다. 5도 이상의 수술 마디의 전만각 감소는 A 집단에서는 14.29% (4/28), B 집단에서는 7.69% (2/26) 으로 보였으나 통계적 의미는 없었다. 케이지 침하는 A 집단에서는 35.71% (10/28), B 집단에는 11.54% (3/26) 으로 통계적으로 의미있게 A 집단에서 많이 관찰 되었다. 임상 경과에 대한 두 집단 간의 차이는 없었다.

두 마디 전방 경추 유합술 시에 케이지와 전방 경추 플레이트를 사용한 집단에서 골유합이 빨리 형성되고, 케이지 침하율이 낮았다. 그러나 경추 전만각의 변화나 임상 결과는 두 집단 간 차이가 없었다.

핵심되는 말 : 전방 경추 유합술, 케이지, 전방 경추 플레이트, 침하, 유합