Open accurate reduction for irreducible mallet fracture through a novel pulp traction technique with primary tendon repair

Su Keon Lee

Department of Medicine

The Graduate School, Yonsei University

Open accurate reduction for irreducible mallet fracture through a novel pulp traction technique with primary tendon repair

Directed by Professor Ho-Jung Kang

The Master's Thesis submitted to the Department of Medicine, the Graduate School of Yonsei University in partial fulfillment of the requirements for the degree of Master of Medical Science

Su Keon Lee

December 2011

This certifies that the Master's Thesis of
Su Keon Lee is approved

Thesis supervisor: Ho-Jung Kang

Thesis Committee Member #1: Ick-Hwan Yang

Thesis Committee Member #1: Seong-Woong Kang

The Graduate School
Yonsei University

December 2011

Acknowledgements

I would first like to give my full gratitude to professor Ho-Jung Kang who has given me guidance from the beginning of this thesis. His wisdom and experience as an orthopedic surgeon, teacher and role model has greatly affected this thesis. I would also like to thank professor Ick-Hwan Yang and Seong-Woong Kang for their precious time in revising the paper. My sincere gratitude and respect goes out to all my professors in the orthopedic department of Yonsei University who have taught me to become the orthopedic surgeon I am today through their passion for the field and teaching. My parents who have always been my inspiration and driving force also deserve full thanks and love. My sister who has helped me in the revision of my English thesis has always been my advocate, thank you very much. Finally I would like to thank my future wife for always supporting and believing in me.

<Table of Contents>

List of figures

List of tables

<Abstract>

Open accurate reduction for irreducible mallet fracture through a novel pulp traction technique with primary tendon repair

Su Keon Lee

Department of Medicine
The Graduate School, Yonsei University

(Directed by Professor Ho-Jung Kang)

Sixteen patients with bony mallet fingers were treated by a new technique of open reduction through a T-shaped dorsal incision and oblique wire fixation via pulp traction with additional primary extensor repair. Surgical indications included fractures with intra-articular involvement over 1/3 of the articular surface, distal phalanx subluxation and displacement greater than 3mm, irreducible by extension block pinning. The cases were analyzed prospectively for a mean follow up period of 12 months. The results were evaluated using Crawford's criteria. Eleven cases were evaluated as excellent, 3 cases as good and 2 cases as fair. Complications included 3 cases with transient nail deformity, 2 cases with flexion limitation of 5 degrees and 10 degrees, and three cases with extension lag between 5 to 10 degrees. This novel method of accurate reduction achieves good clinical outcomes with comparatively less complications in mallet fractures irreducible to closed extension block reduction.

Key words: irreducible mallet fractures, pulp traction, primary tendon repair, T-shaped incision

Open accurate reduction for irreducible mallet fracture through a novel pulp traction technique with primary tendon repair

Su Keon Lee

Department of Medicine
The Graduate School, Yonsei University

(Directed by Professor Ho-Jung Kang)

I. INTRODUCTION

Bony mallet finger deformities are common in the field of hand surgery. For non complicated cases some authors recommend employment of conservative treatment usually by splinting or casting[1-5]. Under some conditions, however, surgical intervention is much more preferred as suggested by various reports[6-8] . These conditions include fragments involving more than 1/3 of the articular surface, subluxation of the distal interphalangeal (DIP) joint and fracture displacement greater than 3mm. Most of these cases can be treated by closed reduction by extensor block technique[9] . In certain cases however where closed reduction is not possible due to the small size of the fragment, fragment communition, rotation of the fragment or interposition of soft tissue or periosteum there is still much controversy in terms of the open reduction method the surgeon can rely on. Various open reduction techniques have been described, including fixation with a screw[10] , pull-out wire technique[11], tension band wiring[6], internal suture technique[12] and hook plating[13]. The various open techniques require various types of dorsal skin incisions of considerable length resulting in inevitable damage to the surrounding tissues such as the extensor tendon, the DIP joint, the periosteum or the nail bed[14].

We present an open accurate reduction technique for bony mallet fracture by pulp traction and DIP joint oblique wire fixation with additional primary extensor tendon repair using a T-shaped dorsal skin incision for cases irreducible to extension block pinning. This technique allows more accurate reduction of the fragment under direct visualization through traction tolerated by the pulp with additional stability obtained by repair of the extensor tendon. Clinical assessment was performed for this novel technique of anatomical reduction of irreducible bony mallet fractures.

II. MATERIALS AND METHODS

1. Patients and Inclusion criteria

Sixteen bony mallet finger deformities in 16 patients received surgery using pulp traction guided open reduction and oblique trans-articular wire fixation with additional primary extensor tendon repair technique from 2005 to 2010. Surgical candidates for this technique included patients with either 1) fragment involving more than one-third (1/3) of the articular surface 2) volar subluxation of the DIP joint 3) displacement of more than 3mm which could not be reduced by extension block pinning (Fig 1A).

The age distribution of the patient group was 17 years to 48 years with a mean age of 30.8 years. The male to female ratio was 14 to 2. The dominant hand was involved in 12 cases and non-dominant hand in 4 cases. The fingers affected were one thumb, two index fingers, three middle fingers, three ring fingers and seven little fingers. The mean interval between injury and surgery was an average 22 days (range, 6-60 days). Ten cases were operated 2 weeks after initial injury while six cases were operated within 2 weeks of injury. One case was neglected for 6 weeks without any treatment. There was one case with nonunion and one case that showed nonunion with extensor lag of 30 degrees after 6 weeks of splinting. The most

common cause of injury was from accidental trauma to the DIP joint with a total of nine cases. Eight cases were due to sporting activities all involving a ball (Table 1).

2. Radiographic evaluation

Pre-operative lateral X-rays of the finger were used to determine the percentage of articular surface involvement, presence of DIP joint volar subluxation and fracture fragment displacement. (Fig 1B) The fractures were classified by the Wehbe and Schneider[15] method (Table 2).

Postoperative serial X-rays were taken immediately after operation, at 2 weeks, 4 weeks, 2 months, 4 months and 6 months to determine evidence of union and articular congruity (Fig 1C, 1D and 1E). Range of motion of DIP joint, extensor lag and presence of nail deformity was recorded. Functional outcome was determined using the Crawford criteria[1] on degree of extension lag, DIP joint flexion, and pain (Table 3).

Figure 1 Mallet fracture neglected for 4 weeks treated with pulp traction technique

A. Preoperative x-ray of bony mallet finger with over 1/3 articular involvement and subluxation of DIP joint
B. Reduction with closed extension block technique was attempted but distal reduction of avulsed fragment was not possible
C. Immediate postoperative antero-posterior x-ray shows obliquely inserted horizontal 0.58mm 24 G spinal needles converging at fracture site
D. Immediate postoperative lateral x-ray shows good reduction with oblique transarticular wires
E. Follow up x-ray at 12 months shows full bone union and joint congruity

Table 1 Preoperative clinical information of mallet fractures

Patient	Sex	Age (years)	Source of injury	Finger	Time to Surgery (days)	Prior Treatment
1	M	39	Kickball	Left 2nd	27	Splinting
2	M	22	Slip injury	Right 5th	7	None
3	F	17	Hit tree	Left 5th	18	Nonunion and Extension lag 30° after 6 weeks of splinting
4	M	36	Soccer	Right 5th	50	Splinting
5	M	25	Hit wall	Right 5th	19	Splinting
6	M	17	Basketball	Right 3rd	22	Splinting
7	M	28	Hit by a TV screen	Right 5th	7	Splinting
8	M	38	Kickball	Left 3rd	8	Splinting
9	M	27	Stuck in a door	Right 2nd	19	Splinting
10	F	17	Dodgeball	Right 4th	11	Splinting
11	M	36	Stuck in a door	Right 4th	10	Splinting
12	M	31	Hit steering wheel	Left 3rd	20	Splinting
13	M	23	Basketball	Right 4th	45	None
14	M	44	Soccer	Right 5th	60	Nonunion after 6 weeks of splinting
15	M	48	Bicycle fall	Left 1st	6	None
16	M	46	Fist brawl	Right 5th	29	Splinting

Table 2 Wehbe and Schneider classification of mallet fractures

Fracture type	X-Ray Appearance
Type 1	No distal interphalangeal joint subluxation
Type 2	Distal interphalangeal joint subluxation
Type 3	Distal phalanx physis involved
Subtypes	
Type A	Fracture involves <1/3 of articular surface
Type B	Fracture involves 1/3-2/3 of articular surface
Type C	Fracture involves >2/3 of articular surface

Table 3 Crawford's criteria for evaluation of mallet injuries

Excellent	Full DIP joint extension
	Full flexion
	No pain
Good	0-10° extension lag
	Full flexion
	No pain
Fair	10-25° extension lag
	Any flexion loss
	No pain
Poor	>25° extension lag
	Persistent pain

3. SURGICAL TECHNIQUE

The procedure is performed under general anesthesia, with tourniquet control. A 1.1mm Kirschner wire is passed through the finger pulp in a transverse fashion and cut leaving an inch of wire on both sides (Fig 2A). This outer wire on both sides will later be used to apply traction during reduction.

A T-shaped skin incision is made on the dorsum over the DIP joint above the fracture site (Fig 2B). The dissection is deepened with caution to absolutely avoid any injuries to the extensor tendon insertion site on the fragment. Then fracture site maybe confirmed using a 24-gauge syringe needle tip with image intensifier guidance. The fracture line is exposed by carefully dissecting the soft tissue distal to the fracture site. During this process it is essential not to dissect the periosteum excessively which may cause the distal avulsed fragment to detach from the extensor apparatus to produce a loose body. After confirmation of the fragment, distally oriented manual traction force is applied on the wire passed through the pulp using gauze rolls to improve visual field compared to direct digital traction of the wire (Fig 2B). Soft

tissue, periosteum and hematoma removal between the fracture fragments becomes feasible via direct visualization through traction. Accurate reduction may be aided by volar compression of the fragment. The anatomical landmark for reduction must be set on the dorsal cortex of the distal phalanx (Fig 2C and 2D).

After accurate anatomical reduction laterally oriented oblique trans-articular 24G spinal needles (diameter 0.58mm) or thin Kirschner wires (diameter 0.7mm) are used for fixation of the fragment and the DIP joint at about a 10 degree hyper-extended state. The insertion point of the wires is located 3-4mm proximal to nail plate. The wire is laterally oriented parallel to the longitudinal plane of the DIP joint. Two wires are inserted in this manner on opposite sides so as to converge at the fracture site. An additional wire may be used for additional stability (Fig 2E). In cases where fragments cannot be directly fixed with lateral wires a wire may be used for direct fixation through the operative incision in a dorsal to volar direction. In patients with a congenitally thin dorsal lip or with small fractures involving only a small proportion of the articular surface direct fixation of the fragment is difficult. In these cases the oblique trans-articular wires are inserted just above the dorsal cortex of the fragment to indirectly reduce the fracture with further stability obtained by extensor suture described below. After fixation of the fragment primary repair of the ruptured extensor apparatus at the avulsed terminal tendon is done by suture with #6-0 undyed nylon. Initially 4 to 5 stitches are made and tie is done afterwards with inspection of the tension of the extensor tendon (Fig 2F).

The wires may be removed after 4 weeks however the DIP joint must be immobilized by volar DIP splinting for 2 more weeks. Active PIP joint motion is started immediately after surgery. Active range of motion exercise of DIP joint is started after the removal of the volar splint.

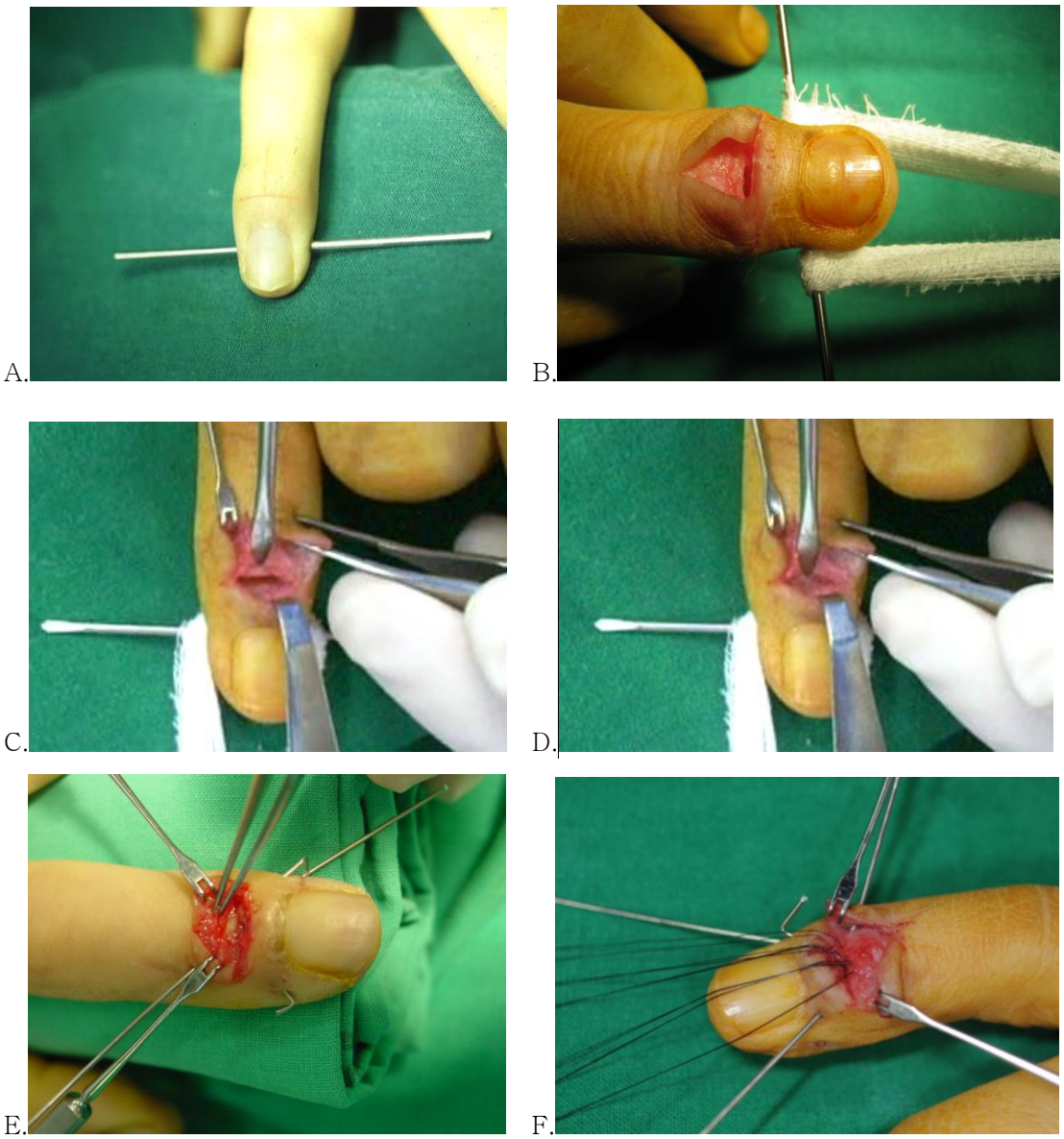

Figure 2 Intraoperative photographs

A. A 1.1mm kirschner wire is inserted through the pulp which will later be used for traction during reduction.
B. A dorsal T-shaped skin incision is made and pulp traction is being applied using gauze rolls.
C. Pulp traction and T-shaped dorsal incision provides a good visual field of the fracture site.
D. Anatomical reduction is done through direct visualization with reduction landmark set on dorsal cortex.
E. Fixation with oblique 0.58mm 24G spinal needle is made while directly confirming accurate reduction of dorsal cortex.
F. Extensor repair is done with undyed 6-0 nylon. Four to five stitches are first made and tie is done sequentially with inspection of tension of the terminal tendon.

III. RESULTS

The average percentage of articular surface involvement was 53.5% (range 36-70%). Eleven cases had volar subluxation of the distal phalanx while 5 cases showed no subluxation. According to Wehbe and Schneider's classification 10 cases were type IIB, 5 cases were type IB and 1 case was IIC. Mean follow-up period was 12 months (range, 9-16 months). The Kirschner wires were removed at a mean of 4.5 weeks (range, 4-6 weeks).

The Crawford's criteria include extension lag, DIP joint flexion, and pain; 11 cases rated as excellent, 3 cases as good while 2 cases rated as fair. The 2 cases with fair outcome both had residual mild flexion loss of 5 and 10 degrees, respectively. Three cases had residual extension lag between 5 to 10 degrees on final follow up (Table 4). No patient had both flexion loss and extension lag simultaneously. On final follow up all cases had maintained full union and no patient had residual subluxation of the DIP joint or evidence of posttraumatic osteoarthritis. Three cases reported of transient nail deformity which all improved on final follow-up. On final follow up all patients were satisfied with function and cosmetic outcome.

Table 4-Fracture type and clinical outcome

Patient	Articular surface involvement (%)	Subluxation	Classification Wehbe & Schneider	Complications
1	36	No	IB	None
2	54	No	IB	Ext. lag 5°
3	52	Yes	IIB	None
4	55	Yes	IIB	Flexion loss 5°
5	53	Yes	IIB	None
6	45	Yes	IIB	1. Nail Deformity 2. Ext. lag 10°
7	63	Yes	IIB	None
8	53	No	IB	Ext. lag 10°
9	55	Yes	IIB	None
10	62	Yes	IIB	None
11	49	Yes	IIB	None
12	57	Yes	IIB	Flexion loss 10°
13	42	No	IB	None
14	72	Yes	IIC	None
15	48	No	IB	Nail deformity
16	60	Yes	IIB	Nail deformity

IV. DISCUSSION

Bony mallet fingers develop from disruption of the dorsal terminal extensor apparatus at the level of distal interphalangeal joint, usually in the form of an avulsion fracture at the insertion of the extensor tendon at the distal phalanx resulting in extension lag of the distal interphalangeal joint.

Wehbe & Schneider[15] concluded that there were no specific advantages in surgical treatment compared to splinting however several of their patients developed posttraumatic arthritis and stiffness probably as a result of non-anatomic reduction. McCue and Abbott[7] suggested surgical treatment be mandatory if the fragment involves greater than 1/3 of the articular surface or if there is displacement or subluxation of the distal phalanx. Niejachev[8]

concluded from his study that surgical intervention should be undertaken for all fractures with subluxation or displacement of more than 3mm. Most of these cases can be treated by closed reduction with percutaneous pinning using the extension block technique. However although numerous open techniques have been introduced for treatment of bony mallet fracture there is no common consent on how difficult cases which can not be reduced by extension block technique should be treated. Open techniques reported to date have utilized screws[10], tension band wiring[6], sutures[12] and Kirschner wires alone, or in combination. Although these techniques have yielded good overall results, 46% of patients with tension band fixation reported residual pain and 28% functional limitation at follow-up[6]. The screw fixation technique also reported good outcomes but reported screw prominence in 30% of patients[10]. The open technique using suture-only reported poor patient satisfaction in 30% of patients and residual joint subluxation in 20%[12]. Our technique produced excellent or good outcome in 14/16 patients. The patients who had fair results were both due to mild flexion loss on final follow-up. Both these cases had articular involvement greater than 1/2 however there was no definite correlation with delay period to surgery. Three patients had residual extension lag which however seemed to have no relation with amount of articular surface involvement or delay period to surgery. No patient had both flexion loss and extension lag at the same time. This could be explained by the contrasting etiology of these two complications. Further studies with a larger group number to elicit the factors involved in loss of flexion and residual extensor lag may be useful to decrease complications and for patient selection for future reference.

The surgical technique presented in this study is made possible by the unique characteristic of the pulp. Numerous fibrous septa of the pulp allows for enough traction force needed for good visualization for anatomical reduction of the bony mallet finger[16-18]. The technique introduced in this study has the following advantages.

The T-shaped incision allows later extension of the dissection through either horizontal end of the T-shape if further visualization of the fracture is needed due to severe displacement or comminution. The balanced forces of the terminal extensor tendon and the long flexor tendon dynamically stabilize The DIP joint while the proper and accessory collateral ligaments and the volar plate provide static stability[19]. Therefore minimal damage to these vital structures during dissection and fixation is crucial in preserving the function and preventing extensor lag of the DIP joint. Transient nail deformity was seen in 3 cases which improved on final follow up. The nail deformity was due to direct injury to the nail bed during initial injury in 2 cases and due to wire irritation during fixation in 1 case.

Pulp traction allows direct visualization and adequate operative space for easier anatomical reduction. Anatomical reduction of the fracture fragment is made possible by manual traction using the wire through the pulp in cases with a large fracture fragment or with onset over 2 weeks. In acute cases with an onset of less than 2 weeks, this pulp traction may not be compulsory. This traction provides the surgeon which a greater visual field and facilitates in reducing large fragments or fragments with serve rotation.

Fixation using thin oblique 0.7mm K-wire or 0.58mm 24 gauge spinal needle has the benefits of direct fracture fixation with less morbidity during retargeting of the fragment during fixation attempts. For fixation of the fragment our surgical team recommends using a 24 gauge spinal needle with a diameter of 0.58mm or a thin Kirschner wire with a diameter of 0.7mm. These thin wires not only allows more precise fixation of small fragments but also produces less morbidity at the insertion site. This is an advantage in cases of bony mallet fractures where fixation on first targeting is difficult due to the small size of the fragment. The obliquely oriented lateral wires used are comparable to most techniques which employ longitudinal wire fixation of the DIP joint. This new entry point is technically less demanding in fixating the DIP

joint due to the proximity to the fracture site and produces less nail bed complications.

Reinforced primary tendon repair promotes further stabilization of the extensor apparatus. For comminuted mallet fractures fixation of all the fragments is impossible. In theses cases the main fragment is fixed using the oblique wire fixation technique mentioned above and the smaller fragments are stabilized by suture of the extensor tendons. None of our cases showed loss of reduction during the follow up period. We believe this can be attributed to anatomic reduction of the fracture with further soft tissue stability obtained by primary tendon repair.

Analysis of the time interval to surgery of the cases treated with our technique shows that 10 cases were neglected or treated with splinting without satisfactory reduction for over 2 weeks. Six of the cases were operated upon within 2 weeks of injury. Initial reduction with extension block technique was unsuccessful in all 16 cases. In cases neglected or treated without satisfactory reduction for over 2 weeks the reason for unsuccessful closed reduction were due mainly to scar contracture of the avulsed tendon on open inspection. The 6 cases operated within 2 weeks of injury had no definite contracture but showed comminuted or rotated fracture fragments or soft tissue interposition upon open inspection.

REFERENCES

1. Crawford GP. The molded polyethylene splint for mallet finger deformities. J Hand Surg Am. 1984;9A:231-7.
2. Clement R, Wray RC. Operative and nonoperative treatment of mallet finger. Ann Plast Surg. 1986;16:136-41.
3. Maitra A, Dorani B. The conservative treatment of mallet finger with a simple splint: A case report. Arch Emerg Med. 1993;10:244-8.
4. Richards DS, Kumar G, Booth S et al. A model for the conservative management of mallet finger. J Hand Surg Br. 2004;29:61-3.
5. Wilson SW, Khoo CT. The Mexican hat splint. Ann R Coll Surg Engl. 2008;90:72.
6. Damron TA, Engber WD. Surgical treatment of mallet finger fractures by tension band technique. Clin Orthop and Relat Res. 1994;300:133-40.
7. McCue FC, Abbott JL. The treatment of mallet finger and boutonniere deformities. Va Med Mon 1967;94:623.
8. Niechajev IA. Conservative and operative treatment of chronic mallet finger. Plastic Reconstr Surg. 1985;76:580-5.
9. Ishiguro T, Itoh Y, Yabe Y et al. Extension block with Kirschner wire for fracture dislocation of the distal interphalangeal joint. Tech Hand Up Extrem Surg. 1997;1(2):95–102.
10. Kronlage SC, Faust D. Open reduction and screw fixation of mallet fractures. J Hand Surg Br. 2004; 29:135–8.
11. Zhang X, Meng H, Shao X et al. Pull-out wire fixation for acute mallet finger fractures with k-wire stabilization of the distal interphalangeal joint. J Hand Surg Am. 2010;35(11):1864-9.

12. Bauze A, Bain G. Internal suture for mallet fracture. J Hand Surg Br. 1999;24:688.
13. Teoh LC, Lee JY. Mallet fractures: A novel approach to internal fixation using a hook plate. J Hand Surg Eur. 2007;32:24-30.
14. Kang HJ, Shin SJ, Kang ES. Complications of operative treatment for mallet fractures of the distal phalanx. J Hand Surg Br. 2001;26:28–31.
15. Wehbe´ MA, Schneider LH. Mallet fractures. J Bone Joint Surg Am. 1984;66:658–69.
16. Schweitzer TP, Rayan GM. The terminal tendon of the digital extensor mechanism: Part I. Anatomic study. J Hand Surg Am. 2004;29:898-902.
17. Schweitzer TP, Rayan GM. The terminal tendon of the digital extensor mechanism: Part II. Kinematic study. J Hand Surg Am. 2004;29:903–8.
18. Hussain SN, Dietz JF, Kalainov DM, Latuenschlager EP. A biomechanical study of distal interphalangeal joint subluxation after mallet fracture injury. J Hand Surg Am. 2008;33:26-30.
19. Bucholz RW, Heckman JD, Court-Brown CM, *Rockwood and Green's Fractures in Adults*, 6th Edn. Lippincott, Williams and Wilkins, 2006:787.

Abstract (In Korean)

비관혈적 정복이 불가능한 골성 추지의 수지 말단부 펄프 견인과 일차적 신전건 봉합술을 이용한 관혈적 정복술

<지도교수 강호정>

연세대학교 대학원 의학과

이수건

2005년부터 2001년까지 16명의 골성 추지 환자가 T 모양의 절개 및 펄프 견인을 이용한 관혈적 정복, 강선을 이용한 사선 고정술 및 일차적 신전건 봉합술을 이용한 새로운 수술적 요법으로 치료받았다. 수술의 적응증은 골절편이 관절면의 1/3이상 차지하거나, 원위 지골 아탈구가 있거나 3㎜이상의 골편전위를 보이는 사례 중 extension block pinning으로 정복 되지 않은 사례를 대상으로 하였다. 16례에 대한 결과는 전향적으로 평균 12개월간 추적하였다. 임상적 결과 판정은 신전지체, 원위지절의 범위 제한 여부 및 통증을 포함하는 Crawford's criteria를 사용하여 판정하였다. 16례중 11례에서 excellent, 3례에서 good, 2례에서 fair한 결과를 얻었다. 합병증으로 일시적 조갑 변형 3례, 각각 5도 및 10도 의 굴곡 제한을 보인 2례와 5도에서 10도 사이의 신전지체를 보인 3례가 있었다. 골성 추지에 일반적으로 사용되는 비관혈적 extension block pinning으로 정복이 안되는 사례의 경우 본 논문에서 제시한 새로운 수술적 방법으로 치료 한 결과 만족스러운 임상적 결과 및 상대적으로 낮은 합병증을 보였다.

핵심되는 말: 정복 불가능한 골성 추지, 펄프 견인, 일차적 신전건 봉합술, T-모양 절개