The correlations between TMJ symptoms and MRI finding in German patients

Min Kyoung Kye

The Graduate School

Yonsei University

Department of Orthodontics

The correlations between TMJ symptoms and MRI finding in German patients

A Masters Thesis
Submitted to the Department of Orthodontics
and the Graduate School of Yonsei University
in partial fulfillment of the
requirements for the degree of
Master of Orthodontics

Min Kyoung Kye

December 2011

This certifies that the masters thesis of Min Kyoung Kye is approved.

Thesis Supervisor: Kee- Joon Lee

Young-Chel Park

Seong-Taek Kim

The Graduate School

Yonsei University

December 2011

Table of Contents

List of Figures and Legends

ABSTRACT

The correlation between TMJ symptom and MRI finding in German patients

The purpose of this study was to investigate a possible association between magnetic resonance imaging (MRI) findings on the condyle-disc pathology and clinical symptoms in German patients. Bilateral temporomandibular joint magnetic resonance imaging (MRI) scans were obtained from all subjects of 240 German patients and clinical examinations were studied retrospectively. The hypothesis of this study was that clinical symptoms are related to some MRI findings on the condyle-disc pathology. Patients displayed various degrees of joint clicking, crepitus and joint pain. MRI evaluations of temporomandibular joints were studied by seven categories of condyle degeneration, disc position, disc degeneration, osteophyte, sclerosis, synovitis and hypermobility. The results show some correlations between clinical symptoms and MRI findings on the condyle-disc. The results of correlations test showed crepitus, joint clicking had a significant correlation with condyle-disc degeneration. However, pain was not correlated with any MRI findings significantly except hypermobility. The results of this study imply that condyle-disc deformities could be advanced without pain, and joint clicking and crepitus could be clinical symptoms of condyle-disc degeneration.

Key words : Temporomandibular, TMD, condyle, disc, MRI

The correlations between TMJ symptoms and MRI finding in German patients

Min Kyoung Kye, D.D.S
Department of Orthodontics
Graduate School of Yonsei University
(Directed by Prof.Kee-Joon Lee, D.D.S.,M.S.D.,Ph.D.)

I. INTRODUCTION

Temporomandibular disorder (TMD) is very common not only in dental patients but also in general population. The overall prevalence of TMD was 20-68 % (Liu, and Tsai 1996). One third of the population had at least one clinical symptom of TMD. The prevalence of TMD in orthodontic patients was not lower than normal population (Okeson 2008).

Plain radiography, panoramic tomography, magnetic resonance imaging (MRI), computed tomography (CT), and cone-beam CT (CBCT) are widely used for diagnostic imaging of the TMD. Of these, MRI is accepted as the most reliable modality on which to base TMD diagnosis and therapeutic decisions (Wiese et al. 2008, Adame et al. 1998,Limchaichana, Petersson, and Rohlin 2006).

MRI is generally inferior to CBCT and CT for evaluating small regions of hard tissue. CBCT and CT produce high-resolution bone images, and CBCT is

particularly suitable for evaluation of small bony structures, but MRI is a still effective diagnostic method because it makes multi-planar images, 3D-visualizations, differentiations of hard tissue and soft tissue and finds minor inflammations. Moreover MRI is capable of providing information on the disc position and its morphology through soft-tissue resolution without exposing the patient to radiation (Dergin et al. 2011, Campos et al. 2008). Disadvantages of MRI are longer examination time than other radiographic methods. Contraindications of MRI are cardiac pacemaker, all motor objects, metal vessel clips, claustrophobia, diazepam. Multidisciplinary indications of MRI are Psoriasis-Arthritis, Juvenile arthritis, rheumatoid arthritis, Bechet's disease and tumor suspiction (Haley et al. 2001).

Contradictory relations between the symptoms and the radiologic pathology have been reported (Kopp and Rockler 1979, Hansson and Petersson 1983, Helenius et al. 2005, Kurita et al. 2004). While a prevalence of internal derangement as high as 33% in asymptomatic subjects was claimed (Katzberg et al. 1996), no relation between the patients' discomfort or pain and the degree of TMD was also shown (Dworkin and Massoth 1994).

The objectives of this research are to investigate the prevalence of clinical symptoms and condyle-disc displacement and degeneration, to determine a possible correlation between various TMD pathology found in MRI and clinical symptoms and to provide clinical guidelines for assessment of TMD.

II.Materials and Methods

A. Participants collection

The data of Two hundred and forty German TMD patients (109 males and 131 females) were collected for this study retrospectively. Two hundred and forty German TMD patients who visited the Frankfurt University Dental Clinic were retrospectively selected from 1997 to 2004. All of the patients exhibited at least one of the TMD symptoms; clincking, crepitus and pain. All patients had clinical exams regarding joint clicking, crepitus and joint pain and received MRI exams for temporomandibular joint (TMJ) area.

B. MRI scanning

Continuous 3-mm para-sagittal, para-coronal and para-transverse slices of the temporomandibular joint (TMJ) were taken with a 3.0-T (Tesla) superconductive MR scanner (Magnetom Espree, Siemens)(Fig. 1). MRI assessment of each subject was performed and studied for condyle degeneration, disc position, disc degeneration, osteophyte, sclerosis, synovitis and hypermobility (Fig. 2,3)(Table 1)(American Academy of Craniomandibular Disorders, and McNeill 1990, Okeson 2008).

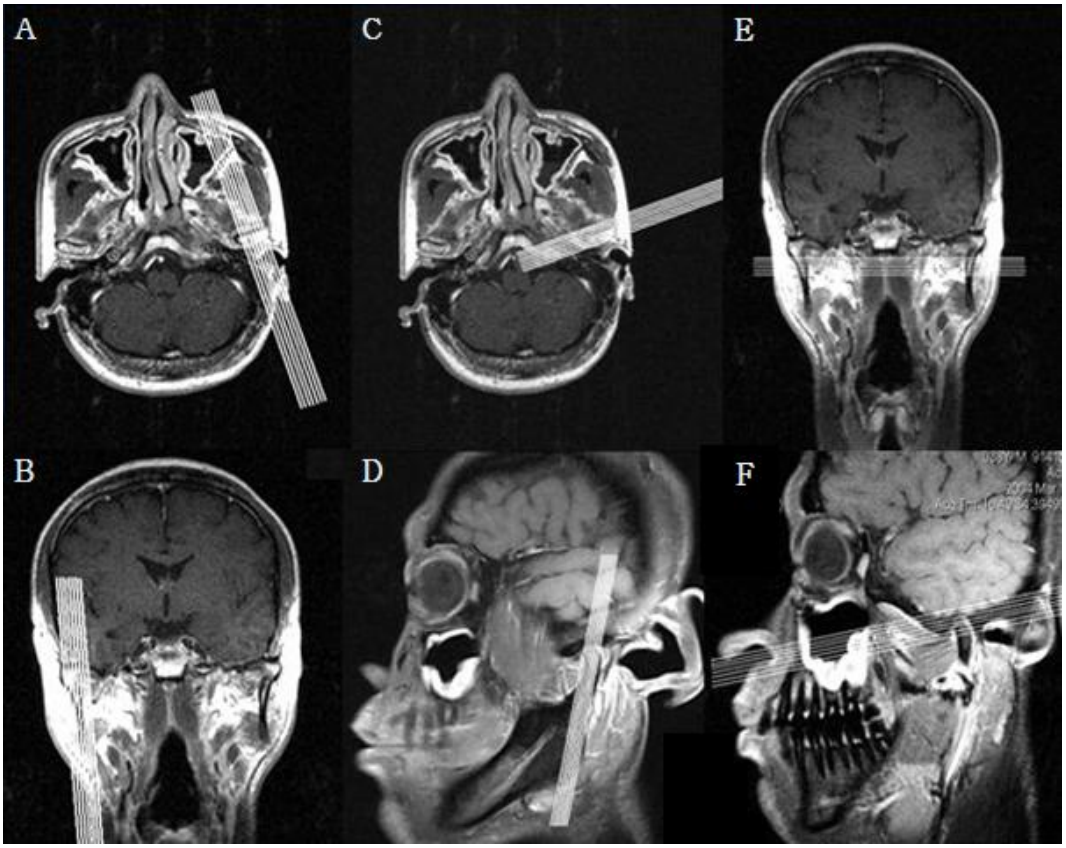

Figure 1 MRI sections for TMD. All participants had taken several sections of MRI for TMD evaluation. (A, B: Para-sagittal section, C, D: Para-coronal section, E, F: Para-transverse section)

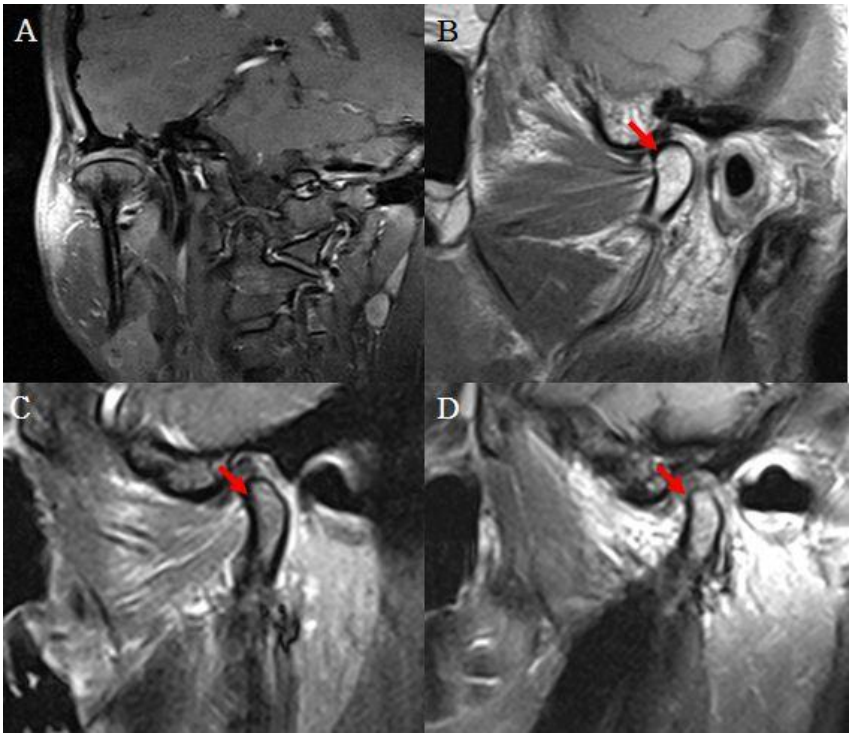

Figure 2 MRI findings of condyle degeneration. MRI findings show degree of condylar degeneration. (A: Normal relationship between condyle and disc., B: Degeneration of condyle, beginning, C: Degeneration of condyle, intermediate state, D: Significant degeneration of condyle and disc)

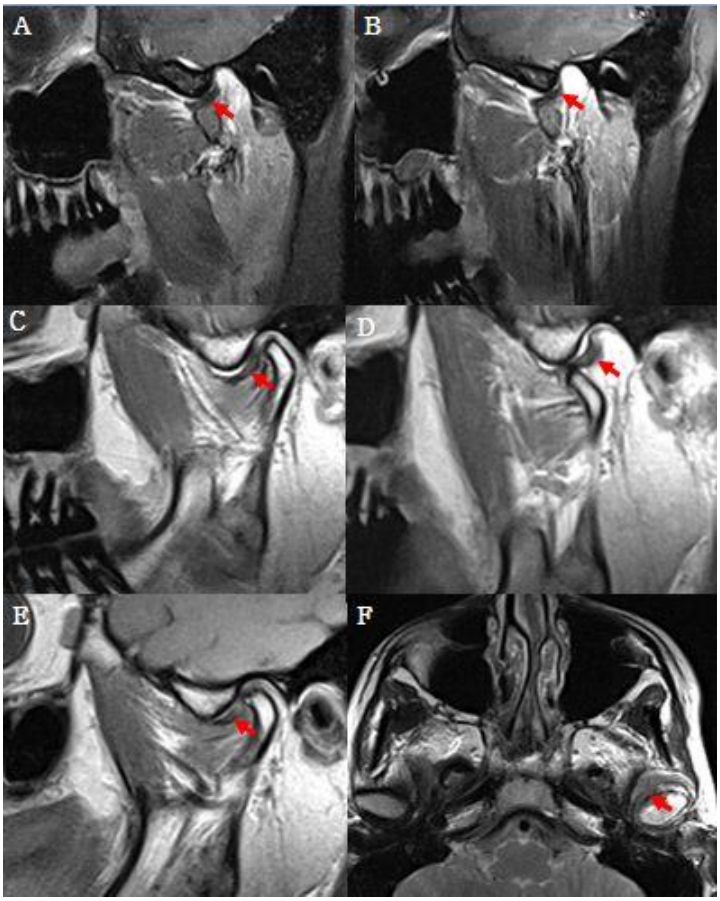

Figure 3 MRI findings of disc degeneration. MRI findings show degree of disc degeneration and synovitis. (A: Normal elasticity of disc, B: Degeneration of disc, loss of elasticity, C: Total anterior displacement, acute phase, D: Total anterior disc displacement with reduction acute phase, E: Total anterior disc displacement, chronic phase, F: Synovitis in juvenile TMJ)

Table 1 Definition of temporomandibular joint disorders.

Disorder	Description
Disc displacement with reduction	Alteration, usually abrupt, or the disc−condyle structural relationship during mandibular translation, usually characterized by reciprocal clicking
Disc displacement without reduction	Altered disc−condyle structural relationship that is maintained during translation; can be acute or chronic
Synovitis	An inflammation in the synovial lining of the TMJ
Hypermobility	Excessive disc or condyle translation usually well beyond the eminence
Osteophyte	Small bone projection on condyle, condyle is flattened
Sclerosis	An increase in the density of the bone

C.MRI criteria

The condyle degeneration was divided to 5 degrees as condyle degeneration none, little condyle degeneration, moderate condyle degeneration, heavy condyle degeneration and beakpeak when reading the MRI. In these 5 degrees, as statistically analyzed moderate, heavy and beakpeak degrees were studied as condyle degeneration state and none and little degrees as no condyle degeneration state.

The disc degeneration was initially divided to 4 degrees as no disc degeneration, flat disc degeneration, perfusion and adhesion when reading the MRIs. In these 4 degrees flat, perfusion and adhesion degrees were studied as disc degeneration state.

The condyle position was divided to 5 categories as norm, dorsal, ventral, medial and lateral. For statistical analysis, they were re-categorized as norm, unilateral and bilateral condyle dislocation.

The disc position was divided as norm, dorsal, ventral, medial, lateral, none luxation, partial luxation, total luxation, none reposition, partial reposition and total reposition by 11. And these categories were re-divided to 5 divisions as norm position, unilateral reposition with reduction, bilateral reposition with reduction, unilateral reposition without reduction and bilateral reposition without reduction.

D.STATISTICS

Correlations between clinical symptoms and MRI findings were analyzed with Pearson Chi Square Test by SPSS 10.0. Correlation coefficients were calculated between clinically symptoms and MRI findings. When p−value is under 0.05, the correlation is statistically significant.

III. RESULTS

A. DEMOGRAPHIC DATA

Age distribution was from 4 years old to 70 years old, 53 persons were under 20 years old and 46 persons were 20's. 8 persons were over 60 years old (Fig. 4).

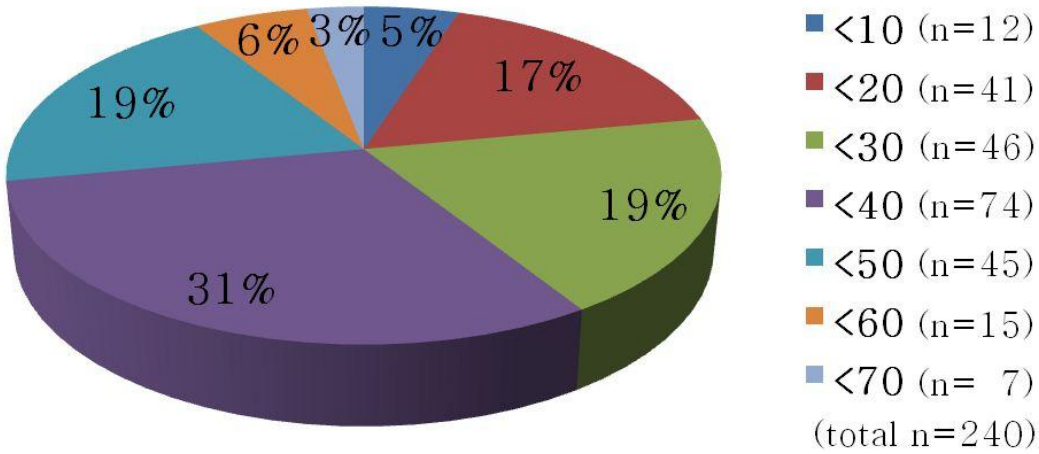

Figure 4 Demographic finding of participants. Age distribution varies from 4-year old to 70-year old.

B. PREVALENCE OF CLINICAL SYMPTOMS AND MRI FINDINGS

In 240 patients, 117 patients showed no clicking, 67 patients had unilateral clicking and 56 patients had bilateral clicking. Of the 240 patients, 219 had no crepitus, 14 had unilateral crepitus and 7 had bilateral crepitus. 84 had unilateral or bilateral pain (Fig. 5).

Condyle degeneration, disc position, disc degeneration, osteophyte, sclerosis and synovitis have normal, unilateral and bilateral findings (Fig. 6).

18 percents of the patients showed normal disc position, 67.5 percents of the patients showed disc reposition with reduction state and 14.5 percents of the patients showed disc reposition without reduction state (Fig. 7).

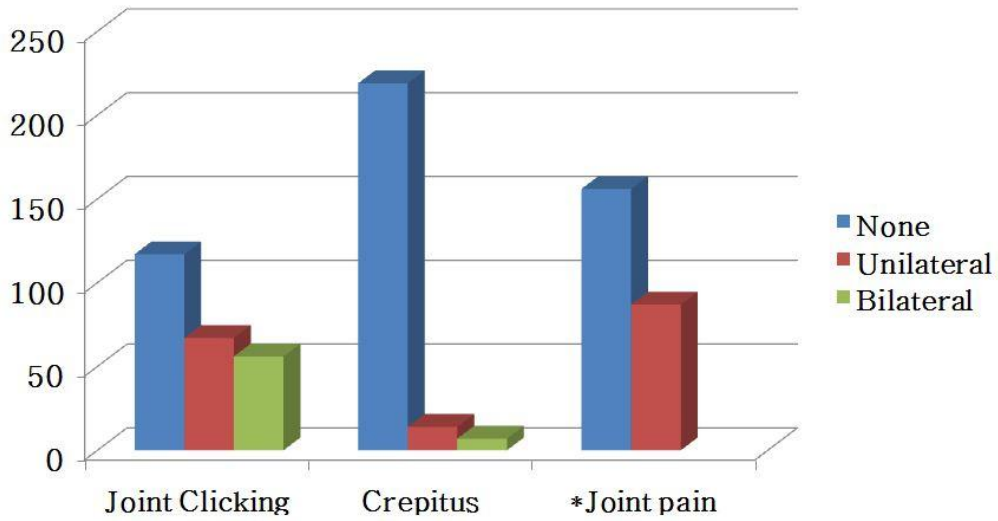

Figure 5 Prevalence of clinical symptoms. Joint clicking, crepitus and joint pain were examined in all patients. (*: Joint pain was not divided into unilateral or bilateral)

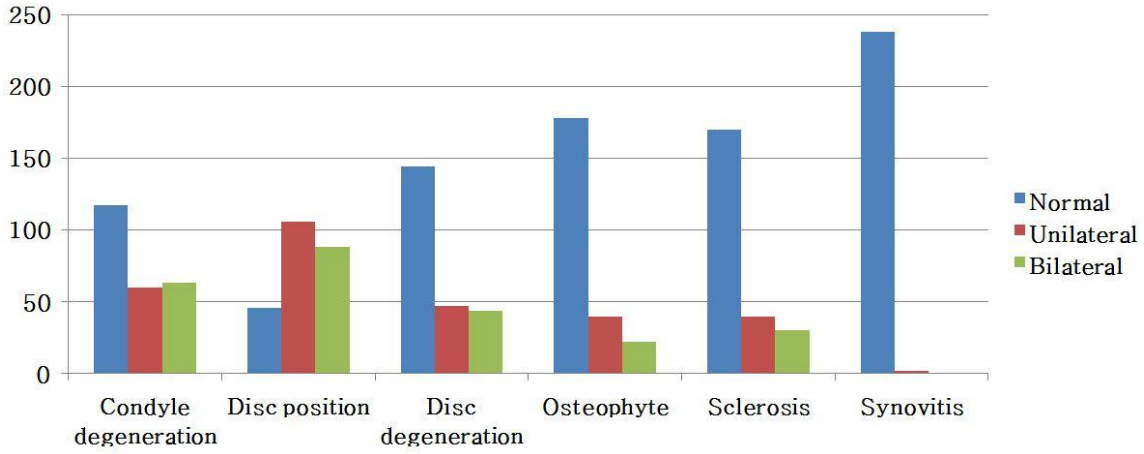

Figure 6 Prevalence of MRI findings in TMD.

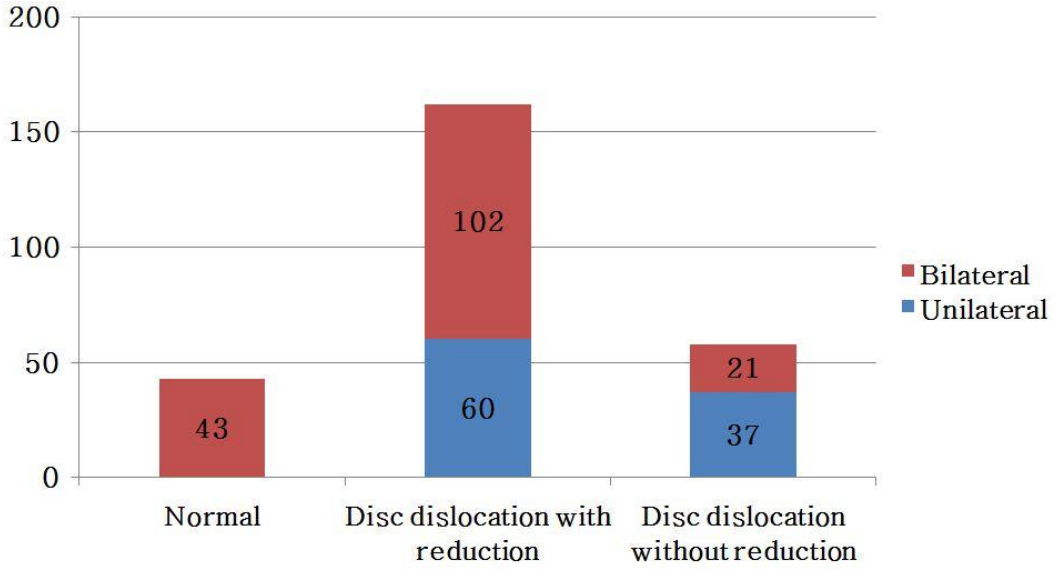

Figure 7 Prevalence of disc dislocation with reduction and without reduction in MRI.

C.CORRELATION BETWEEN CLINICAL SYMPTOMS AND MRI FINDING

Bilateral joint clicking had significant correlations with unilateral disc degeneration. Unilateral joint clicking showed significant correlations with unilateral sclerosis. Bilateral crepitus had negative correlations with normal condyle position and none condyle degeneration. Bilateral crepitus showed strong correlations with bilateral osteophyte. Pain was correlated with hypermobility, dorsal disc position and moderate disc degeneration (Table 2).

Table 2 Correlation between clinical symptoms and condyle position. There is negative correlation (R = −0.136) between normal condyle position and bilateral crepitus.

		Condyle Position					
		Norm		Unilateral dislocation		Bilateral dislocation	
		R	*p* value	R	*p* value	R	*p* value
Joint Clicking	none	0.031	0.631	−0.076	0.24	0.041	0.528
	unilateral	0.032	0.619	0.053	0.41	−0.075	0.248
	bilateral	−0.071	0.276	0.033	0.61	0.031	0.635
Crepitus	none	0.112	0.082	−0.026	0.688	−0.068	0.291
	unilateral	−0.019	0.77	0.006	0.923	0.017	0.792
	bilateral	**−0.136***	**0.035**	0.071	0.274	0.086	0.186
Pain		−0.021	0.746	−0.025	0.701	0.05	0.437

R: Pearson correlation coefficients, *p<0.05

Table 3 Correlation between clinical symptoms and condyle degeneration. There is negative correlation (R=−0.136) between none condyle degeneration and bilateral crepitus.

		Condyle degeneration					
		None		Unilateral		Bilateral	
		R	*p* value	R	*p* value	R	*p* value
Joint Clicking	none	0.016	0.804	−0.009	0.887	0.01	0.872
	unilateral	0.038	0.555	0.021	0.75	−0.076	0.242
	bilateral	−0.059	0.361	−0.011	0.866	0.068	0.297
Crepitus	none	0.039	0.547	−0.022	0.729	−0.068	0.291
	unilateral	0.075	0.245	−0.023	0.725	0.017	0.792
	bilateral	**−0.143***	**0.026**	−0.018	0.78	0.086	0.186
Pain		−0.093	0.153	0.033	0.61	0.05	0.437

R: Pearson correlation coefficients, *p<0.05

Table 4 Correlation between clinical symptoms and disc position or disc dislocation. There is no significant correlation between disc position and joint clicking, crepitus or pain.

		Disc position									
		Norm		Unilateral dislocation				Bilateral dislocation			
				with reduction		without reduction		with reduction		without reduction	
		R	*p* value	R	*p* value	R	*p* value	R	*p* value	R	p value
Joint Clicking	none	−0.017	0.793	−0.077	0.235	−0.113	0.081	0.079	0.221	−0.034	0.601
	unilateral	0.024	0.71	0.027	0.679	0.043	0.508	−0.028	0.669	−0.028	0.662
	bilateral	−0.005	0.933	0.062	0.337	0.087	0.179	−0.064	0.324	0.07	0.282
Crepitus	none	0.029	0.651	−0.026	0.694	−0.072	0.267	0.057	0.376	0.078	0.458
	unilateral	0.023	0.725	0.062	0.342	0.091	0.161	−0.07	0.279	−0.014	0.827
	bilateral	−0.068	0.293	−0.084	0.194	0.019	0.775	0.052	0.426	0.058	0.37
Pain		−0.001	0.986	0	1	0.074	0.255	0.005	0.935	−0.011	0.868

R: Pearson correlation coefficients, *p<0.05

Table 5 Correlation between clinical symptoms and disc degeneration. There is negative correlation (R = −0.171) between unilateral disc degeneration and none joint clicking. There is positive correlation (R=0.162) between unilateral disc degeneration and bilateral joint clicking.

		Disc degeneration					
		Norm		Unilateral		Bilateral	
		R	*p* value	R	*p* value	R	*p* value
Joint Clicking	none	0.143*	0.027	**−0.171****	0.008	0.006	0.927
	unilateral	−0.099	0.128	0.037	0.567	0.067	0.298
	bilateral	−0.064	0.324	**0.162***	0.014	−0.078	0.228
Crepitus	none	0.048	0.458	0.044	0.495	−0.107	0.097
	unilateral	−0.087	0.179	0.009	0.891	0.101	0.118
	bilateral	0.06	0.358	−0.073	0.26	0.002	0.981
Pain		−0.061	0.35	0.023	0.686	0.056	0.387

R: Pearson correlation coefficients, *p<0.05; **p<0.01

Table 6 Correlation between clinical symptoms and osteophyte. There is positive correlation (R=0.154) between unilateral osteophyte and unilateral joint clicking. There is strong correlation (R=0.257) between bilateral osteophyte and bilateral crepitus.

		Osteophyte					
		None		Unilateral		Bilateral	
		R	*p* value	R	*p* value	R	*p* value
Joint Clicking	none	0.086	0.185	−0.110	0.090	0.011	0.87
	unilateral	−0.085	0.191	**0.154***	**0.017**	−0.069	0.287
	bilateral	−0.012	0.859	−0.034	0.605	0.06	0.353
Crepitus	none	−0.011	0.86	0.096	0.136	−0.106	0.101
	unilateral	0.064	0.326	−0.061	0.343	−0.017	0.788
	bilateral	−0.116	0.073	−0.064	0.322	**0.257****	**0.000**
Pain		−0.033	0.610	0.008	0.898	0.039	0.544

R: Pearson correlation coefficients, *p<0.05; **p<0.01

Table 7 Correlation between clinical symptoms and sclerosis. There is positive correlation(R=0.154) between unilateral sclerosis and unilateral joint clicking.

		Sclerosis					
		None		Unilateral		Bilateral	
		R	*p* value	R	*p* value	R	*p* value
Joint Clicking	none	0.086	0.185	−0.11	0.09	0.011	0.87
	unilateral	−0.085	0.191	**0.154***	**0.017**	−0.069	0.287
	bilateral	−0.012	0.859	−0.034	0.605	0.06	0.353
Crepitus	none	0.044	0.502	−0.027	0.674	−0.025	0.697
	unilateral	−0.008	0.898	−0.011	0.871	0.02	0.754
	bilateral	−0.041	0.513	0.017	0.797	0.038	0.559
Pain		−0.064	0.324	0.017	0.796	0.087	0.179

R: Pearson correlation coefficients, *p<0.05

Table 8 Correlation between clinical symptoms and synovitis. There is positive correlation(R= 0.147) between unilateral synovitis and unilateral joint clicking.

		Synovitis					
		None		Unilateral		Bilateral	
		R	*p* value	R	*p* value	R	*p* value
Joint Clicking	none	0.109	0.093	−0.089	0.171	−0.063	0.334
	unilateral	−0.097	0.133	**0.147***	**0.022**	−0.04	0.535
	bilateral	−0.025	0.696	−0.051	0.43	0.116	0.073
Crepitus	none	−3035	0.591	0.028	0.662	0.02	0.758
	unilateral	0.028	0.666	−0.023	0.725	−0.016	0.804
	bilateral	0.016	0.8	−0.013	0.837	−0.009	0.884
Pain		0.004	0.952	0.029	0.657	−0.047	0.464

R: Pearson correlation coefficients, *p<0.05

Table 9 Correlation between clinical symptoms and hypermobility. There is positive correlation(R= 0.135) between hypermobility and pain.

		Hypermobility	
		R	*p* value
Joint Clicking	none	0.026	0.69
	unilateral	0.031	0.631
	bilateral	−0.063	0.33
Crepitus	none	0.019	0.769
	unilateral	0.009	0.887
	bilateral	−0.038	0.561
Pain	Pain	**0.135***	**0.036**

R: Pearson correlation coefficients, *p<0.05

IV. DISCUSSION

MRI defines hard and soft tissue and is usually applied to examine the soft tissue pathology of the TMJ. Studies which compared MRI findings with surgical and autopsy specimens reported an accuracy of about 90-95% for detecting disc position abnormalities when both coronal and sagittal images were evalulated (Tasaki, and Westesson 1993).

The purpose of this study was to investigate whether clinical symptoms such as clicking, crepitus and pain have correlations with MRI findings of condyle-disc pathology or not. The prevalence of clinical symptoms and condyle-disc displacement and degeneration was investigated and the association between MRI findings on the condyle-disc pathology and clinical symptoms was studied.

In TMD patients displacement of the articular disc is occurred most frequently and the disc displacement is the most common cause of TMJ clicking and crepitus (Park et al. 2011). TMJ pain is another major clinical symptom of TMD (Limchaichana et al. 2007).

The results of correlation test showed that the crepitus had a significant correlation with disc degeneration, condyle degeneration and also correlation with osteophyte. Joint clicking also had significant correlations with disc degeneration and sclerosis. Joint clicking and crepitus showed especially significant relations with specific MRI findings such as condyle degeneration, disc degeneration or sclerosis. However, pain was not correlated with any MRI findings significantly except hypermobility.

To diagnose TMD, clinicians perform clinical examinations and conventional imagings. Clinical examinations consist of range of mouth opening, pain, joint clicking, crepitus and muscle tenderness on palpation. When diagnosing TMD with clinical examination and conventional X-ray imaging, many clinicians make different decisions about the treatment plans for the TMD patients (Park et al. 2011). The question in this study is MRI can help the diagnosis of TMD or not and diagnosis without MRI is reliable to diagnose disc displacement.

In the results, joint clicking and crepitus were significant correlated to condyle-disc degeneration and no relations were seen between clinical symptoms and disc displacement. However this does not mean joint clicking and crepitus have no relation with MRI finding of disc displacement, disc position

Oseteoarthritis/osteoarthrosis is considered to be present if erosion, concavity, flattening, osteophyte formation, osteosclerosis, subchondral cyst, and/or deformity were found at the articular surface of the condyle (Kurita et al. 2004, Lin et al. 2007). In the previous study, a higher prevalence of joint pain was observed in joints with osteoarthritis/arthrosis (Kurita et al. 2004). However, several authors have reported a high prevalence of signs of osteoarthritis without radiographic findings. In many previous studies condyle and disc degeneration could progress without pain or other clinical symptoms (Wiberg, and Wanman 1998, Helenius et al. 2006).

In this study joint clicking and crepitus were correlated with MRI findings on condyle-disc pathology. And this study pain was not correlated with MRI findings on condyle-disc pathology significantly without hypermobility. In previous studies with conventional radiography or CT, the correlations between

joint clicking and crepitus had correlations with radiographic abnormalities (Wiese et al. 2008). However, others have stated that this relationship is not present in all cases (Vasconcelos Filho et al. 2007). In this study joint clicking and crepitus were significantly correlated with condyle disc degeneration and pain was not significantly correlated. The results of this study imply that condyle-disc deformities could be advanced without pain, and joint clicking and crepitus could be the clinical symptoms of condyle-disc degeneration.

Pain as a clinical symptom of the TMD has diverse origins such as myofascial pain, TMJ pain and referred pain. Therefore in this study data about pain was not sufficient because the origin of pain was not clarified and the scale of the severity of pain was not specified. Range of mouth opening is the one of the clinical sign of TMD. Mouth opening limitation is a clinically important symptom to diagnose the TMD however in this study mouth opening limitation was not investigated (Rudisch et al. 2001).

This study has a limitation. All data were re-constructed to unilateral and bilateral findings. If one patient has a disc displacement with reduction in the right side TMJ and disc displacement without reduction in the left TMJ, MRI findings of this patient were categorized as unilateral displacement with reduction and unilateral disc displacement without reduction. If another patient has a disc displacement with reduction on both TMJ, this patient was categorized as bilateral disc displacement with reduction. When analyzing correlations between clinical symptoms and MRI findings on condyle-disc pathology, MRI findings of each TMJ would be categorized into 3 types as unilateral, bilateral and normal state. To make more accurate diagnosis, Additional information

should be considered such as range of mouth opening, Angle's classification, origin of pain and tenderness of muscle palpation.

This study was performed to find out an association of clinical symptoms and MRI findings, so for clinicians to have any prospects about TMJ problems with only clinical symptoms and to get noticed already for TMJ problems before taking further TMJ examination. The results of this study are that joint clicking and crepitus were correlated with MRI findings of condyle-disc pathology and without pain condyle-disc degeneration could be advanced.

V.CONCLUSION

The hypothesis of this study that the clinical symptoms have the correlation with MRI findings were accepted. And specifically joint clicking and crepitus had significant correlations with condyle degeneration, disc degeneration or sclerosis. However, pain was not correlated with any MRI findings significantly except hypermobility. The results of this study imply that condyle-disc deformities could be advanced without pain, and joint clicking and crepitus could be clinical symptoms of condyle-disc degeneration.

REFERENCES

Liu, J. K. and M. Y. Tsai. 1996. "The prevalence of TMD in orthodontic patients prior to treatment at NCKUH in southern Taiwan. National Cheng Kung University Hospital". *Funct Orthod,* 13(5): 9-12.

Okeson, J. P. 2008. *Management of temporomandibular disorders and occlusion*. 6th Ed. St. Louis, Mo.: Mosby Elsevier.

Wiese, M., P. Svensson, M. Bakke, T. List, H. Hintze, A. Petersson, K. Knutsson and A. Wenzel. 2008. "Association between temporomandibular joint symptoms, signs, and clinical diagnosis using the RDC/TMD and radiographic findings in temporomandibular joint tomograms". *J Orofac Pain,* 22(3): 239-51.

Adame, C. G., F. Monje, M. Offnoz and R. Martin-Granizo. 1998. "Effusion in magnetic resonance imaging of the temporomandibular joint: a study of 123 joints". *J Oral Maxillofac Surg,* 56(3): 314-8.

Limchaichana, N., A. Petersson and M. Rohlin. 2006. "The efficacy of magnetic resonance imaging in the diagnosis of degenerative and inflammatory temporomandibular joint disorders: a systematic literature review". *Oral Surg Oral Med Oral Pathol Oral Radiol Endod,* 102(4): 521-36.

Dergin, G., C. Kilic, R. Gozneli, D. Yildirim, H. Garip and S. Moroglu. 2011. "Evaluating the correlation between the lateral pterygoid muscle attachment type and internal derangement of the temporomandibular joint with an emphasis on MR imaging findings". *J Craniomaxillofac Surg*.

Campos, M. I., P. S. Campos, M. C. Cangussu, R. C. Guimaraes and S. R. Line. 2008. "Analysis of magnetic resonance imaging characteristics and pain in temporomandibular joints with and without degenerative changes of the condyle". *Int J Oral Maxillofac Surg,* 37(6): 529-34.

Haley, D. P., E. L. Schiffman, B. R. Lindgren, Q. Anderson and K. Andreasen. 2001. "The relationship between clinical and MRI findings in patients with unilateral temporomandibular joint pain". *J Am Dent Assoc,* 132(4): 476-81.

Kopp, S. and B. Rockler. 1979. "Relationship between clinical and radiographic findings in patients with mandibular pain or dysfunction". *Acta Radiol Diagn (Stockh),* 20(3): 465-77.

Hansson, L. G., T. Hansson and A. Petersson. 1983. "A comparison between clinical and radiologic findings in 259 temporomandibular joint patients". *J Prosthet Dent,* 50(1): 89-94.

Helenius, L. M., D. Hallikainen, I. Helenius, J. H. Meurman, M. Kononen, M. Leirisalo-Repo and C. Lindqvist. 2005. "Clinical and radiographic findings of the temporomandibular joint in patients with various rheumatic diseases. A case-control study". *Oral Surg Oral Med Oral Pathol Oral Radiol Endod,* 99(4): 455-63.

Kurita, H., Y. Kojima, A. Nakatsuka, T. Koike, H. Kobayashi and K. Kurashina. 2004. "Relationship between temporomandibular joint (TMJ)-related pain and morphological changes of the TMJ condyle in patients with temporomandibular disorders". *Dentomaxillofac Radiol,* 33(5): 329-33.

Katzberg, R. W., P. L. Westesson, R. H. Tallents and C. M. Drake. 1996. "Orthodontics and temporomandibular joint internal derangement". *Am J Orthod Dentofacial Orthop,* 109(5): 515-20.

Dworkin, S. F. and D. L. Massoth. 1994. "Temporomandibular disorders and chronic pain: disease or illness?". *J Prosthet Dent,* 72(1): 29-38.

American Academy of Craniomandibular Disorders. and C. McNeill. 1990. *Craniomandibular disorders : guidelines for evaluation, diagnosis, and management*. Chicago: Quintessence Pub. Co.

Tasaki, M. M. and P. L. Westesson. 1993. "Temporomandibular joint: diagnostic accuracy with sagittal and coronal MR imaging". *Radiology,* 186(3): 723-9.

Park, J. W., H. H. Song, H. S. Roh, Y. K. Kim and J. Y. Lee. 2011. "Correlation between clinical diagnosis based on RDC/TMD and MRI findings of TMJ internal derangement". *Int J Oral Maxillofac Surg*.

Limchaichana, N., H. Nilsson, E. C. Ekberg, M. Nilner and A. Petersson. 2007. "Clinical diagnoses and MRI findings in patients with TMD pain". *J Oral Rehabil,* 34(4): 237-45.

Kurita, H., Y. Kojima, A. Nakatsuka, T. Koike, H. Kobayashi and K. Kurashina. 2004. "Relationship between temporomandibular joint (TMJ)-related pain and morphological changes of the TMJ condyle in patients with temporomandibular disorders". *Dentomaxillofac Radiol,* 33(5): 329-33.

Lin, Y. C., M. L. Hsu, J. S. Yang, T. H. Liang, S. L. Chou and H. Y. Lin. 2007. "Temporomandibular joint disorders in patients with rheumatoid arthritis". *J Chin Med Assoc,* 70(12): 527-34.

Wiberg, B. and A. Wanman. 1998. "Signs of osteoarthrosis of the temporomandibular joints in young patients: a clinical and radiographic study". *Oral Surg Oral Med Oral Pathol Oral Radiol Endod,* 86(2): 158-64.

Helenius, L. M., P. Tervahartiala, I. Helenius, J. Al-Sukhun, L. Kivisaari, R. Suuronen, H. Kautiainen, D. Hallikainen, C. Lindqvist and M. Leirisalo-Repo. 2006. "Clinical, radiographic and MRI findings of the temporomandibular joint in patients with different rheumatic diseases". *Int J Oral Maxillofac Surg,* 35(11): 983-9.

Vasconcelos Filho, J. O., A. V. Menezes, D. Q. Freitas, F. R. Manzi, F. N. Boscolo and S. M. de Almeida. 2007. "Condylar and disk position and signs and symptoms of temporomandibular disorders in stress-free subjects". *J Am Dent Assoc,* 138(9): 1251-5; quiz 1268.

Rudisch, A., K. Innerhofer, S. Bertram and R. Emshoff. 2001. "Magnetic resonance imaging findings of internal derangement and effusion in patients with unilateral temporomandibular joint pain". *Oral Surg Oral Med Oral Pathol Oral Radiol Endod,* 92(5): 566-71.

국문요약

독일인 환자군 에서 턱관절 증상과 자기공명영상 소견의 상관성

이 연구의 목적은 독일인 환자에서 과두관절질환의 MRI 영상과 임상증상 사이의 관련성을 연구하는 것이다. 240 명의 독일인 환자에서 MRI 검사를 하여 턱관절 부위의 MRI 양측 영상을 획득하였고 임상증상에 대한 검사를 시행한 자료를 조사하였다. 이 연구의 가정은 과두관절질환의 MRI 영상은 임상증상과 어떤 연관성이 있을 것이라는 것이다. 환자들에게 조사한 임상증상은 턱관절의 관절음, 턱관절 염발음, 그리고 턱관절 동통이다. 턱관절의 MRI 검사 후 판독은 7 가지의 판독 범주로 이루어졌는데 그 범주는 과두 변성, 턱관절 디스크 위치, 턱관절 디스크의 변성, 골증식체, 골경화, 활막염 그리고 과운동 이다. 이 연구의 결과는 다음과 같다. 관련성을 평가해 본 결과 턱관절 잡음과 과두 관절의 변성 사이에는 중요한 관련성이 있었다. 반면 턱관절 동통과 턱관절 질환과의 관련성은 크게 나타나지 않았다. 동통은 TMD 의 중요한 임상증상으로 다양한 기원을 가지고 나타난다. 턱관절 동통뿐만 아니라 근육통, 연관통 등이 포함된다. 이번 연구에서는 동통의 기원이 명확히 연구되지 않은 제한점이 있다. 또한 동통의 정도를 측정한 것도 제외되었기 때문에 동통과 자기공명영상 소견의 상관성을 연구하는 데 제한점이 있었을 것으로 예상된다.

기존 연구에서는 턱관절 증상과 자기공명영상 소견의 상관성에 대하서 논란이 많아왔다. 이번 연구에서는 관절 잡음, 염발음과 자기공명영상 소견의 상관성이 나타났고 과두 관절의 변성은 동통이 없이도 진행될 수 있다는 것을 확인하였다.