

Clinical effect of combined  
treatment by subgingival curettage  
and CO<sub>2</sub> laser application.

Sang-Heon Lee

The Graduate School  
Yonsei University  
Department of Dental Science

Clinical effect of combined  
treatment by subgingival curettage  
and CO<sub>2</sub> laser application.

A Dissertation Thesis

Submitted to the Department of Dental Science  
and the Graduate School of Yonsei University

in partial fulfillment of the  
requirements for the degree of  
Master of Dental Science

Sang-Heon Lee

November 2003

This certifies that the dissertation  
thesis of Sang-Heon Lee is approved

Thesis supervisor : Chong-Kwan Kim

Seong-Ho Choi

Yun-Jung Yoo

The Graduate School  
Yonsei University  
November 2003

## 감사의 글

본 논문이 완성되기까지 세심한 배려와 함께 격려해 주시고 많이 부족한 저를 지도하여 주신 김종관 교수님께 깊은 감사를 드립니다. 아울러 많은 관심과 도움을 주신 최성호 교수님께도 진심으로 감사드립니다. 또한 많은 조언과 관심으로 지켜봐주신 채중규 교수님, 조규성 교수님, 김창성 교수님, 방은경 선생님께도 감사의 말씀 올립니다.

본 임상연구에 많은 노력을 더해주신 진미성, 임세웅 선생님을 포함한 치주과 교실원 여러분께도 깊은 감사의 마음을 전합니다.

한결같이 저에게 전적인 신뢰와 함께 저를 지지해주신 부모님께 이 논문을 드립니다.

2003년 11월

저자 씀

## Table of Contents

List of Tables & Figures . . . . .	iii
Abstract (English) . . . . .	iv
I. Introduction . . . . .	1
II. Materials & Methods . . . . .	3
A. Clinical sampling & design . . . . .	3
B. Clinical Parameters . . . . .	3
1. Probing pocket depth and probing attachment level . . . . .	3
2. Bleeding on probing . . . . .	4
3. Gingival Recession . . . . .	4
C. Treatment Procedures . . . . .	4
D. Application of Laser . . . . .	4
E. Statistical Analysis . . . . .	5
III. Results . . . . .	6
1. Probing pocket depth . . . . .	6
2. Clinical attachment level . . . . .	7
3. Bleeding on probing . . . . .	8
IV. Discussion . . . . .	10
V. Conclusion . . . . .	13
References . . . . .	14
Clinical Photos . . . . .	18
Abstract (Korean) . . . . .	20

## List of Tables and Figures

Table 1. Probing Pocket Depth . . . . .	6
Table 2. Clinical attachment level . . . . .	8
Table 3. Clinical attachment level . . . . .	9
Figure 1. Changes in Probing Pocket Depth (mm) . . . . .	7
Figure 2. Changes in clinical attachment level (mm) . . . . .	8
Figure 3. Changes in Bleeding on probing (%) . . . . .	9
Figure 4. Clinical findings of a patient (55-year-old female) of the laser group	
Figure 4-a Pretreatment view . . . . .	18
Figure 4-b Laser Irradiation. . . . .	18
Figure 4-c Laser application is finished . . . . .	18
Figure 4-d 1 month after treatment . . . . .	19
Figure 4-e 6 months after treatment . . . . .	19

## Abstract

### Clinical effect of combined treatment by subgingival curettage and CO<sub>2</sub> laser application.

The objective of the present study was to evaluate the clinical effect of CO<sub>2</sub> laser treatment when used in combination with conventional subgingival curettage through the measurement of clinical parameters.

Twelve patients with chronic moderate to advanced periodontitis were selected. 2 quadrants of each patient were randomly assigned to one of the following study groups: 1) subgingival curettage only as Control group 2) subgingival curettage and laser treated using an energy level of 0.8W as Laser group; Clinical parameters such as probing pocket depth, clinical attachment level, gingival recession and bleeding on probing were recorded at baseline and 1, 3, 6 month(s) after baseline respectively.

An obvious clinical improvement (marked reductions of bleeding on probing, probing pocket depth and clinical attachment level) were found in both groups comparing with baseline. However, the differences between groups in probing pocket depth and clinical attachment level were not significant. Bleeding on probing showed statistically significant difference between groups on after 6 months only ( $p < 0.05$ ).

In conclusion, additional use of CO<sub>2</sub> laser on non-surgical periodontal treatment may help reduction of inflammation.

---

**Key words:** CO<sub>2</sub> laser, periodontitis, non-surgical therapy, bleeding on probing, clinical attachment level, comparison study, split-mouth design.

# Clinical effect of combined treatment by subgingival curettage and CO<sub>2</sub> laser application.

Sang-Heon Lee, DDS

Department of Dental Science, Graduate School,

Yonsei University

(Directed by Prof. Chong-Kwan Kim, D.D.S., M.S.D., PhD.)

## I. INTRODUCTION

Recent development of laser technology suggests a great deal of possibilities in the field of dentistry. The mechanism and safety of laser surgery is well established in many studies especially on the soft tissue applications. It has advantages including excellent hemostasis, visibility and less postoperative pain(claimed but undocumented) (Myers, 1991; Research, Science and Therapy Committee of the American Academy of Periodontology, 2002). But from a periodontal point of view, much has yet to be proven.

Several researchers have reported studies on laser applications to periodontal therapy. Cobb et al.(1992) and Ando et al. (1996) examined the in vivo bactericidal effect and concluded that the exposure of the root surface to laser could significantly decrease the levels of subgingival microflora of the patients with generalized adult periodontitis. Some studies have reported that the laser could reduce the number of curette strokes necessary for removing calculus (Tseng et al., 1991), Ito et al.(1993) reported that the laser irradiation effectively removed the smear layer, uncovered dentinal tubules, and exposed collagen fibers on the root surface.



Many studies have also suggested efficacy of CO<sub>2</sub> laser application on the root surfaces in vitro. There was an in vitro study which described the effectiveness of CO<sub>2</sub> laser irradiation on the root surfaces removing the smear layer which could impede soft tissue attachment (Misra et al., 1999). Crespi et al. (2002) found that more fibroblasts attached onto root surfaces CO<sub>2</sub> laser applied in vitro.

The objective of the present study was to evaluate the clinical effect of CO<sub>2</sub> laser treatment when used in combination with conventional subgingival curettage through the measurement of clinical parameters.

## **II. MATERIALS AND METHODS**

### **A. Clinical Sampling and Design**

This study was designed as 6-month clinical trial with split mouth design. Enrolled patients included men and women in good general health, 30 years of age or older who has chronic moderate periodontitis and has at least one site of periodontal pocket with  $PD \geq 5\text{mm}$  in each quadrant. Subjects enrolled were 12 patients (9 males and 3 females) aged 34–67 years (mean: 53 years) selected from patients presenting for periodontal treatment at the Dept. of Periodontics, Dental Hospital, Yonsei University Medical Center. The written informed consent was given and it was submitted from the participants.

The experimental site(subgingival curettage and laser application) and control site(subgingival curettage only) were randomly assigned on same patients. Scaling and basic oral hygiene education including instruction of tooth brushing, flossing, and use of an interdental brush were given at the start of the study and instructions reinforced at all subsequent visits. Clinical parameters such as probing pocket depth, clinical attachment level, gingival recession and bleeding on probing were recorded at baseline, 1 month and 3, 6 months subsequently.

### **B. Clinical parameters**

#### ***1. Probing pocket depth and probing attachment level***

Probing pocket depth and probing attachment level were measured to the nearest of 1mm with Marquis color corded probe (0.5mm in diameter). During probing the probe was directed to the long axis of the tooth. The probe was

moved twice towards the base of the pocket to secure finding the pocket base. The distances from the pocket base to the gingival margin (probing pocket depth) and to the cementoenamel junction (probing attachment level) were recorded.

### ***2. Bleeding on probing***

Presence or absence of bleeding was recorded 5 second after removing the periodontal probe when measuring pocket depth and attachment level. The proportion of bleeding surfaces out of the total number of examined surfaces was calculated.

### ***3. Gingival recession***

The location of the gingival margin was assessed by subtraction of the figure for pocket depth from the figure for attachment level.

## **C. Treatment Procedures**

Conventional subgingival curettage was employed in one quadrant. The other quadrant of same maxilla was treated with CO<sub>2</sub> laser irradiation to the root surface after root planing. Subsequently, they were recalled monthly for regular check up and supragingival professional tooth cleaning. And the measurement of clinical parameters was done 3 and 6 months after treatment.

## **D. Application of Laser**

Laser-treated sites were irradiated with a CO<sub>2</sub> laser<sup>‡</sup> using a focused beam (2mm from target surface), an 0.4mm diameter focal spot, wavelength of 10.6 $\mu$ m. Laser parameters were 0.8W of power delivered at 50Hz with continuous mode

with cooling air blow supplied according to the manufacturer instructions. Instrumentation was performed from coronal to apical in parallel paths with an inclination of the fiber tip of 15 to 20 degrees to the root surface. The instrumentation for both laser group and control group was performed until the operator felt that the root surfaces were adequately debrided and planed. As for the laser group during laser application, char layer was formed on the root surfaces. And it was removed intermittently with hand instruments during and after laser application.

## **E. Statistical Analysis**

Mann-Whitney test was used to determine the statistical significance of clinical parameters between different treatment groups at baseline and at indicated time points after therapy. Wilcoxon signed rank test was used to determine the statistical significance of clinical parameters within groups in comparison with baseline.

‡ OPELASER O3SII, Yoshida Dental MFG. CO., Japan.

### III. RESULTS

#### 1. Probing pocket depth

The pocket depth decreased in all of the groups after 1 month and 3, 6 months from the treatment. The baseline pocket depth were  $3.96\pm1.21\text{mm}$ ,  $3.84\pm1.09\text{mm}$  respectively in laser group, control group and it was  $2.95\pm0.89\text{mm}$ ,  $3.04\pm1.06\text{mm}$  with an approximately 0.8–1.0mm of decrease in the pocket depth after 1 month. And the results were maintained thereafter, it was  $2.83\pm0.79\text{mm}$ ,  $2.93\pm0.71\text{mm}$  after 3 months and it was  $2.83\pm0.71\text{mm}$ ,  $2.84\pm1.01\text{mm}$  after 6 months, which showed an approximately 1.0–1.1mm decrease in the pocket depth. Both of the groups showed a consistent decrease after the treatment. However there were no differences between the two groups (  $p<0.05$  ). (Table 1, Figure 1)

Table 1. Probing pocket depth(mm)

	Baseline	1 month	3 months	6 months
Laser	$3.95\pm1.21$	$2.95\pm0.89^*$	$2.83\pm0.79^*$	$2.83\pm0.71^*$
Control	$3.84\pm1.09$	$3.04\pm1.06^*$	$2.93\pm0.71^*$	$2.84\pm1.01^*$

\*Statistically significant differences compared with baseline(  $p<0.05$  )

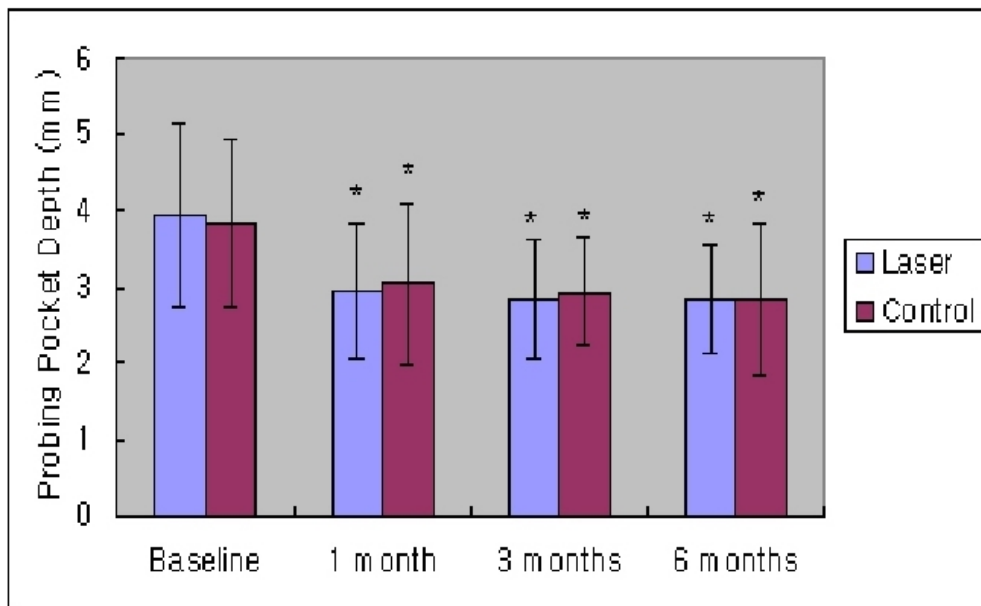


Figure 1. Changes in Probing pocket depth(mm)

\*Statistically significant differences compared with baseline( $p<0.05$ )

## 2. Clinical attachment level

The gain of attachment followed the same fashion of change as probing pocket depth above. Clinical attachment level in all of the groups also decreased after 1 month and 3, 6 months from the treatment. The results after 1 month were  $3.34\pm1.31$ mm for the laser group,  $3.55\pm1.85$ mm for the control group. The laser group revealed slightly more gain of attachment, but there were no statistically significant difference ( $p<0.05$ ). It was  $3.28\pm1.05$ mm,  $3.31\pm1.10$ mm, and  $3.24\pm1.28$ mm,  $3.26\pm1.19$ mm respectively in the laser group and the control group after 3 and 6 months respectively. And likewise the laser group and the control group showed a similar gain of attachment, and there were no differences between the laser group and the control group, either ( $p<0.05$ ). (Table 2, Figure 2)

Table 2. Clinical attachment level(mm)

	Baseline	1 month	3 months	6 months
Laser	4.14±1.38	3.34±1.31*	3.28±1.05*	3.24±1.28*
Control	4.12±1.70	3.55±1.85*	3.31±1.10*	3.26±1.19*

\*Statistically significant differences compared with baseline( $p<0.05$ )

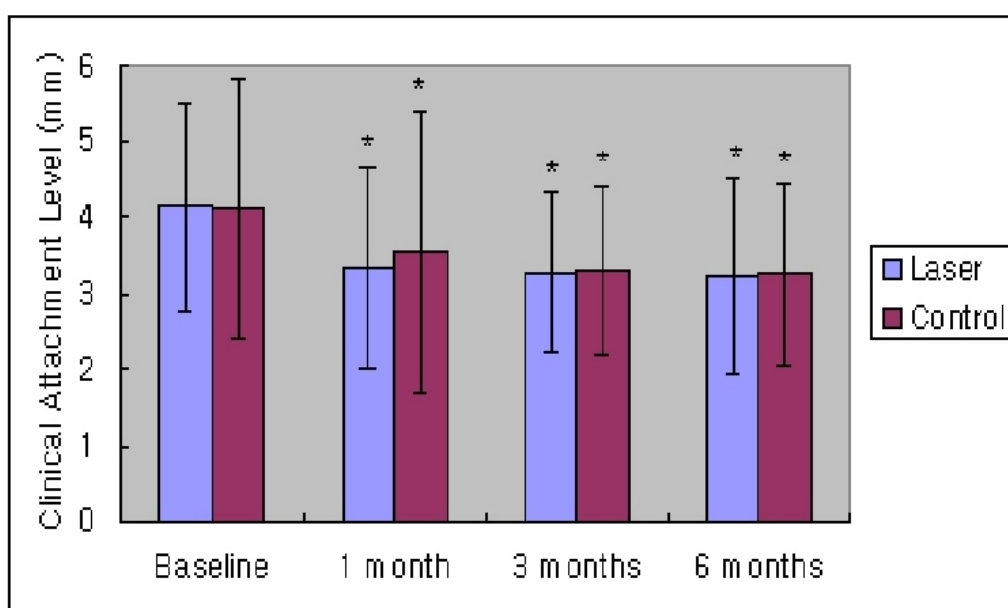


Figure 2. Changes in Clinical attachment level(mm)

\*Statistically significant differences compared with baseline( $p<0.05$ )

### 3. Bleeding on probing

The percentage of the bleeding on probing decreased in both of the groups after the treatment. The baseline of the percentage of bleeding on probing were 62.5±28.4% 57.9±29.2%, respectively in the laser group and control group and it was 27.8±16.4%, 34.7±17.8%, after 1 month and 24.9±12.2%, 28.6±11.8% after 3 months of treatment, showing a consistent decrease after the treatment (

$p < 0.05$  ). But there were no differences between the 2 groups.

After 6 months of treatment, it was  $16.5 \pm 8.8\%$ ,  $26.74 \pm 13.0\%$ , and there was statistically significant difference between the laser group and control group ( $p < 0.05$ ). (Table 3, Figure 3).

Table 3. Bleeding on probing(%)

	Baseline	1 month	3 months	6 months
Laser	$62.5 \pm 28.4$	$27.8 \pm 16.4^*$	$24.9 \pm 12.0^*$	$16.5 \pm 8.8^*$
Control	$57.9 \pm 29.2$	$34.7 \pm 17.8^*$	$28.6 \pm 11.8^*$	$26.7 \pm 13.0^{*\dagger}$

\*Statistically significant differences compared with baseline( $p < 0.05$ )

†Statistically significant differences compared with control( $p < 0.05$ )

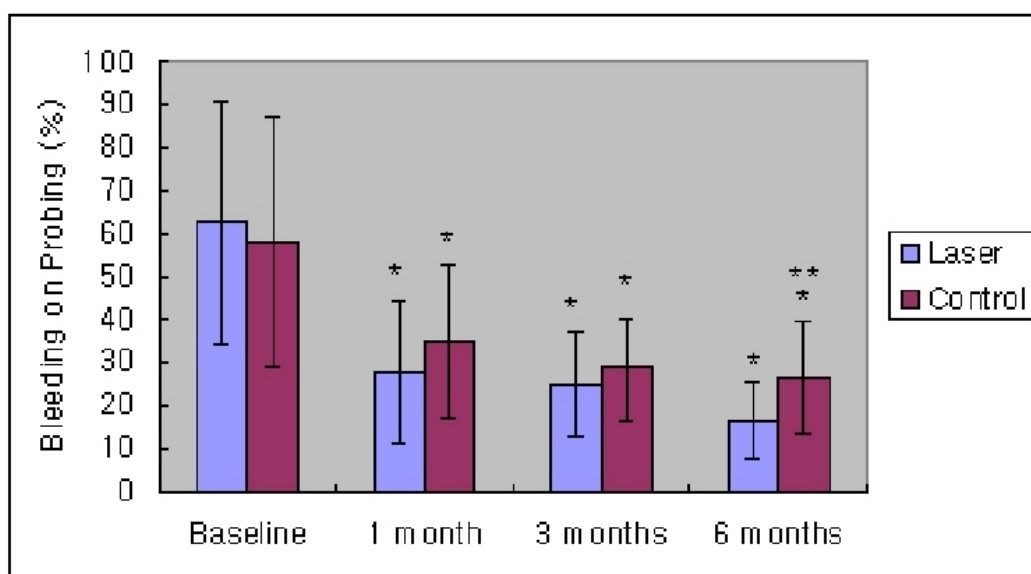


Figure 3. Changes in Bleeding on probing(%)

\* Statistically significant differences compared with baseline( $p < 0.05$ )

\*\* Statistically significant differences compared with control and laser group( $p < 0.05$ )



## IV. DISCUSSION

Many have shown interests on applying laser on the field of periodontics, but most of papers had focused on the Nd:YAG laser or Er:YAG laser.

Sjostrom and Friskopp (2002) applied Nd:YAG laser in the treatment of periodontal pockets and they reported that the laser application facilitated instrumentation by removing the majority of the calculus deposits enhancing vision with hemostatic effect.

In a comparable clinical studies, Schwarz et al. (2001) found the use of Er:YAG laser had similar clinical outcome comparing with Scaling & Root Planing(SRP) and laser applied together. And in a split mouth designed clinical study (Schwarz et.al., 2003), they concluded that the condition established through non-surgical therapy using laser or SRP could be maintained over 2-year period.

CO<sub>2</sub> laser has been used widely in the field of soft tissue surgery especially in excisional ones(Roed-Petersen,1993;Barak & Kaplan, 1988;Apfelberg et al., 1985). In those indications the power setting of the laser device is usually set as high as 5 to 15 watts (Research, Science and Therapy Committee of the American Academy of Periodontology, 2002). However by lowering the power level, CO<sub>2</sub> could be utilized just like other lasers. And there are several reports suggesting the possibility of CO<sub>2</sub> laser in treating periodontal diseases in a similar way as other type of lasers. Misra et al. (1999) performed an in vitro study examining the effect of CO<sub>2</sub> laser irradiation on the root surfaces. When reaching sufficient energy level(1 second at 3W), the smear layer formed after root planing was removed. Furthermore comparing with other root surface conditioning methods such as EDTA treatment or citric acid application, the laser showed advantage regarding less damage onto the dentinal tubule

structure.

Crespi et al. (2002) utilized SEM observations to confirm the biocompatibility of the lased root surfaces. They found that more fibroblasts attached onto root surfaces CO<sub>2</sub> laser applied combined with SRP than SRP group or control group in vitro.

The aim of the present study was to compare the clinical results following non-surgical periodontal treatment with conventional subgingival curettage or conventional curettage and additional CO<sub>2</sub> laser application. In the test of a treatment modality if it is successful in patients with periodontitis is evaluated with the decrease of the pocket depth and the gain of clinical attachment level (Lindhe et al., 1984; Ramfjord et al., 1987; Kaldahl et al., 1996).

The results have demonstrated that non-surgical periodontal treatment with both treatment modalities results in significant reductions in PD and gains of CAL that lasted at least 6 months of observation period. But there were not any statistically significant difference between 2 groups except for BOP.

Bleeding on probing is a significant clinical factor demonstrating to have an inflammatory lesion in the base of connective tissue of the gingival crevice (Meitner et al., 1979), and it has been acknowledged by many investigators (Hancock, 1981; Polson and Caton, 1985) that gingival bleeding acts as an indicator of the activity of the of the periodontal diseases.

In present study, initially BOP was slightly higher at the laser sites but did not have statistically significant difference at the baseline. However the laser group showed slightly more reduction of BOP under significance level till 3 months. And after 6 months it differed significantly ( $p < 0.05$ ). But other parameters, PD and CAL, did not have significant difference. With limitation of information, we can only prudently conclude that the application of laser contributed on the reduction of inflammatory condition. The mechanisms of action of laser therapy might have to be investigated based on subcellular level

to identify it.

Liu et al. (1999) suggested that laser therapy alone was less effective than conventional SRP. But when jointly used laser application with SRP group revealed best treatment results considering the reduction of IL-1. Gopin et al. (1997) pointed out with a histologic evaluation that soft tissue attachment loss occurred after CO<sub>2</sub> irradiation. It might be due to the presence of char layer.

When the laser comes into contact with surface debris, organic material, or pigmented surface, intense, localized heat is produced and then charring layer is formed. It includes remnants of ammonia, cyanate and cyanamide. The residual char layer could act as a significant barrier to soft tissue reattachment. Trylovich et al. (1992) reported that in case of char layer in vitro, there is a suppression of fibroblast attachment. Thomas et al. (1994) reported that there is a fibroblast attachment when root planing and air-powder abrasive slurry are used on lased root surface in vitro.

Therefore in the present study, after the application of laser, the root surfaces were checked again and carefully planed with hand instruments to get rid of the char layer. By employing efforts described above, we expected more attachment gain on the laser treated sites than the sites conventionally treated. But the difference between the two treatment modalities was not large enough to be analyzed as statistically significant. It might mean that the laser therapy has nothing better than conventional non-surgical therapy. But it might have to be evaluated with more qualitative ways to confirm if difference exists or not.

Additional use of CO<sub>2</sub> laser on non-surgical periodontal treatment may help reduction of inflammation. But genuine or additive effect of the laser therapy on the new attachment is cannot be judged with present, limited data. So more detailed clinical and biochemical research including histologic evaluation might be required to find out the exact mechanisms of action of laser application on the periodontal tissues if there are another processes which is still unknown.

## V. Conclusion

The aim of the present study was to compare the clinical results following non-surgical periodontal treatment with conventional subgingival curettage or conventional curettage and additional CO<sub>2</sub> laser application. 24 quadrants from 12 patients were examined and 2 quadrants of each patient were randomly assigned to one of the 2 groups. The experimental group received laser irradiation at 0.8W in combination with conventional subgingival curettage and control group received subgingival curettage only. The results are as follows.

An obvious clinical improvement (marked reductions of bleeding on probing, probing pocket depth and clinical attachment level) were found in both groups comparing with baseline. However, the differences between groups in probing pocket depth and clinical attachment level were not significant. Bleeding on probing showed statistically significant difference between groups on after 6 months only ( $p < 0.05$ ).

In conclusion, additional use of CO<sub>2</sub> laser on non-surgical periodontal treatment may help reduction of inflammation.

## REFERENCES

Ando Y, Aoki A, Watanabe H, Ishikawa I. Bactericidal effect of erbium YAG laser on periodontal bacteria. *Lasers in Surgery & Medicine* 19:190-200, 1996.

Apfelberg DB, Master MR, Lash H, White DN. Benefits of the CO<sub>2</sub> laser in oral hemangioma excision. *Plastic and Reconstructive Surgery* 75:46-50 1985.

Barak S, Kaplan I. The CO<sub>2</sub> laser in the excision of gingival hyperplasia caused by nifedipine. *Journal of Clinical Periodontology* 15:633-635, 1988.

Cobb CM, McCawley TK, Killoy WJ. A preliminary study on the effects of the Nd:YAG laser on root surfaces and subgingival microflora in vivo. *Journal of Periodontology* 63:701-707, 1992.

Crespi R, Barone A, Covani U, Ciaglia RN, Romanos GE. . Effects of CO<sub>2</sub> laser on fibroblast attachment to root surfaces. a scanning electron microscopy analysis *Journal of Periodontology* 73:1308-1312, 2002.

Gopin BW, Cobb CM, Rapley JW, Killoy WJ. Histologic evaluation of soft tissue attachment to CO<sub>2</sub> laser-treated root surfaces: An in vivo study. *International Journal of Periodontics & Restorative Dentistry* 17:317-325, 1997.

Hancock EB. Determination of periodontal disease activity. *Journal of Periodontology* 52:492-499, 1981.

Ito K, Nishikata J, Murai S. Effects of Nd:YAG laser radiation on removal of a root surface smear layer after root planing: A scanning electron microscopic study. *Journal of Periodontology* 64:547-552, 1993.

Kaldahl WB, Kalkwarf KL, Patil KD, Molvar MP, Dyer JK. Long term evaluation of periodontal therapy: I. Response to 4 therapeutic modalities. *Journal of Periodontology* 67:93-102, 1996.

Lindhe J, Westfelt E, Nyman S, Socransky SS, Haffajee AS. Long-term effect of surgical/non-surgical treatment of periodontal disease. *Journal of Clinical Periodontology* 11:448-458, 1984.

Liu CM, Hou LT, Wong MY, Lan WH. Comparison of Nd:YAG laser versus scaling and root planing in periodontal therapy. *Journal of Periodontology* 70:1276-1282, 1999.

Meitner SW, Zander HA, Iker HP, Polson AM. Identification of inflamed gingival surfaces. *Journal of Clinical Periodontology* 6:93-97, 1979.

Misra, V, Mehrotra KK., Dixit, J., Maitra SC. Effect of a carbon dioxide laser on periodontally involved root surfaces. *Journal of Periodontology* 70:1046-1052, 1999.

Myers TD. Lasers in dentistry. *Journal of American Dental Association* 122:47-50, 1991.

Polson AM, Caton JG. Current status of bleeding in the diagnosis of periodontal disease. *Journal of Periodontology* 56(suppl):1-7, 1985.

Ramfjord SP, Caffesse RG, Morrison EC, et al. Four modalities of periodontal treatment compared over 5 years.. Journal of Clinical Periodontology 18:445-452, 1987.

Research, Science and Therapy Committee of the American Academy of Periodontology. Lasers in Periodontics. Journal of Periodontology 73:1231-1239, 2002.

Roed-Petersen B.. The potential use of CO2-laser gingivectomy for phenytoin-induced gingival hyperplasia in mentally retarded patients. Journal of Clinical Periodontology 20:729-731, 1993.

Schwarz F, Sculean A, Georg T, Reich E. Periodontal treatment with an Er:YAG laser compared to scaling and root planing. A controlled clinical study Journal of Periodontology 72:361-367, 2001;.

Schwarz F, Sculean A, Berakdar M, Georg T, Reich E, Becker J. Periodontal treatment with an Er:YAG laser or scaling and root planing. A 2-year follow up splitmouth study. Journal of Periodontology 74:590-596, 2003.

Sjostrom L, Friskopp J. Laser treatment as an adjunct to debridment of periodontal pockets. Swedish Dental Journal 26(2):51-57, 2002.

Thomas D, Rapley JW, Cobb CM, Spencer P, Killoy WJ. Effects of the Nd:YAG laser and combined treatments on fibroblast attachment to root surfaces. Journal of Clinical Periodontology 21:38-44, 1994.

Trylovrich DJ, Cobb CM, Pippin DJ, Spencer P, Killoy WJ. The effects of the Nd:YAG laser on in vitro fibroblast attachment to endotoxin-treated root surfaces. *Journal of Periodontology* 63:626-632, 1992.

Tseng P, Gilkeson CF, Pearlman B, Liew V. The effect of Nd:YAG laser treatment on subgingival calculus in vitro. *Journal of Dental Research* 70(Spec. Issue):657(Abstr.62), 1991.



## Clinical photos (I)

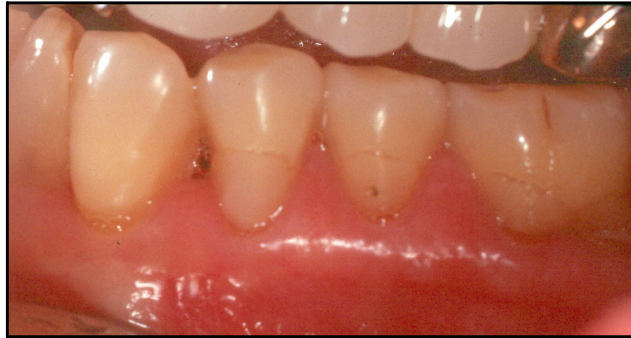

Figure 4-a Pretreatment view

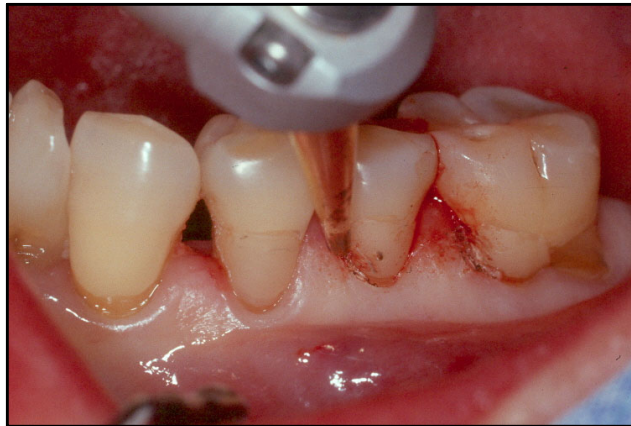


Figure 4-b Laser Irradiation.

Note the good bleeding control during the instrumentation

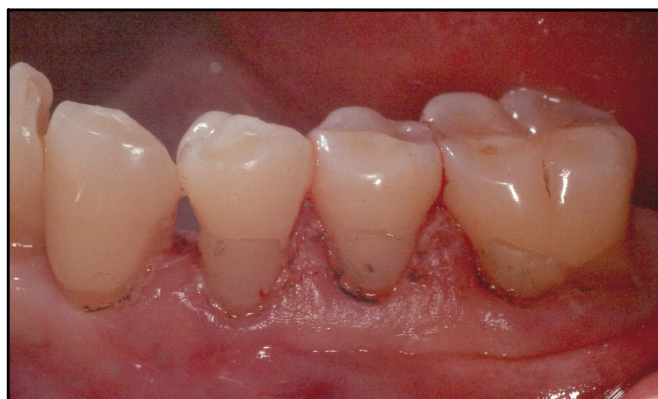

Figure 4-c Laser application is finished

## Clinical photos (II)

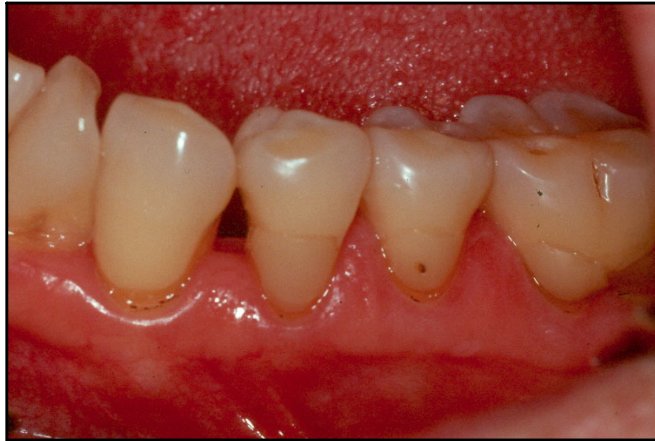

Figure 4-d 1 month after treatment

Gingival inflammation is reduced markedly.

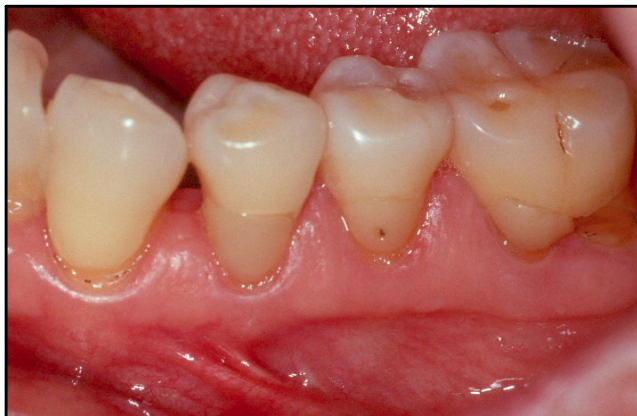

Figure 4-e 6 months after treatment.

Treated sites are well maintained throughout the observation period.

국문요약

## 치은연하 소파술과 CO<sub>2</sub> 레이저의 병용시의 임상적 효과

연세대학교 대학원 치의학과

(지도 김종관 교수)

이 상 현

최근의 레이저 기술의 발전은 치의학영역에서 많은 가능성을 제시해주고 있으며, 레이저를 이용한 외과적 치료의 기전과 안전성은 많은 분야에서 입증되어 있다. 근래에는 치주학적 분야에도 레이저를 적용하려는 노력이 계속되어 왔으며, 치석의 제거나 치근면의 세균제거 등에서 효과를 제시한 연구들이 있었다. 본 연구의 목적은 CO<sub>2</sub> 레이저를 통상적 치은연하소파술과 병용하였을때의 임상적 효과를 임상 지수의 측정을 통하여 평가하는 것이다.

만성 중등도-고도의 치주염으로 진단된 12명의 환자가 본 임상연구에 포함되었다. 한 환자에서 각각 2부위의 사분악을 선택하여 임의로 2가지 치료군에 다음과 같이 나누어 포함시켰다: 1) 치은연하 소파술만을 적용한 사분악을 대조군 2) 치은연하 소파술과 0.8W의 에너지 수준을 갖는 CO<sub>2</sub> 레이저를 병용하여 적용한 사분악을 Laser 군으로 포함하였다. 치주낭 탐침 깊이, 임상 부착 수준, 치은 퇴축 및 탐침시 출혈 등의 임상지수를 치료 전과 술후 각각 1, 3, 6개월 경과시에 측정하여 다음과 같은 결과를 얻었다.

치주낭 탐침 깊이, 임상 부착 수준, 치은 퇴축 및 탐침시 출혈 등의 모든 측정된 임상지수에서 치료 전·후를 비교하였을 때 통계적으로 유의한 개선을 보였다. 그러나 실험군과 대조군간의 비교에서는 치주낭 탐침 깊이, 임상 부착 수준에서는 통계적으로 유의한 차이를 보이지 않았다. 탐침시 출혈은 술후 6개월시에 Laser군

에서 대조군에 비하여 통계적으로 유의성있는 차이를 보이며 감소하였다( $p<0.05$ ).

결론적으로 CO<sub>2</sub> laser를 비외과적 치주 치료에 부가적으로 적용하였을 때 염증 감소에 기여할 가능성이 있을것으로 사료된다.

---

핵심되는 말: CO2 레이저, 치주염, 비외과적 치료, 탐침시 출혈, 임상부착수준, 비교 연구, split-mouth 설계.