The incidence and the type of canal isthmuses and accessory canals in the human permanent first molars following instrumentation

The Graduate School

Yonsei University

Department of Dentistry

Myoungah Seo

The incidence and the type of canal isthmuses and accessory canals in the human permanent first molars following instrumentation

A Masters Thesis
Submitted to the Department of Dentistry
and the Graduate School of Yonsei University
in partial fulfillment of the requirements for the degree of
Master of Dental Science

Myoungah Seo

December 2002

This certifies that the masters thesis of Myoungah Seo is approved.

_____
Thesis Supervisor : Il-Young Jung

_____
Thesis Committee Member : Seung-Jong Lee

_____
Thesis Committee Member : Hee-Jin Kim

The Graduate School

Yonsei University

December 2002

감사의 글

먼저 지금은 미국 플로리다에 계시지만 본 논문이 나오기 까지 지속적인 관심과 학문적인 충고를 아끼지 않으신 정일영 교수님께 깊은 존경과 감사를 드리고 싶습니다. 그리고 다듬어지지 않은 저의 논문을 꼼꼼히 지적해 주신 이승종 교수님, 김희진 교수님, 항상 따뜻한 관심과 조언을 하여 주신 이찬영 교수님, 박성호 교수님, 노병덕 교수님, 김의성 교수님께도 감사를 드립니다.

특히 지금은 비록 미국 코네티컷에 계시지만 **e-mail** 을 통해 저의 수련생활을 바로 곁에서 지켜봐 주신거나 다름없는 금기연 교수님께도 깊은 감사를 드립니다.

논문을 쓰는데 많은 도움을 주신 보존학 교실원들과 영동 세브란스의 의국원들, 특히 교수님이 안계시는데도 열심히 수련생활을 함께 해 준 홍상희 선생과 장경하 선생, 바쁜 수련생활에도 시간을 내어 실험을 도와준 권중구 선생에게도 고마움을 전하고 싶습니다.

남들보다 긴 학생 생활을 하는 딸을 위해 곁에서 바다처럼 깊고 하늘처럼 넓은 사랑으로 보살펴 주신 부산에 계시는 엄마와 늘 하느님의 사랑으로 저를 위해 기도해 주신 시어머니께도 이 글을 빌어 사랑한다고 말하고 싶습니다.

마지막으로 지난 **10** 년간 저의 멋진 애인이었고 이제는 영원한 인생의 동반자가 된 미국에서 힘든 유학생활을 하고 있는 저의 남편 정충서씨에게 사랑과 감사의 말을 전하고 싶습니다.

2002 년 **12** 월

서 명 아

Contents

Lists of Figures, Tables ---------- v

Abstract in English ---------- vii

I. Introduction ---------- 1

II. Materials and Methods ---------- 3

1. Tooth preparation ---------- 3
2. Classification of cross-sectional canal configurations ---------- 4

III. Results ---------- 8

IV. Discussion ---------- 11

References ---------- 16

Abstract in Korean ---------- 18

List of Figures

Fig. 1. Type A : One canal (a) or 2 canals merged into one (b). ---------- 6

Fig. 2. Type B : Two separated canals without an isthmus or accessory canal. ---------- 6

Fig. 3. Type C1 : Two canals with one or more partial isthmuses between main canals. ---------- 6

Fig. 4. Type C2 : Two canals with a complete isthmus. ---------- 7

Fig. 5. Type D1: Two canals with one or more accessory canals that are located between main canals. ---------- 7

Fig. 6. Type D2 : Two canals with one or more accessory canals that are located between a main canal and outer root surface. ---------- 7

Fig. 7. Accessory canal located in the palatal side to MB_2 canal (Type D2) was shown at the 4mm level of the maxillary first molars (arrowhead). ---------- 13

Fig. 8. Type B was shown at the 2 mm level (upper, a) but the type of 2 mm upper level was Type C2 (complete isthmus) in the resected root surface of the mandibular molar (upper, b). In the maxillary molar, Type B was shown at the 2 mm level (lower, a) but Type C1 (partial isthmus) was found at the 4 mm level (lower, b). ---------- 15

List of Tables

Table 1. Canal types in the MB roots of the maxillary first molars and the mesial roots of the mandibular first molars, as determined by the periapical radiographs .- 8

Table 2. The classification of the canal configuration types at each level in the MB root sections of the maxillary first molars with two canals- - - - - 9

Table 3. The classification of the canal configuration types at each level in the mesial root sections of the mandibular first molars with two canals. - 9

Table 4. Incidence of the canal configuration type in the MB roots of maxillary first molars and the mesial roots of the mandibular first molars according to the canal type. - 10

Abstract

The incidence and the type of canal isthmuses and accessory canals in the human permanent first molars following instrumentation

Myoungah Seo

Department of dentistry, The Graduate School, Yonsei University

(Directed by Professor Il-Young Jung, D.D.S., M.S.D., Ph.D.)

A dental isthmus and accessory canals usually containing pulp tissue are such a region that is difficult to clean and obturate during surgical endodontics. There have been several studies about the incidence of the isthmus and accessory canal in human extracted permanent molars without root canal instrumentation. But root canal instrumentation may change the canal shape and affect the incidence of the isthmus and accessory canal.

Therefore, the purpose of this study in vitro was to determine the incidence and the type of the isthmus and accessory canal in the MB roots of the maxillary first molars and the mesial roots of the mandibular first molars following instrumentation with an aid of stereomicroscope.

Forty maxillary first molars and 38 mandibular first molars with 2 canals were evaluated in this study. After resection of the MB root or the mesial root of each first molar, the root canal was instrumented to size #30 and filled with single cone and Tubuli-seal. Transverse serial section was performed at the 2-5 mm level from the root apex and the cross-sectional

configurations were observed using stereomicroscope. Also the sum of the incidence with isthmus and accessory canal in the roots with two canals were evaluated because of its importance in surgical endodontics. The results were as the followings..

1. The incidence of isthmuses and accessory canals in the maxillary and the mandibular molars with two canals were highest at the 4 mm level from apex (63.2%; 82.5%).
2. The incidence of the anatomical variances was higher in molar roots with type III canal.
3. In the MB roots of the maxillary molars, the accessory canals, which are located between a main canal and outer root surface, was seen at the 2-4 mm level(Type II canal: 6.3%, Type III canal : 9.0-13.6%).
4. Different canal configurations were often found at the each cutting level in the same root.

Under the conditions of this study, the MB roots of the maxillary first molars and the mesial roots of the mandibular first molars with two canals showed still high incidence and variable location of accessory canals and isthmuses at the 2-5 mm level of selected root even after instrumentation. This information may be helpful for practitioners during endodontic treatment, especially the retrograde preparation of the permanent first molars.

Key words : mesiobuccal root of the maxillary first molar, mesial root of the mandibular first molar, surgical endodontics, canal isthmus, accessory canal

The incidence and the type of canal isthmuses and accessory canals in the human permanent first molars following instrumentation

Myoungah Seo

Department of dentistry, The Graduate School, Yonsei University
(Directed by Professor Il-Young Jung, D.D.S., M.S.D., Ph.D.)

I. Introduction

Failures of endodontic surgery may be caused by a lack of knowledge of the anatomical variations such as the isthmus and accessory canal on the resected root surface (Stephan and Richard, 2002 ; Weller *et al.* , 1995)

Previous studies have reported that the detection and the incorporation of the isthmuses into the root-end cavity are important for ensuring the complete debridement and sealing of the root canal system (Cambruzzi and Marshall, 1983 ; Rubinstein and Kim, 1999).

There have been several studies on the incidence of isthmuses in human permanent molars. Cambruzzi and Marshall (1983) reported that the incidence of isthmuses in the mesiobuccal (MB) roots of the maxillary molars and the mesial roots of the mandibular molars were 30.1% and 60.2%, respectively. Weller *et al.* (1995) presented the concept of a partial

isthmus and reported a 100% incidence of a canal isthmus including a partial isthmus at the 4mm level from the apex of the MB roots in the permanent maxillary first molars containing two canals. Tam and Yu (2002) included the accessory canals when classifying the canal configurations and reported that 12.5% of the MB roots in the permanent maxillary first molars with 2 canals had one or more accessory canals between the two MB canals.

However, most previous studies have reported the incidence and the type of isthmuses and accessory canals from the cross-sectional configurations of extracted teeth without root canal instrumentation (Weller *et al.* , 1995 ; Cambruzzi and Marshall, 1983 ; Tam and Yu, 2002). Root canal instrumentation may change the canal shape and affect the incidence of isthmuses and accessory canals. Therefore, information on the anatomical variances from the post-instrumented root may assist clinicians during surgical endodontics.

The purpose of this study *in vitro* was to determine the incidence and the type of the isthmuses and accessory canals in the MB roots of the maxillary first molars and the mesial roots of the mandibular first molars following instrumentation with an aid of a stereomicroscope.

II. MATERIALS AND METHODS

1. Tooth Preparation

Fifty-one human maxillary first molars and 44 mandibular first molars with a fully developed root were collected from oral surgeons and general dentists. The age, sex and reason for extraction were not considered in this study. The identification of these teeth as the maxillary and the mandibular first molars was confirmed using the accepted criteria (DuBrul, 1980 ; Kim and Lee, 1997). All teeth were stored in a 5% sodium azide solution at 4℃ until needed.

In order to facilitate the measurement and instrumentation, the MB roots of the maxillary first molars and the mesial roots of the mandibular first molars were resected using a Minitom (Struers, Denmark) at the furcation level. A #10 K-flex file or files (Maillefer, Ballaigues, Switzerland) were placed into the canal or canals of the resected roots, and periapical radiographs were taken in the buccolingual and the mesiodistal directions. Using these periapical radiographs, the number of canals was recorded and the canal type of each root was determined using the classification reported by Weine (1989). The working length of each root was calculated by placing a #10 file in the canals until it was visible at the apical foramen and subtracting one millimeter. All root canals were instrumented with 0.06 taper ProFile reamers (Maillefer, Ballaigues, Switzerland) to an apical size of 30 using a crown-down method. Each Profile was prepared at 300 r.p.m. using a 16:1 high torque handpiece (MICRO-MEGA, Besancon, France) powered by an electric motor(Nm uP-1500 motor, Nouvag Co., Switzerland). Irrigation was performed after each instrument procedure, using 2 ml of a 2.5% NaOCl solution.

In order to identify the main canals, a non-standard medium-sized gutta-percha cone (Meta Dental corp., Korea) was coated with Tubli-seal (Kerr corp., USA), and placed into the prepared canal without added pressure. The gutta-percha-filled roots were placed in an incubator for 7 days at 37°C to allow the sealer to set. The coronal one third of each root was then embedded in a self-cured acrylic resin (Jet acrylic resin, Lang Dental MFG. Co., USA). A Minitom (Struers, Denmark) was used to section each root at the 2, 3, 4, and 5mm level from the root apex, perpendicular to the long axis of the root. The resected surface of each root was stained with 2% methylene blue, rinsed in water, and dried with an air-syringe. The serial sections were arranged from the 2 mm level to the 5 mm level in a labeled slide glass. Only the apical sides of each section were examined at magnifications ranging from ×60 to ×300 using a Micro Hiscope System (Hirox Corp., Japan). The images were recorded digitally, and the cross-sectional canal configuration was examined using these photographs.

2. Classification of cross-sectional canal configuration

In the teeth with the two main canals, a further classification was performed as follows: A main canal was a canal with a gutta-percha cone. An isthmus was defined as a narrow extension from either one or two main canals. The isthmus was further classified as to whether it was complete or incomplete. The canal structure that was present separately from a main canal was regarded as an accessory canal. Accessory canals usually appear as relatively small round openings, but sometimes, they had a narrow extension. The accessory canals were found either between two main canals or between a main canal and the outer root surface. In the case of a difference in the location, a subclassification was carried out. Overall, six

categories were used to catalog the canal configuration in this study and could be classified as follows:

Type A	:	One canal or 2 canals merged into one (Fig. 1).
Type B	:	Two separated canals (Fig. 2).
Type C1	:	Two canals with one or more partial isthmuses (Fig. 3).
Type C2	:	Two canals with a complete isthmus (Fig. 4).
Type D1	:	Two canals with one or more accessory canals which are located between the main canals (Fig. 5).
Type D2	:	Two canals with one or more accessory canals which are located between a main canal and the outer root surface (Fig. 6).

In addition, the C1, C2, D1 and D2 configuration types in the roots with two canals were arbitrarily categorized in one category (Type S).

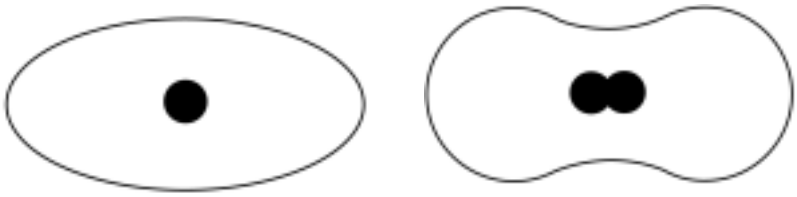

(a) (b)

Fig 1. Type A : One canal (a) or 2 canals merged into one (b).

Fig 2. Type B : Two separated canals without an isthmus or accessory canal.

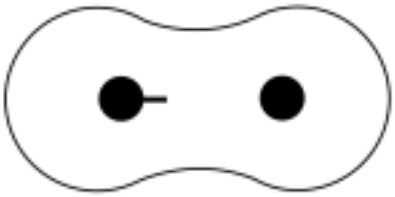

Fig 3. Type C1 : Two canals with one or more partial isthmuses between the main canals.

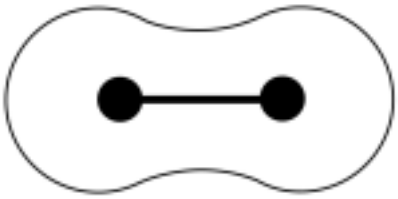

Fig 4. Type C2 : Two canals with a complete isthmus.

Fig 5. Type D1: Two canals with one or more accessory canals that are located between the main canals.

Fig 6. Type D2 : Two canals with one or more accessory canals that are located between a main canal and the outer root surface.

III. Results

Four MB roots of the maxillary first molars and two mesial roots of the mandibular first molars were excluded as a result of instrument separation or apical transportation during the instrumentation. Therefore, 47 of the 51 MB roots of the maxillary first molars and 42 of the 44 mesial roots of the mandibular first molars were used.

The radiographic data of the canal types in the maxillary and the mandibular molars used in this study are shown in Table 1. The incidence of two canals in the MB roots of the maxillary molars and the mesial roots of the mandibular molars was 80.8 % and 95.2 % respectively.

Table 1. Canal types in the mesiobuccal (MB) roots of the maxillary (Mx) first molars, and the mesial roots of the mandibular (Mn) first molars, as determined by the periapical radiographs.

Tooth root	One canal	Two canals		Total
		Type II	Type III	
MB roots of Mx first molar	9 (19.2%)	16 (34.0%)	22 (46.8%)	47 (100%)
Mesial roots of Mn first molar	2 (4.8%)	20 (47.6%)	20 (47.6%)	42 (100%)

Table 2 and 3 show the type of cross-sectional canal configurations at each level in both roots, respectively. The incidence of the Type S (sum of C1, C2, D1 and D2) configuration in the maxillary and the mandibular roots with two canals were highest at the 4 mm level from the apex (63.2%; 82.5%).

Table 2. The classification of the canal configuration types at each level in the MB root sections of the maxillary first molars with two canals.

Level from Apex (mm)	Canal Configuration Type (No. of roots)							
	A	B	C1	C2	D1	D2	S*	Total
2	10 (26.3)	8 (21.0)	6 (15.8)	5 (13.2)	5 (13.2)	4 (10.5)	20 (52.6)	38 (100)
3	9 (23.7)	9 (23.7)	4 (10.5)	9 (23.7)	4 (10.5)	3 (7.9)	20 (52.6)	38 (100)
4	7 (18.4)	7 (18.4)	2 (5.3)	13 (34.2)	5 (13.2)	4 (10.5)	24 (63.2)	38 (100)
5	12 (31.6)	9 (23.7)	1 (2.6)	14 (36.8)	2 (5.3)	0 (0)	17 (44.7)	38 (100)

S*: Sum of the number of roots with Type C1, C2, D1 and D2

The numbers in parenthesis are percentages.

Table 3. The classification of the canal configuration types at each level in the mesial root sections of the mandibular first molars with two canals.

Level from Apex (mm)	Canal Configuration Type (No. of roots)							
	A	B	C1	C2	D1	D2	S*	Total
2	10 (25.0)	6 (15.0)	5 (12.5)	10 (25.0)	9 (22.5)	0 (0)	24 (60.0)	40 (100)
3	5 (12.5)	4 (7.5)	8 (20.0)	14 (35.0)	10 (25.0)	0 (0)	32 (80.0)	40 (100)
4	1 (2.5)	6 (15.0)	9 (22.5)	17 (42.5)	7 (17.5)	0 (0)	33 (82.5)	40 (100)
5	1 (2.5)	11 (27.5)	6 (15.0)	15 (37.5)	6 (15.0)	1 (0)	28 (70.0)	40 (100)

S*: Sum of the number of roots with Type C1, C2, D1 and D2

The numbers in parenthesis are percentages.

Table 4 shows the incidence of the cross-sectional canal configuration according to the type of main canals. Generally, the incidence of the Type S classification was higher in the roots with a TypeIII canal than in those with a Type II. In the Type II canal, the incidence of the Type A classification was higher than that of the Type S classification, and the Type D1 classification was almost absent. In contrast, the incidence of the Type D1 classification in the Type III canal ranged from 9.0 to 22.7% in the maxillary molars and 25.0% to 45.0% in the mandibular molars.

Table 4. Incidence of the canal configuration types in the MB roots of the maxillary first molars and the mesial roots of the mandibular first molars according to the canal type.

Tooth Root	Canal Type	Level from Apex (mm)	Canal Configuration Type (%)							
			A	B	C1	C2	D1	D2	S*	Total
Mx MB Root	II	2	62.5	6.3	12.5	12.5	0	6.3	31.2	100
		3	56.3	12.5	6.3	18.7	0	6.3	31.2	100
		4	43.8	12.5	12.5	25.0	0	6.3	43.7	100
		5	56.3	6.3	0	37.5	0	0	37.4	100
	III	2	0	31.8	18.2	13.6	22.7	13.6	68.1	100
		3	0	31.8	13.6	27.3	18.2	9.0	68.2	100
		4	0	22.7	0	40.9	22.7	13.6	77.3	100
		5	13.6	36.4	4.5	36.4	9.0	0	50.0	100
Mn Mesial Root	II	2	50.0	5.0	15.0	30.0	0	0	45.0	100
		3	25.0	0	10.0	55.0	10.0	0	75.0	100
		4	5.0	10.0	15.0	65.0	5.0	0	85.0	100
		5	5.0	25.0	15.0	50.0	5.0	0	70.0	100
	III	2	0	25.0	10.0	50.0	45.0	0	75.0	100
		3	0	15.0	30.0	15.0	40.0	0	85.0	100
		4	0	20.0	30.0	20.0	30.0	0	80.0	100
		5	0	30.0	15.0	25.0	25.0	5.0	70.0	100

S*: Sum of the number of roots with Type C1, C2, D1 and D2

II & III : canal type of Weine classification

IV.Discussion

It is generally accepted that thorough knowledge of the anatomical variations on a resected root surface is essential for successful endodontic surgery.

Hsu and Kim (1997) suggested a classification method for canal isthmuses, which is meaningful for understanding the anatomy of a complex root canal system. However, it is believed that for endodontic surgery not only should the isthmus be examined thoroughly but a systematic examination of the other variable structures on the entire resected root surface is needed. The classification method of the cross-sectional canal configuration used in this study was based on the presence and the location of a main canal, an isthmus and an accessory canal. These structures are not different entities from each other because all these structures form part of the pulp canal system. For the practical application, however, these structures had been regarded as different ones and classified. Hsu and Kim (1997) classified all the canal structures present between two canals as isthmuses, while Tam and Yu (2002) differentiated accessory canals from isthmuses.

Clinically, it is more difficult to locate an accessory canal when the accessory canal is located at the lingual side to the lingual canal. Moreover, since the definition of an isthmus is a pulp canal present between two canals, a canal located outside a main canal cannot be classified as an isthmus. Therefore, this study separated and classified the accessory canal from the isthmuses for the convenience of clinical applications. In addition, the C1, C2, D1 and D2 configuration types in the roots with two canals were arbitrarily categorized in one (Type S) category because of its importance in surgical endodontics.

These results showed that the incidences of the Type S category in the mandibular molars were higher at all levels than those of the maxillary molars and the highest incidence in both

molars was 82.5% and 63.2%, respectively, at the 4mm level from the apex. This finding concurs with a previous study (Weller *et al.* , 1995), which showed that the incidence of isthmuses was highest at the 4mm level from the apex.

One of the intriguing features in this study was the incidence of the Type D2 classification. Although the incidence of the mandibular roots was quite low, the incidence of the maxillary roots ranged from 7.9% to 10.5% in the 2 to 4 mm level from the apex (Table 2). Furthermore, the accessory canals were mainly located at the lingual side of the MB_2 canals (Fig 7). Tam and Yu defined an accessory canal as one located between the main canals only, and did not report the presence of accessory canals outside the main canal (Tam and Yu, 2002). This difference might be due to the instrumentation of canals. If instrumentation was not performed, it might be difficult to determine which canal was a main canal. This might not allow certain cases to be classified as the Type D2 shown in this study.

Therefore, a thorough examination of the lingual side of the resected MB root surface during the surgical operation of the maxillary first molars is recommended.

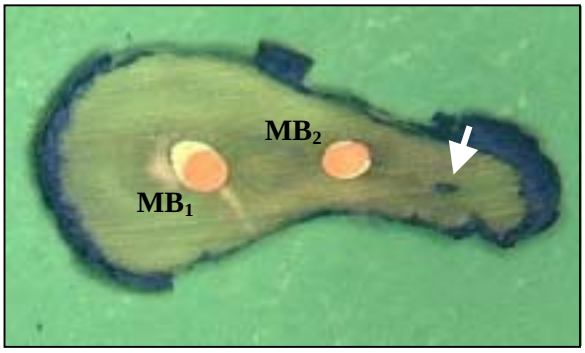

Fig 7. Accessory canal located in the palatal side to MB_2 canal (Type D2) was shown at the 4 mm level of the MB roots of maxillary first molars (arrowhead).

In addition, an interesting characteristic of the incidence of the Type A configuration (one canal) was observed on the cross-sectioned surfaces after instrumentation. Compared to the mesial roots of the mandibular molars with the Type II canals, the incidence was higher in the MB roots of the maxillary first molars (Table 4). This might be explained by the short distance between the MB_1 and the MB_2 canal and the incorporation into one of both canals by instrumentation.

However, in the Type III mesial roots of the mandibular first molars, there was no case of the Type A classification at the 2-5 mm level. At the 3 mm level, the incidence of the isthmuses and accessory canals was 85%. Therefore, incorporation between the mesiobuccal and mesiolingual canal should be considered in the cavity design of the root-end preparation during surgery on this type of root.

Weller *et al.* (1995) reported that in the MB roots of maxillary first molar, the range with partial isthmus (23.1 % to 88.0%) was higher than that of a complete isthmus (5.0% to 14.8%). However, this study showed the incidence of a partial isthmus to be relatively low, 26.0% to 15.8%, in the maxillary molars and 12.5% to 22.5% in the mandibular molars. These results may be the result of differences in the definition of the classification category of the partial isthmus in both studies. This study separated the Type C1 and Type D1, while Weller *et al.* defined the partial isthmus as an incomplete communication with one or more patent openings between two main canals. Therefore, the incidence of a partial isthmus (Type C1) found in this study might be low. However, even the sum of the incidence of the Type C1 and D1 categories was less than that of Weller's study. These differences can be attributed to the disappearance of the partial isthmus by the root canal instrumentation.

This study also showed that the types of the canal configurations were different at each level even in the same root. For example, when a Type B canal was found on a resected root

surface, the types of the 1 to 2mm upper level from the resected root surface were shown to be the C1, C2, and D1 types in many cases (Fig.8).

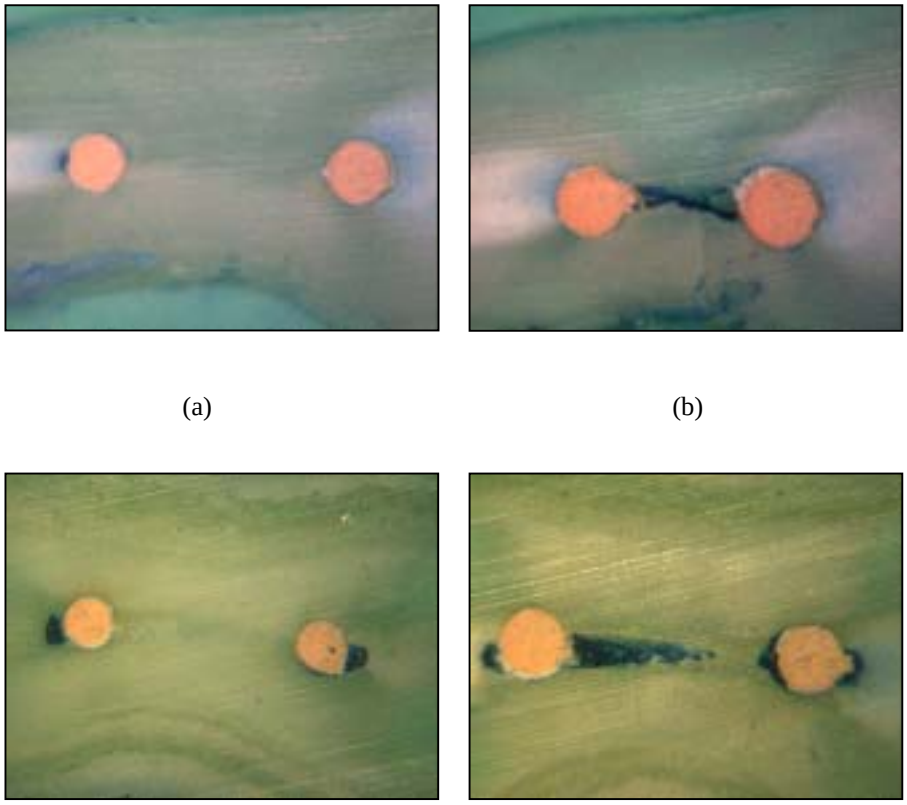

Fig 8. Type B was shown at the 2 mm level (upper, a) but the type of 2 mm upper level was Type C2 (complete isthmus) in the resected root surface of the mandibular molar (upper, b). In the maxillary molar, Type B was shown at the 2 mm level (lower, a) but Type C1 (partial isthmus) was found at the 4 mm level (lower, b).

This is in agreement with the findings reported by Weller *et al.* (1995), but differed from those reported by Tam and Yu (2002), where similar configurations at the sections of the 3, 4 and 5 mm level in the same root were reported. It is difficult to explain the difference, but differences in the methods or possible race-specific effects might be the cause.

Whether or not the configurations at the different levels in the same root are similar may be important to clinicians. If the configurations of the resected root surface are of either the Type C1, C2, D1, D2 and the cleaning and shaping are performed in the main canals only, some pulp tissues from the isthmuses or accessory canals, which may contain bacteria or irritating elements, may be remained over the resected dentin surface.

If these circumstances develop, bacteria and the other harmful irritants may gain access to the periradicular tissue via the resected and patent dentinal tubules. This may have an adverse effect the outcomes of endodontic surgery. Therefore, it is believed that clinicians should always consider these anatomical possibilities before a retrograde preparation.

In this study, the categories for classifying the canal configurations are arbitrary and may provide incomplete information. However, there is currently little information available as to standardizing the classification category. Further studies will be needed in order to standardize these experimental parameters.

Overall, this study demonstrated that the MB roots of the maxillary first molars and the mesial roots of the mandibular first molars with two canals had various canal configurations on the resected root surface at the selected cutting level from the apex. This information may be useful for practitioners during surgery on the permanent first molar.

References

Cambruzzi JV, Mashall FJ. : Molar endodontic surgery. *J Can Dent Assoc* 49 :61-65, 1983.

DuBrul EL.: Sicher's oral anatomy. 7th ed. 1980, pp. 256-259, 262-264, CV Mosby , St. Louis.

Hsu YY, Kim S. : The resected root surface : the issue of canal isthmuses. *Dent Clin North Am* 41:529-540, 1997.

Kim HJ, Lee KW. : Tooth anatomy. 1st ed. 1997, pp. 222-236, 245-258, Jisung, Seoul, Korea .

Rubinstein RA, Kim S. : Short-term observation of the results of endodontic surgery with the use of a surgical operation microscope and Super-EBA as root-end filling material. *J Endodon* 25:43-48, 1999.

Stephan Cohen, Richard C. Burns. : Pathways of the pulp. 8th ed. 2002, chap. 19, CV Mosby, St. Louis.

Tam A, Yu DC. : Location of canal isthmus and accessory canals in the mesiobuccal root of maxillary first permanent molars. *J Can Dent Assoc* 68 :28-33, 2000.

Weller RN, Niemczyk SP, Kim S. : Incidence and position of the canal isthmus. Part 1. Mesiobuccal root of the maxillary first molar. *J Endodon* 21:380-383, 1995.

Weine FS. : Endodontic therapy. 4th ed. 1989, Chap.6. CV Mosby, St. Louis.

국문요약

상,하악 제 1 대구치의 근관성형 후 협부와 부근관의 형태 및 빈도

연세대학교 대학원 치의학과

서명아

외과적 근관치료의 실패원인으로 절제된 치근면에 존재하는 협부 (Isthmus) 나 부근관 (accessory canal) 과 같은 해부학적 다양성에 대한 인지부족을 들 수 있다. 두개의 근관을 연결하고 있으며 치수 조직을 포함하고 있는 협부는 세정과 충전을 하기 힘든 부분이다. 이전의 연구들에서 발치된 상, 하악 대구치의 협부 및 부근관의 빈도를 제시한 바 있다. 그러나 근관성형이 협부와 부근관의 빈도 및 근관형태에 영향을 미칠 수 있어 근관성형 후 치근단면에 나타난 협부와 부근관의 빈도에 관하여 알아보는 것이 임상에 더 도움이 되리라 본다.

이에 본 연구는 2 개의 근관을 가지는 38 개의 상악 제 1 대구치 근심협측 치근과 40 개의 하악 제 1 대구치 근심 치근을 대상으로 엔진구동형 Ni-Ti 파일로 근관성형한 후 협부와 부근관의 형태 및 빈도를 알아보았다.

해당 치아의 치근을 치근분지부에서 잘라낸 후 #10 K-파일을 삽입하여 치근단 방사선 촬영 후 Weine 에 의한 근관의 type 을 결정하였다. 각 치근을 Profile 0.06 taper file 을 이용하여 Crown-down 방법으로 #30 까지 근관성형 (MAF #30) 하였다. 주근관을 구분짓기 위하여 성형된 근관내로 거타퍼차 콘을 위치시킨 후 저속형 다이아몬드 절삭기를 이용하여 근단부로부터 2mm 에서 1mm 간격으로 5mm 까지

절단하고 메틸렌블루로 각 절편의 치근단쪽을 염색하였다. 각 절편의 치근단쪽을 Stereomicroscope 을 이용하여 관찰하고 관찰된 단면상의 협부와 부근관을 포함한 단면모양의 유형을 분류한 후 빈도를 측정하였으며 그 결과는 다음과 같았다.

1. 두개의 근관을 가지는 상악 제 1 대구치의 근심협측 치근과 하악 제 1 대구치의 근심치근에서 협부와 부근관을 나타내는 경우의 빈도는 치근단으로부터 4mm 높이에서 각각 63.2%와 82.5%로 가장 높았다.
2. 상악과 하악 모두 Type III 근관에서 협부와 부근관의 빈도가 높게 나타났다.
3. 두개의 근관을 가지는 상악 제 1 대구치 근심협측 치근에서, MB_2 근관의 구개측에 존재하는 한 개 이상의 부근관이 치근단으로부터 2~4mm 높이에서 존재하였다. (Type II 근관 : 6.3%, Type III 근관 : 9~13.6%)
4. 두 개의 근관을 가지는 상악 제 1 대구치의 근심협측 치근과 하악 제 1 대구치의 근심치근의 단면에서 협부와 부근관을 포함하는 근관의 단면 모양이 각 높이마다 다양하게 나타남을 알 수 있었다.

이상의 연구에서 두 개의 근관을 가지는 상악 제 1 대구치의 근심협측 치근과 하악 제 1 대구치의 근심치근에서 근관성형 후에도 여전히 높은 빈도의 근관 협부와 부근관을 가짐을 알 수 있었다. 따라서 임상에서 외과적 근관치료시 성공적인 치료를 위해 절단된 치근단면의 면밀한 검사와 특히 하악 제 1 대구치의 근심치근이 Type III 근관을 가지는 경우, 치근단 와동 형성시 두 개의 근관을 와동형성에 포함시키는 것이 필요하리라 생각한다.

핵심되는 말 : 상악 제 1 대구치 근심협측 치근, 하악 제 1 대구치 근심 치근, 외과적 근관치료, 근관 협부, 부근관