# The effect of succinnylated atelocollagen and ablative fractional resurfacing laser on striae distensae

Jung U Shin

Department of Medicine

The Graduate School, Yonsei University

# The effect of succinnylated atelocollagen and ablative fractional resurfacing laser on striae distensae

Jung U Shin

Department of Medicine

The Graduate School, Yonsei University

# The effect of succinnylated atelocollagen and ablative fractional resurfacing laser on striae distensae

Directed by Professor Hwal Suh

The Master's Thesis
submitted to the Department of Medicine
the Graduate School of Yonsei University
in partial fulfillment of the requirements for the degree
of Master of Medical Science

Jung U Shin

June 2009

This certifies that the Master's Thesis
of Jin Young Jung is approved.

---

Thesis Supervisor : Hwal Suh

---

Thesis Committee Member: Kee Yang Chung

---

Thesis Committee Member: Dong Kyun Rah

The Graduate School
Yonsei University

June 2009

# ACKNOWLEDGEMENTS

I very much appreciate my thesis supervisor, professor Hwal Suh, for his supervision and encouragement to study this subject.

I also very appreciate professors Kee Yang Chung and Dong Kyun Rah who gave me experienced advice and warm support. I also thank Dr. Mi Ryung Roh and Jin Young Jung for great support and encouragement.

I am truly grateful to my family members, especially my parents and fiancé who have been by my side with love during the years of my study. I give my love and admiration to them. Thank you very much!

**TABLE OF CONTENTS**

ABSTRACTS ····· 1

I. INTRODUCTION ····· 3

II. PATIENTS AND METHODS

1. Patients ····· 6
2. Treatments ····· 6
3. Assessment of clinical effect ····· 8
4. Assessment of histological effect ····· 9
5. Statistical analysis ····· 9

III. RESULTS

1. Degree of clinical improvement ····· 10
2. Spectrophotometric analysis ····· 12
3. Histologic changes ····· 13
4. Complications ····· 19

IV. DISCUSSION ····· 20

V. CONCLUSION ····· 24

REFERENCES ····· 25

ABSTRACTS (IN KOREAN) ····· 28

# LIST OF FIGURES

Figure 1. Laser treatment area. (left: laser only, middle: laser + succinylated atelocollagen (or placebo), right: succinylated atelocollagen (or placebo) only) ·····7

Figure 2. Clinical improvement of SD. Before treatment (A, C, E, G, I), 1 month after treatment (B, D, F, H, J); using laser only(B), laser plus succinylated atelocollagen (D), succinylated atelocollagen only (F), laser plus placebo (H), placebo only (J) ·····11

Figure 3. Average of EI difference in each site. ·····12

Figure 4. Average of MI difference in each site. ·····13

Figure 5. Average of epidermal thickness, collagen and elastic fiber amount in normal and untreated SD. ·····14

Figure 6. H&E stain (x200). Normal (A), Untreated SD (B), Laser only (C), Laser + Succinylated ateloollagen (D), Succinylated atelocollagen only (E) ·····16

Figure 7. Masson trichrome stain (x200). Normal (A), Untreated SD (B), Laser only (C), Laser + Succinylated ateloollagen (D), Succinylated atelocollagen only (E) ·····17

Figure 8. Verhoeff-van Gieson stain (x200). Normal (A), Untreated SD (B), Laser only (C), Laser + Succinylated ateloollagen (D), Succinylated atelocollagen only (E) ·····18

# LIST OF TABLES

Table 1. Ingredients of succinylated atelocollagen and placebo solution. ·····7

ABSTRACT

The effect of succinnylated atelocollagen and ablative fractional resurfacing laser on striae distensae

Jung U Shin

*Department of Medicine*

*The Graduate school, Yonsei University*

*(Directed by Professor Hwal Suh)*

Striae distensae are a dermal atrophic scar with epidermal thinning and decreased collagen and elastic fiber. There is no “gold standard” treatment modality in the treatment of striae distensae. Collagen is a major extracellular matrix component and is important in wound healing. Ablative CO2 fractional laser is effective in various cutaneous scars. This study was attempted to evaluate the effect of succinnylated atelocollagen and ablative CO2 fractional laser in the treatment of striae distensae. Patients were divided into two groups and received 3

laser treatments at 4-week interval. Clinical improvement was evaluated by patients and two masked physicians by observing the comparative photographs using a 4-point scale. Skin biopsies were performed in randomly selected 6 patients before treatment and 4 weeks after the final treatment. Ablative fractional resurfacing laser was effective in clinical improvement of striae distensae. Statistically significant differences were partly observed between collagen treated group and placebo treated group. Clinical improvement scored by doctors showed more improvement in collagen group. However scoring by patients did not show significant differences in collagen and placebo treated group. In conclusion ablative fractional resurfacing laser is effective in the treatment of striae distensae and succinylated atelocollagen might improve the striae distensae, but the further research with large group of patients is needed.

---

Key words: ablative fractional laser, collagen, striae distensae

The effect of succinnylated atelocollagen and ablative fractional resurfacing laser on striae distensae

Jung U Shin

*Department of Medical engineering*

*The Graduate school, Yonsei University*

*(Directed by Professor Hwal Suh)*

## I. INTRODUCTION

Striae distensae (SD) are dermal scar with linear atrophic depression. SD are common and do not cause significant medical problem but may cause emotional stress at cosmetic aspects. They are usually located on the buttocks, thighs, knees, calves, and lumbosacral areas[1,2]. Many physiologic states, such as pregnancy, adrenocortical excess and changes in body habitus, as seen in rapid weight change are associated with SD, but the exact etiology is still controversial. Clinically, SD start as a linear pink lesion which evolve to

longer and wider red lesion and then become white atrophic scar. Histologically, in the early stage, there are dermal edema and perivascular lymphocytic cuffing[3] and in the later stage, there are epidermal atrophy and loss of rete ridges[4].

Several treatment modalities have been tried to improve SD, however most of treatments are associated with suboptimal outcomes. Weight gain can induce SD but weight loss does not ameliorate SD[5]. Topical tretinoin (0.1%) improves SD and the improvement may persist for almost a year after discontinuation of therapy[6]. Various laser treatments has been used in treating SD. The 585-nm pulsed dye laser has a moderate beneficial effect in the treatment of striae rubra[7]. The 308-nm excimer laser was effective in repigmentation of striae alba[8]. Intense pulsed light was also effective, and had minimal side effects[9]. Recently, Kim et al[10]. introduced a fractional photothermolysis as a useful treatment modality for the improvement of SD at clinical and histologic aspects. The other treatment modalities are 1,320nm Nd-YAG laser, 1,450-nm diode laser, radiofrequency, 585nm PDL, however none of these laser therapies are satisfied.

Traditional CO2 laser ablation shows significant clinical improvements, but post-treatment erythema last for weeks and significant complications such as infection, scarring or alteration in skin texture may occur. Ablative fractional

resurfacing laser is a novel approach for the treatment of scars, such as acne and surgical scars, as well as wrinkles[11]. According to the concept of fractional photothermolysis, these lasers deliver energy in a novel beam pattern and ablate only a fraction of the epidermis and dermis in the treatment area. An array of microscopic thermal zone is created ;adjacent to these areas, the epidermis and dermis are spared. Thereby, unlike conventional CO2 resurfacing laser technique, fractional CO2 laser is safer and healing is more rapid and recovery time is dramatically reduced. It has been proved to be effective for photoaging, periorbital wrinkling, acne scarring, melasma and pigmented lesions[12-14].

Collagen is a major component of extracellular matrix in dermis and is important in wound healing process[15]. Succinylated atelocollagen is non-immunogenic hydrophilic molecule modified to enhance skin penetration. We hypothesized that if we can deliver collagen through the microscopic thermal zone, SD may be treated more safely and effectively. To confirm the effectiveness of ablative fractional resurfacing laser and succinylated atelocollagen, we performed the double blind randomized controlled study on asian patients with SD.

## II. PATIENTS AND METHODS

### 1. Patients

Fourteen female participants (Fitzpatrick skin types III-IV) with moderate to severe atrophic striae alba were recruited. Exclusion criteria were history of keloid scarring, isotretinoin use, or nonablative laser procedures within 1 year of study initiation, ablative resurfacing procedures within 3 years of the study initiation, pregnancy, or who were taking immunosuppressive drugs and any other disease which can affect the wound healing process. The protocol and informed consent were approved by the Severance Hospital institutional review board. All participants were female.

### 2. Treatment

The patients were divided into two groups. One group applied succinylated atelocollagen(L-Lysin, sodium hyaluronate, succinylated atelocollagen) and the other group applied placebo(L-Lysin, sodium hyaluronate) (Table 1). Each patient had three treatment site, left site for only laser treatment, middle site for laser treatment and collagen or placebo apply, and right site for only collagen or placebo apply (Figure 1). Every site was 4 x 4 cm sized.

| Ingredients (gm/30ml) | Placebo | Collagen |
|---|---|---|
| Sodium hyaluronate | 0.12 | 0.12 |
| L-Lysine | 0.00006 | 0.00006 |
| Succinylated atelocollagen | - | 0.12 |

Table 1. Ingredients of succinylated atelocollagen and placebo solution.

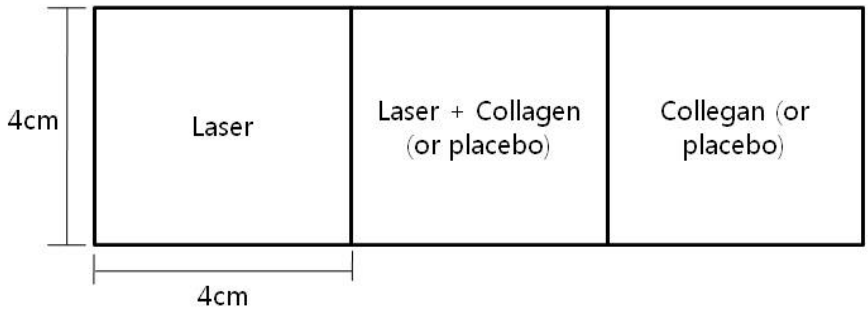


Figure 1. Laser treatment area. (left : laser only, middle : laser + succinylated atelocollagen (or placebo), right : succinylated atelocollagen (or placebo) only

Prior to ablative fractional resurfacing laser treatment, a topical anesthetic cream (EMLA®, Lidocaine and pilocaine, AstraZeneca, Wilmington, DE, USA) was applied under an occlusive dressing for 1 hour and subsequently washed off. SD on the left and middle site were treated with an ablative fractional resurfacing laser (eCO2$^{TM}$, Lutronic, Seoul, Korea) at pulse energy of 50mJ, spot density of 200spots/cm$^2$, using 12 mm x 12 mm scan area size in a static mode. After the laser treatment, the areas were cooled down with

ice packs for 10 minutes to protect spared epidermis. Patients were educated to apply collagen or placebo twice a day on the middle and right site and not to apply any other moisturizer on the treated site.

Each patient received laser therapy every 4 weeks for 3 times and followed up 4 weeks after the treatment.

In six volunteers, skin biopsies for histologic analysis were completed before treatment and 4 weeks after the final treatments.

### 3. Assessment of clinical effect

Therapeutic outcomes were assessed by digital photography and measurements of erythema index (EI) and melanin index (MI) at every visit. Digital photographs were obtained under identical camera settings (Canon 400D, Japan) and lighting condition at every visit. EI and MI of SD were measured by narrow-band reflectance spectrophotometry (DermaSpectrometer II®, Cortex Technology, Hadsund, Denmark) using 568-nm and 655-nm probe wavelengths. Clinical improvement was evaluated by patients and two blinded physicians by observing the comparative photographs and rating in 4-point score system (0 = no, 1 = 1%-25%, 2 = 26%-50%, 3 = 51%-75%, 4 = 76~100% improvement) at last visit. Complications were recorded at each visit.

## 4. Assessment of histologic change

Skin biopsies were performed in 6 volunteers before treatment and 4 weeks after the final treatment using a 2 mm biopsy punch. At the first visit, normal skin and untreated striae were obtained. The biopsy after treatment was performed right next to the previous biopsy site. Biopsy specimens (n=4 per patients at the initial, n=3 per patients at the final) were fixed in 10% formalin and embedded in paraffin. Each sections were stained with hematoxylin and eosin (H&E), Masson trichrome (for the analysis of collagen), and Verhoeff-van Gieson (for elastic fiber analysis). The images of each section were taken at a magnification x200 with a 12.5 megapixel digital camera (DP70, Olympus Optical Co., Tokyo, Japan) connected to a light microscope (BX40, Olympus Optical Co., Tokyo, Japan). The images were analyszed by MetaMorph (Molecular devices, Sunnyvale, California, USA).

## 5. Statistical analysis

Statistical analysis was performed using Wilcoxon signed rank test and Kruskal Wallis test for evaluation of EI, MI, histological change. GENMOD procedure was performed to evaluate clinical improvement scoring by two doctors. Wilcoxon rank sum test was used to evaluate clinical improvement by patient.

## III. RESULTS

Twelve of fourteen patients completed the 12-week study. One patient was lost due to psoriasis developed on the laser-irradiated site, and another patient was lost due to scar at the skin biopsied site.

### 1. Degree of clinical improvement

The clinical improvement scores evaluated by two doctors were analyzed by GENMOD procedure. There was significant difference between succinylated atelocollagen and placebo applied sites after laser irradiation (P=0.0284), and also between succinylated atelocollagen only and placebo only applied sites (P=0.0281). However, evaluation by patients showed no significant difference between LC group and LP group, and between C group and P group (P=0.5736, P=0.7798). Photograph of a representative subject who showed an excellent response can be seen in Figure 2.

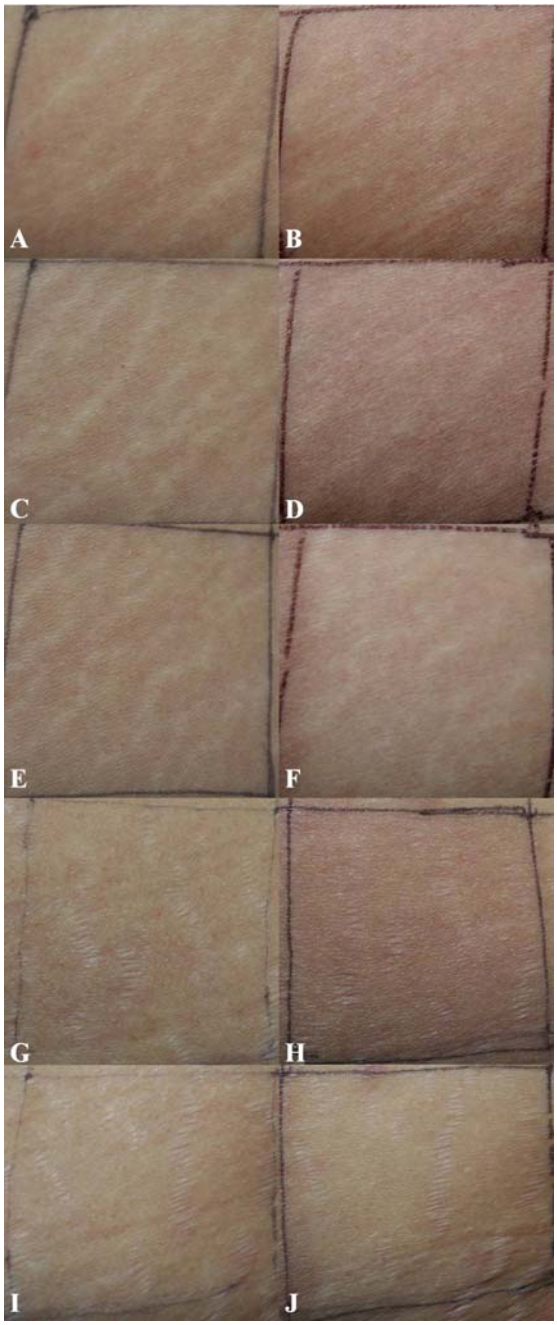


Figure 2. Clinical improvement of SD. Before treatment (A, C, E, G, I), 1 month after treatment

(B, D, F, H, J); using laser only(B), laser plus succinylated atelocollagen (D), succinylated atelocollagen only (F), laser plus placebo (H), placebo only (J)

## 2. Spectrophotometric analysis

Spectrophotometric analysis was carried out by measuring the EI and MI before and after the treatment. Both EI and MI were increased in laser irradiated sites and laser plus collagen or placebo treated sites (Figure 3 and 4). However, there was no significant difference between laser plus collagen treated sites and laser plus placebo treated sites (EI, P=0.3973; MI, P=0.5864)

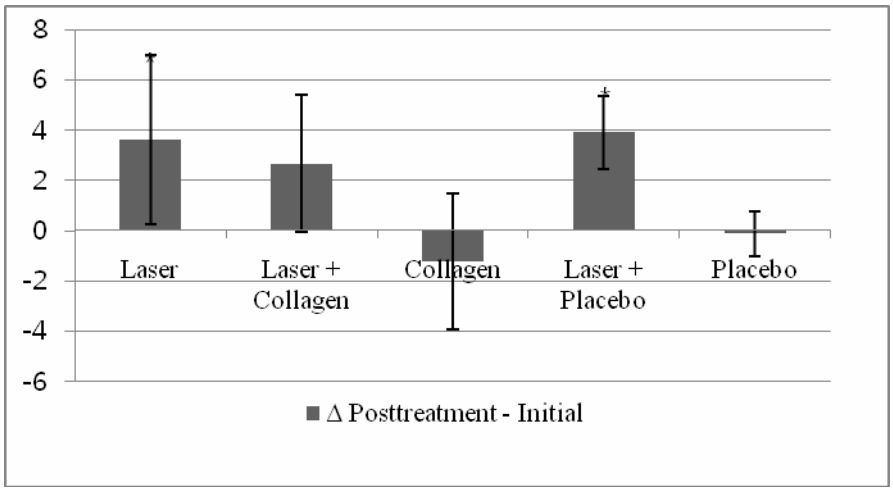


Figure 3. Average of EI difference in each site

.

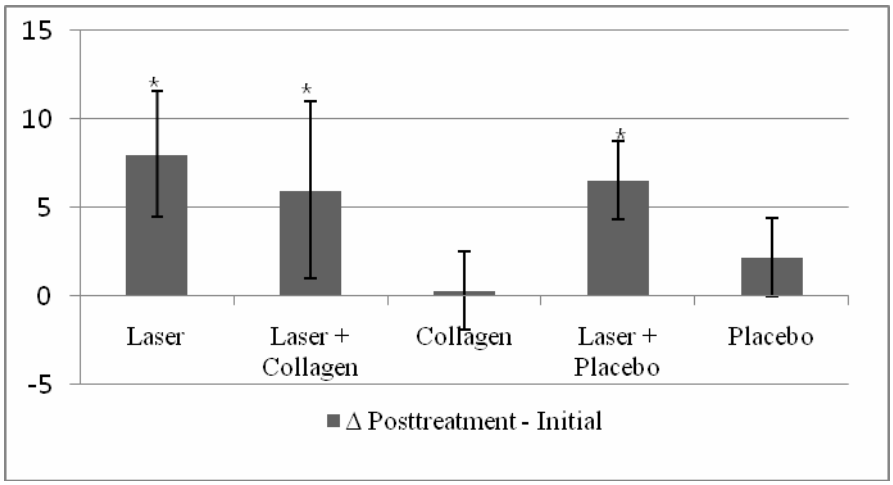


Figure 4. Average of MI difference in each site

## 3. Histologic changes

Prior to treatment, epidermal thickness, collagen and elastic fiber of untreated SD differed significantly from the epidermal thickness, collagen and elastic fiber amount of normal skin (Figure 5).

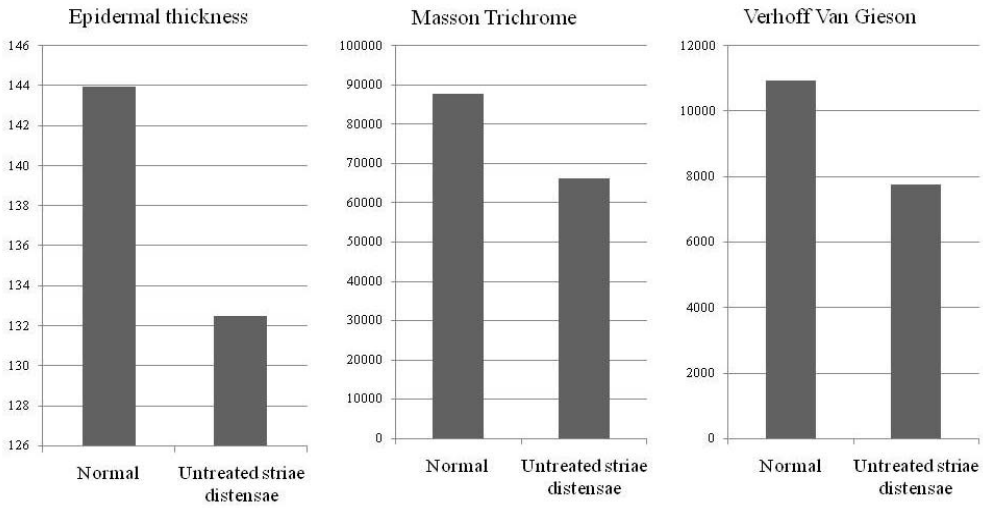


Figure 5. Average of epidermal thickness, collagen and elastic fiber amount in normal and untreated SD.

H&E stain showed epidermal thinning in untreated SD, with flattening of the rete ridges. 4 weeks after final treatment, laser-irradiated striae and succinylated atelocollagen treated after laser irradiation striae exhibited thickening of epidermis (Figure 6). Quantitative image analyses of pre- and post-treatment biopsies reveals that at 4 weeks following treatment, the epidermal thickness of each group had increased significantly compared with baseline ($P=<0.00238$, Bonferroni correction adjust p-value) but there was no difference between succinylated atelocollagen and placebo only treated sites, and between succinylated atelocollagen and placebo applied after laser irradiation sites ($P>0.00238$).

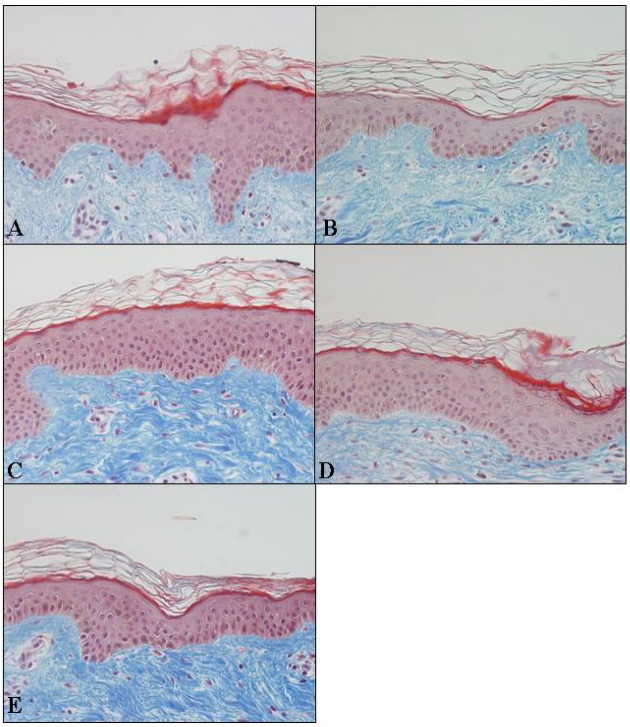


Figure 6. H&E stain (x200). Normal (A), Untreated SD (B), Laser only (C), Laser + Succinylated ateloollagen (D), Succinylated atelocollagen only (E)

The quantities of collagen fibers in the untreated SD were reduced compared with normal control at baseline, but increased 4 weeks after the final treatment in all groups (P=<0.00238, Bonferroni correction adjust p-value). However, there was no difference between succinylated atelocollagen and placebo only treated sites,, and between succinylated atelocollagen and placebo applied after laser irradiation sites (P>0.00238). (Figure 7)

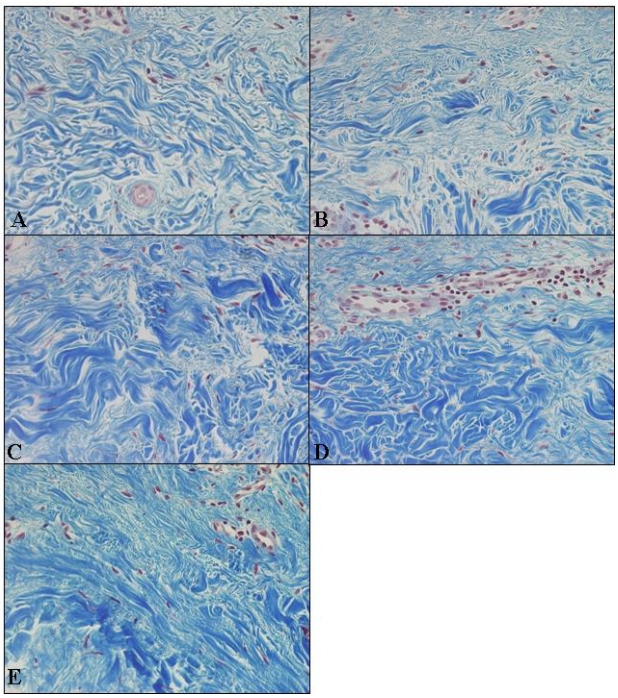


Figure 7. Masson trichrome stain (x200). Normal (A), Untreated SD (B), Laser only (C), Laser + Succinylated ateloollagen (D), Succinylated atelocollagen only (E)

The quantities of elastic fibers in the untreated SD were reduced compared with normal control at baseline, but increased 4 weeks after the final treatment in all groups (P=<0.00238, Bonferroni correction adjust p-value). There were significant statistical difference between succinylated atelocollagen and placebo only treated sites, and between succinylated atelocollagen and placebo applied after laser irradiation sites (P=<0.00238). (Figure 8)

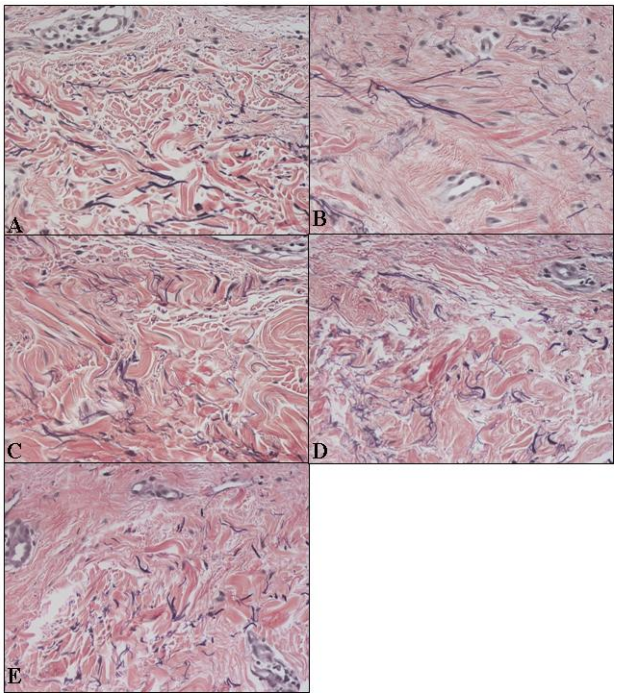


Figure 8. Verhoeff-van Gieson stain (x200). Normal (A), Untreated SD (B), Laser only (C), Laser + Succinylated ateloollagen (D), Succinylated atelocollagen only (E)

## 4. Complications

The treatments were well tolerated and most of complications were limited and transient. Posttreatment erythema observed in all patients and generally resolved within 2~3 days after treatment. The pruritus and postinflammatory hyperpigmentation occurred in 9 (75%) patients. One patient developed psoriasis due to Koebner phenomenon.

## IV. DISCUSSION

Striae distensae are considered as dermal scars associating with many physical states. It is very common and does not cause medical problem but may cause emotional stress in cosmetic aspects. Although numerous attempts have been made to improve SD, there is no “gold standard” treatment modality. Many topical therapies or laser and light devices have been tried to treat SD. Tretinoin is one of effective topical treatment modalities but suggested to use in active stage, before the scarring process is complete[21]. PDL is a most widely used laser therapy but effective only for the immature element of striae and not effective in darker skin.

Ablative fractional CO2 laser is a new modality which is more effective and has less side-effect profile than other laser device. It delivers microscopic columns of energy which vaporize tiny holes covering only a small percentage of the skin surface. The majority of the epidermis is left intact, allowing rapid healing and limited complications. This modality is currently used for treatment of photoaging, periorbital wrinkling, acne scarring, melasma and pigmented lesions[12-14]. There are a few published studies on SD and nonablative fractional photothermolysis. Geronumus et al.[19] reported evidence of new collagen formation and demonstrated an overall increase in

the density of collagen after fractional photothermolysis. This mechanism anticipate the effectiveness of fractional photothermolysis in SD. Recently Kim et al.[20] demonstrated increase in collagen and elastic fiber deposition and clinical improvement in SD after fractional photothermolysis. Fractional CO2 laser has similar laser irradiation system but in ablative mode. Therefore it is supposed to have effect in SD.

Succinylated atelocollagen solution was composed of sodium hyaluronate, L-lysine, succinylated atelocollagen and purified water. Collagen is a major component of extracellular matrix in the dermis and accelerate the wound healing process when used as a dressing material[16]. Hyaluronic acid is another major component of extracellular matrix and regulates cell behavior during embryonic development, healing processes, inflammation and tumor development[17-18]. Using collagen with hyaluronic acid is supposed to have synergistic effect that they accelerate the differentiation of fibroblast and increase the cell migration and proliferation when they used together. Succinylated atelocollagen molecule in this study is 300 nm x 2.4 nm sized. Removing telopeptide of collagen molecule reduce the size and immunogenicity and succinylation enhance the skin penetration of molecule. It is small enough to penetrate stratum corneum based on the evidence that smaller than 3 um sized solid particles can penetrate stratum corneum and

follicle[18]. Therefore, in theory succinylated atelocollagen molecule can penetrate skin and may improve SD which showing decreased collagen. Like other techniques that aid penetration particles, such as microneedles, iontophoresis and needleless jet injectors, ablative fractional laser was assumed to increase the penetration of collagen molecules.

This study was intended to investigate the efficacy of ablative fractional laser and succinylated atelocollagen in the treatment of SD. In this study, patients were treated three times (200 spots/cm2 at 50mJ) at 4-week inverval. Patients were randomly divided into two groups (collagen and placebo) and instructed to apply solution twice a day. The results showed that ablative fractional resurfacing laser was effective in the treatment in SD. EI and MI were increased after laser irradiation and histologic analysis showed epidermal thickening and increased collagen and elastic fiber. Increased erythema and pigmentation after treatment of striae alba might result from upregulated angiogenic activity or activation of melanocytes by a variety of growth factors induced during the wound healing process[22]. Because striae alba presents decreased erythema and pigmentation[20], increase of EI and MI can improve clinical appearance of SD.

Succinylated atelocollagen or placebo applied sites also showed epidermal thickening and increased collagen and elastic fiber. There was significant

difference between two sites in EI, MI, and quantities of elastic fiber however there was no significant difference in epidermal thickness and quantities of collagen fiber. In some data, succinylated atelocollagen treated site showed more significant epidermal thickening and more large increase in amount of collagen, but too small number of subjects (each group, n=3) might be a reason for no difference between two sites.

Analysis of clinical improvement score measured by two physicians showed more improvement in succinylated atelocollagen treated sites than placebo treated sites. We also tried to subjectively evaluate the clinical effect by patients but there was no significant difference between two sites. It can be explained by relatively objective scoring by two doctors who compared photographs to score the clinical effect.

Ablative fractional resurfacing laser therapy is safer than other ablative laser modalities, but it may result in transient erythema, edema and persistent scarring. One patient developed psoriasis at laser irradiated site and nine patients experienced pruritus and postinflammatory hyperpigmentation. Psoriasis lesions were thought to be developed by Koebner phenomenon. So it is critical to aware and recognize the possible complications and carefully take a history of any disease which may show Koebner phenomenon.

## V. CONCLUSION

Ablative fractional resurfacing laser was effective in clinical improvement of SD. Statistically significant differences were partly observed between succinylated atelocollagen treated sites and placebo treated sites. Clinical evaluation by doctors showed more improvement in succinylated atelocollagen treated sites. However scoring by patients did not show significant differences in succinylated atelocollagen and placebo treated sites.

Our study shows that ablative fractional laser is effective noninvasive treatment for SD and succinylated atelocollagen may improve SD, but the number of subjects were too small.

## REFERENCES

1. Cho S, Park ES, Lee DH, et al. Clinical features and risk factors for striae distensae In Korean adolescents. J Eur Acad Dermatol Venereol 2006;20: 1108-13.

2. Zheng P, Lavker RM, Kligman AM. Anatomy of striae. Br J Dermatol 1985;112:185-93.

3. Burrows NP, Lovell CR. Disorders of connective tissue. In: Burns T, Breathnach S, Cox N, Griffith C, editors. Rook's Textbook of dermatology, 7th edn. Oxford: Blackwell Science; 2004:46-7.

4. Watson RE, Parry EJ, Humphries JD, Jones CJ, Polson DW, Kielty CM, et al. Fibrillin microfibrils are reduced in skin exhibiting striae distensae. Br J Dermatol 1998;138:931-7.

5. Schwingel AC, Shimura Y, Nataka Y, Kazunori O, Tanaka K. Exercise and striae distensae in obese women. Med Sci Sports Exerc 2003;35:33.

6. Elson ML. Treatment of striae distensae with topical tretinoin. J Dermatol Surg Oncol 1990;16:267-70.

7. Jimeenez GP, Flores F, Berman B, Gunja-Smith Z. Treatment of striae rubra and striae alba with the 585 nm pulsed dye laser. Dermatol Surg 2003;29:362-5.

8. Alexiades-Armenakas MR, Bernstein LJ, Friedman PM, Geronemus RG.

The safety and efficacy of the 308 nm excimer laser in pigment correction of hypopigmented scars and striae alba. Arch Dermatol 2004;140:955-60.

9. Hernandez-Perez E, Colombo-Charrier E, Valencia-Ibiett E. Intense pulsed light in the treatment of striae distensae. Dermatol Surg 2002;28:1124-30.

10. Kim BJ, Lee DH, Kim MN, Song KY, Cho WI, Lee SK, Kim JY, Kwon OS. Fractional photothermolysis for the Treatment of Striae Distensae in Asian Skin. Am J Clin Dermatol 2008;9:33-7.

11. Gotkin RH, Sarnoff DS, Cannarozzo G, Sadick NS, Alexiades-Armenakas M. Ablative skin resurfacing with a novel microablative CO2 laser. J Drugs Dermatol. 2009;8:138-44.

12. Geronemus RG. Fractional photothermolysis: Current and future applications. Lasers Surg Med 2006;38:169–176.

13. Behroozan DS, Goldberg LH, Dai T, Friedman PM. Fractional photothermolysis for the treatment of poikiloderma of civatte. Dermatol Surg 2006;32:298–301.

14. Alster TS, Tanzi EL, Lazarus M. The use of fractional laser photothermolysis for the treatment of atrophic scars. Dermatol Surg 2007;33:295–9.

15. Mian M, Beghe F, Mian E. Collagen as a pharmacological approach in wound healing. Int J Tissue React 1992;14(suppl):1-9.

16. Greco RM, Iocono JA, Ehrlich HP. Hyaluronic acid stimulates human fibroblast proliferation within a collagen matrix. J Cell Physiol 1998;177:465–73.

17. Ruiz-Cardona L, Sanzgiri YD, Benedetti LM, Stella VJ, Topp EM. Application of benzyl hyaluronate membranes as potential wound dressings: evaluation of water vapor and gas permeabilities. Biomaterials 1996;17:1639–43.

17. Alexander SA, Donoff RB. The glycosaminoglycans of open wounds. J Surg Res 1980;29:422–9.

18. H. Schaefer, T.E. Redelmeier, in: Skin Barrier. Principles of Percutaneous Absorption, Karger, Basel, 1996;35–7.

19. Geronemus RG. Fractional photothermolysis: current and future applicaations. Laser Surg Med 2006;38:169-76.

20. Kim BJ, Lee DH, Km MN, et al. Fractional photothermolysis for the treatment of striae distensae in Asian skin. Am J Clin Dermatol 2008;9:33-7.

21. Garcia HL. Dermatological complications of obesity. Am J Clin Dermatol 2002;3:497-506.

22. Shishido E, Kadono S, Manaka I, et al. The mechanism of epidermal hyperpigmentation in dermatofibroma is associated with stem cell factor and hepatocyte growth factor expression. J Invest dermatol 2001;117:627-33.

ABSTRACTS (IN KOREAN)

# 팽창선조에 대한 숙신화 아테로콜라겐과 ablative fractional resurfacing laser의 효과

<지도교수 서활>

연세대학교 대학원 의학과

신정우

팽창선조는 표피의 위축과 진피의 콜라겐 및 탄력섬유의 감소를 보이는 진피의 흉터이다. 여러 가지 치료 방법이 시도되고 있지만 아직까지 가장 효과가 좋은 대표적인 치료방법은 제시되지 못하고 있다. 콜라겐은 결합조직을 구성하는 대표적인 물질로서 상처치유에 중요한 역할을 한다. Ablative CO2 fractional laser는 새로운 레이저 치료 방법으로 여러 가지 피부의 흉터를 완화시키는 데 효과가 있는 것으로 보고되고 있다. 본 연구에서는 숙신화 아테로콜라겐과 ablative fractional resurfacing laser의 팽창선조에 대한 효과를 보고자 하였다. 환자를 콜라겐 군과 플라시보 군, 두 군으로 나누어 치료를 진행하였으며 4주 간격으로 총 3회 치료하였다. 임상적 치료 효과는 두 명의 의사와 환자 본인이 4-point scale 을 이용하여 측정하였다. 무작위로 선정된 6명의 환자에서 치료 전과 치료 한달 후에 피부조직검사를 시행하였다. Ablative fractional CO2 laser 는 팽창선조의 임상적인 호전을 가져왔으며 콜라겐과 플라시보

군 사이에는 팽창선조에 대한 효과에 있어 일부 차이를 보였다. 의사가 판정한 임상적인 호전 정도는 콜라겐으로 치료한 군에서 더 크게 나타났으나 환자들이 측정한 결과는 콜라겐과 플라시보 군 사이에 차이가 없는 것으로 나타났다. 결론적으로 ablative fractional resurfacing laser 는 팽창선조의 치료에 효과적인 것을 볼 수 있었으며 콜라겐의 팽창선조에 대한 효과를 보기 위해서는 대규모 연구가 추가적으로 필요함을 알 수 있었다.

핵심되는 말 : ablative fractional laser, 콜라겐, 팽창선조