Evaluating Intra-and Inter-examiners Reproducibility in Histometric Measurement : The One-Wall Intrabony Periodontal Defects in Beagle Dogs

Soo Kyung Kim

The Graduate School

Yonsei University

Department of Dental Science

Evaluating Intra-and Inter-examiners Reproducibility in Histometric Measurement : The One-Wall Intrabony Periodontal Defects in Beagle Dogs

A Dissertation Thesis
Submitted to the Department of Dental Science,
the Graduate School of Yonsei University
in partial fulfillment of the
requirements for the degree of
Doctor of Philosophy of Dental Science

Soo Kyung Kim

June 2009

This certifies that the dissertation thesis
of Soo Kyung Kim is approved.

Thesis Supervisor : Chong-Kwan Kim

Jung-Kiu Chai

Seong-Ho Choi

Jooah Kim

Yun-Jung Yoo

The Graduate School

Yonsei University

June 2009

감사의 글

본 논문이 완성되기까지 부족한 저를 항상 격려해 주시고 사랑과 관심으로 이끌어 주신 지도교수 김 종관 교수님께 깊은 감사를 드립니다. 그리고 많은 조언과 따뜻한 관심으로 지켜봐 주신 채 중규 교수님, 조 규성 교수님, 최 성호 교수님, 김 창성 교수님께 진심으로 감사드립니다.

논문의 작성과 심사에 아낌없는 조언과 도움을 주신 김 주아 교수님, 유 윤정 교수님께도 진심으로 감사드립니다. 또한 연구 내내 많은 도움을 주신 의학통계학과 최 은희 선생님께 감사드립니다. 더불어 치주 과 교실 원 여러분, 특히 지금은 군의관으로 복무중인 이 중석 선생님과 레지던트 3년차 최 정유 선생님께 고마움을 전합니다.

늘 아낌없는 사랑과 헌신적인 도움으로 든든하고 따뜻한 버팀목이 되어준 사랑하는 남편 석영 씨와 나의 얼굴에 미소 짓게 만들고 오늘의 힘든 모든 생각들을 이겨내게 만드는 사랑하는 나의 두 딸 영진이와 예진이에게 진정으로 사랑과 고마움의 마음을 전합니다.

저를 이 세상에 존재하게 하여 주신 사랑하는 부모님과 항상 저에게 사랑과 관심을 보여주시는 모든 분께 진심으로 감사드립니다.

2009년 6월

저자 씀

Table of contents

List of Figures

List of Tables

Abstract

Evaluating Intra-and Inter-examiners Reproducibility in Histometric Measurement: The One-Wall Intrabony Periodontal Defects in Beagle Dogs

Soo-Kyung Kim, D.D.S., M.S.D

Department of Dental science, Graduate School, Yonsei University

(Directed by Prof. **Chong-Kwan Kim**, D.D.S., M.S.D., PhD.)

Background: Accurate and exact measurement is an important factor for a meaningful result for any properly designed study. Reliable and accurate measurements serve as the basis for evaluation in many scientific disciplines. Histometric assessments are used as part of the overall histopathologic evaluation. For periodontal regeneration protocol, the histometric evaluation is used to quantify the amount of regeneration of alveolar bone, cementum, a functionally oriented periodontal ligament, formation of a junctional epithelium and the position of any devices and biomaterial implanted in conjunction with the surgical procedure. One of the various measurement methods, histometric measurements are routinely used to evaluate biological events ascertained in histologic sections acquired from animal and human study. But, to get an expected study result, most examiners need to spend innumerable

time and effort. Therefore, if all the participating examiners are able to yield a similar result, it will be possible to evaluate the objective results of the study more easily and faster. The purpose of this study was to evaluate the intra and inter examiner reproducibility of histologic and histometric measurements in the intrabony periodontal defect model by the ICC and Overall concordance correlation coefficient (OCCC) as elaborated by Barnhart (Biometics 2002 58, 1020-7),

Methods: Twenty young adult (age 18 Month, body weight: 12-15 kg) beagle dogs were used. The mandibular first and third premolar teeth were surgically extracted prior to the experimental surgery in each animal. The experimental surgery included elevation of buccal and lingual mucoperiosteal flaps to surgically create one wall intra bony defects, "box type", critical size, (4×4×4 mm) at the distal aspect of the second and the medial aspect of the fourth mandibular premolars in the right and left jaw quadrants in each animal. Bilateral intra bony periodontal defects in each jaw quadrant either received: ß-TCP, GDF-0, GDF-100, and Sham-surgery. Histometric analysis using incandescent microscopy, an attached digital camera system, and a PC based image analysis system including a custom program that was performed on the slide of histologic sections acquired from animal study after 8 weeks performed on surgically created intrabony defects. Histometric parameters were recorded and repeated within three months interval by three examiners. Intra and inter examiner reproducibility was assessed using the ICC and the OCCC.

results: Most parameters of all the groups showed high intra and inter

examiner reproducibility. Parameters including defect height, bone regeneration height, cementum regeneration height, and formation of junctional epithelium yielded inter examiner correlation $\geqq$ 0.9. The intra examiner reproducibility showed a high result, over 0.9.

conclusions: Histometric evaluation in the one wall intra alveolar periodontal defect model showed high reproducibility not only in single examiner but also among the three examiners.

KEY WORDS: ICC, Overall concordance correlation coefficient (OCCC). Intra and inter examiner reproducibility. histometric measurements, one wall intra bony periodontal defect model.

Evaluating Intra-and Inter-examiners Reproducibility in Histometric Measurement: The One-Wall Intrabony Periodontal Defects in Beagle Dogs

Soo-Kyung Kim, D.D.S., M.S.D

Department of Dental science, Graduate School, Yonsei University
(Directed by Prof. **Chong-Kwan Kim**, D.D.S., M.S.D., PhD.)

Ⅰ. Introduction

Reliable and accurate measurements serve as the basis for evaluation in many scientific disciplines. Clinical measurements serve as a basis for record of variable parameters such as probing depth, clinical attachment level, comparisons of radiographic registration pre- to post therapy, and surgical procedures to assess changes in alveolar morphology.[1] Any of these methods may not be reliable in evidence of regeneration of the periodontal attachment. The inability of periodontal probing to assess the coronal level of connective tissue attachment has been amply demonstrated.[2,3,4] (Listgarten et al. 1976, Armitage et al. 1977, Van der Velden & de Vries 1978). In addition, radiographic analysis may not clearly detect cementum and periodontal

ligament. However, histologic evaluations may disclose the genuine nature of healing following periodontal regenerative procedures. Histometric assessments are used as part of the overall histopathologic evaluation. For periodontal regeneration protocol, the histometric evaluation is used to quantify the amount of regeneration of alveolar bone, cementum, a functionally oriented periodontal ligament, formation of a junctional epithelium, and the position of any devices and biomaterial implanted in conjunction with the surgical procedure.[5] For successful results, establishment of the purpose of study, proper study design, concrete surgical protocol & procedure and precise histometric analysis are very important factors, in particularly, the histometric analysis of the slides acts as the main barometer in evaluating the results. But, to get an expected study result, most examiners need to spend innumerable time and effort. Therefore, if all the participating examiners are able to yield a similar result, it will be possible to evaluate the objective results of the study more easily and faster.

Often, a reliability or a validity study involving multiple observers is conducted in clinical or experimental setting. In method comparison and reliability studies, it is often important to assess agreement between multiple measurements made by different methods, devices, laboratories, observers, or instruments. For continuous data, the concordance correlation coefficient (CCC) is a popular index for accessing agreement between multiple methods on the same subject.[6] If the outcome variable continuous,[7,8] Lin (1989, 1992) stated that the appropriate index for measuring agreement between two observers is the concordance correlation coefficient (CCC), Lin (1989) argued that, even though the agreement is often evaluated by using the Pearson Correlation Coefficient, the

paired t-test, the least square analysis of slope (=1) and intercept (=0), the coefficient of variation, or the intraclass correlation coefficient, non of these can fully assess the desired reproducibility characteristics.[9] Use of the CCC as measure of reproducibility has gained popularity in particle since its introduction by Lin (1989). However this agreement index is defined in the context of comparing two fixed observers. Because the reliability and validity studies often involve more than two observers, there is a need to access agreement among multiple observers. The Overall CCC[10] is presented by Barnhart (2002). The OCCC is adequate index to the inter observer variability for accessing agreement among multiple fixed observers.

The purpose of this study was to evaluate the intra-examiners and inter-three examiner reliability and/or reproducibility of histologic and histometric measurements in the one wall intrabony periodontal defects.

Ⅱ. Materials & Methods

A. Animals

Twenty young adult (age 15 Month, body weight: 12-15 kg) beagle dogs were used.

The animals had intact dentition with healthy periodontium. Animal selection, management, surgery protocol, and periodontal defect preparation followed routines approved by the local Institutional Animal Care and Use Committee, Yonsei Medical Center, Seoul, Korea. The animals were fed soft diets throughout the study to reduce chances of mechanical interference with healing during food intake.

B. Surgical Protocol

Surgical procedures were performed under the general anesthesia induced by IV injection of atropine (0.04mg/kg; Kwangmyung Pharmaceutical Ind. Co. Ltd., Seoul, Korea) and I.M injection of combination of xyline (Rompun, Bayer Korea Co., Seoul, Korea) and ketamin (Ketara, Yuhan Co., Seoul, Korea) followed by inhalation anesthesia (Gerolan, Choongwae Pharmaceutical Co., Seoul, Korea). Routine dental infiltration anesthesia was used at the surgical sites. During surgery, the animals received lactated Ringer's solution. (300-500 mL, IV)

The mandibular first and third premolar teeth were surgically extracted prior to the experimental surgery in each animal.[11] The extraction sockets were allowed to heal for two months. The residual dentition received oral prophylaxis in conjunction with the extractions.

C. Experimental Protocols

The experimental surgery included elevation of buccal and lingual mucoperiosteal flaps to surgically create one-wall intrabony defects, "box-type", critical size, (4×4×4mm) at the distal aspect of the second and the medial aspect of the fourth mandibular premolars in the right and left jaw quadrants in each animal. (Figure.1)[12] (Chang-Sung Kim 2004) Following root planning, a reference notch was made with a round bur on the root surface at the base of the defect[13]. Using a split design, unilateral defect in five animals were implanted with β- TCP, other five animals received to GDF-0; the other five animals treated with in GDF-100 and different five animals served as sharm surgery. Contra lateral side with in treatment reported as well. the mucoperiosteal flaps were advanced, adapted, and sutured using a resorbable suture material (Vicryl 5.0 Polylactin 910, Ethicon: John & Johnson).

Radiographs of the defect sites were taken at presurgery, immediately postsurgery and at the day of euthanasia.

D. Postsurgery Management

Postsurgery care included intramuscular injection of antibiotics (Cefazoline Sodium 20 mg/kg Yuhan corporation, seoul, Korea) and daily topical application of a 0.2% chlorhexidine solution (Hexamedine®, Bukwang Pharmaceutical Co., Seoul, Korea) for infection control.[14] Observations of the experimental sites with regard to gingival health, maintenance of the suture line closure, edema, and evidence of tissue necrosis or infection were made daily until suture removal, and at a least twice weekly thereafter.

E. Histological Procedures

The animals were euthanized at 8 weeks postsurgery using an overdose of pento barbital (90-120 mg/kg: IV). Block sections including the defect sites along with the surrounding alveolar bone and mucosal tissues were collected. The block specimens were rinsed in sterile saline and were immersed in 10 % neutral buffed formalin at a volume 10 times that of the block section for 10 days. After rinsing in sterile water, the sections were decalcified in 5 % formalic acid for 14 days, trimmed, dehydrated in a graded ethanol series, and embedded in paraffin. Step-serial section of 5 μm thick were cut in a mesial-distal vertical plane at an 80 μm intervals.[15] The sections were stained using hematoxyline/eosine stains. The three most central sections of each defect site selected based on the width of the root canal were used for the

histological and histometric analysis.

F. Histometric measurement protocols for Intra-and inter-examiner reproducibility.

1) Selection of examiners: The three periodontists who worked more than three years and have experience more than one year on histometric analysis were chosen.

2) Training of examiners: The examiners were trained to assess four parameters of surgically created defects from professional histologist about three months.

Also, this examiner performed two separate repeated histometric evaluations three months apart. An one-wall periodontal defect was surgically created in mesial aspect of mandibular fourth premolar and in the distal aspect of second premolar in intra-alveolar periodontal defects presented in 2004 (Chang-Sung Kim 2004).[12]

3) Histometric analysis

The three examiners (KSK, KTG, LJS) independently performed the histometric analysis using incandescent microscopy (BX 60, Olympus America Inc., Melville, NY, USA), a microscope digital camera system (DP 10, Olympus America) and a PC-based image analysis system (Image-pro plus^{TM}, Media Cybernetic, Silver Spring, MD, USA) customized for the intra-alveolar

periodontal defect models[16]

The following parameters were recorded for buccal and the lingual tooth surfaces for each section: (Figure 2)

① Defect height: distance from the apical extension of the root surface notch to the cemento-enamel junction.

② Bone regeneration (height): distance from the apical extension of the root surface notch to the coronal extension of newly formed bone along the root surface.

③ Cementum regeneration(height): distance from the apical extension of the root surface notch to the coronal extension of newly formed cementum or a cemetum like substance on the root surface.

④ Epithelial attachment: distance from the cemento-enamel junction to the apical extension of an epithelial attachment on the root surface. This parameter includes gingival recession.

4) The measurement of the inter-examiner reproducibility:

The measurement value of histometric parameters were recorded and repeated within three months interval by three examiners. The blind datas of three examiners were collected and the intra-examiner reproducibility and inter-examiner reproducibility were assessed by the ICC and OCCC[10] (Barnhart HX, Haber M, Song J, 2002)

G. Statistical Analysis

Blind data was collected from three examiner and this was taken into consideration in the analysis. Standard errors of mean were adjusted for the correlation. The SAS 9.1 Ver. (SAS Inc., North Carolina) was used for the statistical analysis for differences between experimental conditions using one-way analysis of variance and Pearson correlation coefficient. The statistical method was used for Intra class correlation coefficient to identify intra-examiner reproducibility.[17,18] Then, two examiners were paired and interclass correlation coefficient (ICC) was found to evaluate the inter-three examiner reproducibility. And inter-examiner reliability were assessed by the OCCC

* Intraclass correlation coefficient(ICC)

-An index to observe reproducibility within the examiner.

:an index to see the reproducibility of which an examiner had measured several times, it can be expressed as the coefficient value.

* Interclass correlation coefficient

-An index to observe the reproducibility between the examiners.

:an index to identify the reproducibility between the examiners, the Pearson correlation coefficient can be used so that it is expressed as the value of two paired examiners.

* Overall concordance correlation coefficient

- An index to observe the reproducibility among multiple examiners.

:an index to inter observer variability for accessing agreement among multiple fixed observers. The OCCC is the weighted average of all pairwise CCCs.

Ⅲ. Results

A. Clinical Observations

All of the surgical sites appeared as healthy gingival conditions (Figure 1) exception for one coronal site exhibiting gingival inflammation. There was no specific clinical characteristic when compared to the non-surgical site.

B. Histological observations

The defect sites are available for analysis with the exception for one root in a control site that was lost in the histotechnical preparation. Generally, the barrier device was located near the CEJ and the epithelium arrested at the CEJ. Two animals exhibited an inflammatory infiltrate, partially involved in the defect site, localized to the buccal and/or distal root of the premolar teeth in sites receiving sham surgery. These animals also exhibited sites without an inflammatory infiltrate. The histologic evaluation revealed limited inflammatory cell infiltration in the defect sites. The junctional epithelium appeared to extend more apically in the treated sites compared to the control site. New bone was observed in the treated sites. All defect sites maintained a periodontal ligament space. The new cementum appeared thicker at the notch area, becoming thinner coronally. None of the specimens exhibited ankylosis. Limited root resorption was observed in most of the defect sites.

C. Histometric Analysis

The intra-examiner histometric records showed high reproducibility for most parameters. There were no statistically significant differences in bone formation among the treatments. Measurement of defect height, bone regeneration height, cementum regeneration height, epithithelial attachment height expressed an ICCs. The intra examiner reproducibility resulted very high. ICCs are greater than or equal to 0.99 to assessment of defect height, bone height, cementum, and epithelium. Mean histometric recordings for individual measurement score and overall group means (± SD) are shown in Table 1 and 3. The reproducibility of three examiners are expressed as different measurement values to each group(β-TCP, GDF 0, GDF 100, Sham), but most of the measurement values showed high reproducibility. P-values are over 0.05 and inter examiner ICCs are over than or equal to 0.95, and OCCC were revealed high results ($\geqq$0.9) even though sharm group are relatively lower than other group. The reproducibility value of histometric measurement for three examiners and overall group means (± SD) are shown in Table 2 and 3, 4. Upon initial review, it was decided that the histometric evaluation should only include the three most central sections since the histologic observations showed that the healing events were closely repeated among the four central sections. This is not expected to alter the outcomes of the histometric evaluation as shown by Koo et al. (2005). As for the qualitative analysis, a few experimental sites showing pulp exposure or unresorbed suture knot with minor inflammation were excluded from the histometric analysis. Similarly, a few sites exhibiting residual old cementum were excluded.

1) Intra-examiner Reproducibility

Table 1. Intraclass correlation coefficient of KSK

Material scale	CEJ to Notch	Bone Height	Cementum	Epithelium
β-TCP (n=19)	0.997	1.000	0.998	1.000
GDF 0 (n=30)	0.999	0.998	1.000	1.000
GDF100 (n=27)	0.995	0.997	0.983	0.974
Sharm (n=21)	0.999	0.999	1.000	0.995

2) Inter-examiners reproducibility by ICC

Table 2. Reproducibility between each two examiners: two examiners were paired and interclass correlation coefficient were found to evaluate the inter three examiners reliability.

	CEJ to Notch	**Bone Height**	**Cementum**	**Epithelium**
β-TCP(n=19)				
A : B	0.90314 p≦.0001	0.98231 p≦.0001	0.97423 p≦.0001	0.97368 p≦.0001
A : C	0.79973 p≦.0001	0.96529 p≦.0001	0.97637p≦.0001	0.93707 p≦.0001
B : C	0.87262 p≦.0001	0.96907 p≦.0001	0.98627 p≦.0001	0.96641 p≦.0001
GDF 0(n=30)				
A : B	0.96327 p≦.0001	0.98031 p≦.0001	0.99283 p≦0.0001	0.97423 p≦.0001
A : C	0.96500 p≦.0001	0.97937 p≦.0001	0.97295 p≦0.0001	0.97312 p≦.0001
B : C	0.93696 p≦.0001	0.97916 p≦0.0001	0.97097 p≦0.0001	0.95355 p≦.0001
GDF100(n=27)				
A : B	0.98372 p≦.0001	0.97055 p≦.0001	0.97437 p≦.0001	0.97702 p≦.0001
A : C	0.96023 p≦.0001	0.95653 p≦.0001	0.97784 p≦.0001	0.98893 p≦.0001
B : C	0.96866 p≦.0001	0.97916 p≦.0001	0.97097 p≦.0001	0.97212 p≦.0001
SHAM(n=21)				
A : B	0.96021 p≦.0001	0.98523 p≦.0001	0.83542 p=0.0572	0.87529 p≦.0001
A : C	0.96021 p≦.0001	0.98841 p≦.0001	0.81162 p=0.0637	0.93153 p≦.0001
B : C	0.96569 p≦.0001	0.98794 p≦.0001	0.97239 p≦.0001	0.86304 p≦.0001

*****Examiner **: A: KSK. B: LJS. C: KTG**

Table 3. Reproducibility among three examiners : used the ICC measurement for reliability.

	Inter-examiners correlation	Intra-examiner correlation
β-TCP(n=19)		
CEJ to Notch	0.951(p≦.0001)	0.997(p≦.0001)
Bone Height	0.968(p≦.0001)	1.000(p≦.0001)
Cementum	0.975(p≦.0001)	0.998(p≦.0001)
Epithelium	0.953(p≦.0001)	1.000(p≦.0001)
GDF 0(n=30)		
CEJ to Notch	0.956(p≦.0001)	0.999(p≦.0001)
Bone Height	0.967(p≦.0001)	0.998(p≦.0001)
Cementum	0.976(p≦.0001)	1.000(p≦.0001)
Epithelium	0.962(p≦.0001)	1.000(p≦.0001)
GDF 100(n=27)		
CEJ to Notch	0.971(p≦.0001)	0.995(p≦.0001)
Bone Height	0.955(p≦.0001)	0.997(p≦.0001)
Cementum	0.971(p≦.0001)	0.983(p≦.0001)
Epithelium	0.969(p≦.0001)	0.974(p≦.0001)
Sham(n=21)		
CEJ to Notch	0.953(p≦.0001)	0.999(p≦.0001
Bone Height	0.984(p≦.0001)	0.999(p≦.0001)
Cementum	0.896(p≦.0001)	1.000(p≦.0001)
Epithelium	0.877(p≦.0001)	0.995(p≦.0001)

3) Inter-and Intra examiner reproducibility by OCCC

Table 4. reproducibility among three examiners : assessed by OCCC

	Overall Concordance Correlation Coefficient
CEJ to Notch	0.909299
Bone Regeneration Height	0.958204
Cementum Regeneration Height	0.951817
Epithelium	0.94868

Ⅳ. Discussion

The objective of this study was to evaluate the intra examiner (KSK) and inter three examiners (KSK, LJS, KTG) reliability and/or reproducibility of histologic and histometric measurements in the one wall intrabony periodontal defects.

For periodontal regeneration protocol, the histometric evaluation is used to quantify the amount of regeneration of alveolar bone, cementum, a functionally oriented periodontal ligament, formation of a junctional epithelium, and the position of any devices and biomaterial implanted in conjunction with the surgical procedure.[5] So the assessment of reproducibility is essential element for histometric measurement of any study to evaluate the bone regenerative effect of recombinent human bone. It is well accepted that repeated measures could increase reliability and reduced and examiner or technique error.

Before using the measurement scale in practice, one often needs to assess agreement of multiple observers taken by several methods. If there is observed disagreement, one often wants to know whether the disagreement is due to random error within a method or due to true differences attributed by the different methods. If the disagreement is due to the random error within a particular method, this method may not be used in practice. If disagreement is due to the true difference among the methods, the methods will need to be modified for improvement. Therefore, assessing agreement often leads to assessing both intra-method agreement and inter-method agreement, where intra-method agreement measure consistency of reading taken by the same

method and the inter-method agreement measures consistency of true readings attributed by the methods.[19]

Issues related to reliable and accurate measurement have involved over many decades, dating back to the nineteenth century and the pioneering work of Galton (1886), Pearson (1896, 1899, 1901), and Fisher (1925).[20] The popular agreement indices based on the observed reading such as concordance correlation coefficient (CCC) (Lin, 1989) or different versions of intra-class correlation coefficient (ICC) (Shrout and Fleiss, 1979) are in fact the measure of total agreement although they are often reported as inter-method agreement.[19] As elaborated by Lin (1989), the concordance correlation coefficient (CCC)[26] is more appropriate than other indices for measuring agreement when the variable of interest is consecutive.[9] However, this agreement index is defined in the context of comparing two fixed observers.[22] In order to use multiple observers in a study involving large numbers of subject, there is a need to assess agreement among these multiple observers. The overall CCC in terms of the interobserver variability for assessing agreement among multiple fixed observers are presented by Barnhart HX, Haber M, Song J. The OCCC of the interobserver variability for accessing agreement among multiple fixed observers. The OCCC offers the following important points. First, it addresses the precision and accuracy indices as components of the OCCC. Second, the OCCC is the weighted average of all pairwise CCCs.[10] In this study of repeated measurements, the class variable was the examiner. Multiple examiners can be trained at different times to measure histomatric characteristics with good to excellent intra examiner reliability.[23] The measurement errors of histometric assessments, made by one or two examiners,

in the critical size, intra alveolar periodontal defect model was evaluated.[24] For repeated measurements made by the same examiner, histometric parameters yielded ICCs greater than or equal to 0.97. This suggest that the single examiner had excellent reproducibility in assessing most of the histometric parameters evaluated.

When measurements made by three independent examiners were evaluated, the all parameters assessed yield interclass correlation coefficients greater than or equal to 0.95, and over 0.9 (OCCC) also suggesting excellent consistency. The correlations were somewhat higher in repeated measurements made by one examiner compared to the measurements made by three examiners, and this was consistent for all the studied parameters. This finding is in accordance with other studies showing higher intra examiner than inter examiner reproducibility of repeated measurements of clinical periodontal parameters[24]

The goal of periodontal treatment is the regeneration of periodontal attachment including the formation of new cementum, functionally oriented periodontal ligament, and alveolar bone on a root surface previously exposed to periodontitis. To achieve this goal, various protocols have been proposed. Treatment outcomes for periodontal defects were influenced by several factors, bacterial contamination, innate wound healing potential, site characteristic, and surgical procedure. Among this factors, evidence suggests that the healing potential of intra bony lesions is primarily dependent on the defect morphology as expressed by the number of associated bone walls. So, we used the surgically created intra bony box-type (4×4×4mm) periodontal defect model presented by Chang-Sung Kim in 2004 in this study.[12] Many of these outcomes are continuous scale variables and the more importance of these

include defect height and area, and newly formed alveolar bone, height and area.[25] Histometric analysis of the latter variables are formed regularly in studies of novel periodontal and implant therapies. This study showed that, when a single examiner performed the measurement of these parameters, 1% ~ 6% of the total variation was due to the examiners' random measurement error. Furthermore, a measurement error component of about 1-17% of the total variation was due to the differences among the examiners. This suggests that assessments made by one examiner is quite adequate for analyzing the data. Other study outcomes examined in this model demonstrated a range of measurement reproducibilities,[26] some variables showing higher measuring consistency than the others. Thus, measurement of newly regenerated bone and density of biomaterial exhibited the highest level of measurement errors. The estimated error component was 23- 34% for single examiner and 27- 40% for two examiners. On the other hand, measurement of junctional epithelium and ankylosis showed low intra examiner measurement errors, but a higher inter examiner error component ranging from 23-27%. For some of the histometric variables, the measurement errors may have been attenuated by the skewness of the variables, since some specimens did not reveal presence of the outcome variable being assessed. This was particularly evident for the measurement of cementum regeneration, which was scored as absent in a high percentage of the specimens. For this reason, the consistency of measuring cementum regeneration in this study material was not assessable.

Ⅴ. Conclusion

This study has determined that, Histometric evaluations in the one- wall intra alveolar defects yield high reproducible results on inter-examiners but also on intra-examiner. Even though, the study was properly designed, concrete surgical protocol and procedure, the precise histometric analysis was beneficial to evaluate the result of the objective study easier and faster. Especially for the single examiner performing the histometric measurements, this apply even when the examiner had received limited training. What's more, the use of analysis rules may help to increase reproducibility among and within examiner groups.

Consequently, the participating examiners are able to yield a similar result, it will be possible to evaluate the objective results of the study more easier and faster.

References

1. Ki-Tae Koo, Giuseppe Polimeni, Jasim M. Albandar and Ulh M. E. Wikesjö Periodontal repair in dogs: examiner reproducibility in the supra alveolar periodontal defect model. J Clin Periodontol 2004; 31: 439-442.

2. Listgarten, M. Periodontal probing and relationship of the probe tip to periodontal tissue. J periodontol 1976; 47: 511-513.

3. Armitage, G.C., Svanberg, G.K. & Løe, H. Microscopic evaluation of clinical measurements of connective tissue attachments levels. J Clin Periodontol 1997; 4: 173-190

4. Van der Velden, U. & de Vries, J. H. Introduction of a new peridontal probe: the press probe. J Clin Periodontol 1987; 5: 188-197

5. Koo, K.-T, Polimeni, G., Qahash, M., Kim, C. K. & Wikesjö, U. M. E. Periodontal repair in dogs: guided tissue regeneration associated with a coral calcium carbonate implant. J Clin Periodontol 2005; 32: 104-110

6. Barnhart HX, Lokhnygina Y, Kosinski AS, Haber M. Comparison of concordance correlation coefficient and coefficient of individual agreement in assessing agreement. Biopharm Stat. 2007; 17(4): 721-738

7. Lin, LX. A concordance correlation coefficient to evaluate reproducibility. Biometrics 1989; 45: 255-268.

8. Lin, LX. Assay validation using the concordance correlation coefficient. Biometrics 1992; 48: 599-604

9. Liao JJ, Lewis JW. A note on the concordance correlation coefficient. PDA J Pharm Sci Technol 2000; 54: 23-26

10. Banhart HX, Haber M, Song J. Overall concordance correlation coefficient for evaluating agreement among multiple observers. J Biometrics 2002 Dec; 58(4): 1020-1027

11. Wikesjö, U. M. E., kean, C. J. C. & Zimmerman, G. J. Periodontal repair in dogs: supraalveolar defect models for evaluation of safety and efficacy of periodontal reconstruction therapy. J periodontol 1994; 5: 1151-1157

12. Chang-Sung Kim. Periodontal Repair in surgically Created Intra bony Defects in Dog: Influence of the Number of Bone Walls on Healing Response. J Periodontol 2004; 75: 229-235.

13. Kim HY, Kim CS, Jhon GJ, The effect of safflower seed extract on periodontal healing of 1-wall intrabony defects in beagle dogs. J Periodontol 2002 Dec; 73 (12): 1457-1466

14. Wikesjö, U. M. E., Hargen, K. & Nielsen, D. D. Periodontal repair in dogs: effect of saliva contamination of the root surface. J Periodontol 1990; 61: 559-563

15. Wikesjö UM, Lim WH, Razi SS, Sigurdsson TJ, Lee MB, Tatakis DN, Hardwick WR. Periodontal repair in dogs: a bioabsorbable calcium carbonate coral implant enhances space provision for alveolar bone regeneration in conjunction with guided tissue regeneration. J Periodontol. 2003 Jul; 74(7): 957-964.

16. Wikesjö, U. M. E. & Nilveůs, R. Peridontal of repair in dogs: effect of wound stabilization on healing. J Periodontol 1990; 61, 719-714

17. Shrout, P. E & Fleiss, J. L. Intraclass correlations: use in assessing rater reliability. Psychol Bull 1979 Mar; 86: 420-428.

18. Jomha NM, Anoop PC, Elliott JA, Bagnall K, McGann LE. Validation and reproducibility of computerised cell-viability analysis of tissue slices. BMC Musculoskelet Disord. 2003 Mar; 21: 4-5.

19. Huiman X, Barnhart, Jingli Song, Michael J. Haber. Assessing Intra, Inter and Total agreement With Replicated Readings. Stat Med. 2005; 15: 1371-1384

20. Barnhart HX, Haber MJ, Lin LX. An overview on assessing agreement with continuous measurement. J Biopharm 2007; 17(4): 529-569

21. Lin LI. A concordance correlation coefficient to evaluate reproducibility. J Biometrics. 1989; 45: 225-268

22. Shaoi J, Zhong B. Assessing the agreement between two quantitative assays with repeated measurements. J Biopharm Stat. 2004; Feb; 14(1): 201-212

23. Shultz SJ, Nguyen AD, Windiey TC, Kuias AS, Botic TL, Beynnon BD. Intratester and intertester reliability of clinical measures of lower extrimity anatomic characteristics: implications for multicenter studies. Clin J Sport Med. 2006 Mar; 16: 155-161

24. Kingman, A. & Albandar, J. M Methodological aspects of epidemiological studies of periodontal diseases. J Periodontol 2002; 29: 11-30

25. Zeger, S. L. and Liang, K.Y.. Longitudinal data analysis for discrete and continuous outcome. Biometrics 1986; 42: 121-130.

26. S F Wang, K N Leknes, G J Zimmerman, T J sigurdsson, U M Wikesjö, K A Selvig. Intra- and inter-examiner reproducibility in constant force probing. J Clin Periodontol., 1995 Dec; 22 (12): 918-922

Figure Legends

Figure 1. Surgically created, critical-size, one-wall, intra bony periodontal defect at the distal aspect of the mandibular second and mesial aspect of the mandibular 4th premolar teeth. Clinical observation of surgical sites 8 weeks after surgery. All of surgical sites appeared as healthy gingival conditions.

Figure 2. Parameters used in the histometric analysis.

Figure 3. Photomicrographs showing the critical size, intra bony periodontal defects at 8 weeks postsurgery. They are displaying the sites from the apical extension of the root planing along the root surface to the coronal extension of the newly formed bone and cementum and the apical extension of an epithelial attachment (hematoxylin / eosin stain)

Figures

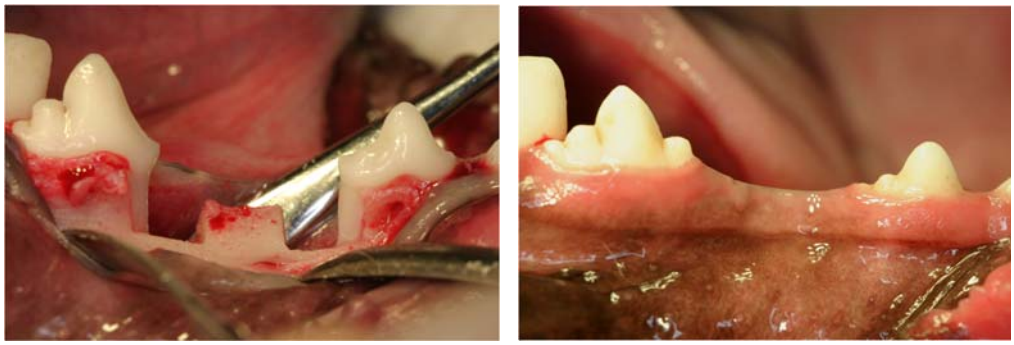

Figure 1. Surgically created, critical-size (4×4×4mm), one-wall, intra bony periodontal defect at the distal aspect of the mandibular second and mesial aspect of the mandibular 4th premolar teeth. (left) Clinical obsevation of surgical sites 8 weeks after surgery. All of surgical sites appeared as healthy gingival conditions. (right)

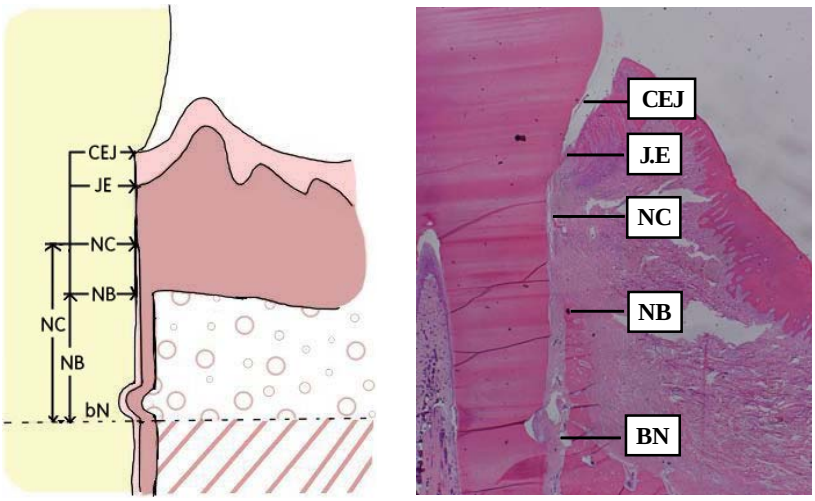

Figure 2. Landmarks / parameters used in the histometric analysis.

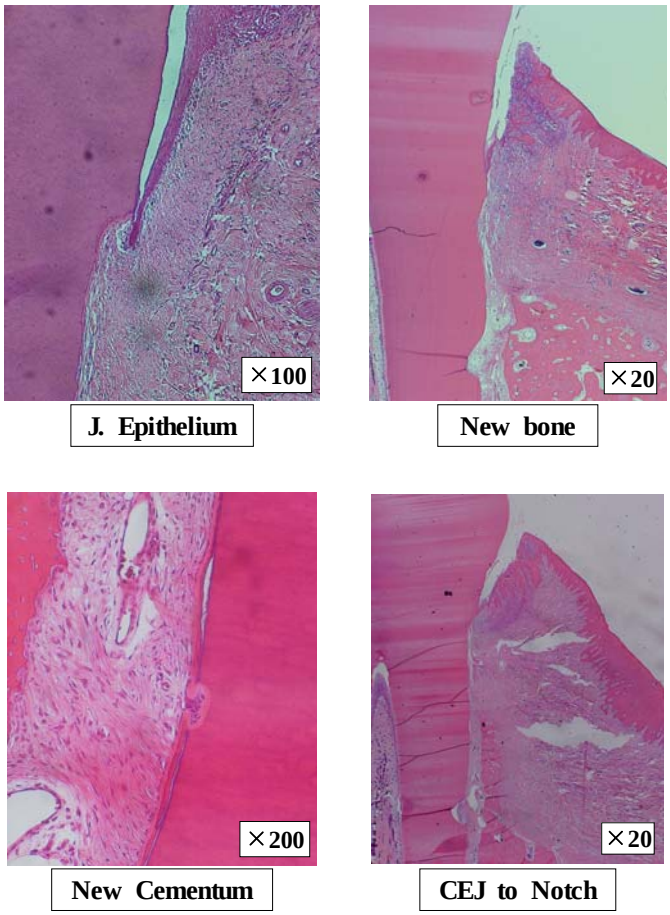

Figure 3. Photomicrographs showing the critical size, intra bony preiodontal defects at 8 weeks postsurgery. They are displaying the sites from the apical extension of the root planing along the root surface to the coronal extension of the newly formed bone and cementum and the apical extension of an epithelial attachment (hematoxylin / eosin).

국문 요약

조직 계측학적 측정에서 관찰자 내 관찰자 간 재현성 평가 : 성견의 1벽성 골내 결손 부

연세대학교 대학원 치의학과
(지도 김 종관 교수)

김 수 경

배경: 정확하고 확실한 측정은 잘 계획된 연구에서 좋은 결과를 야기하는데 매우 중요한 요소이다. 여러 가지 측정 방법 중에서 동물 및 인간실험에서 획득된 조직학적 슬라이드에서 사용되어지는 조직계측학적 평가는 생물학적인 진행상황을 평가하는데 의미 있는 결과를 얻을 수 있다. 이런 조직계측학적 측정은 많은 장점에도 불구하고 연구 전체에서 많은 시간과 노력이 필요한 부분이다. 일정기간 훈련을 받은 제한적 연구자들 간의 측정결과가 의미 있는 재현성을 가지고 있다면 술자 이외의 다른 연구자들의 측정 결과를 이용 할 수 있게 되어 보다 빠른 연구 결과를 얻는데 도움이 될 것이다. 이 연구의 목적은 치조골 1벽성 골내 결손 부 모델에서 조직학적 그리고 조직계측학적 측정 방법의 술자 단독의 술자 내 재현성뿐만 아니라 관찰자 간의 재현성을 평가해보고자 한다. 이 연구에서 사용되어진 통계학적 측정 방법은 ICC 및 Barnhart (2002)이 제안한 Overall concordance correlation coefficient (OCCC)를 이용하였다.

실험방법: 조직계측학적 분석은 20마리의 성견을 이용하였다. 외과적으

로 상자 형태의 4×4×4mm 골 결손 부를 형성하여 5마리 성견의 편측 결손부에 ß-TCP를 이식하였고, 다른 5마리 성견의 편측 결손부에는 GDF 0을 주입하였다. 또 5마리 성견의 편측 결손 부는 GDF 100으로 처리 하였고, 나머지 5마리 성견의 편측 결손부에는 Sharm Surgery를 시행하여 치유를 유도하였다. 반대 측 결손 부는 다른 실험에 이용하였다. 실험 8주 후 희생으로 얻어진 조직 슬라이드를 이용하여 결손부의 길이, 치조골 재형성, 백악질 재형성, 상피세포의 재형성 정도를 계측 하였으며 술자 이외에 숙련된 다른 두 명의 관찰자도 계측을 시행하였다. 조직계측 분석에 사용되어지는 디지털 카메라 및 전통적인 프로그램 및 PC바탕인 이미지 분석기가 달린 광학현미경을 이용하였다. 관찰자 간 및 관찰자 내 계측 재현성을 평가하기 위해 조직계측학적 측정은 술자를 포함 3명의 관찰자가 3개월 이후에 반복 시행하였다. 술자 단독의 술자 내 재현성뿐만 아니라 서로 다른 세 명의 관찰자간의 재현성은 ICC와 OCCC를 이용하여 평가하였다.

결과: 대부분의 측정치들은 단독의 술자 내 재현성뿐만 아니라 술자 간에서도 높은 재현성을 보였다. 술자가 실시한 두 번의 반복 측정결과 모든 측정값에서 0.97 이상의 높은 ICC 값을 보였다. 세 명의 관찰자 간의 재현성을 보기 위해 세 명의 관찰자를 각각 두 명씩 쌍으로 ICC 값을 구한 결과 모든 측정값에서 0.93이상으로 유의하게 높게 나왔으며 P-value는 0.001보다 낮게 나타났다. OCCC 값 또한 0.9 이상의 높은 결과를 보였다. 세 명의 관찰자 간의 재현성을 평가한 ICC 값 중 대조군 그룹의 백악질과 접합 상피에서 다소 낮게 나옴에도 불구하고 (0.89, 0.87), 결손 부 높이, 골 재생 높이, 백악질 재생 높이, 접합상피 형성은 술자 내뿐아니라 술자 간에서 0.9보다 같거나 그 이상의(≥0.9) 상관성을 보였다.

결론: 이상의 결과에서 볼 때 성견의 1벽성 치조골 결손부에서의 조직계측학적 평가는 술자 단독의 술자 내 재현성뿐 아니라 세 명의 관찰자 간에서도 높은 재현성을 얻을 수 있음을 알게 되었다. 따라서 다수의 연구에서 일정 기간 훈련되어진 관찰자에 한하여 보다 쉽고 빠른 조직계측 결과를 얻는데 도움이 될 것으로 사료된다.

핵심 되는 말: 1벽성 골내 결손 부, 조직계측학적 측정 방법, 술자 내 재현성, 술자 간의 재현성, ICC, 포괄적인 일치 상관계수 (OCCC)