# Efficacy and Feasibility of Radiofrequency Ablation for Liver Metastases from Gastric Adenocarcinoma

Hye Ryun Kim

Department of Medicine

The Graduate School, Yonsei University

# Efficacy and Feasibility of Radiofrequency Ablation for Liver Metastases from Gastric Adenocarcinoma

Directed by Professor Sun Young Rha

The Master's Thesis submitted to the Department of Medicine, the Graduate School of Yonsei University in partial fulfillment of the requirements for the degree of Master of Medical Science

Hye Ryun Kim

December 2009

This certifies that the Master's Thesis
of Hye Ryun Kim is approved.

---
Thesis supervisor: Sun Young Rha

---
Thesis committee: Hei-Cheul Jeung

---
Thesis committee: Kwang-Hun Lee

The Graduate School
Yonsei University

December 2009

# ACKNOWLEDGEMENTS

의대 졸업 후 인턴, 레지던트 5 년의 수련일정이 끝나갑니다. 쉽지는 않았지만 제게 많은 것을 생각하게 느끼게 그리고 깨우치게 하였습니다. 그리고 조그만 결실을 얻었습니다.

격려와 칭찬 때로는 혹독한 채찍으로 저를 이끌어 주신 저의 지도교수님 라선영 교수님. 제 마음을 다 말씀 드리지는 못하지만 진심으로 감사드립니다. 교수님의 인생철학이 제 인생의 밑거름이 될 것입니다. 부족한 논문을 지도하여 주신 정희철 교수님. RFA 에 대하여 아낌없는 조언을 해주신 이광훈 교수님. 진심으로 감사드립니다.

항상 공부하시고 가르쳐주시려고 노력하시는 정현철 교수님, 선생님 모습이 저한테는 닮고 싶은 모습입니다. 지금은 다른 병원에 가셨지만저한테 종양내과에 대해 관심을 갖게 해주시고 항상 격려를 아낌없이 해주신 전성하 선생님. 감사드립니다. 종양내과를 같이 시작한 우리 치프들, 안정련, 김찬, 전홍재, 홍민희. 같이여서 즐겁고 재미있게 할수 있었습니다.

저를 항상 믿어주고 인정해주는 엄마, 아빠에게 무한한 감사를 드립니다.

마지막으로 힝상 옆에 있어줘서 고마운 사람에게 마지막으로 감사의 인사를 보냅니다.

이렇게 감사의 글을 쓰고 보니 정말 감사드릴 분들이 많습니다. 이렇게 많은 분들의 도움이 있었음이 새삼 느껴집니다.

# Table of Contents

ABSTRACT……1

I. INTRODUCTION…….…...4

II. MATERIALS AND METHODS……7

1. Patient selection…….…..7
2. Indications for use of RFA treatment……...9
3. Modality of RFA (intraoperative vs. percutaneous) ……10
4. RFA technique ……11
5. Chemotherapy treatment ……12
6. Evaluation of clinical characteristics ……..12
7. Follow-up……15
8. Treatment after recurrence ……16
9. Morbidity classification……16
10. Statistics……17

III. RESULTS……...18

1. Patient characteristics ……18
2. RFA treatment……...20
3. Chemotherapy treatment……...21
4. Recurrence……21
5. Survival……23
6. Complication and morbidity of RFA……24
7. Comparision of RFA and chemotherapy treatment……26

IV. DISCUSSION……26

V. CONCLUSION……31

REFERENCES……32

ABSTRACT(IN KOREAN) ……...34

# LIST OF FIGURES

Figure 1. Flow chart of enrolled patients·····8

Figure 2. Overall survival and progression-free survival of patients treated with RFA ·····24

Figure 3. Overall survival comparing patients who underwent RFA with sequential chemotherapy (n=20) with patients who received chemotherapy only (n=9). (31 months vs. 7 months, hazard ratio, 0.24; *p*=0.004)·····25

# LIST OF TABLES

Table 1. Patients characteristics·····14
Table 2. Treatment outcome of individual patient ·····19
Table 3. Treatment modality in 14 recurred patients after RFA ·····22
Table4. Comparison of reports regarding liver-directed treatment for gastric adenocarcinoma with liver-only metastases ·····30

<ABSTRACT>

Efficacy and Feasibility of Radiofrequency Ablation

for Liver Metastases from Gastric Adenocarcinoma

Hye Ryun Kim

*Department of Medicine*
*The Graduate School, Yonsei University*

(Directed by Professor Sun Young Rha)

**PURPOSE.** Optimal treatment for liver metastases from gastric cancer remains a matter of debate. The aim of our study is to evaluate the efficacy of radiofrequency ablation (RFA) for the treatment of liver-only metastases from gastric adenocarcinoma.

**MATERIALS AND METHODS.** We retrospectively reviewed medical records of 29 patients who developed liver-only metastases from gastric adenocarcinoma and subsequently underwent gastric resection and RFA (n=20) or gastric resection and systemic

chemotherapy (n=9) between January 1995 and February 2008. Overall survival was estimated using the Kaplan-Meier method, and was compared using the log rank test to evaluate RFA efficacy.

**RESULTS**. Twenty patients who underwent RFA showed a median overall survival of 30.7 months (range: 2.9 to 90.9 months), a median progression free survival of 6.8 months (range: 0.8 to 45.2 months), and median overall 1, 3, and 5-year survival rates were 66.8%, 40.1%, and 16.1% respectively. The RFA group showed a 76% decreased death rate compared to the chemotherapy-only group (30.7 months vs. 7 months, hazard ratio, 0.24; p=0.004). Most patients tolerated RFA well, and complications were found to be minor (transient fever (20%) and/or right upper quadrant pain (25%)). One case of treatment-related death occurred due to sepsis that originated from a liver abscess at the ablation site.

**CONCLUSIONS.** The data suggest that a use of RFA as a liver-

directed treatment may provide greater survival benefit than chemotherapy and is an alternative option for the treatment of liver-only metastases from gastric cancer.

---

Key words: radiofrequency ablation, gastric cancer, liver metastases

Efficacy and Feasibility of Radiofrequency Ablation

for Liver Metastases from Gastric Adenocarcinoma

Hye Ryun Kim

*Department of Medicine*
*The Graduate School, Yonsei University*

(Directed by Professor Sun Young Rha)

## I. INTRODUCTION

The liver is one of the most common distant sites for metastasis of gastric cancer. Approximately 5-14% of patients who undergo gastric cancer surgery develop liver metastases synchronously or metachronously [1-7]. Although this metastasis is limited to the liver, liver-only metastases from gastric cancer are usually considered a systemic disease, and are therefore treated with systemic chemotherapy. Despite an improvement in chemotherapy regimens over the last decade, patients with liver metastases from gastric cancer consistently

show a poor prognosis with a median survival of 3-13 months) [8-19]. Therefore, a novel therapeutic strategy is required to improve the survival of patients with liver metastases, especially those with metastases limited to the liver.

In colorectal liver metastases, hepatic resection has been validated as the curative modality, and has been established as the standard treatment [4, 20, 21]. Recent reports have shown that radiofrequency ablation (RFA) could increase the overall survival of colorectal cancer patients with liver metastases [22-25], suggesting that RFA might be an alternative option for patients where surgical resection is unfeasible [25, 26]. Moreover, RFA has shown beneficial treatment outcomes in some specific cases. In addition, the process of RFA is minimally invasive compared to liver resection.

Applying this rationale from treatment strategies for colorectal metastases, several reports have evaluated the efficacy of hepatic resection for liver-only metastases from gastric carcinoma [3, 4, 6, 27-33]. Our previous study also showed that hepatic resection had benefits for overall and recurrence-free survival,

providing the rationale for liver-directed treatment of liver metastases from gastric cancer [1]. However, there are a few anecdotal case studies that reported on the use of RFA as a treatment option for liver metastasis from gastric cancer [34-36].

The aim of this study was to assess both the feasibility and efficacy of RFA with respect to overall survival and progression-free survival in 20 patients with liver-only metastases from gastric cancer. We also investigated the recurrence pattern after RFA treatment. To the best of our knowledge, this is the first reported comprehensive review on patients who underwent RFA for gastric cancer with liver-only metastases.

## II. MATERIALS AND METHODS

This retrospective study was approved by the Severance Hospital Institutional Review Board. All patients signed a written informed consent for participation in the study.

### *Patient selection*

Between January 1995 and February 2008, 13,826 patients were diagnosed with gastric adenocarcinoma at the Yonsei Cancer Center (YCC) of Severance Hospital, Yonsei University Health System (YUHS) in Korea. Among them, 1,309 (9.4%) were shown to have synchronous or metachronous liver metastases. Gastrectomy was performed on 101 of the 1,309 patients. Of the 1,309 patients, 69 had liver-only metastases, 20 patients were treated with RFA, 34 with liver resection, and 15 with systemic chemotherapy (Figure 1). We included 20 patients who underwent gastric resection for the primary cancer and received RFA for liver metastases either simultaneously or after gastrectomy treatment and nine patients who underwent gastric resection and

received systemic chemotherapy.

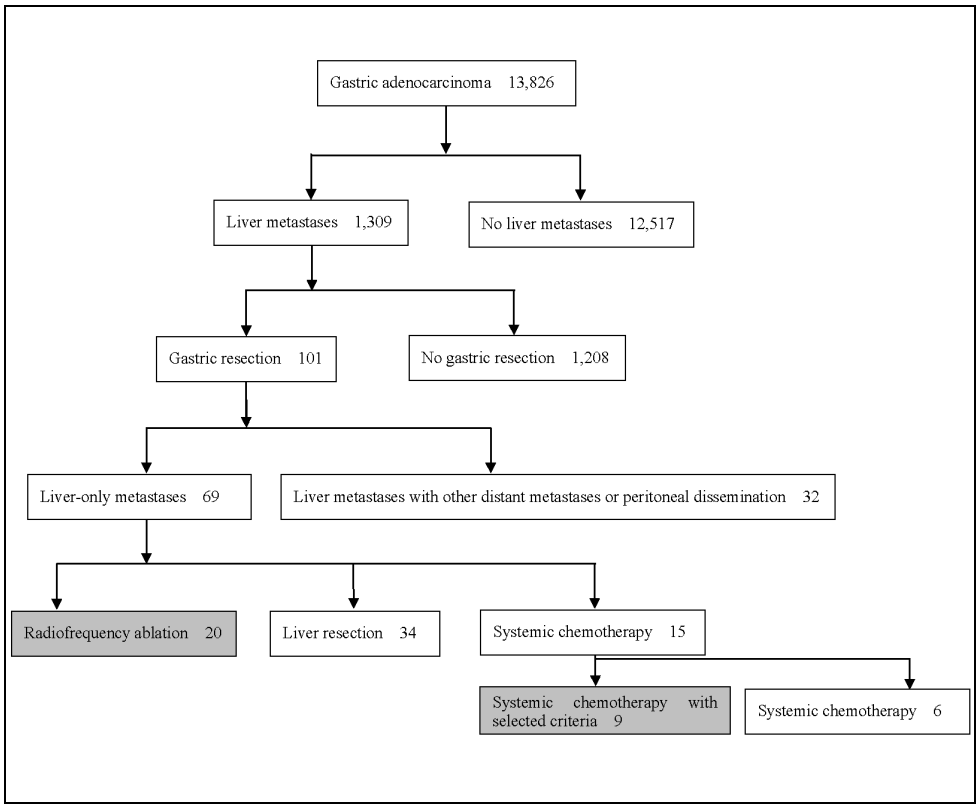


**FIGURE 1.**

**Flow chart of enrolled patients**

All patients treated with RFA had lesions proven to be liver metastases based on contrast-enhanced three-phase computed tomography (CT) (100%, 29/29), dynamic contrast-enhanced magnetic resonance imaging (MRI) (48.3%,

14/29), hypermetabolic lesions on positron emission tomography (PET) (20.7%, 6/29), or positive biopsy findings (41.3%, 12/29). All patients were categorized as Eastern Cooperative Oncology Group (ECOG) 0-1 for performance status, and the median follow-up period was 14.4 months (range; 2.9 to 90.9 months).

Among the 15 patients who received chemotherapy without liver-directed treatment, nine patients with liver metastases characteristics similar to the RFA group were included for a comparative analysis of RFA efficacy. Liver metastases in those nine were treatable by RFA.

***Indications for use of RFA treatment***

Indications for the use of RFA treatment were as follows: (1) no sign of peritoneal dissemination or any other extrahepatic systemic metastases on imaging studies at the time of liver metastases diagnosis; (2) size of the largest liver metastasis was ≤5 cm and the number of liver metastases was less

than four; (3) patients were inoperable either due to the location of liver metastases or an increase in post operative morbidity and mortality was expected; (4) RFA was performed when the patients wished to avoid surgery. Eligibility was clinically determined by the physicians based on the number, size, location, and the timing (synchronous or metachronous) of liver metastasis.

***Modality of RFA (intraoperative vs. percutaneous)***

We performed simultaneous gastric resection and intraoperative RFA in synchronous metastatic liver lesions. For metachronous liver lesions, the choice of intraoperative versus percutaneous RFA was dependent upon the lesion location. Visibility by percutaneous ultrasound and the possibility of injury to adjacent organs were the major determinants. Of the 14 patients with metachronous liver metastases, three received intraoperative RFA due to technical limitations of percutaneous RFA caused by tumor location. RFA was

performed as percutaneous (n=11) or intraoperative (n=9) using ultrasonographic guidance.

***RFA technique***

Single tip 17-G internally cooled electrodes (Cool-tip™ RF Ablation System; Valleylab) were used for 12 minutes at 100℃ per one ablation. The ablative margin was intended to be at least 0.5 cm, so single puncture (n=12) was performed in tumors with no greater than 2.0 cm in size. Double puncture (n=2) was used for tumors between 2.0 and 3.0 cm in size, and triple puncture (n=6) was performed tumor sizes between 3.0-5.0 cm. After the electrode was connected to the generator (Valleylab), RF energy was applied for 12 minutes at each site of the tumor using an impedance control algorithm for the Cool-tip™ RF Ablation System.

***Chemotherapy treatment***

All patients treated with RFA were recommended to receive post-RFA chemotherapy because of metastatic setting even though there have been no established data about the role of post-RFA chemotherapy in this setting.

Nine patients who underwent gastric resection without liver-directed treatment received systemic chemotherapy within four weeks after gastric resection. Systemic chemotherapy was administered until disease progression or intolerance of the treatment.

***Evaluation of clinical characteristics***

The following demographic and clinicopathologic information was retrospectively obtained from the medical records: age, gender, status of primary gastric cancer and liver metastases, treatment after RFA, and recurrence pattern. Primary gastric cancer was characterized by TNM stage, pathologic type, tumor differentiation, tumor location, and primary gastric

cancer tumor size (Table 1). Characteristics of liver metastases included number, size, lobar distribution, and timing of liver metastases (synchronous or metachronous). In this study, liver metastasis diagnosed at the time of gastric tumor resection was considered synchronous, while metastasis detected after gastric cancer resection was considered metachronous. Pathological staging was determined according to criteria defined by the American Joint Committee on Cancer ($6^{th}$ edition, 2002).

**TABLE 1. Patient characteristics**

| Variable | | Number of patients (%) | | p-value |
|---|---|---|---|---|
| | | RFA (n=20) | Chemotherapy-only(n=9) | |
| **Gender** | Male | 15 (75) | 9 (100) | |
| | Female | 5 (25) | 0 (0) | 0.131 |
| **Age (median years)** | | 57 (33-77) | 60 (52-74) | 0.269 |
| **Primary gastric cancer** | | | | |
| T stage | T1 | 2 (10) | 0 (0) | 0.78 |
| | T2 | 3 (15) | 2 (22) | |
| | T3 | 11 (55) | 6 (67) | |
| | T4 | 3 (15) | 1 (11) | |
| | NA | 1 (5) | 0 (0) | |
| N stage | N0 | 2 (10) | 1 (11) | 0.88 |
| | N1 | 4 (20) | 3 (33) | |
| | N2 | 9 (45) | 4 (45) | |
| | N3 | 4 (20) | 1 (11) | |
| | NA | 1 (5) | 0 (0) | |
| Histological grade (differentiation) | Poorly | 7 (35) | 4 (44) | 0.55 |
| | Moderate | 9 (45) | 5 (56) | |
| | Well | 1 (5) | 0 (0) | |
| | NA | 3 (15) | 0 (0) | |
| Tumor lesion | Upper body | 4 (20) | 3 (33) | 0.64 |
| | Mid body | 4 (20) | 1 (11) | |
| | Lower body | 10 (50) | 5 (56) | |
| | NA | 2 (10) | 0 (0) | |
| Tumor size (cm, mean ± SD) | | 5.1 ± 2.3 | 6.1 ±2.2 | 0.61 |
| **Hepatic metastasis** | | | | |
| Number | 1 | 13 (65) | 1 (11) | **0.02** |
| | 2 | 5 (25) | 6 (67) | |
| | 3 | 2 (10) | 2 (22) | |
| Metastatic type | Synchronous | 6 (30) | 6 (67) | 0.06 |
| | Metachronous | 14(70) | 3 (33) | |
| Distribution | Unilobar | 16 (80) | 7 (78) | 0.62 |
| | Bilobar | 4 (20) | 2 (22) | |
| Tumor size (cm, mean ± SD) | | 2.8 ± 1.4 | 4.5±1.5 | 0.41 |
| **Chemotherapy after liver-directed Tx** | | 15 (75) | - | |

NA: not available, SD: standard deviation, Tx: treatment

***Follow-up***

Post-treatment contrast-enhanced three-phase CT was performed 3-4 weeks after RFA to assess the treatment response. Patients who were confirmed as complete ablation underwent follow-up imaging at three to six months intervals for the first two to three years after RFA. Evidence of recurrence was documented as the date on which a recurrence was noted on CT scan. Complete ablation of macroscopic tumor was defined as no viable portion in the remaining lesion based on three-phase liver dynamic CT scan at 3-4 weeks after RFA. Local tumor progression was defined as the recurrence of tumor at the site of ablation [37]. Disease progression was defined as the evidence of new tumor located outside the treated region, and included intrahepatic and extrahepatic sites. Overall survival was defined as the time from liver metastases treatment to either death from any cause or to the last follow-up date. Progression-free survival was defined as the time from the liver metastasis treatment to either the first documentation of recurrence or

progression or death from any cause. In chemotherapy-only patients, CT was performed every two cycles. An evaluation of the response to chemotherapy was performed during the entire course of chemotherapy treatment using Response Evaluation Criteria in Solid Tumors (RECIST).[38]

***Treatment after recurrence***

Patients who had only single site recurrence in the liver after RFA underwent repetitive RFA if possible, whereas those who had multiple liver recurrences or distant metastases received systemic chemotherapy.

***Morbidity classification***

Complications were categorized using the Society of Interventional Radiology (SIR) classification system for complications by outcome [37, 39] into minor and major complications.

***Statistics***

Analysis of the patient's clinicopathologic characteristics was completed by either Fisher's exact test or a $\chi^2$ test. Survival was calculated by the Kaplan-Meier method and was compared using the log rank test. All statistical analyses were conducted using SPSS 13.0 statistical software. A *p*-value less than 0.05 was considered significant.

## III RESULTS

### *Patient characteristics*

Table 1 summarizes the baseline clinicopathologic characteristics of patients who underwent RFA as a liver-directed treatment and those that received only chemotherapy. Detailed information for the 20 individual patients who received RFA is presented in Table 2. The RFA group included 15 men and five women with a median age of 57 years (range 33-77). Unilobar distribution was observed in most patients (80%), and hepatic metastases were detected synchronously in six patients (30%) and metachronously in 14 patients (70%). In patients who had metachronous liver metastases, the median interval between gastric resection and the diagnosis of hepatic metastases was 13.6 months (range 0.5-40.7 months). The percentage of patients who subsequently received chemotherapy after RFA was 75 % (15 patients).

**TABLE 2. Treatment outcome of individual patient.**

| No | age | sex | Primary gastric ca. | | | | Liver metastases | | | | RFA | | | Recur | | | OS | PFS | |
|---|---|---|---|---|---|---|---|---|---|---|---|---|---|---|---|---|---|---|---|
| | | | T | N | M | Initial stage | N | Loc | Chroni -city | Size (cm) | Modality | CTx after RFA | Complete ablation | Recur | Pattern | Tx after recur | (mon) | (mon) | Alive[a] |
| 1 | 57 | M | 4 | 2 | 0 | IV | 1 | uni | meta | 2.5 | intraop | yes | yes | yes | Liver (S5) | RFA | 48.1 | 23.2 | no |
| 2 | 61 | M | 4 | 3 | 1 | IV | 1 | uni | syn | 0.7 | intraop | yes | yes | yes | Liver (multi) | CTx | 37.3 | 3.6 | no |
| 3 | 36 | M | 3 | 3 | 1 | IV | 2 | bi | syn | 1.2 | intraop | yes | yes | yes | Liver (multi) | CTx | 3.7 | 0.8 | no |
| 4 | 45 | F | 3 | 1 | 1 | IV | 3 | bi | syn | 1.0 | intraop | yes | yes | yes | Liver (S1) | CTx | 69.9 | 7.6 | no |
| 5 | 64 | M | 3 | 2 | 1 | IV | 1 | uni | syn | 1.0 | intraop | yes | yes | yes | Liver (multi) | no Tx | 10.9 | 6.8 | no |
| 6 | 67 | M | 2 | 3 | 0 | IV | 1 | uni | meta | 3.5 | intraop | yes | yes | no | - | - | 9.8 | 9.8 | yes |
| 7 | 61 | F | 2 | 1 | 1 | IV | 1 | uni | syn | 2.0 | intraop | yes | yes | no | - | - | 4.3 | 4.3 | yes |
| 8 | 33 | M | - | - | 1 | IV | 1 | uni | syn | 0.9 | intraop | yes | yes | no | - | - | 45.2 | 45.2 | yes |
| 9 | 64 | M | 4 | 1 | 0 | IV | 2 | uni | meta | 4.0 | intraop | no | yes | yes | Liver (S7) | RFA | 30.7 | 10.8 | no |
| 10 | 34 | F | 3 | 2 | 0 | IIIb | 1 | uni | meta | 1.5 | percut | yes | yes | yes | Liver (dome) | RFA | 90.9 | 1.7 | yes |
| 11 | 71 | M | 1 | 0 | 0 | Ia | 2 | bi | meta | 3.5 | percut | yes | yes | yes | Liver (S4) | RFA | 27.3 | 1.1 | no |
| 12 | 65 | F | 3 | 2 | 0 | IIIb | 1 | uni | meta | 1.5 | percut | yes | yes | yes | Liver, lung | CTx | 20.7 | 3 | no |
| 13 | 63 | M | 1 | 0 | 0 | Ia | 1 | uni | meta | 4.0 | percut | yes | yes | yes | Liver, peritoneum | CTx | 53.5 | 19.8 | no |
| 14 | 57 | M | 3 | 2 | 0 | IIIb | 2 | uni | meta | 1.0 | percut | yes | yes | yes | Liver, peritoneum | CTx | 33.8 | 2.5 | no |
| 15 | 64 | M | 3 | 2 | 0 | IIIb | 2 | uni | meta | 4.0 | percut | no | yes | yes | Liver, peritoneum | no Tx | 5.7 | 1.5 | no |
| 16[b] | 49 | M | 3 | 1 | 0 | IIIa | 3 | bi | meta | 2.6 | percut | no | no | yes | Liver, peritoneum | no Tx | 2.9 | 0.9 | no |
| 17[b] | 66 | M | 3 | 2 | 0 | IIIb | 1 | uni | meta | 5.0 | percut | no | no | yes | Liver, lung | no Tx | 5.0 | 4.4 | no |
| 18 | 77 | M | 2 | 3 | 0 | IV | 1 | uni | meta | 1.2 | percut | yes | yes | no | - | - | 3.4 | 3.4 | yes |
| 19 | 42 | M | 3 | 2 | 0 | IIIb | 1 | uni | meta | 1.8 | percut | yes | yes | no | - | - | 14.4 | 14.4 | yes |
| 20 | 66 | F | 3 | 2 | 0 | IIIb | 1 | uni | meta | 2.0 | percut | no | yes | no | - | - | 7.4 | 3.5 | no |

[a] alive at the time of analysis

[b] the patients who showed incomplete ablation

syn, synchronous; meta, metachronous; N, number; Loc, location; CTx, chemotherapy; Tx, treatment; OS, overall survival; PFS, progression-free survival; uni, unilateral lobe; bi, bilateral lobe; intraop, intra-operative; percut, percutaneous

There were no major differences between the two groups in terms of primary gastric cancer characteristics except the number of hepatic metastases, where a single metastasis was observed in 13 out of 20 patients (65%) in the RFA group and only one patient (11%) in chemotherapy-only group ($p$=0.02). In the chemotherapy-only group, the number of liver metastases was as follows: one in one patient (11%), two in six patients (67%), and three in two patients (22%). The total number of liver metastases was less than four due to the selection criteria for the purpose of comparison.

***RFA treatment***

Regarding the modality of RFA, nine patients (patient #1-9) received intra-operative RFA while the remaining 11 patients received percutaneous RFA (patient #10-20). Since percutaneous RFA was preferred to intraoperative RFA to avoid re-operation after gastrectomy for primary gastric cancer, 78% (11/14) of the patients with metachronous-type liver metastases received percutaneous RFA. Three patients received intraoperative RFA since their

tumor locations were technically inaccessible with percutaneous RFA (Table 2). These three patients underwent open surgery as they were initially planned for either hepatic resection or RFA procedure. Then, they underwent intraoperative RFA by the surgeon's and interventional radiologist's collaborative medical decision.

***Chemotherapy treatment***

Of the 20 patients received RFA, 15 patients (75%) underwent sequential chemotherapy, and the remaining five (patient #9, #15-17, and #20; 25%) did not for issues related to liver abscess (patient #15), patient refusal (patient # 9, 16, and 20), or follow-up loss (patient # 17) respectively.

***Recurrence***

Complete ablation was achieved in 90% (18/20) of the patients treated with RFA, indicating the feasibility of the use of RFA in the treatment of liver

metastasis. Local tumor progression three weeks after RFA was detected in two patients (patient # 16 and 17). One patient had a single 5.0 cm liver metastasis, and the other had a total of three liver metastases distributed in the bilateral lobe. The overall recurrence rate after RFA was 70% (14/20): eight patients (40%; 8/20) showed intra-hepatic recurrence only in the remnant liver without any recurrence at the site of ablation, whereas six patients (30%; 6/20) showed both intra- and extrahepatic recurrences (Table 3).

**TABLE 3.** Treatment modality in 14 recurred patients after RFA

| Relapse pattern | Treatment after relapse n (%) | | | Total |
|---|---|---|---|---|
| | Chemotherapy | RFA | No treatment | |
| Intrahepatic only relapse | 2 (25) | 4 (50) | 2 (25) | 8 (100) |
| Single | 1 (12.5) | 4 (50) | 0 (0) | 5 (62.5) |
| Multiple (≥4) | 1(12.5) | 0 (0) | 2 (25) | 3 (37.5) |
| Systemic relapse only except liver | 0 (0) | 0 (0) | 0 (0) | 0 (0) |
| Intrahepatic and systemic relapse | 3 (50) | 0 (0) | 3 (50) | 6 (100) |

Recurrence was commonly observed in the liver (100%), but there was no patient with only extrahepatic recurrence. Among the 8 patients with intra-hepatic recurrence, a single site recurrence was observed in five patients. Among them, four patients underwent RFA treatment for the second time, and

one received systemic chemotherapy. After repetitive RFA at the recurred single site, there was no tumor recurrence at 4.1, 2.1, 89.3, and 3.2-month follow-ups in patients #1, 9, 10, and 11 respectively. Overall survival of theses patients was 48.1, 30.7, 90.9, and 27.3 months respectively.

***Survival***

Progression-free survival was 6.8 months (range 0.8 to 45.2 months), and the median overall survival was 31 months (range 2.9 to 90.9 months) in all patients treated with RFA. The survival rates in the RFA group were 66.8 % for one year, 40.1 % for three years, and 16.7 % for five years (Figure 2). Interestingly, two out of 20 patients (10%) survived more than five years (patients #4 and 10).

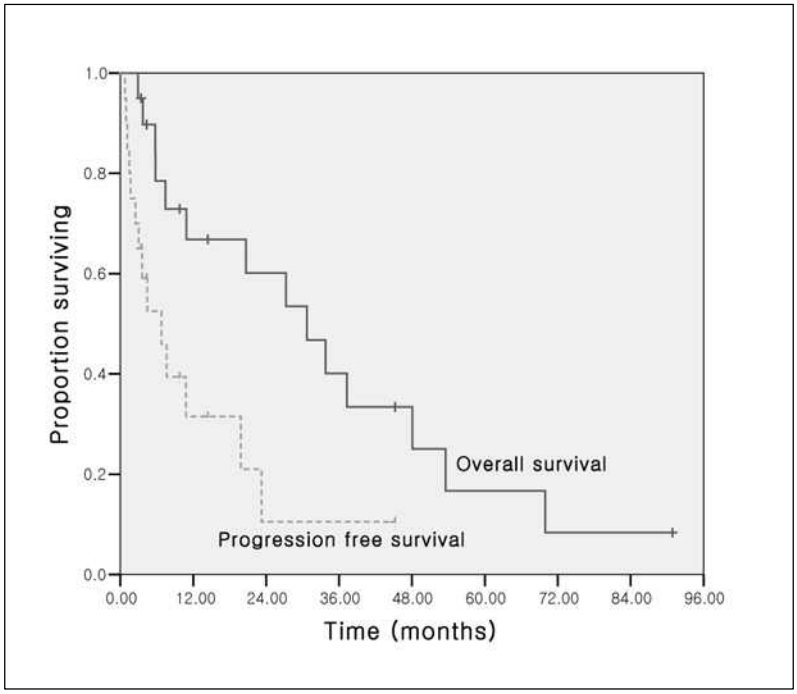


**FIGURE 2.**

**Overall survival and progression-free survival of patients treated with RFA**

***Complication and morbidity of RFA***

Most patients tolerated RFA treatment, due to its predominantly minor side effects. The most common complications by RFA were transient fever (4/20; 20%) and/or right upper quadrant pain (5/20; 25%). These complications were

all categorized as SIR minor, B complications. One patient developed a liver abscess the ablation site and died due to sepsis (patient #15, Table 2). This patient had no underlying co-morbidity issues such as diabetic mellitus or hepatobilliary tract infection, which are risk factors for post-RFA complications.

***Comparision of RFA and chemotherapy treatment***

To evaluate whether RFA had a direct benefit for the treatment of liver metastases, we compared the median overall survival of RFA with the systemic chemotherapy-only group (n=9). The patients in the chemotherapy-only were selected from the same retrospective group, and had similar pretreatment risks to the reference group. The RFA group showed a 76% decrease death compared to the chemotherapy-only group (31 months vs. 7 months, hazard ratio, 0.24; p=0.004) (Figure 3). In this regard, the data show that RFA treatment enhances the survival rate of patients.

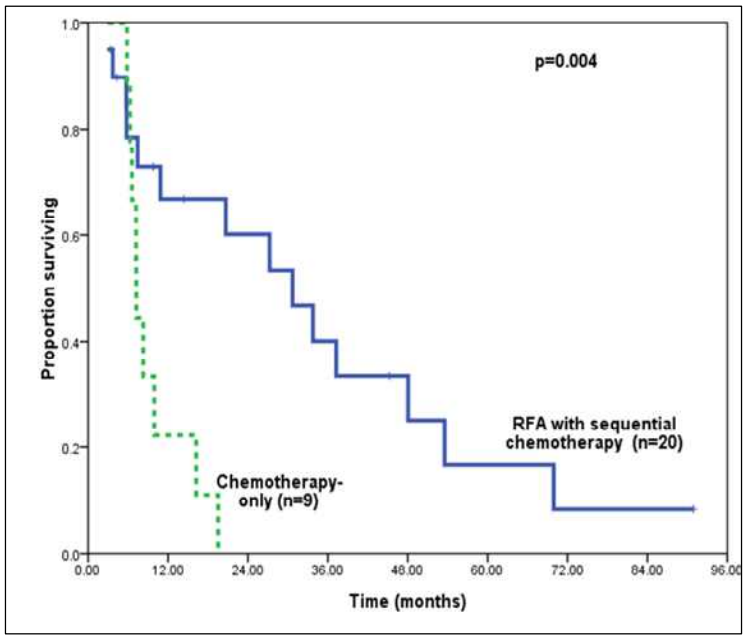


**FIGURE 3.**

**Overall survival comparing patients who underwent RFA with sequential chemotherapy (n=20) with patients who received chemotherapy only (n=9). (31 months vs. 7 months, hazard ratio, 0.24; *p*=0.004)**

## IV DISCUSSION

Given the dismal treatment outcome of conventional systemic chemotherapy for gastric cancer with liver metastases, alternative treatment options are urgently required. The management of these patients with such a dismal prognosis is a therapeutic challenge for both surgeons and oncologists. Recently, liver-directed treatment such as hepatic resection and RFA has been applied to patients with liver-only metastases. The rationale for liver-directed treatment of gastric cancer with liver metastases is as follows. First, when overt metastases are isolated to a specific organ, cytoreduction enables chemotherapy to be more effective and is helpful for good prognosis [40, 41]. Second, removal of the isolated metastatic deposit can prevent further dissemination of the disease to other sites [42].

Until now, there has been no report showing the benefit of RFA for the treatment of liver metastases arising from gastric adenocarcinoma. Even though systemic chemotherapy is recommended as the current standard

treatment for gastric cancer with liver-only metastases, the use of systemic chemotherapy alone made long term survival difficult to achieve, as the treatment outcome was not satisfactory with a median survival of 13 months or less. [8-19]. Considering these historical data, as well as the data presented here on chemotherapy-only treatment without RFA, our RFA treatment followed by systemic chemotherapy showed a better treatment outcome with a median overall survival of 31 months, suggesting that RFA could be a potential treatment option for liver metastases originated from gastric adenocarcinoma.

Generally, RFA has several benefits including both safety and easy accessibility [43]. RFA is less invasive and can be easily repeated when applied in a percutaneous manner. This can be especially important in metachronous metastasis, where re-operative hepatic resections after previous gastrectomy can increase postoperative morbidity and mortality. As shown in our study, most of metachronous metastases were treatable with RFA. In addition, RFA

might be an alternative treatment option when tumors are unresectable or inoperable due to either poor liver function or difficulty in surgical approach [26, 43-49]. Therefore, careful selection of patients with reasonable indications of RFA success is important for improving patient outcome.

In this study, indications for RFA did not always include unresectable patients. Even when the hepatic lesion was resectable, both clinicians and patients tended to prefer the less invasive RFA treatment to the more aggressive resection. A point that requires attention is whether RFA can be used for a patient eligible for surgical resection because an efficacious liver-directed treatment of gastric liver metastases has not yet been established.

In our study, chemotherapy after RFA was performed in 75% patients as an adjuvant treatment. In actual clinical circumstances, many medical oncologists believe that post-operative chemotherapy is an available and helpful treatment option for metastatic cancer after resection, because developing liver metastases is considered as systemic disease. There is no

phase III study comparing local therapy accompanied with systemic chemotherapy vs. systemic chemotherapy. However, there are some reports that show adjuvant chemotherapy after hepatic resection [1, 3-5, 7, 28].

After completion of RFA treatment, the dominant site of recurrence was the liver (Table 3), suggesting that the liver should be under surveillance even after the initial completion of metastases. The rate of local recurrence in the liver without any systemic recurrence was 57.1%. Such high recurrence rate in the remnant liver can be explained by micrometastases that are defined as cancer cell clusters of 1.0 mm or less separated from cancer by normal liver parenchyma, around liver metastases suggested by Nomura et al. [50]. However, these high recurrence rates in the liver do not indicate the local failure of RFA treatment because most local recurrences involve the development of new lesions in the remnant liver and not at the RFA site. Local tumor progression after RFA or incomplete ablation was observed in only two patients (patient #16, 17 in Table 2). The cause of RFA local failure may be due to the

relatively large lesion (5 cm), bilateral distribution and large number. Theses patients showed a comparatively reduced overall survival of 2.9 and 5.8 months respectively. Therefore, complete ablation in RFA can be considered as an important predictive factor for the reduction of RFA failure.

Some studies pertaining to hepatic resection demonstrated the number or size of liver metastases as prognostic factors for survival [4, 5, 7, 51], whereas there was no significant prognostic factor for survival identified in our study. We compared our results with previous reports and reviewed Shirabe's reports. (Table 4)

**Table 4. Comparison of reports regarding liver-directed treatment for gastric adenocarcinoma with liver-only metastases**

| Reference | Nation | Enroll period (years) | Patient number (n) | Syn/meta-chronous | Single/Multiple LM | Prognostic factor | Adjuvant chemotherapy (n) | Median survival duration (months) | Overall survival (%) | | |
|---|---|---|---|---|---|---|---|---|---|---|---|
| | | | | | | | | | 1 yr | 3 yr | 5 yr |
| Sakamoto Y et al. [4] | Japan | 1985-2001 | 22 | 12/10 | 16/6 | Number/size | 8 (36%) | 21.0 | 73.0 | 38.0 | 38.0 |
| Okano K et al. [3] | Japan | 1986-1999 | 19 | 13/6 | 10/9 | Peritumoral | 11 (58%) | 21.0 | 77.0 | 34.0 | 34.0 |
| Ambiru S et al. [28] | Japan | 1975-1999 | 40 | 18/22 | 19/21 | Time of thepatic | 13 (33%) | 12.0 | _ | _ | 18.0 |
| Sakamoto Y et al. [5] | Japan | 1990-2005 | 37 | 16/21 | 21/16 | Distritubion, size | 6 (16%) | 31 | _ | _ | 11 |
| Koga R et al. [7] | Japan | 1985-2005 | 42 | 20/22 | 29/13 | Seroral invasion | 13 (31%) | 34 | 76 | 48 | 42 |
| Kim et al.(current study) | Korea | 1995-2008 | 20 | 6/14 | 13/7 | none | 15 (75%) | 30.7 | 66.8 | 40.1 | 16.1 |

Our study had some limitations. One was that patients enrolled in this study may have had other than true, liver-confined metastases. Since peritoneal metastases were usually found in almost 40% of gastric cancer patients with liver metastases, we needed to laparoscopically explore for accurate eligibility. Also, this was a retrospective study including a very small subset of patients. With the possibility of selection bias, we are limited in applying these results to all patients with liver-only metastases from gastric cancer.

Despite these limitations, our results show that RFA followed by chemotherapy can be considered a treatment option because it was shown to be more beneficial to prolonged survival than chemotherapy alone and feasible for patients who underwent gastrectomy. Based upon our data, we suggest RFA for the treatment of liver metastatic lesions if the liver metastases are up to 5 cm in diameter, less than four in number, and metachronous. For future study, a well controlled prospective study would be more helpful for a detailed evaluation of RFA efficacy in gastric cancer with liver metastases.

**V. CONCLUSIONS.** The data suggest that a use of RFA as a liver-directed treatment may provide greater survival benefit than chemotherapy and is an alternative option for the treatment of liver-only metastases from gastric cancer.

## REFERENCES

1. Cheon SH, Rha SY, Jeung HC, Im CK, Kim SH, Kim HR, et al. Survival benefit of combined curative resection of the stomach (D2 resection) and liver in gastric cancer patients with liver metastases. *Ann Oncol* 2008;19(6):1146-53.

2. Marrelli D, Roviello F, De Stefano A, Fotia G, Giliberto C, Garosi L, et al. Risk factors for liver metastases after curative surgical procedures for gastric cancer: a prospective study of 208 patients treated with surgical resection. *J Am Coll Surg* 2004;198(1):51-8.

3. Okano K, Maeba T, Ishimura K, Karasawa Y, Goda F, Wakabayashi H, et al. Hepatic resection for metastatic tumors from gastric cancer. *Ann Surg* 2002;235(1):86-91.

4. Sakamoto Y, Ohyama S, Yamamoto J, Yamada K, Seki M, Ohta K, et al. Surgical resection of liver metastases of gastric cancer: an analysis of a 17-year experience with 22 patients. *Surgery* 2003;133(5):507-11.

5. Sakamoto Y, Sano T, Shimada K, Esaki M, Saka M, Fukagawa T, et al. Favorable indications for hepatectomy in patients with liver metastasis from gastric cancer. *J Surg Oncol* 2007;95(7):534-9.

6. Zacherl J, Zacherl M, Scheuba C, Steininger R, Wenzl E, Mühlbacher F, et al. Analysis of hepatic resection of metastasis originating from gastric adenocarcinoma. *Journal of gastrointestinal surgery* 2002;6(5):682-9.

7. Koga R, Yamamoto J, Ohyama S, Saiura A, Seki M, Seto Y, et al. Liver resection for metastatic gastric cancer: experience with 42 patients including eight long-term survivors. *Jpn J Clin Oncol* 2007;37(11):836-42.

8. Koizumi W, Narahara H, Hara T, Takagane A, Akiya T, Takagi M, et al. S-1 plus cisplatin versus S-1 alone for first-line treatment of advanced gastric cancer (SPIRITS trial): a phase III trial. *Lancet Oncol* 2008;9(3):215-21.

9. Pozzo C, Barone C. Is there an optimal chemotherapy regimen for the treatment of advanced gastric cancer that will provide a platform for the introduction of new biological agents? *Oncologist* 2008;13(7):794-806.
10. Wagner AD, Grothe W, Haerting J, Kleber G, Grothey A, Fleig WE. Chemotherapy in advanced gastric cancer: a systematic review and meta-analysis based on aggregate data. *J Clin Oncol* 2006;24(18):2903-9.
11. Yonemura Y, Matuki N, Sakuma H, Katayama K, Sawa T, Fujimura T, et al. Effect of intra-hepatoarterial infusion of MMC and CDDP for gastric cancer patients with liver metastases. *Surg Today* 1992;22(3):253-9.
12. Tiberio GA, Coniglio A, Marchet A, Marrelli D, Giacopuzzi S, Baiocchi L, et al. Metachronous hepatic metastases from gastric carcinoma: a multicentric survey. *Eur J Surg Oncol* 2009;35(5):486-91.
13. Kumada T, Arai Y, Itoh K, Takayasu Y, Nakamura K, Ariyoshi Y, et al. Phase II study of combined administration of 5-fluorouracil, epirubicin and mitomycin-C by hepatic artery infusion in patients with liver metastases of gastric cancer. *Oncology* 1999;57(3):216-23.
14. Ohtsu A, Shimada Y, Shirao K, Boku N, Hyodo I, Saito H, et al. Randomized phase III trial of fluorouracil alone versus fluorouracil plus cisplatin versus uracil and tegafur plus mitomycin in patients with unresectable, advanced gastric cancer: The Japan Clinical Oncology Group Study (JCOG9205). *Journal of clinical oncology* 2003;21(1):54-9.
15. Van Cutsem E, Moiseyenko VM, Tjulandin S, Majlis A, Constenla M, Boni C, et al. Phase III study of docetaxel and cisplatin plus fluorouracil compared with cisplatin and fluorouracil as first-line therapy for advanced gastric cancer: a report of the V325 Study Group. *Journal of clinical oncology* 2006;24(31):4991-7.
16. Vanhoefer U, Rougier P, Wilke H, Ducreux MP, Lacave AJ, Van Cutsem E, et al. Final results of a randomized phase III trial of

sequential high-dose methotrexate, fluorouracil, and doxorubicin versus etoposide, leucovorin, and fluorouracil versus infusional fluorouracil and cisplatin in advanced gastric cancer: A trial of the European Organization for Research and Treatment of Cancer Gastrointestinal Tract Cancer Cooperative Group. *Journal of clinical oncology* 2000;18(14):2648-57.

17. Yonemura Y, Ohyama S, Kamata T, Fujimura T, Kimura H, Matsuki N, et al. [Multivariate analysis of gastric cancer patients with liver metastases]. *Gan To Kagaku Ryoho* 1990;17(10):2063-9.

18. Ajani JA. Evolving chemotherapy for advanced gastric cancer. *Oncologist* 2005;10 Suppl 3:49-58.

19. Kang GH, Kim GS, Lee HR, Yuh YJ, Kim SR. A Phase II Trial of Paclitaxel, 5-fluorouracil (5-FU) and Cisplatin in Patients with Metastatic or Recurrent Gastric Cancer. *Cancer Res Treat* 2008;40(3):106-10.

20. Aloia TA, Vauthey JN, Loyer EM, Ribero D, Pawlik TM, Wei SH, et al. Solitary colorectal liver metastasis: resection determines outcome. *Arch Surg* 2006;141(5):460-6; discussion 66-7.

21. Scheele J, Stang R, Altendorf-Hofmann A, Paul M. Resection of colorectal liver metastases. *World J Surg* 1995;19(1):59-71.

22. Kornprat P, Jarnagin WR, DeMatteo RP, Fong Y, Blumgart LH, D'Angelica M. Role of intraoperative thermoablation combined with resection in the treatment of hepatic metastasis from colorectal cancer. *Arch Surg* 2007;142(11):1087-92.

23. Oshowo A, Gillams A, Harrison E, Lees WR, Taylor I. Comparison of resection and radiofrequency ablation for treatment of solitary colorectal liver metastases. *Br J Surg* 2003;90(10):1240-3.

24. Sean Garrean JH, Abdul Saied et al. Radiofreqency ablation of primary and metastatic liver tumors: a critical review of the literature. *The American Journal of Surgery* 2008;195:508-20.

25. Bremers AJ, Ruers TJ. Prudent application of radiofrequency

ablation in resectable colorectal liver metastasis. *Eur J Surg Oncol* 2007;33(6):752-6.
26. Abitabile P, Hartl U, Lange J, Maurer CA. Radiofrequency ablation permits an effective treatment for colorectal liver metastasis. *Eur J Surg Oncol* 2007;33(1):67-71.
27. Imamura H, Matsuyama Y, Shimada R, Kubota M, Nakayama A, Kobayashi A, et al. A study of factors influencing prognosis after resection of hepatic metastases from colorectal and gastric carcinoma. *Am J Gastroenterol* 2001;96(11):3178-84.
28. Ambiru S, Miyazaki M, Ito H, Nakagawa K, Shimizu H, Yoshidome H, et al. Benefits and limits of hepatic resection for gastric metastases. *Am J Surg* 2001;181(3):279-83.
29. Bines SD, England G, Deziel DJ, Witt TR, Doolas A, Roseman DL. Synchronous, metachronous, and multiple hepatic resections of liver tumors originating from primary gastric tumors. *Surgery* 1993;114(4):799-805; discussion 04-5.
30. Miyazaki M, Itoh H, Nakagawa K, Ambiru S, Shimizu H, Togawa A, et al. Hepatic resection of liver metastases from gastric carcinoma. *Am J Gastroenterol* 1997;92(3):490-3.
31. Elias D, Cavalcanti de Albuquerque A, Eggenspieler P, Plaud B, Ducreux M, Spielmann M, et al. Resection of liver metastases from a noncolorectal primary: indications and results based on 147 monocentric patients. *J Am Coll Surg* 1998;187(5):487-93.
32. Foster JH. Survival after liver resection for secondary tumors. *Am J Surg* 1978;135(3):389-94.
33. Harrison LE, Brennan MF, Newman E, Fortner JG, Picardo A, Blumgart LH, et al. Hepatic resection for noncolorectal, nonneuroendocrine metastases: a fifteen-year experience with ninety-six patients. *Surgery* 1997;121(6):625-32.
34. An JY, Kim JY, Choi MG, Noh JH, Choi D, Sohn TS, et al. Radiofrequency ablation for hepatic metastasis from gastric

adenocarcinoma. *Yonsei Med J* 2008;49(6):1046-51.
35. Kosaka T, Imaizumi H, Kamei K, Usami K, Nakano Y, Ueno K, et al. [A case of gastric cancer patient with liver metastasis treated by radiofrequency ablation therapy combined with intra-arterial chemotherapy]. *Gan To Kagaku Ryoho* 2004;31(11):1737-9.
36. Carditello A, Scisca C, Stilo F, Parisi A, Basile M. The possible role of radiofrequency as complementary treatment of locally advanced gastric cancer. *Annali italiani di chirurgia* 2005;76(1):39-41.
37. Goldberg SN, Grassi CJ, Cardella JF, Charboneau JW, Dodd GD, 3rd, Dupuy DE, et al. Image-guided tumor ablation: standardization of terminology and reporting criteria. *J Vasc Interv Radiol* 2009;20(7 Suppl):S377-90.
38. Therasse P, Arbuck SG, Eisenhauer EA, Wanders J, Kaplan RS, Rubinstein L, et al. New guidelines to evaluate the response to treatment in solid tumors. European Organization for Research and Treatment of Cancer, National Cancer Institute of the United States, National Cancer Institute of Canada. *J Natl Cancer Inst* 2000;92(3):205-16.
39. Sacks D, McClenny TE, Cardella JF, Lewis CA. Society of Interventional Radiology clinical practice guidelines. *J Vasc Interv Radiol* 2003;14(9 Pt 2):S199-202.
40. Fumoleau P. Treatment of patients with liver metastases. *Anticancer Drugs* 1996;7 Suppl 2:21-3.
41. Frezza EE, Wachtel MS, Barragan B, Chiriva-Internati M, Cobos E. The role of radiofrequency ablation in multiple liver metastases to debulk the tumor: a pilot study before alternative therapies. *J Laparoendosc Adv Surg Tech A* 2007;17(3):282-4.
42. Schildberg FW, Meyer G, Piltz S, Koebe HG. Surgical treatment of tumor metastases: general considerations and results. *Surg Today* 1995;25(1):1-10.
43. Ribeiro MA, Jr., Rodrigues JJ, Habr-Gama A, Chaib E, D'Ipolitto G,

Fonseca AZ, et al. Radiofrequency ablation of primary and metastatic liver tumors--4 years experience. *Hepatogastroenterology* 2007;54(76):1170-5.
44. Sorensen SM, Mortensen FV, Nielsen DT. Radiofrequency ablation of colorectal liver metastases: long-term survival. *Acta Radiol* 2007;48(3):253-8.
45. Siperstein AE, Berber E, Ballem N, Parikh RT. Survival after radiofrequency ablation of colorectal liver metastases: 10-year experience. *Ann Surg* 2007;246(4):559-65; discussion 65-7.
46. Mulier S, Ni Y, Jamart J, Michel L, Marchal G, Ruers T. Radiofrequency ablation versus resection for resectable colorectal liver metastases: time for a randomized trial? *Ann Surg Oncol* 2008;15(1):144-57.
47. Leen E, Horgan PG. Radiofrequency ablation of colorectal liver metastases. *Surg Oncol* 2007;16(1):47-51.
48. Rasmussen F. Radiofrequency ablation of liver metastases improves the survival rate of patients with metastatic colorectal disease. *Acta Radiol* 2007;48(3):250-1.
49. Pereira PL. Actual role of radiofrequency ablation of liver metastases. *Eur Radiol* 2007;17(8):2062-70.
50. Nomura T, Kamio Y, Takasu N, Moriya T, Takeshita A, Mizutani M, et al. Intrahepatic micrometastases around liver metastases from gastric cancer. *J Hepatobiliary Pancreat Surg* 2009;16(4):493-501.
51. Shirabe K, Wakiyama S, Gion T, Watanabe M, Miyazaki M, Yoshinaga K, et al. Hepatic resection for the treatment of liver metastases in gastric carcinoma: review of the literature. *HPB (Oxford)* 2006;8(2):89-92.

< ABSTRACT(IN KOREAN)>

# 위암 간전이 환자에서 고주파 소작술의 효용성

<지도교수 라선영>

연세대학교 대학원 의학과

김혜련

위암의 간전이에서의 최적의 치료에 대해서는 아직 정립되지 않았다. 본 연구의 목적은 위선암으로부터의 간전이에서의 치료에 있어 고주파소작술의 효용성에 대하여 밝히는 것이다. 본 연구는 연세대학교 세브란스 병원에서 1995년 1월부터 2008년 2월 사이에 위선암에서 간전이만 있는 환자 중에서 위암에 대하여는 위절제술을 시행한 사람을 대상으로 하여 이중 간전이에 대하여 고주파 소작술을 시행한 20명과 위절제는 하였으나 간전이에 대하여는 치료를 받지 않은 9명의 환자의 의무기록을 후향적으로 분석하였다.

위절제술을 받고 동시에 혹은 이후에 고주파 소작술을 받은 20명의

환자의 전체 생존율은 30.7개월이며 무병 생존률은 6.8개월이고 1년, 3년, 5년 생존율은 각각 66.8 %, 40.1%, 16.1% 로 나왔다. 대부분의 환자는 고주파 소작술에 잘 견뎠으며 시술에 따른 부작용도 일시적 발열 20% 상복부 통증(25%) 등으로 비교적 심하지 않았다. 한 환자에서 시술부위로의 감염증으로 간농양이 생기고 이로 인한 패혈증으로 사망하였다. 결론적으로 간 직접치료로서 고주파 소작술은 위암의 간전이만 있는 환자에게서 유용한 치료로서 고려될 수 있겠다.

---

핵심되는 말: 고주파 소작술, 위암, 간전이