Comparison of Intraparenchymal Biocompatibilities of Oxidized Regenerated Cellulose, Porcine Small Intestine Submucosa, and Absorbable Gelatin in Rat Kidney

Kyo Chul Koo

Department of Medicine

The Graduate School, Yonsei University

Comparison of Intraparenchymal Biocompatibilities of Oxidized Regenerated Cellulose, Porcine Small Intestine Submucosa, and Absorbable Gelatin in Rat Kidney

Kyo Chul Koo

Department of Medicine

The Graduate School, Yonsei University

Comparison of Intraparenchymal Biocompatibilities of Oxidized Regenerated Cellulose, Porcine Small Intestine Submucosa, and Absorbable Gelatin in Rat Kidney

Directed by Professor Seung Choul Yang

The Master's Thesis submitted to the Department of Medicine, the Graduate School of Yonsei University in partial fulfillment of the requirements for the degree of Master of Medical Science

Kyo Chul Koo

December 2008

This certifies that the Master's Thesis of Kyo Chul Koo is approved

Thesis Supervisor : Seung Choul Yang

Thesis Committee Member : John A. Linton

Thesis Committee Member : Dae Suk Han

The Graduate School
Yonsei University

December 2008

ACKNOWLEDGEMENTS

I would like to express the deepest appreciation to my supervisor, Professor Seung Choul Yang who has the attitude and substance of a genius : he continually and convincingly conveyed a spirit of adventure in regard to research and scholarship, and an excitement in regard to teaching.

I would like to specially thank Professor Woong Kyu Han for introducing me into enthusiasm for research, for giving me valuable advice, and for helping me in getting started with animal experimentation.

Many extra thanks to Professor John A. Linton and Professor Dae Suk Han who very kindly have taken the time and trouble to alert me errors in the texts for improvement of its quality.

Special thanks to Ju Yeon Pyo for kindly sacrificing weekends to guide me through slides. I hope the very best for her Doctor’s.

And finally never enough thanks to my parents who made me come so far. Without their guidance and persistent help this master’s would not have been possible. No doubt dad is as much proud as mom. I miss you dad.

<TABLE OF CONTENTS>

LIST OF FIGURES

LIST OF TABLES

ABSTRACT

Comparison of Intraparenchymal Biocompatibilities of Oxidized Regenerated Cellulose, Porcine Small Intestine Submucosa, and Absorbable Gelatin in Rat Kidney

Kyo Chul Koo

Department of Medicine

The Graduate School, Yonsei University

Directed by Professor Seung Choul Yang

I. Purpose : The objective of this study was to evaluate biological properties of a variety of materials used in partial nephrectomy.

II. Materials and Methods : 48 Sprague-Dawley rats, 6 for each group were divided into an experimental period of 2 and 8 weeks. 2 groups were negative control for the experiment. Oxidized regenerated cellulose (Surgicel®), porcine small intestine submucosa (SIS®), and absorbable gelatin (Gelfoam®) were inserted into the defected renal parenchyma. At the end of two observation periods, animals were sacrificed and specimens were prepared for

histological examination to compare their biocompatibilities.

III. Results : The reaction of the host tissue to the materials diminished with time. After analyzing both periods, there were no significant differences of inflammatory reaction between all materials. Oxidized regenerated cellulose, porcine small intestine submucosa (porcine SIS), and absorbable gelatin were biocompatible at both periods.

IV. Conclusion : It was concluded that there were no biocompatibility differences in between oxidized regenerated cellulose, porcine SIS, and absorbable gelatin. All materials were safe and biocompatible when substituted into the renal parenchyma.

Key words: biocompatibility, kidney, rat

Comparison of Intraparenchymal Biocompatibilities of Oxidized Regenerated Cellulose, Porcine Small Intestine Submucosa, and Absorbable Gelatin in Rat Kidney

Kyo Chul Koo

Department of Medicine

The Graduate School, Yonsei University

Directed by Professor Seung Choul Yang

I. INTRODUCTION

For decades, clinicians and scientists have been attempting to use a variety of synthetic and harvested natural substitutes for successful genitourinary tract reconstruction. Among various biosynthetic substitutes used in parenchymal defect reconstruction during partial nephrectomy oxidized regenerated cellulose (Surgicel®), porcine small intestine submucosa (porcine SIS : SIS®) and absorbable gelatin (Gelfoam®) are currently the most widely used materials.[1] Through previous literature these materials have been proven to be effective as mechanical and chemical bolsters to reconstruct renal parenchymal defects and to induce hemostasis.[2]

Among broad characteristics of biosynthetic substitutes used in partial

nephrectomy the ideal material should be biocompatible, dimensionally stable, non-toxic, and non-immune in order to minimize adverse effects after implantation. Adjacent host tissue size, shape and durability should be maintained during the healing process. Besides, it should not trigger inflammation or induce tumor.[3] However, there are limited studies upon quantitative analysis of inflammatory processes of biosynthetic substitutes after implantation.

In this study, a rat model was used to evaluate and compare the biocompatibilities of oxidized regenerated cellulose, porcine SIS, and absorbable gelatin when implanted into the defected renal parenchyma after partial nephrectomy. Biocompatibilities of these biosynthetic substitutes were compared by a pathologic means after 2 and 8 week periods.

II. MATERIALS & METHODS

1. Experiment group

The policy and regulation recommended by the Institutional Animal Care and Use Committee of Yonsei University Medical Center was used in this experiment. 48 Sprague-Dawley rats 12 for each material, divided into experimental periods of 2 and 8 weeks received 1 implant in the lower pole of the right kidney after a partial resection of the parenchyma. Rats were randomly assigned to 1 of 8 (n=12/group, 6/period) experimental implantations: control, oxidized regenerated cellulose, porcine SIS, and absorbable gelatin (Table 1). At the end of the experimental periods, animals were sacrificed and specimens were prepared for histological analysis to evaluate and compare their biocompatibilities.

Table 1. Experimental design

Materials	SIS®		Surgicel®		Gelfoam®		Control	
Experimental periods	2 weeks	8 weeks	2 weeks	8 weeks	2 weeks	8 weeks	2 weeks	8 weeks
Parenchymal implant units	6	6	6	6	6	6	6	6

2. Surgical procedure

The animals were anesthetized intraperitoneally with tiletamine/zolazepam (Zoletil100®-Virbac), dissolved at 200 mg/ml. The abdomen was prepped and draped in the left lateral decubitus position. A 15 mm transverse incision was made and the

right kidney was dissected and mobilized until exposure of the lower pole. A 0.5-1.0 cm sized defect was created in the inferior lateral aspect of the kidney using a #11 surgical blade. The created gap was packed with oxidized regenerated cellulose, porcine SIS, and absorbable gelatin tailored to a length of 0.5 cm and a width of 0.3 cm. Compression was performed until there was no active bleeding. After replacing the kidney in its position, skin suture was performed with a 2-0 absorbable material. In all cases preoperative or postoperative antibiotics were not applied.

3. Pathologic evaluation

Standardized methods were used to evaluate the biological reactions recommended by the technical report #9 Federation Dentaire Internationale (FDI). The specimens were prepared in 10% buffered formalin solution for routine histological analysis. Serial sections of 5 μm thickness were sliced and stained with hematoxylin-eosin (H & E). A single pathologist determined inflammatory reactions through nine histological criteria - neutrophilic leukocyte, macrophage, lymphocyte, plasma cell, giant foreign body cell, dispersed material, necrotic tissue, inflammatory response, and calcification.[4]

4. Statistical analysis

Comparison between groups of the same experimental period was analyzed by means of one-way ANOVA. A *p*-value of less than 0.05 indicated a significant difference.

III. RESULTS

The histological evaluations of the materials were performed using the experimental classification model recommended by the technical report #9 FDI. The results at 2 and 8 weeks are summarized in Table 2.

Table 2. Histological evaluations of tested materials at 2 and 8 weeks

	SIS®		Surgicel®		Gelfoam®	
Histological criteria	2 weeks	8 weeks	2 weeks	8 weeks	2 weeks	8 weeks
Neutrophilic leukocytes	++	+	+	+	+	+
Macrophages	+	+	+++	+++	++	+++
Lymphocytes	+++	+	++	++	++	++
Plasma cells	+	++	+	+	++	+
Giant foreign body cells	+	+	+++	++	+++	+
Dispersed material	+	+	+	+	++	+
Necrotic tissue	+	+	+	+	+	+
Inflammatory response	++	+	++	+	++	++
Calcification	++	+	+	++	+++	++

+ Absent/slight; ++ moderate; +++ severe

1. 2-week observations

A. Negative control

The tissue response alongside the lower pole parenchymal defect served as a negative control for the technique. No inflammatory reactions were evident at all observation periods in all specimens.

B. Oxidized regenerated cellulose

Inflammatory reaction was severe with mononuclear inflammatory infiltrates demonstrated by the presence of macrophages and giant foreign body cells. Among all inflammatory cells, macrophages were the most predominant. Eosinophils and neutrophils were not evident suggesting rapid regression of acute inflammatory reaction. The degree of calcification was the least among all materials.

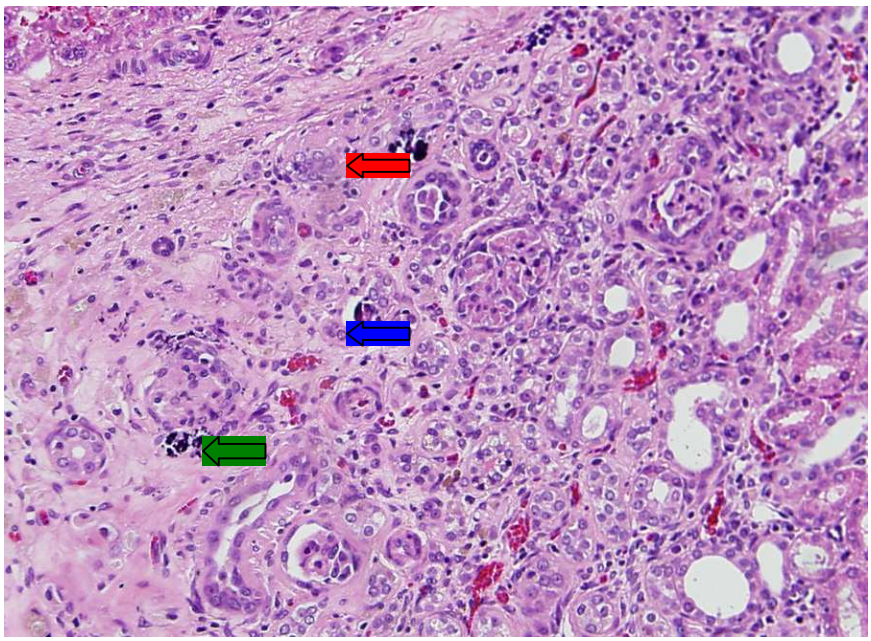

Figure 1. Oxidized regenerated cellulose 2 weeks. Overview of the tissue reaction adjacent to the implanted material demonstrating macrophages, calcification, and

giant foreign body cells indicated by blue, green, and red arrows, respectively (H & E, original magnification 100x).

C. Porcine SIS

The presence of eosinophilic and neutrophilic infiltrates was a unique finding which was not observed in any other specimens. The in-growth of urothelium into the consistent and durable implanted porcine SIS was also a unique finding.

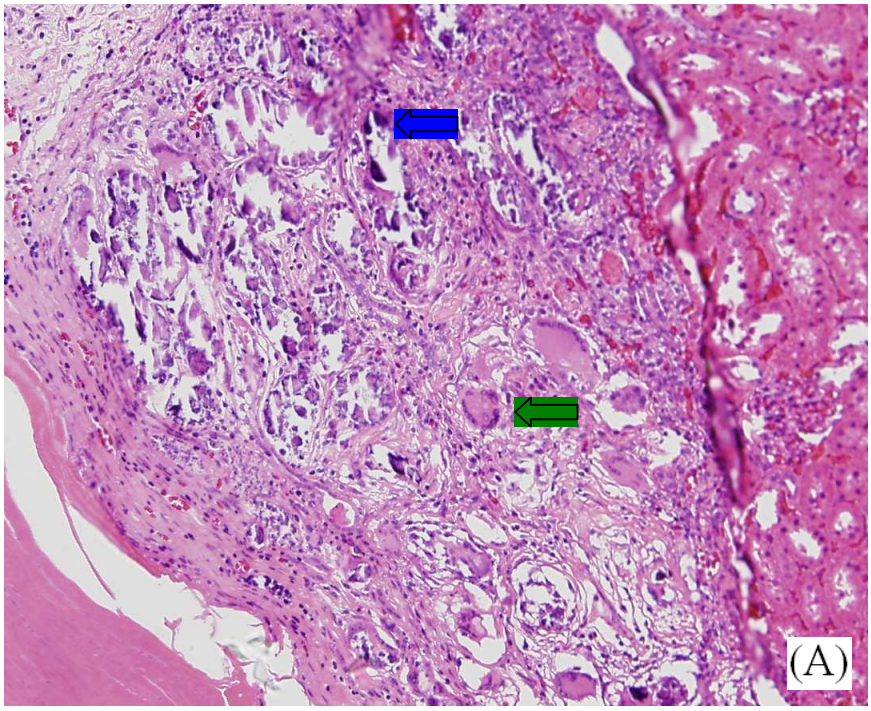

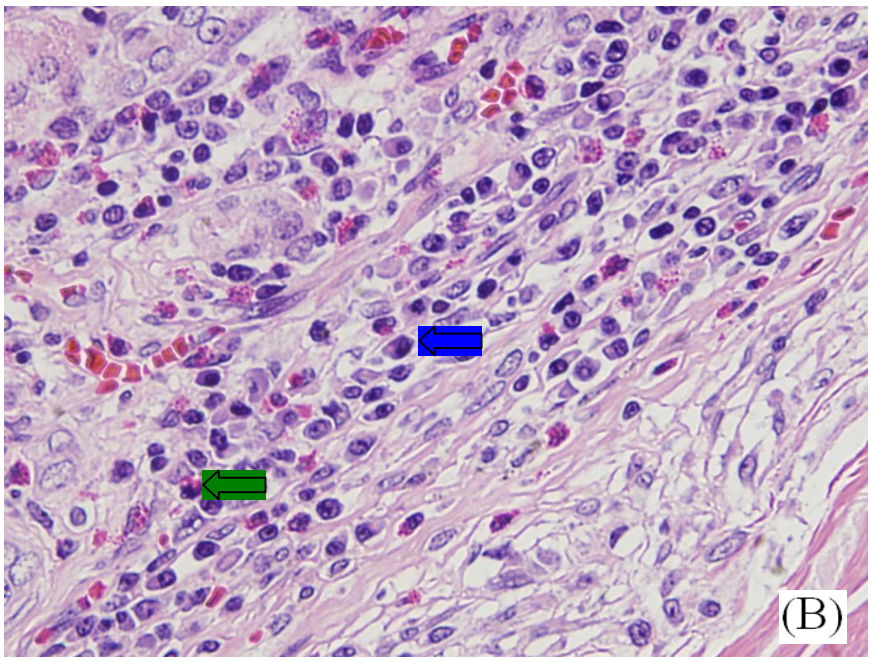

Figure 2. Porcine SIS 2 weeks. (A) Overview of the tissue reaction adjacent to the implanted material demonstrating calcification and giant foreign body cells, blue and green arrows, respectively (H & E, original magnification 200x). (B) A higher magnification of the area indicated by the blue arrow demonstrates neutrophils and the green arrow demonstrates eosinophils (H & E, original magnification 400x).

D. Absorbable gelatin

The reaction was severe with mononuclear inflammatory infiltrates demonstrated by high contents of macrophages and giant foreign body cells. The degree of inflammation in this group was higher compared to that of porcine SIS group. There were higher contents of plasma cells than in the oxidized regenerated cellulose group at the same period.

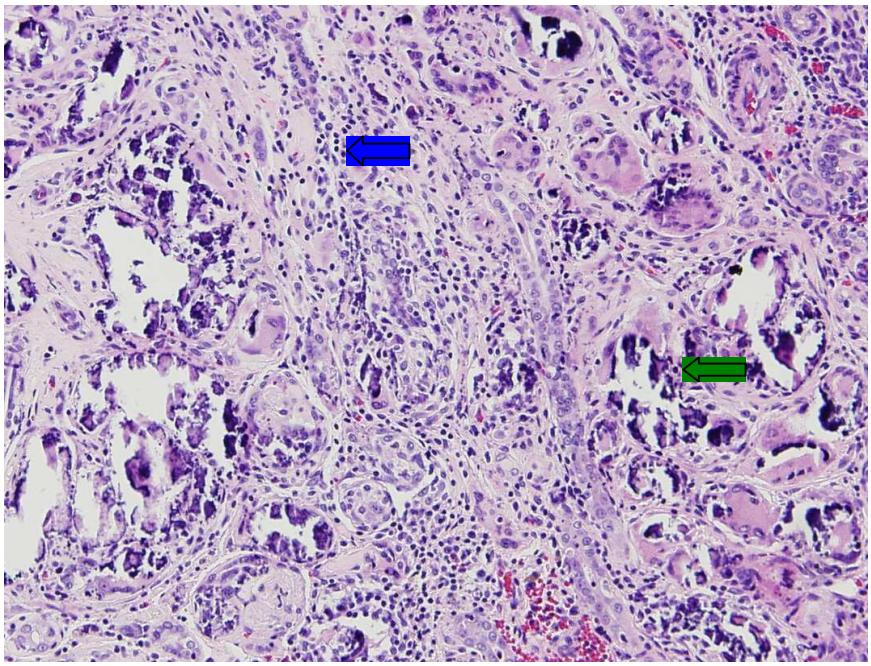

Figure 3. Absorbable gelatin 2 weeks. Overview of the tissue reaction adjacent to the implanted material demonstrating lymphocytes indicated by the blue arrow and calcification indicated by the green arrow (H & E, original magnification 100x).

2. 8-week observations

A. Negative control

The tissue response alongside the lower pole parenchymal defect served as a negative control for the technique. No inflammatory reactions were evident at all observation periods in all specimens.

B. Oxidized regenerated cellulose

There was greater absorption of material and calcification deposits compared to that of 2-week period. Lymphocytes were most predominant among inflammatory infiltrates. The presence and morphology of macrophages and foreign body giant cells adjacent to the material were constant findings.

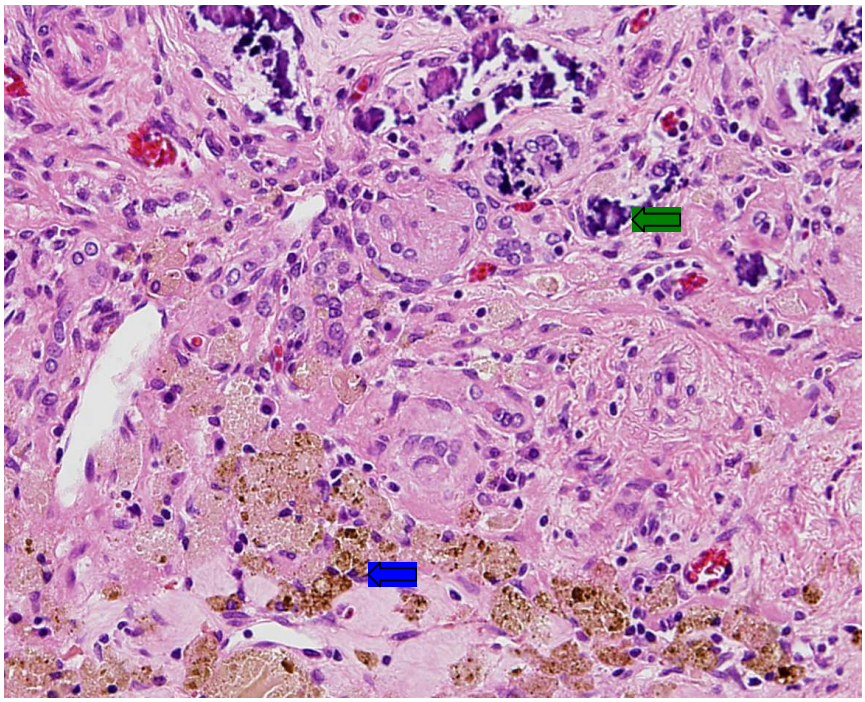

Figure 4. Oxidized regenerated cellulose 8 weeks. Overview of the tissue reaction adjacent to the implanted material demonstrating macrophages indicated by the blue arrow and calcification indicated by the green arrow (H & E, original magnification 200x).

C. Porcine SIS

After 8-weeks, there was greater in-growth of urothelium into the material as demonstrated in figure 5-(D). Besides, the degree inflammation had significantly decreased compared to that of 2-weeks period. Neutrophilic leukocytes diminished by time, however there was no change of calcification or mononuclear inflammatory infiltrates. The increment of plasma cells was a significant finding which was not noted in other materials at the same period. The shape of adjacent host tissue was most well maintained among all experimental groups.

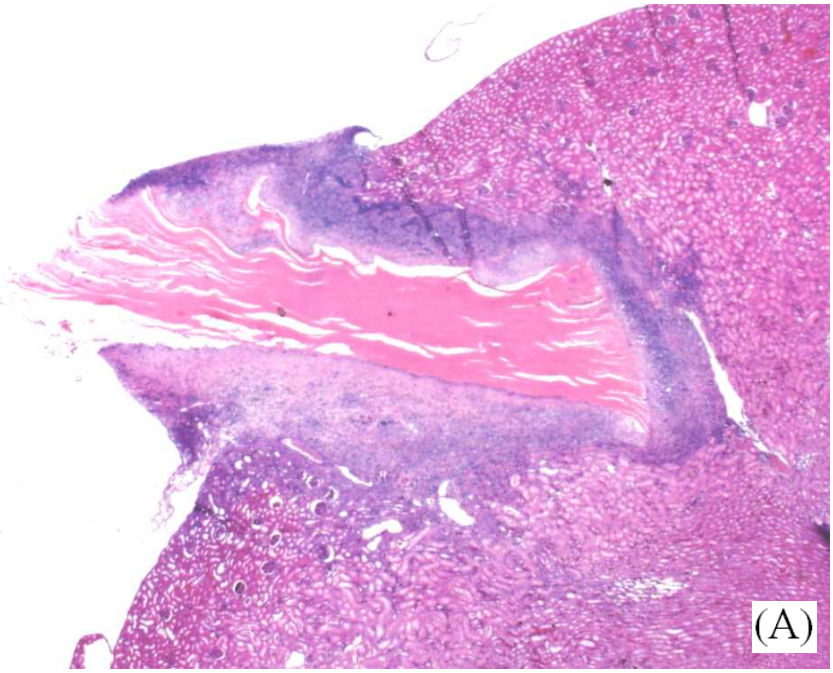

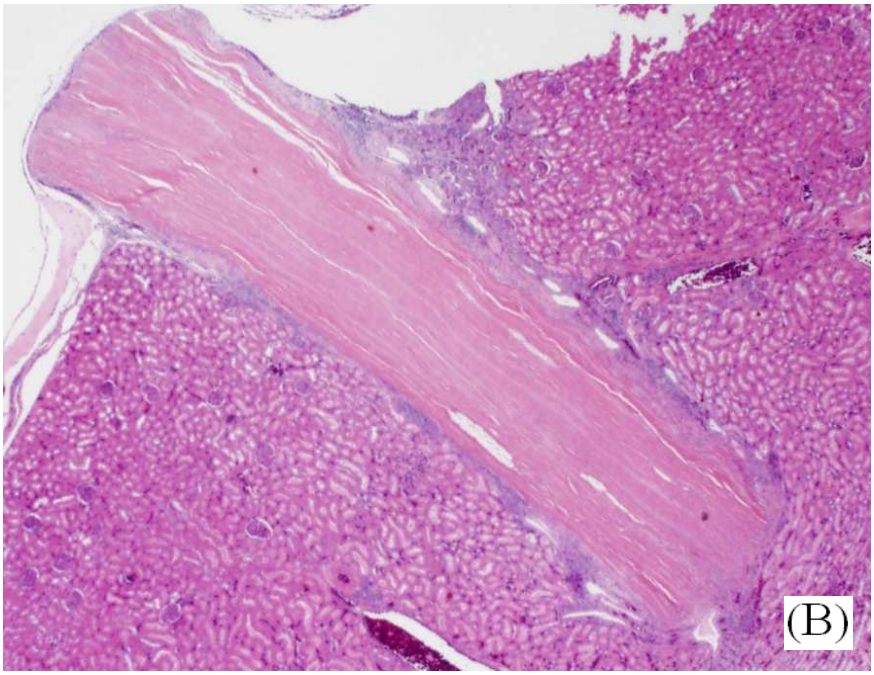
(B)

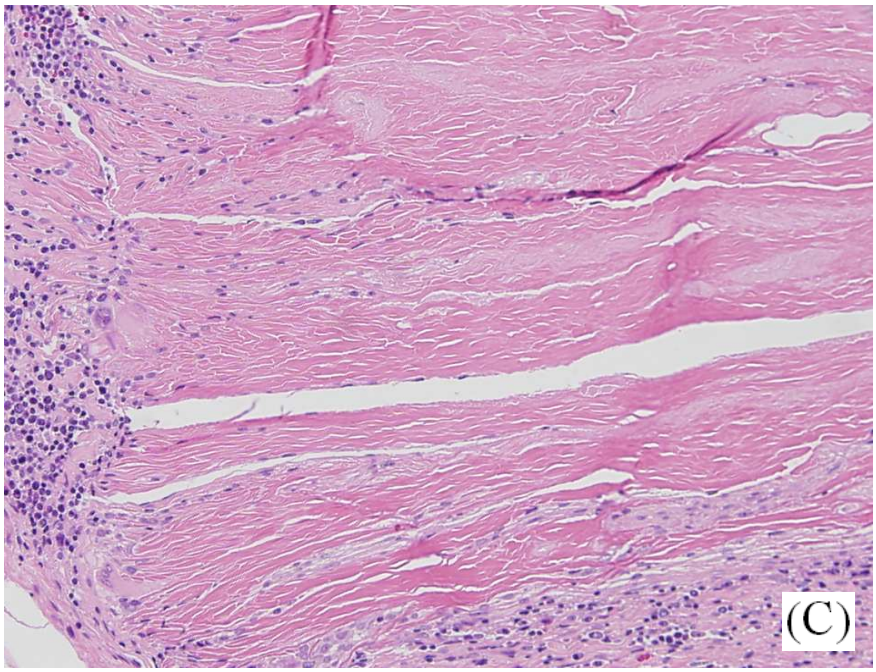
(C)

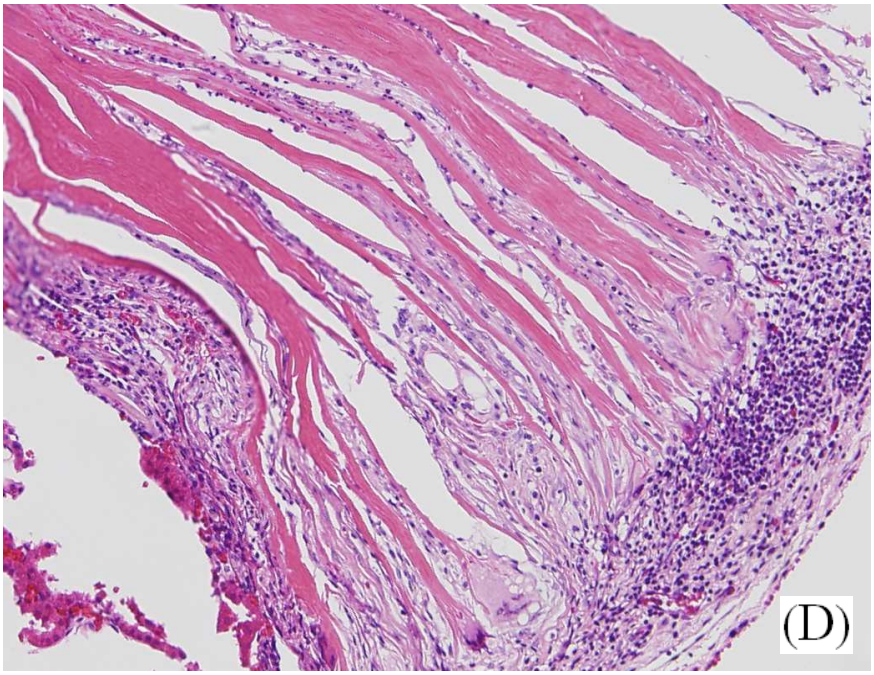
(D)

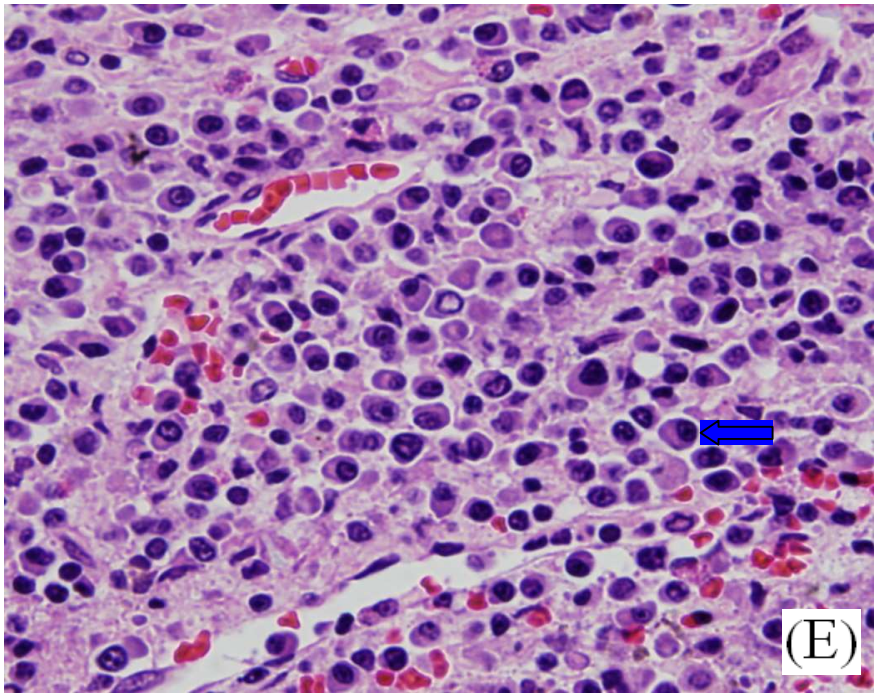
(E)

Figure 5. Comparison of porcine SIS between 2 periods. (A) Porcine SIS 2 weeks. Shows the material-host tissue interface with diverse lymphocytic infiltrations (H & E, original magnification 12.5x). (B) Porcine SIS 8 weeks. Shows strip of lymphocytes interposing between the material and host tissue has become narrow compared to that of 2 weeks (H & E, original magnification 12.5x). (C) Porcine SIS 2 weeks. Demonstrates in-growth of urothelium into the material matrix (H & E, original magnification 200x). (D) Porcine SIS 8 weeks. Demonstrates further in-growth of urothelium into the material matrix (H & E, original magnification 100x). (E) Porcine SIS 8 weeks. A higher magnification of the area indicated by the blue arrow demonstrates plasma cells (H & E, original magnification 400x).

D. Absorbable gelatin

There was significant increase of macrophage formation than at 2-weeks. The degree of plasma cells, calcification, residual material, and extent of inflammatory infiltrates noted at 2-weeks diminished at this period. Compared to other materials, inflammatory reaction of absorbable gelatin was the most severe at both periods.

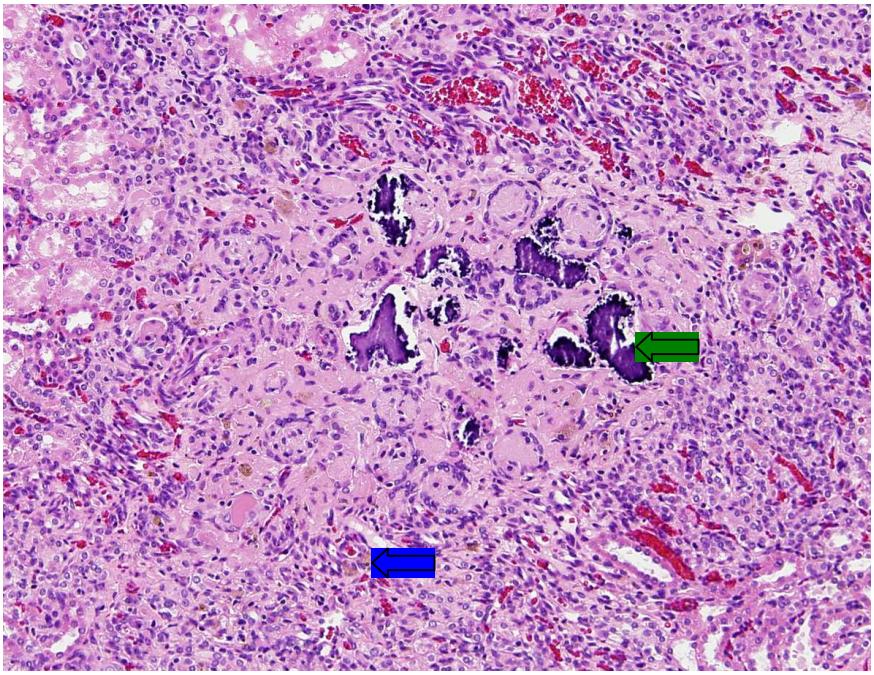

Figure 6. Absorbable gelatin 8 weeks. Overview of the tissue reaction adjacent to the implanted material demonstrating macrophages indicated by the blue arrow and calcification indicated by the green arrow (H & E, original magnification 200x). (H & E, original magnification 100x).

There were no significant statistical differences of inflammatory responses in between oxidized regenerated cellulose, porcine SIS and absorbable gelatin at 2-weeks (p=0.075) and at 8-weeks (p=1.0). In respect to oxidized regenerated cellulose, porcine SIS, and absorbable gelatin there were no significant statistical differences of inflammatory responses according to experimental periods (p=0.161, p=0.259, p=1.0, respectively) (Table 3).

Table 3. Number of renal units and intensity of inflammatory response

Inflammatory response	SIS®		Surgicel®		Gelfoam®	
	2 weeks	8 weeks	2 weeks	8 weeks	2 weeks	8 weeks
No response /slight	0	2	0	1	2	2
Moderate	4	4	5	4	4	4
Severe	2	0	1	1	0	0
Total	6	6	6	6	6	6

IV. DISCUSSION

The number of partial nephrectomy is recently upsurging in line with increased detection of early stage renal parenchymal tumor. Besides, with the advancement of noninvasive radiological imaging techniques, partial nephrectomy has broadened its indications owing to increased detection of incidental and asymptomatic small sized tumor of less than 1 cm in diameter.[5] In 1969 Robson *et al* demonstrated that radical nephrectomy is associated with good oncological and survival outcomes.[6] Partial nephrectomy, since its first introduction in 1887 had to bear with various adverse outcomes such as urinary leakage, fistula, and parenchymal bleeding (1.4%, 17.4%, 7.9%, respectively).[7] However, refinements in the surgical technique of partial nephrectomy and the development of imaging techniques have made this procedure as safe and as effective in tumor control with acceptable complication rates compared to radical nephrectomy. Fergany *et al* described partial nephrectomy as effective as radical nephrectomy for localized renal cell carcinoma, providing long term tumor control with maintenance of renal function.[8] Nam *et al* reported that partial nephrectomy for localized renal cell carcinoma has similar local recurrence and survival rates as to those of radical nephrectomy.[9] For these reasons, the role of partial nephrectomy has become increasingly recognized during the last several years.

Partial nephrectomy has unique characteristics in its surgical technique. It requires that the kidney be reconstructed in a manner that is hemostatic, watertight, and least traumatic to the remaining renal tissue. During the procedure, ischemic time

is one of the most important factors in preserving postoperative renal function. With the renal pedicle controlled to limit blood flow to the kidney it is important that the hemostatic material not only retards bleeding by physical or biochemical means, but also be applied quickly and efficiently.[10] In this context, biosynthetic materials provide a method of minimizing blood loss quickly by covering the raw surface of the kidney and supplying additional hemostasis through compression of exposed vascular structures. Additionally, the risk of parenchymal tearing could be avoided by providing a re-approximation of the remaining renal tissue.[2]

To date, oxidized regenerated cellulose, porcine SIS, and absorbable gelatin are the most widely used biosynthetic hemostatic materials for bolstering defected renal parenchyma. However, no studies have been conducted to compare biological reactions such as degrees of inflammation or hemostatic profiles of these materials when implanted into the renal parenchyma. Therefore, in clinical practice it is only at surgeon's discretion on which material to apply. This animal study was the first of its kind using a histological analysis method to compare biocompatibilities of these materials.

Oxidized regenerated cellulose is a local biosynthetic hemostatic gauze used in a variety of surgical procedures which has been reported to control bleeding by means of a mechanical and chemical bolster.[1] This polyanion, the functional unit termed polyanhydroglucuronic acid is composed of two active components. The soluble uronic acid components diminishes after 6 hours, while the fibrous components

persist.[11] From results of previous experimental animal studies Bornemisza *et al* reported that oxidized regenerated cellulose occludes part of the convoluted tubules and local circulation, however has no substantial effects in renal function deterioration.[12]

Porcine SIS since its approval for human implantation in 1998 has been widely applied in various clinical studies such as for cardiovascular medicine, gastroenterology, dermatology, and orthopedics. Recently, literature has demonstrated promising results as to the use of this material in these anatomical settings. Among them genitourinary reconstruction has been the mainstay for the use of porcine SIS.[13-15] Porcine SIS is a biodegradable, acellular, nonimmunogenic, and xenogenic collagen-based biomaterial derived from the submucosal layer of porcine small intestine. After implantation fast neovascularization, infiltration, and spatial organization for regeneration of urothelial epithelium are the unique characteristics of this material.[13] In aspect of immune reactions, Ansaloni *et al* reported that porcine SIS does not trigger rejection when implanted into the host tissue.[16] There had been various reports on the use of porcine SIS in partial nephrectomy. O'connor *et al* described that during a mean follow-up of 18.4 months, porcine SIS promoted urothelial regrowth without significant postoperative complications such as urinary leakage, fistula or hemorrhage that required transfusion.[2]

Absorbable gelatin is a non-immunogenic water insoluble hemostatic biomaterial widely used in partial nephrectomy. Its hemostatic property is a result of

hemostasis induction from structural support of the thrombus. The efficacy of absorbable gelatin has been proved in gynecological surgery however, there are limited studies on its application in urologic surgery.

This study demonstrated the statistical differences of biocompatibilities in between oxidized regenerated cellulose, porcine SIS, and absorbable gelatin when applied to the renal parenchyma. As mentioned, biosynthetic materials should be biocompatible, dimensionally stable, non-toxic, and non-immune in order to minimize side effects after implantation. Besides, adjacent host tissue size, shape, and durability should be maintained during the healing process.[3] However, most importantly renal function should not be influenced by the implanted biosynthetic material especially in the setting of partial nephrectomy.

There are various methods to compare biocompatibilities of implanted materials. A typical method is to measure the distance between host tissue and implanted material. Another method is to evaluate the interface between host tissue and implanted material to measure the intensity of inflammation.[12] Overall level of inflammatory reaction was graded depending on the amount of neutrophilic leukocytes, macrophages, lymphocytes, plasma cells, giant foreign body cells, dispersed material, necrotic tissue, inflammatory response, and calcification.[4] One independent pathologist blindly evaluated the reactions in this study.

None of the experimental slides showed presence of bacterial colonization. This was consistent with previous clinical studies demonstrating the safe and effective use

of these materials. In most of cases the inflammatory response was observed as none to slight. Severe inflammation was observed in a significantly limited number of cases. According to experimental periods there were no statistically significant inflammatory reaction differences between each group. Due to the fact that there were no differences in inflammatory reactions at the 2-week period, it could be concluded that all biosynthetic materials are similarly biocompatible in the early stages of implantation. In all experimental slides size, shape, and durability of adjacent host tissue were well maintained. According to datasheet, porcine SIS is known to act as a tissue scaffold, allowing re-growth of urothelium and to foster angiogenesis by providing an extracellular matrix during 2 years of regenerative process.[2] However, this process was only partly observed in this study probably due to the short term follow up period of 8 weeks.

In regard to choosing an appropriate biosynthetic material for renal parenchymal reinforcement, there is a broad range of characteristics that should be considered. Biocompatibility has been demonstrated to be the most important factor to be considered because toxic components derived from inflammatory reactions may cause irritation or even deterioration of renal function.[17] Other factors that make biosynthetic materials anatomically and functionally suitable for implantation are ease of surgical handling, placement efficacy, cost competitiveness, and no associated adverse reactions. In this study, there were no differences in degree of inflammatory responses between all materials and only the types of infiltrated inflammatory cells

were variable. Therefore, results from this study indicates that applying oxidized regenerated cellulose, porcine SIS, and absorbable gelatin is a safe and reliable means to reinforce renal parenchyma defects and to control bleeding during renal surgery.

V. CONCLUSION

Oxidized regenerated cellulose, porcine SIS, and absorbable gelatin appears to have no intraparenchymal biocompatibility differences when implanted into rat kidney. Although inflammatory reactions were different between experimental periods, there were no overall significant statistical differences. There were no adverse events associated with the use of these materials. However, the long term efficacy of these materials still remains a question and further follow up will be necessary to establish their long term effects.

REFERENCES

1. Polascik TJ, Pound CR, Meng MV, Partin AW, Marshall FF. Partial nephrectomy: technique, complications and pathological findings. The Journal of urology. 1995;154(4):1312-8.
2. O'Connor RC, Harding JN, Steinberg GD. Novel modification of partial nephrectomy technique using porcine small intestine submucosa. Urology. 2002;60(5):906-9.
3. Sousa CJ, Loyola AM, Versiani MA, Biffi JC, Oliveira RP, Pascon EA. A comparative histological evaluation of the biocompatibility of materials used in apical surgery. International endodontic journal. 2004;37(11):738-48.
4. Recommended standard practices for biological evaluation of dental materials. Fédération Dentaire International, Commission of Dental Materials, Instruments, Equipment and Therapeutics. International Dental Journal. 1980;30(2):140-88.
5. Jayson M, Sanders H. Increased incidence of serendipitously discovered renal cell carcinoma. Urology. 1998;51(2):203-5.
6. Robson CJ, Churchill BM, Anderson W. The results of radical nephrectomy for renal cell carcinoma. 1969. The Journal of urology. 2002;167(2 Pt 2):873-5; discussion 6.
7. Uzzo RG, Novick AC. Nephron sparing surgery for renal tumors:

indications, techniques and outcomes. The Journal of urology. 2001;166(1):6-18.

8. Fergany AF, Hafez KS, Novick AC. Long-term results of nephron sparing surgery for localized renal cell carcinoma: 10-year followup. The Journal of urology. 2000;163(2):442-5.
9. Nam JK, Cha CS, Chung MK. The Treatment Outcomes of a Partial Nephrectomy in the Management of Renal Cell Carcinomas. Korean J Urol. [Journal Articles]. 2004;45(11):1100-5.
10. Hanks JB, Kjaergard HK, Hollingsbee DA. A comparison of the haemostatic effect of Vivostat patient-derived fibrin sealant with oxidised cellulose (Surgicel) in multiple surgical procedures. European surgical research. 2003;35(5):439-44.
11. Pierce AM, Wiebkin OW, Wilson DF. Surgicel: its fate following implantation. Journal of oral pathology. 1984;13(6):661-70.
12. Bornemisza G, Ladányi J, Furka I, Mikó I. Effect of absorbable cellulose on the renal parenchyma. Acta chirurgica Academiae Scientiarum Hungaricae. 1976;17(4):329-33.
13. Kropp BP. Small-intestinal submucosa for bladder augmentation: a review of preclinical studies. World journal of urology. 1998;16(4):262-7.
14. Liatsikos EN, Dinlenc CZ, Kapoor R, Bernardo NO, Pikhasov D,

Anderson AE, et al. Ureteral reconstruction: small intestine submucosa for the management of strictures and defects of the upper third of the ureter. The Journal of urology. 2001;165(5):1719-23.

15. Xie H, Shaffer BS, Wadia Y, Gregory KW. Use of reconstructed small intestine submucosa for urinary tract replacement. ASAIO journal. 2000;46(3):268-72.
16. Ansaloni L, Cambrini P, Catena F, Di Saverio S, Gagliardi S, Gazzotti F, et al. Immune response to small intestinal submucosa (surgisis) implant in humans: preliminary observations. Journal of investigative surgery. 2007;20(4):237-41.
17. Pascon EA, Leonardo MR, Safavi K, Langeland K. Tissue reaction to endodontic materials: methods, criteria, assessment, and observations. Oral surgery, oral medicine and oral pathology. 1991;72(2):222-37.

ABSTRACT IN KOREAN

흰쥐에서 신장 부분 절제술 후 Oxidized Regenerated Cellulose, Porcine Small Intestine Submucosa 및 Absorbable Gelatin 을 삽입 후 생체적합성 비교

<지도교수 양 승 철>

연세대학교 대학원 의학과

구 교 철

부분 신절제술을 시행할 때 술 후 결손부위를 봉합하고 외부적인 압착으로 지혈효과를 얻기 위하여 이용되는 인공삽입물질은 여러 가지 보고되고 있으나 최근 많은 경우에서 oxidized regenerated cellulose (Surgicel®), porcine small intestine submucosa (SIS®) 및 absorbable gelatin (Gelfoam®) 등이 사용되고 있다. 이와 같은 인공삽입물질은 일반적으로 생체적합성, 비독성, 화학적 안정성, 비면역성 등을 갖추어야 함은 물론 치유되면서 숙주 조직의 특성을 변화시키지 않고 주위조직의 고유의 크기, 형태 및 경도가 유지되어야 한다. 또한 술 후 부작용을 최소화 하기 위하여

염증이나 암을 유발하지 말아야 하며 생체 내에서 분해되는 과정 중에 독성물질이 생성되지 않아야 한다.

본 연구에서는 생후 8 주의 Sprague-Dawley 계 흰쥐에서 부분 신절제술 후 인공삽입물질인 oxidized regenerated cellulose, porcine small intestinal submucosa 및 absorbable gelatin 을 삽입하여 급성면역반응기인 2 주와 만성염증반응기인 8 주에 신장 표본을 통한 병리학적인 변화를 측정함으로써 생체적합성을 비교 관찰하였다.

대조군에서는 주위 구조의 변화나 위축 소견 등의 특이 염증 반응은 관찰되지 않았다. 같은 사료, 환경, 시기에 사육된 것으로 이를 통해서 다른 군에서의 염증 반응이 다른 환경적 요인에 의한 것임을 제외시킬 수 있었다. 2 주 염증 반응에서 세 군을 비교한 결과 통계학적으로 유의한 차이는 없었으며 (p=0.075), 8 주 반응에서도 유의한 차이는 없었다 (p=1.0). Oxidized regenerated cellulose, porcine SIS 및 absorbable gelatin 간에 시기별 염증반응을 보았을 때도 유의한 차이는 나타나지 않았다 (p=0.161, p=0.259, p=1.0). 하지만 염증세포를 조직학적으로 단위화하여 분석한 결과 각 군마다 구성 염증세포의 차이가 관찰되었으며 어느 정도 초기의 염증반응이 후기에는 감소하는 것을 알 수 있었다.

본 실험은 신부분절제술시 임상에서 흔히 사용되는 인공삽입물질을 흰쥐의 신장에 삽입하여 생체적합성을 비교 관찰하였다. 이상의 결과에서 생체에서 흡수되는 속도의 차이로

인하여 급성과 만성의 시기의 반응 모양은 모두 달랐으나, 세 가지 물질간의 염증반응의 유의한 차이는 없었다. 결론적으로 세 물질간의 유의한 생체적합성의 차이는 없었다.

핵심되는 말 : 생체적합성, 흰쥐, 신장