Color Doppler imaging of the liver in neonates with biliary atresia

Mu Sook Lee

Department of Medicine

The Graduate School, Yonsei University

Color Doppler imaging of the liver in neonates with biliary atresia

Directed by Professor Myung-Joon Kim

The Master's Thesis
submitted to the Department of Medicine
and the Graduate School of Yonsei University
in partial fulfillment of the requirements for the degree of
Master of Medical Science

Mu Sook Lee

December 2007

This certifies that the Master's Thesis (Doctoral Dissertation) of Mu Sook Lee is approved.

Thesis Supervisor : Myung-Joon Kim

Choon Sik Yoon

Hyoung Woo Park

The Graduate School

Yonsei University

December 2007

ACKNOWLEDGEMENTS

I gratefully acknowledge the presence and guidance of all professors and research instructors in the Department of Diagnostic Radiology and Research Institute of Radiological Science in Yonsei University College of Medicine who made me a better radiologist and researcher.

I especially thank Professor Myung-Joon Kim who directed this thesis with great tolerance and kind reinforcement. I could not take the master's degree without him.

I would also like to thank Professor Choon Sik Yoon and Professor Hyoung Woo Park who examined this thesis. They suggested good advised which were really helpful and played an important role in submitting this thesis.

I am grateful to Professor Seok Joo Han, Professor Jeong Tak Oh, and Professor Young Nyun Park for preparing and planning this study.

Lastly I thank my family and my colleagues.

<TABLE OF CONTENTS>

LIST OF FIGURES

LIST OF TABLES

<ABSTRACT>

Color Doppler imaging of the liver in neonates with biliary atresia

Mu Sook Lee

Department of Medicine

The Graduate School, Yonsei University

(Directed by Professor Myung-Joon Kim)

Purpose : To describe color Doppler flow imaging findings of the liver in neonates with biliary atresia and to compare them with those of non-biliary atresia

Methods and Materials : From March 2003 to July 2007, from patients with confirmed biliary atresia, we selected 29 patients (51±24 days, 3-91 days) who were preoperatively evaluated with color Doppler US. We also performed color Doppler US in 35 patients (48±32 days, 3-150 days) with hyperbilirubinemia who did not have biliary atresia. In ultrasonography, we evaluated triangular cord sign, gall bladder length, and diameter of the portal vein and the hepatic artery. In color

Doppler imaging, we evaluated presence of hepatic subcapsular flow. Sensitivity, specificity, and positive and negative predictive values were calculated for the TC sign in US and hepatic subcapsular flows in color Doppler imaging. The Mann-Whitney test was used to evaluate differences in the mean diameters of the portal vein and hepatic artery between patients with biliary atresia and non-biliary atresia.

Results : In color Doppler images, all patients with biliary atresia demonstrated hepatic subcapsular flow. Among the 35 patients with non-biliary atresia, 30 did not have hepatic subcapsular flow (sensitivity 100%, specificity 85%, positive predictive value 85%, negative predictive value 100%). There was no difference in portal vein diameter between biliary atresia and non-biliary atresia groups. However, there was a statistically significant difference in hepatic artery diameter between the two groups (2.10±0.65mm vs 1.45±0.41 mm, $p < .05$).

Conclusion : The presence of hepatic subcapsular flow is useful to differentiate biliary atresia from other cause of neonatal jaundice.

Key words : Color Doppler imaging, biliary atresia, hepatic subcapsular flow

Color Doppler imaging of the liver in neonates with biliary atresia

Mu Sook Lee

Department of Medicine

The Graduate School, Yonsei University

(Directed by Professor Myung-Joon Kim)

I. INTRODUCTION

Unconjugated hyperbilirubinemia is a normal physiologic condition that occurs in approximately 60% of normal full-term infants and in 80% of pre-term infants. However, onset of jaundice within the first 24 hours of life, rate of rise of serum bilirubin levels greater than 5mg/dL in 24 hours, direct bilirubin level greater than 1mg/dL at any time, or persistence or new onset of jaundice in infants 2 weeks of age or older may indicate pathology.[1]

There are many causes of neonatal jaundice. Most cholestatic conditions can be

classified as either obstructive or hepatocellular in origin. Obstructive cholestasis results from anatomic or functional obstruction of the biliary system. Biliary atresia accounts for more than 90% of cases of obstructive cholestasis. Hepatocellular cholestasis results from impairment of bile formation and implies defective functioning of most or all hepatocytes. Idiopathic neonatal hepatitis accounts for the majority of hepatocellular cholestasis cases. When assessing neonatal cholestasis, it is important to differentiate obstructive from hepatocellular cholestasis because the former requires surgical correction whereas the latter necessitates medical treatment.[2] However, it is difficult to distinguish these diseases because they share similar clinical symptoms and biochemical and histological findings.[3]

In these cases, high-resolution real-time ultrasonography (US) serves as the first-line screening tool in discovering the cause of jaundice.

The presence of a triangular cord (TC) sign and abnormal gall bladder (GB) in high-resolution real-time US is widely accepted diagnostic criteria for biliary atresia.[4] However, the TC sign cannot be found in every patient, and it is largely dependent on the operator's techniques and experience. Furthermore, it would be difficult to visualize if the infant has hepatic maldevelopment or if the resolution of the ultrasonic apparatus is poor.[5] Positive predictive value in the diagnosis of biliary atresia is 100% when a positive TC sign is coupled with an abnormal gall bladder.[4]

Histologically, biliary atresia is characterized by portal tract inflammation, a small

cell infiltrate, and bile duct plugging and proliferation. In later stages, bridging fibrosis gives way to features of overt biliary cirrhosis.[6] Interestingly, the hyperplastic and hypertrophic changes in branches of the hepatic artery were observed in patients with biliary atresia.[7] On US examination, the diameter of the hepatic artery was larger in patients with biliary atresia than in the non-biliary atresia and control groups.[8, 9]

To our knowledge, there were no reports about hepatic subcapsular flow in biliary atresia.

The purpose of our study is to describe color Doppler imaging findings of the liver in neonates with biliary atresia and to compare them with those with non-biliary atresia.

.

II. MATERIALS AND METHODS

From March 2003 to July 2007, from patients with confirmed biliary atresia, we selected 29 patients (51±24 days, 3-91 days) who were preoperatively evaluated with color Doppler US. The patients included 17 boys and 12 girls. We also performed color Doppler US in 35 patients (48±32 days, 3-150 days) with hyperbilirubinemia who did not have biliary atresia. The patients included 26 boys and nine girls. Their clinical diagnoses were as follows: neonatal hepatitis (n=8), total parenteral nutrition (TPN) induced cholestasis (n=6), Alagille syndrome (n=2), non-syndromic paucity of interlobular bile duct (PIBD) (n=5), portal vein thrombosis (n=1), and idiopathic hyperbilirubinemia (n=13).

All patients underwent US with the use of curved linear (5-8 MHz) and linear (5-12 MHz) transducers (HDI 5000 and iU 22: Phillips, Bothell, Washington, USA). We evaluated the thickness of the echogenic anterior wall of the right portal vein (EARPV) as well as gall bladder (GB) length with a longitudinal scan. We also evaluated the diameter of the portal vein at the level of the proximal portion of the right portal vein and diameter of the hepatic artery at the level of the proximal right hepatic artery, which runs parallel to the right portal vein.

After completion of US, all patients underwent color Doppler imaging (pulse repetition frequency, 1200-1500 Hz: power gain percentage, 82%-92%: medium flow velocity: medium wall filter). On transverse scan, the color box was positioned on the

anterior surface around the falciform ligament.

All patients with biliary atresia underwent the Kasai operation. Ten patients with non-biliary atresia underwent open or laparoscopic liver biopsies. When the Kasai operation or liver biopsy was performed, the surgeon examined the liver surface carefully and noted the presence of hepatic subcapsular telangiectasia. During histopathologic examination, some of the grossly confirmed hepatic subcapsular telangiectatic vessels were evaluated with a microscope.

Levels of total and direct serum bilirubin were checked in all patients.

Sensitivity, specificity, and positive and negative predictive values were calculated for TC sign in US and hepatic surface flows in color Doppler imaging.

The incomplete sample *t* test was used to compare levels of total bilirubin and direct bilirubin between patients with biliary atresia and non-biliary atresia. The Mann-Whitney test was used to evaluate differences in the mean diameters of the portal vein and hepatic artery between patients with biliary atresia and non-biliary atresia. A two-tailed p value of less than 0.05 was considered to indicate a statistically significant difference with all tests. Data analyses were performed with a statistical software package (SPSS, version 12; SPSS, Chicago, III).

III. RESULTS

Although a total of 64 patients had neonatal jaundice, there was no significant difference (p>0.05) in levels of total and direct serum bilirubin between the groups (Table 1).

Table. 1 Patients characteristics at time of US assessment

Characteristics	Biliary atresia (n=29)	Non-biliary atresia (n=35)
Age (day)	51±24 (3-91)	48±32 (3-150)
Male to female ratio	17 : 12	26 : 9
Total bilirubin (mg/dL)*	8.66±2.10 (4.1-12.6)	8.29±4.61 (2.7-28.3)
Direct bilirubin (mg/dL)†	6.29±2.25 (1.5-9.5)	5.10±4.25 (0.6-21.7)

* $p = 0.73$

† $p = 0.24$

In all patients with biliary atresia (n=29), the diagnosis was confirmed at surgery and at subsequent histologic examination. All patients with biliary atresia underwent the Kasai operation, and one patient underwent liver transplantation after the Kasai operation.

In the 35 patients with non-biliary atresia, a variety of diagnoses were determined (Table 2). Ten patients with non-biliary atresia underwent liver biopsies, and their diagnoses were as follows: non-syndromic PIBD (n=5), neonatal hepatitis (n=3), Alagille syndrome (n=1), and TPN induced cholestasis (n=1). All patients with non-biliary atresia were followed up for a median of 13 months (ranges, 2-15 months). Their clinical courses were varied: completely resolved jaundice (n=16), decreased bilirubin level (n=15), increased bilirubin level (n=2), and death (n=2) (each had non-syndromic PIBD and TPN induced cholestasis).

Table. 2 Clinical diagnoses of 35 patients with non-biliary atresia

Diagnosis	Number of patients
Neonatal hepatitis	8
TPN[1] induced cholestasis	6
Non-syndromic PIBD[2]	5
Allagile syndrome	2
Portal vein thrombosis	1
Idiopathic hyperbilirubinemia	13

[1] Total parenteral nutrition

[2] Paucity of interlobular bile duct

There were several different US and color Doppler imaging findings between patients with biliary atresia and non-biliary atresia. (Table. 3) At US, the sole criterion for the TC sign was the EARPV thickness of more than 4mm on a longitudinal scan.[10] Eighteen patients with biliary atresia had positive sonographic TC sign, and 11 patients with biliary atresia showed diffuse periportal echogenicity which was not sufficient for positive TC sign (3.45±0.32mm, 2.80-3.90mm). All patients with non-biliary atresia did not have TC sign. But 12 patients with non-biliary atresia had some periportal echogenicity (2.45±0.67mm, 1.70-3.60mm). According to our result, TC sign provided sensitivity of 62% and specificity of 100%. (Table. 4)

The mean GB length was 1.54±0.77mm (0.60-2.60mm) in patients with biliary atresia and 2.07±0.63mm (0.70-3.70mm) in non-biliary atresia. GB with greatest length of at least 1.5cm was considered to be normal in size.[11] In regard to this US criteria, the GB was small in 15 patients with biliary atresia and in 6 patients with non-biliary atresia. GB was not visualized because of atretic change or contraction in 4 patients with biliary atresia and in 3 patients with non-biliary atresia. Normal or elongated GB was seen in 10 patients with biliary atresia and in 26 patients with non-biliary atresia.

Table. 3 US and color Doppler imaging features in 29 patients with biliary atresia and 35 patients with non-biliary atresia

Imaging features	Biliary atresia (n=29)	Non-biliary atresia (n=35)
TC sign[1]		
Positive[2]	18	0
Negative	11	35
GB length[3]		
< 1.5cm	19	9
≥1.5cm	10	26
Hepatic subcapsular flow		
Present	29	5
Absent	0	30

[1] Triangular cord sign

[2] Positive TC sign means that the thickness of the echogenic anterior wall of the right portal vein is larger than 4mm.

[3] Gall bladder length

Table. 4 Us and color Doppler imaging features as predictor of biliary atresia

Imaging features	Sensivity(%)	Specificity(%)	Positive predictive value(%)	Negative predictive value(%)
TC[1] sign	62	100	100	76
Hepatic subcapsular flow	100	86	85	100

[1] Triangular cord sign

There was no difference in portal vein diameter between biliary atresia and non-biliary atresia groups. However, there was a statistically significant difference in hepatic artery diameter between the two groups (p <0.05) (Table 5).

Table. 5 Diameter[1] of portal vein and hepatic artery in patients with biliary atresia and in those with non-biliary atresia

	Biliary atresia (n=29)	Non-biliary atresia (n=35)
Diameter of portal vein*	4.29±0.78 (3.00-6.00)	3.91±0.80 (2.30-5.40)
Diameter of hepatic artery†	2.10±0.65 (1.30-3.30)	1.45±0.41 (0.70-2.10)

[1] In mm, and data are means±standard, with ranges in parentheses

* $p = 0.085$

† $p = 0.000$

In color Doppler images, all patients with biliary atresia demonstrated hepatic arterial flow extending to the hepatic surface (Figures 1, 2, 3).

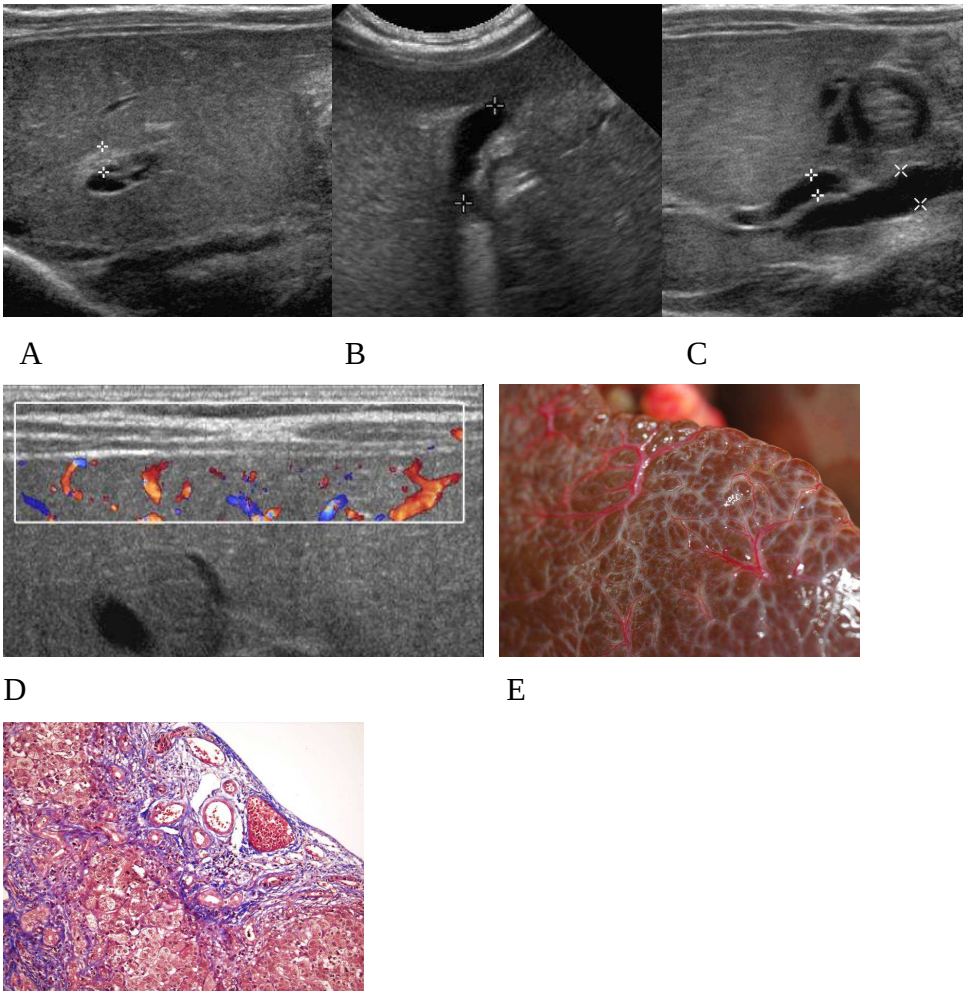

Figure 1. . Ultrasonographic and color Doppler imaging findings of biliary atresia. (A) Thickness of the echogenic anterior wall of the right portal vein was 4mm, which is regarded as a positive triangular cord sign. (B) Gall bladder length was 1.6cm. (C) Diameter of the right proximal hepatic artery (+) was 3.0mm, and portal vein (×) was 5.0mm. (D) Hepatic subcapsular flow was seen in color Doppler imaging. (E) On the

Kasai operation field, the liver showed a nodular and cirrhotic surface and telangiectatic vessels. (F) On microscopic examination, dilated hepatic arteries were seen in the hepatic subcapsular area.

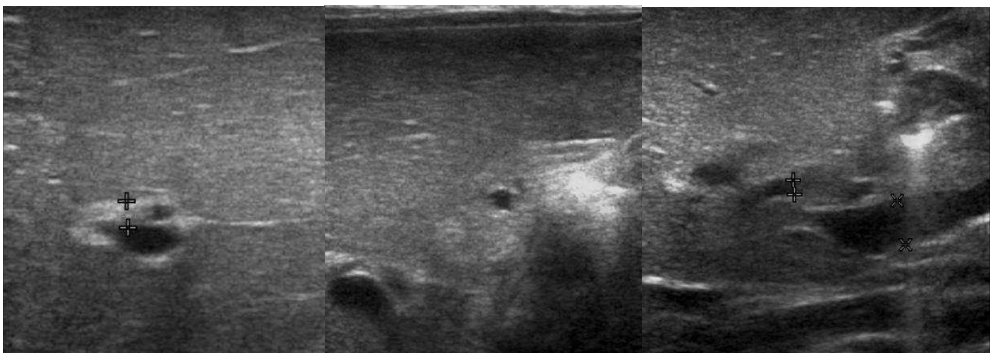

A B C

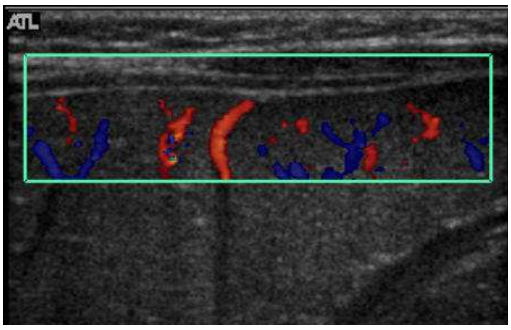

D

Figure 2. Ultrasonographic and color Doppler imaging findings of biliary atresia. (A) Thickness of the echogenic anterior wall of the right portal vein was 2.8mm, which is regarded as a negative triangular cord sign. (B) Gall bladder length could not be

measured because of atretic change. (C) Diameter of the right proximal hepatic artery (+) was 1.5mm, and portal vein (×) was 4.8mm. (D) Hepatic subcapsular flow was seen in color Doppler imaging. Hepatic subcapsular telangiectasia was seen in the Kasai operation.

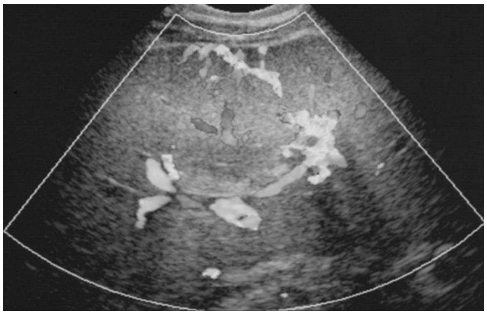

A

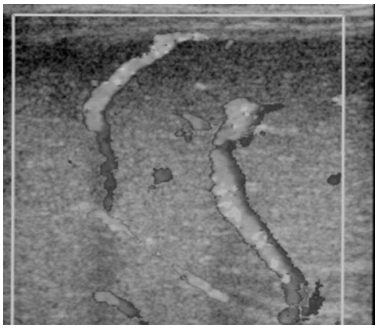

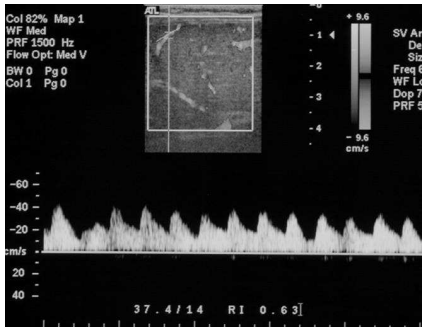

B C

Figure 3. Color Doppler imaging findings of patients with biliary atresia. (A, B) There was hepatic arterial flow that extended to the hepatic surface on color Doppler imaging. (C) Arterial wave form was seen in the enlarged vessel at the hepatic surface.

Among the 35 patients with non-biliary atresia, 30 did not have hepatic subcapsular flow (Figure 4).

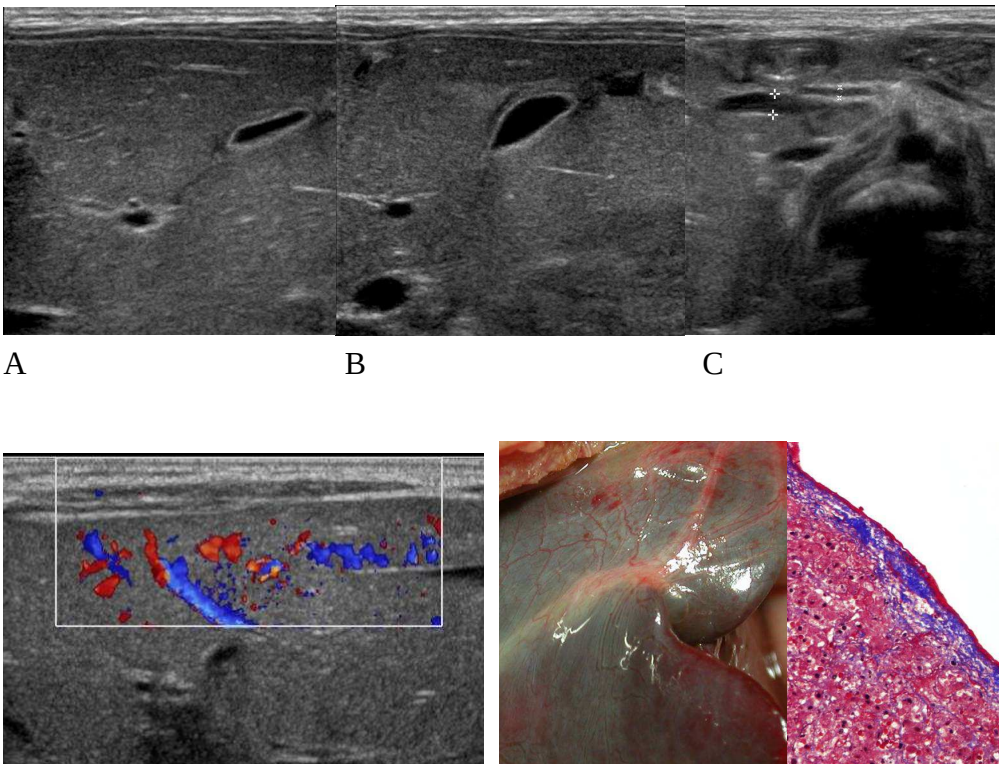

Figure 4. Ultrasonographic and color Doppler imaging findings of non-biliary atresia. (A) There was no periportal thickening. (B) Gall bladder length was 1.4cm. (C) Diameter of the right proximal hepatic artery (×) was 1.0mm, and portal vein (+) was 3.0mm. (D) There was no hepatic subcapsular flow in color Doppler imaging. (E) On open liver biopsy, the liver showed a normal surface. (F) On microscopic examination,

there were no subcapsular telangiectatic vessels. This patient was confirmed to have non-syndromic paucity of the intralobular bile duct.

Five patients with non-biliary atresia had hepatic subcapsular flow; four patients had a history of total parenteral nutrition (TPN) for more than 6 weeks (Figure 5), and one was confirmed to have CMV hepatitis.

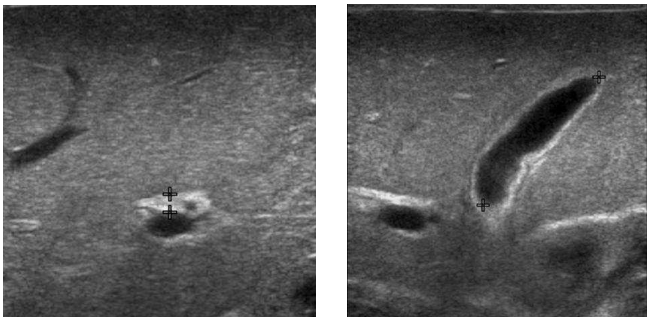

A B

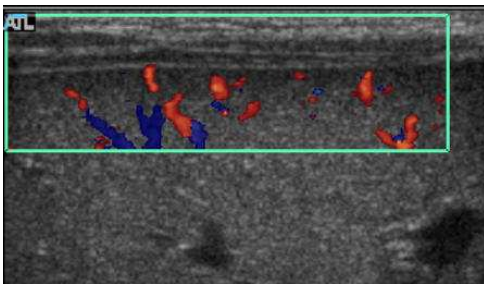

C

Figure 5. Ultrasonographic and color Doppler imaging findings of non-biliary atresia. (A) Thickness of the echogenic anterior wall of the right portal vein was 2.0mm, which is regarded as a negative triangular cord sign. (B) Gall bladder length was 2.2cm. (C) Hepatic subcapsular flow was seen in color Doppler imaging. This patient received total parenteral nutrition for more than 6 weeks.

Hepatic subcapsular flow provided a sensitivity of 100% and specificity of 86% (Table 4).

At surgery, subcapsular telangiectasia was seen in all patients with biliary atresia (Figure 1). Among the 35 patients with non-biliary atresia, 10 patients underwent laparoscopic or open liver biopsies. None of the 10 patients had subcapsular telangiectasia, with the exception of one who had neonatal hepatitis.

IV. DISCUSSION

The presence of the TC sign in US is a widely accepted diagnostic criteria for biliary atresia.[4] According to Lee *et al*., use of 4mm thickness as a criterion for the TC sign in the diagnosis of biliary atresia resulted in a sensitivity of 80%, a specificity of 98%, a positive predictive value of 94%, a negative predictive value of 94%, and an accuracy of 94%.[10] However, recent papers by Kim *et al*. and Hemphrey *et al*. reported sensitivities of the TC sign for diagnosis of biliary atresia to be 58% and 73%.[8, 9] According to a report by Tan Kendrick *et al*., the fibrotic cord can be easily masked when diffuse periportal echogenicity due to non-specific inflammation or cirrhosis is present. Therefore, the TC sign is supportive but not as sensitive when cirrhosis or widespread periportal inflammation is present.[12] In our study, only 18 of 29 patients with pathologically confirmed biliary atresia had positive TC signs (sensitivity of 62% and specificity of 100%) (Table 4). Like the report by Kim *et al*., our results showed that the TC sign was less sensitive for the diagnosis of biliary atresia.

After Stowens described hyperplastic and hypertrophic changes in the branches of the hepatic artery in the intrahepatic portal areas of patients with biliary atresia,[13] there were several reports about hepatic arterial changes in biliary atresia.[7, 14] According to Uflaker *et al*., the presence of angiographically demonstrable perivascular arterial tufts in the periphery of the hepatic arterial circulation is

common in cases of biliary atresia, and may be characteristic angiographic findings for the diagnosis of biliary atresia.[15] According to Kim *et al*. and Hemphrey *et al*., the diameter of the hepatic artery was significantly larger in the biliary atresia group than that in the non-biliary atresia and control groups.[8, 9] In our results, the diameter of the hepatic artery was significantly larger in patients with biliary atresia than in those with non-biliary atresia (p <0.05). Portal vein diameter was not significantly different between patients with biliary atresia and those with non-biliary atresia (p >0.05) (Table 5).

In addition to the enlarged hepatic artery, hepatic arterial flow extending to the hepatic surface, as visualized by color Doppler imaging, was seen in all patients with biliary atresia.

This hepatic subcapsular flow showed a sensitivity of 100%, a specificity of 86% and positive and negative predictive values of 85% and 100% (Table 4). All patients with biliary atresia who demonstrated hepatic subcapsular flow in color Doppler imaging showed subcapsular telangiectatic vessels at the time of the Kasai operation. On microscopic examination, we confirmed dilated vessels in the hepatic subcapsular area, which seemed to be hypertrophic hepatic arteries.

The pathogenesis of hepatic arteriopathy in biliary atresia is unknown. It may be a secondary effect or could be related to the pathogenesis of biliary atresia.[14] During liver development, the intrahepatic bile ducts develop from the layer of hepatoblasts

surrounding the portal vein branches.[16] Between 9 and 12 weeks of gestation, a layer of hepatoblasts surrounds the future portal tract in a cylindrical fashion and becomes the ductal plate, which is considered to be the embryological biliary structure. After the ductal plate forms, three phases of remodeling occur. The first phase consists of the development of periportal tubules. The second phase consists of the appearance of a branch of the hepatic artery in the periportal mesenchyme. The third phase involves the incorporation of the peripheral tubules into the periportal mesenchyme.[17] The third phase of the remodeling process of bile duct development is important for the normal formation of the intrahepatic bile duct.[16] Arterial branch development precedes the incorporation of the tubular part of the ductal plate. There is a close spatio-temporal relationship between the development of the intrahepatic arterial branches and the development of the maturely shaped, tubular intrahepatic bile duct.[16]

Because of this embryological development pattern, it is not surprising that maldevelopment of the intrahepatic bile duct is accompanied by anomalies of the vessels, such as hyperplasia and hypertrophy of the hepatic artery branches. Patients with biliary atresia have an intrahepatic bile duct in its primitive embryonic shape, which indicates a disturbance in the remodeling of the ductal plate.[17] Therefore, the hepatic arteriopathy in patients with biliary atresia can be explained by faulty

embryological development.

However, among the 35 patients with non-biliary atresia, five patients revealed hepatic subcapsular flow. Among them, four patients were thought to have TPN-induced cholestasis, and the remaining patient was confirmed to have CMV hepatitis. Histopathologic results from the liver biopsy of one patient who received TPN for 10 weeks revealed ductular and hepatocyte cholestasis with portal fibrosis and ductular proliferation. These pathologic results were similar to those of biliary atresia and also had been reported in TPN induced cholestasis.[17, 18] The results could also explain the reason for why our four patients who received TPN for more than 6 weeks had hepatic subcapsular flow in color Doppler imaging.

V. CONCLUSION

Hepatic arterial flow extending to the hepatic surface in color Doppler imaging showed high sensitivity and relatively low specificity for the diagnosis of biliary atresia. The TC sign showed low sensitivity and high specificity in our study. Most patients who were negative for the TC sign but positive for hepatic subcapsular flow were pathologically confirmed to have biliary atresia. Therefore, hepatic subcapsular flow in color Doppler imaging can be a helpful feature for the diagnosis of biliary atresia when the TC sign is negative.

This color Doppler imaging finding may reflect hyperplasia and hypertrophy of the hepatic artery in biliary atresia, which are associated with the significant difference in hepatic artery measurements using US.

REFERENCES

1. Gubernick JA, Rosenberg HK, Ilaslan H, Kessler A. US approach to jaundice in infants and children. Radiographics 2000 Jan-Feb;20(1):173-95.

2. Emerick KM, Whitington PF. Neonatal liver disease. Pediatr Ann 2006 Apr;35(4):280-6.

3. Kim MJ, Park YN, Han SJ, Yoon CS, Yoo HS, Hwang EH, et al. Biliary atresia in neonates and infants: triangular area of high signal intensity in the porta hepatis at T2-weighted MR cholangiography with US and histopathologic correlation. Radiology 2000 May;215(2):395-401.

4. Park WH, Choi SO, Lee HJ. The ultrasonographic 'triangular cord' coupled with gallbladder images in the diagnostic prediction of biliary atresia from infantile intrahepatic cholestasis. J Pediatr Surg 1999 Nov;34(11):1706-10.

5. Tang ST, Ruan QL, Cao ZQ, Mao YZ, Wang Y, Li SW. Diagnosis and treatment of biliary atresia: a retrospective study. Hepatobiliary Pancreat Dis Int 2005 Feb;4(1):108-12.

6. Davenport M. Biliary atresia: outcome and management. Indian J Pediatr 2006 Sep;73(9):825-8.

7. Ho CW, Shioda K, Shirasaki K, Takahashi S, Tokimatsu S, Maeda K. The pathogenesis of biliary atresia: a morphological study of the hepatobiliary system and the hepatic artery. J Pediatr Gastroenterol Nutr 1993 Jan;16(1):53-60.

8. Kim WS, Cheon JE, Youn BJ, Yoo SY, Kim WY, Kim IO, et al. Hepatic Arterial Diameter Measured with US: Adjunct for US Diagnosis of Biliary Atresia. Radiology 2007 Sep 21.

9. Humphrey TM, Stringer MD. Biliary atresia: US diagnosis. Radiology 2007 Sep;244(3):845-51.

10. Lee HJ, Lee SM, Park WH, Choi SO. Objective criteria of triangular cord sign in biliary atresia on US scans. Radiology 2003 Nov;229(2):395-400.

11. Kirks DR, Coleman RE, Filston HC, Rosenberg ER, Merten DF. An imaging

approach to persistent neonatal jaundice. AJR Am J Roentgenol 1984 Mar;142(3):461-5.
12. Tan Kendrick AP, Phua KB, Ooi BC, Tan CE. Biliary atresia: making the diagnosis by the gallbladder ghost triad. Pediatr Radiol 2003 May;33(5):311-5.
13. Stowens D. Congenital Biliary Atresia. Ann N Y Acad Sci 1963 Dec 30;111:337-57.
14. dos Santos JL, da Silveira TR, da Silva VD, Cerski CT, Wagner MB. Medial thickening of hepatic artery branches in biliary atresia. A morphometric study. J Pediatr Surg 2005 Apr;40(4):637-42.
15. Uflacker R, Pariente DM. Angiographic findings in biliary atresia. Cardiovasc Intervent Radiol 2004 Sep-Oct;27(5):486-90.
16. Libbrecht L, Cassiman D, Desmet V, Roskams T. The correlation between portal myofibroblasts and development of intrahepatic bile ducts and arterial branches in human liver. Liver 2002 Jun;22(3):252-8.
17. Desmet VJ, Leuven KU. Pathogenesis of ductal plate malformation. Journal of Gatroenterology and Hepatology 2004;19:S356-S60.
18. Buchman AL, Iyer K, Fryer J. Parenteral nutrition-associated liver disease and the role for isolated intestine and intestine/liver transplantation. Hepatology 2006 Jan;43(1):9-19.

국문 요약(IN KOREAN)

담도 폐쇄 환아의 간의 색 도플러 영상

<지도교수 김명준>

연세대학교 대학원 의학과

이무숙

목적 : 담도 폐쇄 환아의 간의 색 도플러 영상 소견을 기술하고 이를 비 담도 폐쇄 환아의 색 도플러 영상 소견과 비교한다.

방법 : 2003년 3월부터 2007년 8월까지 병리학적으로 담도 폐쇄로 진단받은 환아 29명 (평균 나이, 51±24일, 3-91일)과 비 담도 폐쇄로 진단받은 환아 35명(48±32일, 3-150일)을 선택하였다. 초음파 검사상에서 triangular cord sign의 유무를 검사하였고, 담낭의 길이, 그리고 간문맥과 간동맥의 직경을 측정하였다. 색 도플러 영상에서 간의 피막 하 혈류의 유무를 검사하였다. 초음파 검사상의 triangular cord sign과 색 도플러 영상의 간의 피막 하 혈류 유무의 진단적 가치에 대해서 민감도, 특이도, 양성 예측도와 음성 예측도를 각각 측정하였다. 두 집단간의 간 문맥과 간 동맥의 직경의 차이는 Mann-Whitney test을

이용하여 통계학적 유의성을 비교하였다.

결과 : 모든 담도 폐쇄 환아는 색 도플러 영상에서 간의 피막 하 혈류를 보였다. 35명의 비 담도 폐쇄 환아 중 30명에서는 간의 피막 하 혈류가 보이지 않았으나 5명의 환아 에서는 간의 피막 하 혈류가 관찰되었다. (민감도 100%, 특이도 86%, 양성 예측도 85%, 음성 예측도 100%). 담도 폐쇄 환아 군과 비 담도 폐쇄 환아군 사이의 간 동맥의 직경은 통계학적으로 유의한 차이를 보였다. (평균±표준 편차, 2.10±0.65mm 대 1.45±0.41mm, $p<0.05$)

결론 : 색 도플러 영상에서 간의 피막 하 혈류의 존재는 담도 폐쇄와 다른 신생아 황달의 원인을 구별 하는데 도움이 된다.

핵심 되는 말 : 담도 폐쇄, 색 도플러 영상, 간의 피막 하 혈류