An anatomic study of the definite muscle fibers from the buccinator extending into the terminal portion of parotid duct; its role with functional aspects in saliva secretion

Hyo-Chang Kang, D.D.S., M.S.

Department of Dentistry
The Graduate School, Yonsei University

An anatomic study of the definite muscle fibers from the buccinator extending into the terminal portion of parotid duct; its role with functional aspects in saliva secretion

Hyo-Chang Kang, D.D.S., M.S.

Department of Dentistry
The Graduate School, Yonsei University

An anatomic study of the definite muscle fibers from the buccinator extending into the terminal portion of parotid duct; its role with functional aspects in saliva secretion

Directed by Professor Hee-Jin Kim, D.D.S., Ph.D.

The Doctoral Dissertation
submitted to the Department of Dentistry,
the Graduate School of Yonsei University
in partial fulfillment of the requirements for the degree of
Doctor of Philosophy.

Hyo-Chang Kang, D.D.S., M.S.

June 2005

This certifies that the Doctoral Dissertation of Hyo-Chang Kang is approved.

Thesis Supervisor : **Prof. Hee-Jin Kim**

Thesis Committee Member : **Prof. Han-Sung Jung**

Thesis Committee Member : **Prof. Kwang-Kyun Park**

Thesis Committee Member : **Prof. Ki-Seok Koh**

Thesis Committee Member : **Prof. Seung-Ho Han**

The Graduate School

Yonsei University

June 2005

Acknowledgements

I appreciate professor Hee-Jin Kim, D.D.S., Ph.D., division in anatomy & developmental biology, department of oral biology, Yonsei university dental college. He supervised and encouraged me to study this subject.

Table of Contents

List of Figures

List of Tables

ABSTRACT

An anatomic study of the definite muscle fibers from the buccinator extending into the terminal portion of parotid duct; its role with functional aspects in saliva secretion

Hyo-Chang Kang, D.D.S., M.S.

Department of Dentistry, The Graduate School, Yonsei University
(Directed by Professor Hee-Jin Kim, D.D.S., Ph.D.)

It is well known that the parotid duct pierces the buccinator, and then runs obliquely forward for a short distance between the buccinator and the mucous membrane of the oral cavity. However, there are no conclusive anatomic reports on the area that the parotid duct pierces the buccinator. I performed an anatomic and histologic examination on the relationships between the parotid duct and the buccinator. Thirty buccinator including the terminal portion of the parotid duct were obtained from the embalmed and fresh Korean cadavers. The dissection was performed on 22 specimens and 8 specimens were prepared histological sections and stained with hematoxylin-eosin and Gomori trichrome.

Small, distinct muscle fibers originated from the buccinator extended and inserted into the terminal portion of the parotid duct. These fibers were observed in all cases constantly. However, the running aspects of the muscle fibers varied and were classified into three different categories according to the origin of the fibers. Type I defined that the muscle fibers originated in front and back of the duct simultaneously (10 cases, 45.5%). Type II was the cases

that originated in front of the duct and inserted into the anterior side of the duct (7 cases, 31.8%). In type III, which was observed in 5 cases (22.7%), the muscle fibers originated from the posterior aspect to the parotid duct and ran anteriorly to the duct. The same findings were observed in the histologic examination in all 8 specimens. In conclusion, author could lead to the conclusive description on the physiologic role in the salivary secretion and the possible role in the localization of the sialolithiasis.

Key words: parotid duct, terminal portion, buccinator, muscle fibers, sphincter

An anatomic study of the definite muscle fibers from the buccinator extending into the terminal portion of parotid duct; its role with functional aspects in saliva secretion

Hyo-Chang Kang, D.D.S., M.S.

Department of Dentistry
The Graduate School, Yonsei University

(Directed by professor Hee-Jin Kim, D.D.S., Ph.D.)

I. INTRODUCTION

The human parotid duct (Stensen's duct or Stenon's duct) is described as a single duct arising at the anterior border of the parotid gland. The parotid duct is about 6~8 cm in length in adults, and it cross the masseter muscle and at the anterior border of this muscle with the transverse facial artery, it turns in a medial direction, nearly at a right angle, while it passes through the buccal fat pad and pierces obliquely forward for a short distance between the buccinator and the mucous membrane of the oral cavity and opens into the oral cavity opposite the maxillary second molar.[1]

At the distal portion of the parotid duct, it is closely associated with the buccinator. Because the buccinator shows a dynamic function during the oral motor behavior, the physiologic saliva secretion from the parotid gland is

regulated and controlled by the buccinator muscle functions. In the physiologic aspects of the saliva secretion form the parotid gland, it has been considered that the buccinator muscle fibers surrounding the distal portion of the parotid duct might act as a passive sphincter system.[2,3,4]

From the previous reports, it is described the existence of the small muscle fibers from the buccinator at the distal portion of the parotid duct.[3,4,5] Such a connection between the parotid duct and buccinator during the oral motor behavior can participate in secretion control of the saliva. However, there have not been reported the conclusive anatomic and physiologic descriptions on the area that the parotid duct pierces the buccinator in recent literatures and even in the anatomy textbooks.

The aims of this study were to clarify the existence of the muscle fibers originated from the buccinator and determine the topography of their positional relationships and union patterns surrounding the distal portion of the parotid duct, and thereby to provide critical data for the understanding of physiologic function in saliva secretion from the parotid gland.

II. MATERIALS AND METHODS

I performed anatomic and histologic examinations on the relationships between the parotid duct and the buccinator muscle. Thirty specimens from Korean adult cadavers (14 males, 5 females; age 41 to 94 years) perfused with formaldehyde fixative were used in this study.

After removing the facial skin, subcutaneous fat, and facial muscles including superficial musculoaponeurotic system of the specimens, the origins of the buccinator were detached and buccinator *en bloc* was removed, which included the oral mucosa, buccinator, the distal portion of the parotid duct, a part of the buccal fat pad and its surrounding structures (Fig. 1).

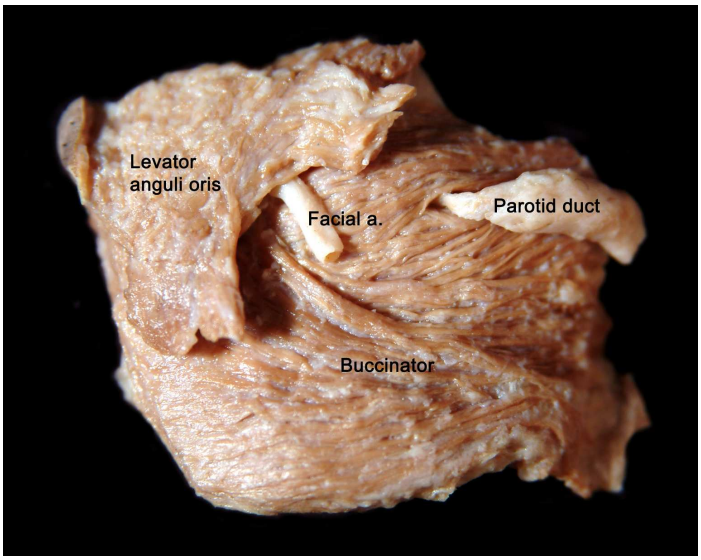

Figure 1. Photograph of the buccinator *en bloc* included the oral mucosa, buccinator, the distal portion of the parotid duct, a part of the buccal fat pad and its surrounding structures.

From 22 cases of the specimens, microdissections were performed using a surgical microscope (Carl Zeiss, Germany). Through the detail dissections from the internal and external aspect, the terminal portion of the parotid duct, muscle fibers of the buccinator and adjacent anatomical structures were carefully exposed. Throughout the dissections, the anatomical relationships and patterns of the buccinator muscle fibers into the distal portion of the parotid duct were examined.

To obtain the histological sections, I harvested terminal portion of the parotid duct including the surrounding buccinator muscular tissues and the parotid duct orifice from 8 undissected specimens. Specimens were post-fixed with 4% paraformaldehyde for 72 hours and then embedded in paraffin wax. Cross and longitudinal sections along the parotid duct of 5㎛ thickness were stained with hematoxylin-eosin and Gomori trichrome. Histologic observations were performed under the light microscope and photographs were taken.

No distinction was made between male and female cadavers. All photographs and diagrams in this article were of structures viewed from the left side of the specimen.

III. RESULTS

1. Topographic relationships between the terminal portion of the parotid duct and buccinator muscle fibers

In all cases, the parotid duct pierced through the maxillary portion of the buccinator to enter the oral cavity at the parotid papilla. Also, the external layer (tunica adventitia) of the parotid duct was continuous with the buccinator fascia (a part of the buccopharyngeal fascia).

Through the meticulous dissections, distinct small muscle fibers originating from the buccinator were extended into the external layer of the terminal portion of the parotid duct (Fig. 2). These muscle fibers were observed constantly in all cases and the length of the muscle fibers extending into the terminal portion of the parotid duct varied from 3 mm to 10 mm.

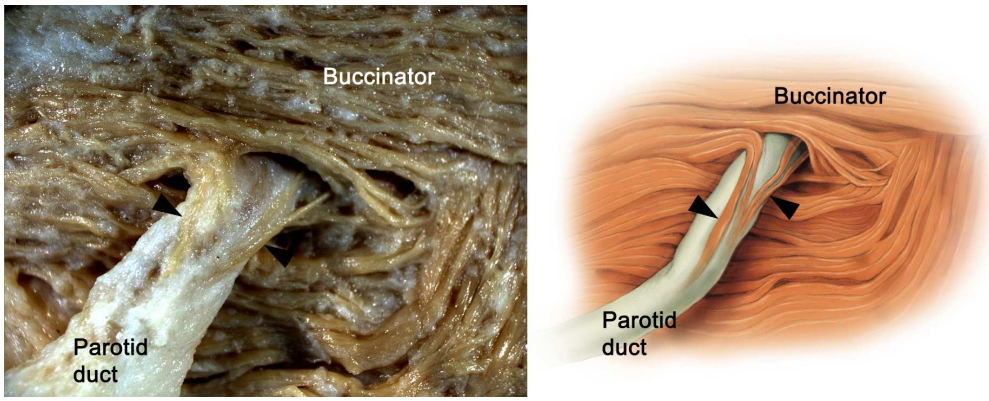

Figure 2. Photograph and the corresponding illustration of the distinct small muscle fibers (arrowheads) originating from the buccinator.

The distinct muscle fibers extending into the terminal portion of the parotid duct were arisen from the superficial or deep layer of the buccinator, respectively. In some cases of the specimen, these muscle fibers originated both from the superficial and deep layer of the buccinator (Fig. 3).

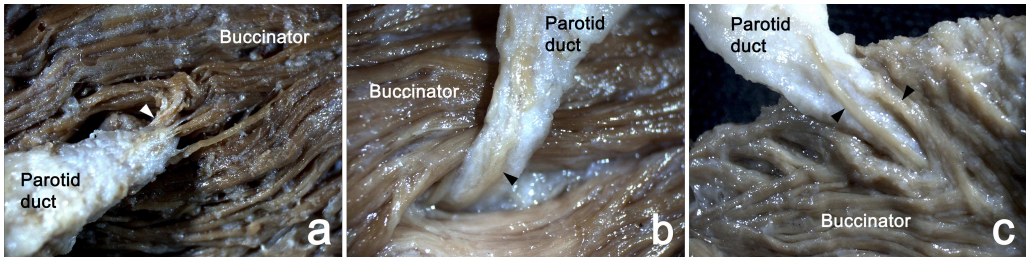

Figure 3. Photographs showing the arising patterns of the distinct muscle fibers extending into the terminal portion of the parotid. a, the fibers were arisen from the superficial layer of the buccinator; b, deep layer; c, superficial and deep layers.

The running aspects of the muscle fibers extending into the parotid duct also varied. These patterns were classified into three different categories based on the origin and location of the muscle fibers (Fig. 4). In type I, this was observed in 10 cases (45.5%), in which there existed the muscle fibers originated from the anterior and posterior aspects of the duct simultaneously. In addition to the cases that themuscle fibers located at the anterior and posterior (4 cases, 18.3%), the cases were observed that the additional muscle fibers from superior (5 cases, 22.7%) and inferior (1 case, 4.5%) aspects of the parotid duct, respectively. Type II defined that there were the muscle fibers originated in front of the duct and inserted into the anterior aspect of the duct (7 cases, 31.8%). In this pattern, there was no case that the muscle fibers

located in front of the parotid duct only, whereas there were the cases of additional muscle fibers located from superior (6 cases, 27.3%) and inferior (1 case, 4.5%) aspect of the parotid duct, respectively.

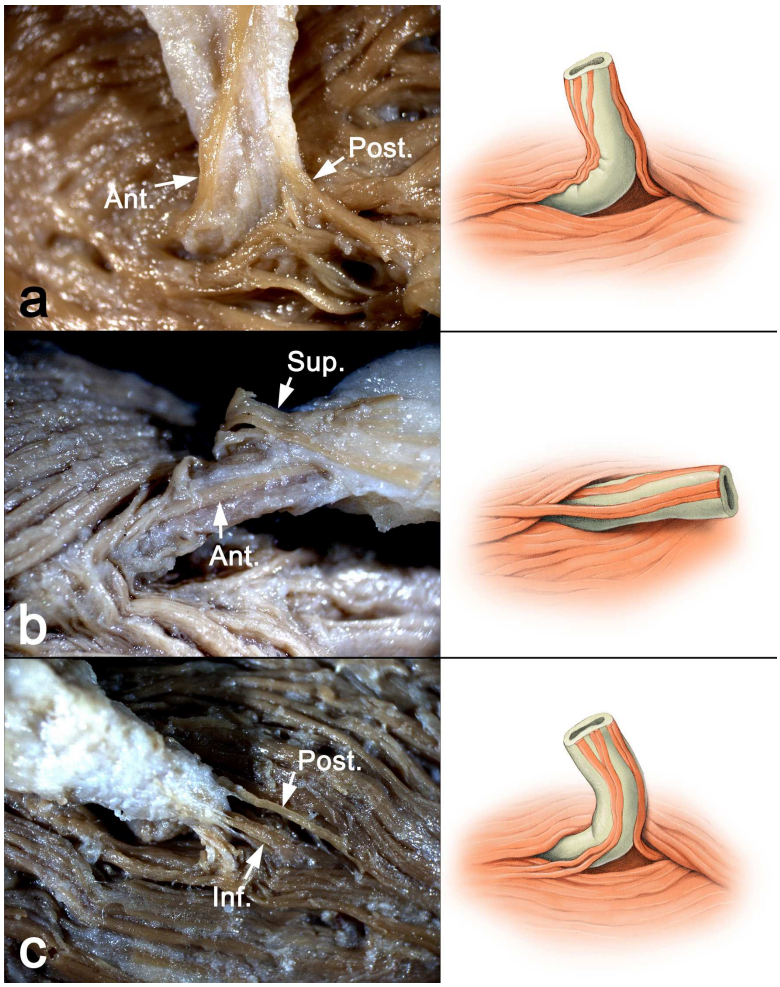

Figure 4. Photographs and the corresponding illustrations of three different categories based on the origin and location of the muscle fibers (arrows). a, the muscle fibers originated from the anterior and posterior aspects of the duct; b, the anterior and superior aspects; c, the posterior and inferior aspects.

Type III was the cases that there were the muscle fibers originated from the posterior aspect to the parotid duct and ran located in the medial aspect of the duct (5 cases, 22.7%). In this pattern, there was no case that the muscle fibers located behind (medial aspect) the parotid duct only. Also, the extending and inserting aspects of the muscle fibers into the terminal portion of the parotid duct showed a variety of patterns. Especially, there were the cases that the additional muscle fibers originated from the superior and inferior aspect simultaneously (3 cases, 13.7%). The results of the various insertion patterns of the muscle fibers are shown in Table 1.

Table 1. The classifications of the extension and insertion patterns of the buccinator muscle fibers into the terminal portion of the parotid duct.

Classifications	Origin and location of muscle fibers into the parotid duct	Number of the specimens (%)	Total (%)
Type I	from A and P	4 (18.3)	10 (45.5)
	from A, P and S	5 (22.7)	
	from A, P and I	1 (4.5)	
Type II	from A only	0 (0)	7 (31.8)
	from A and S	6 (27.3)	
	from A and I	1 (4.5)	
Type III	from P only	0 (0)	5 (22.7)
	from P and S	1 (4.5)	
	from P and I	1 (4.5)	
	from P, S and I	3 (13.7)	
Total		22 (100)	

A, anterior aspect (in front) of the parotid duct; P, posterior aspect of (behind) the parotid duct; S, superior aspect of the parotid duct; I, inferior aspect of the parotid duct.

2. Histologic observations of the terminal portion of the duct

On the cross sections of the parotid duct, it was composed of three layers: mucosa, muscle layer and adventitia (outer connective tissue layer) like the other excretory ducts. The lumen of the duct was round to oval in shape and the diameter varied in the different region even in the similar specimen. Themuscular layer consists of small smooth muscle fiber bundles running in longitudinal direction (Fig. 5). The oblique muscle fibers mixed with the longitudinal fibers were frequently observed, however the circular muscle fibers were not found in any region.

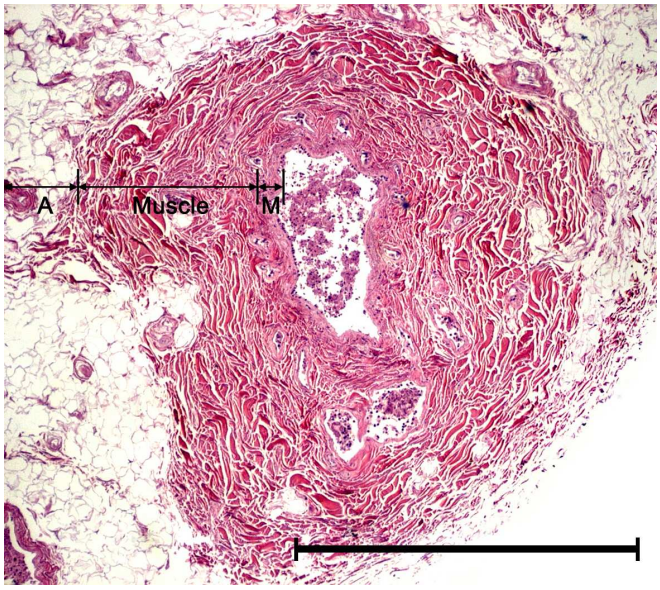

Figure 5. Microphotogaph of the cross section of the parotid duct, it was composed of three layers: mucosa (M), muscle layer (Muscle) and adventitia (A). (Hematoxylin-eosin stain; ×63)

In contrast of the cross section of the duct, I performed the longitudinal histologic sections along the axis of the parotid duct and papilla to investigate the morphology of the junction between the terminal portion of the parotid duct and the buccinator. The terminal portion of the parotid duct within the buccinator did not show the straight, but the tortuous running pattern with a few terminal siphons (Fig. 6). In some cases, there was observed the valve-like structure within the lumen of the terminal duct of the parotid (Fig. 7).

In this region, small, but distinct muscle fibers originated from the buccinator running parallel to the duct were observed (Fig. 6, 7). These muscle fibers extended into the terminal portion of the duct at 4 to 10 mm long from the outermost layer of the buccinator. In contrast, these muscle fibers disappeared as the duct approached to the oral mucosa within the buccinator. Some muscle fibers wrapped around the terminal portion of the parotid duct with spiralin form. These observations were similar to the results as shown in detail dissections.



Figure 6. The longitudinal histologic section along the axis of the parotid duct (Gomori trichrome stain; ×40). Bu, buccinator.

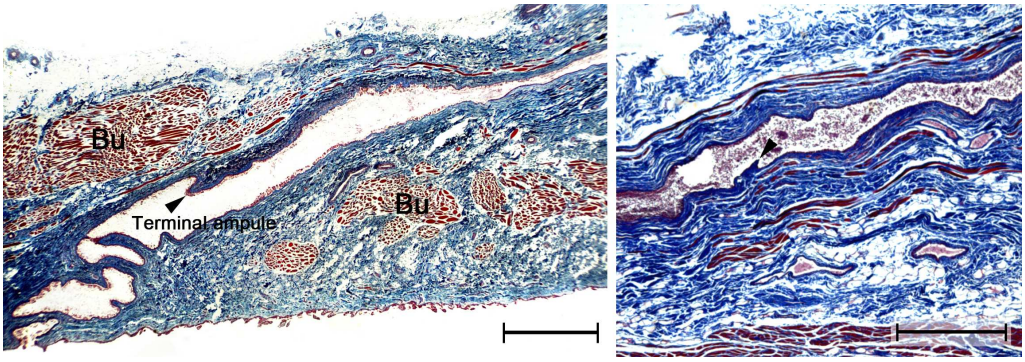

Figure 7. The valve-like structure (arrowheads) within the lumen of the terminal duct of the parotid (Gomori trichrome stain; left, ×20; right ×50). Bu, buccinator.

IV. DISCUSSION

The detail anatomy of the terminal portion of the parotid duct with buccinator has received little attention in the anatomy textbooks and literatures, except few publications.[2,3,4,5] The parotid duct has been considered as the static not dynamic organ, it failed to notice the functional and physiologic aspects with the buccinator. This study indicated that the existence of the definite muscle fibers from the buccinator extending into the parotid duct, and was physiological rather than structural.

From the functional studies by EMG, it is known that the activity in buccinator on working side occurred between the masticatory stokes.[6] In addition, Blanton *et al*.[7] reported that no EMG activity was detected in buccinator at the central part, around the first molar and the opening of the parotid duct when slowly opening and closing the mouth. And Perkins et al.[8] found that the orbicularis oris and buccinator were particularly active in the initial stage of swallowing. They concluded that these muscles initiate swallowing by producing a peristalsis-like wave of contraction originating in the oral cavity passing to the pharynx.

In this study, author could clarify the constant existence of the distinct small muscle fibers originated from the buccinator extending into the terminal portion of the parotid duct, and this finding suggests the possibility of the functional role in saliva secretion. In previous studies,[2,3,4,5] these structures were described as a fibrous tissue, however those were identified as a distinct part of the skeletal muscle fiber from the buccinator based on the anatomic and histologic

examinations in this study.

The sequential movements during the contraction and relaxation of the buccinator were transferred to the parotid duct by these small muscle fibers. Through these movements, the parotid duct can achieve the filled and empty state with saliva in regular sequence. In other words, when the buccinator is relaxed, the small muscle fibers extending into the terminal portion of the parotid duct could stretched the wall of the terminal portion of the parotid duct in various directions and these tractions result in the widening the lumen of the duct forming the terminal ampule. In this phase, the saliva is collected in this region with the opening of the parotid orifice is closed. In contrary, when the buccinator is contracted, this muscle is thickened in the central portion around the parotid duct orifice and squeezes the bulged area (terminal tubule) of the terminal portion of the parotid duct as this region is lengthened. Throughout these sequential events, the main function of saliva secretion could be actively performed. In this reason, these small muscle fibers from the buccinator are regarded as a dilator of the terminal portion of the parotid duct, not the sphincter system as known previously.[3,4] Although it still need to be considered further mechanisms, this striking system of saliva secretion is firmly acceptable.

This dynamic relationship between the buccinator and parotid duct remind the affinity to the function of ureterovesical junction. In the bladder, the muscle bundles of ureteral sheath (Waldey's sheath) extend from the outer bladder wall and function as a part of a preventive mechanism with compressing the intravesical ureter by contraction in voiding and filling phase independently

against vesicoureteral reflux.[9]

In the histologic examination the author also observed two structures in the terminal portion of the parotid duct at piercing the buccinator; the broad terminal siphons and the valve-like structures stood against the salivary flow within the lumen of the terminal siphons of the parotid duct. Through the forms of these structures, the author presumes that they could play a role in the control of salivary flux or the prevention of salivary reflux. The distinct small muscle fibers originated from the buccinator extending into the parotid duct, and valve-like structure within the terminal siphons should be considered together as forming the controlling system of saliva secretion, and they can achieve of the expelling the saliva, and the prevention of reflux or residual of saliva in the terminal portion of the parotid duct.

Sialolithiasis is the most common disease of the salivary glands in middle-aged patients. The cause of the sialolithiasis vary, there are local chemical changes in salivary components, infectious factors, secretory disturbances, ductal anomalies of the salivary glands and foreign bodies. Simultaneous sialolithiasis of several salivary glands is rare, and it appears mainly in a single gland, especially the submandibular gland. The reason why sialolithiasis is frequent in the submandibular gland is thought to be due to the tenacity of the submandibular saliva, which because of its high mucin content, adheres to any foreign particle.[10] The submandibular duct (Wharton's duct) is also long and irregular in its course. Marchal *et al.*[11] suggested another possible reason, the presence of a sphincter system in Wharton's duct described in the context of diagnostic sialendoscopy. However, Teymoortash *et al.*[12]

reported that the Wharton's duct revealed no anatomical correlation for the presence of a sphincter and did not support the involvement of sphincter-like structures in Wharton's duct during the formation of sialoliths. As contrast with Wharton's duct, the presence of functional muscle fibers into the parotid duct would be seemed to play an important role in the formation of sialolith by bulging of the terminal portion of the parotid gland. Under this circumstance, the remnants of the saliva could infrequently make the nidus of the sialolith, and this mechanism might explain the localization of the parotid sialolithiasis, that is, the region of relatively frequent occurrenceis the terminal portion near the orifice. To clarify this point, further morphological and physiological studies are necessary.

V. CONCLUSION

In conclusion, author could lead to the conclusive description on the physiologic role in salivary secretion for the parotid gland through the anatomic and histologic examinations. In this study, the distinct small muscle fibers originated from the buccinator existed constantly and extended into the terminal portion of the parotid duct and these small muscle fibers could act as a dilator of duct. In addition, the tortuous lumen structures related to the longitudinal smooth muscle layer of duct participate in the control of salivary flux (peristaltic activity) and the valve-like structures could play a role in the prevention of salivary reflux. Lastly, the presence of terminal ampule associated with the muscle fibers surrounding the parotid duct would play a possible role in the localization of sialolithiasis.

References

1. Standring S. Gray's anatomy. The anatomical basis of clinical practice. 39th ed., Elsevier Churchill Livingstone, New York. pp. 515-517, 2005.

2. Cerruti H. A parte terminal do ductus parotidicus no humen (pesquisas morfo-histologicus). Rev Ass Paulista de Med. 14(6):345-412, 1939.

3. Guerrier Y, Bolonyi F. L'architecture du muscle buccinateur et ses rapports avec le canal de STENON. Ann Oto-Laryngologie. 65(1):106-108, 1948.

4. Couly G, Guilbert F. Les sysarcoses manducatrices. Rev Stomatol. 1976 (a paraitre).

5. Courbier R, Richelme H. Note sur l'existence d'une gaine musculaire au niveau de la partie terminale du canal de STENON. Travaux de l'Institut d'Anat Fac de Med Marseille., fasc. 16:61-62, 1955-56.

6. Lundquist DO. An electromyographic analysis of the function of the buccinator muscle as an aid to denture retention and stabilization. J Pros Dent. 9:44-52, 1955.

7. Blanton PL, Biggs NL, Perkins RC. Electromyographic analysis of the buccinator muscle. J Dent Res.49:389-394, 1970.

8. Perkins RE, Blanton PL, Biggs NL. Electromyographic analysis of the buccinator mechanism in human beings. J Dent Res 56:783-794, 1977.

9. Tanagho EA, Pugh RC. The anatomy and function of the ureterovesical junction. Br J Urol. 35:151-165, 1963.

10. Shafer WG, Hine MK, Levy BM. A text book of Oral Pathology. 4th ed. W.B.Saunders company. Philadelphia. p. 561. 1983.

11. Marchal F, Kurt AM, Dulguerov P, Lehmann W. Retrograde theory in sialolithiasis formation. Arch Otolaryngol Head Neck Surg 127:66-68, 2001.

12. Teymoortash A, Ramaswamy A, Werner JA. Is there evidence of a sphincter system in Wharton's duct? Etiological factors related to sialolith formation. Journal of Oral Science. 45:233-235, 2003.

국문요약

귀밑샘관의 마지막부분으로 뻗어나가는 볼근섬유에 대한 해부학적 연구

연세대학교 대학원 치의학과
강 효 창

귀밑샘관 (parotid duct)은 볼근 (buccinator muscle)을 뚫고 볼근과 구강점막사이에서 비스듬하게 주행하고 있다는 사실은 잘 알려져 있다. 그러나 귀밑샘관이 볼근을 뚫고 나가는 부위에 대한 명확한 해부학적 연구는 없는 실정이다. 따라서 연구자는 귀밑샘관과 볼근사이의 관계를 밝히고자 해부학적, 조직학적 연구를 수행하였다. 연구를 위해 고정된 또는 고정되지 않은 한국인 시체에서 얻은 30쪽의 볼근을 사용하였으며, 볼근에는 귀밑샘관의 마지막부분이 포함되어 있었다. 22쪽에서 해부를 시행하였으며, 조직학적 연구를 위해 8쪽에서 hematoxylin-eosin 염색과 Gomori trichrome 염색을 시행하였다.

볼근에서 기원된 작고, 뚜렷한 근육섬유가 귀밑샘관 쪽으로 뻗어나가 귀밑샘관의 마지막 부분에 닿고 있었다. 이러한 섬유들은 모든 경우에서 관찰할 수 있었다. 그러나 근육섬유의 주행양상은 다양하였고, 근육섬유의 기원에 따라 3가지 유형으로 분류하였다. I형은 귀밑샘관의 앞과 뒤에서 동시에 기원된 근육섬유로 10예 (45.5%)에서 관찰되었다. II형은 귀밑샘관의 앞쪽에서 기원되어, 귀밑샘관의 앞쪽면으로 닿는 경우로 7예 (31.8%)에서 관찰되었다. III형은 5예 (22.7%)에서 관찰되었으며, 근육섬유가 귀밑샘관의 뒤쪽에

서 기원되어 귀밑샘관의 앞쪽으로 달리는 양상이었다. 이러한 3가지 유형은 조직학적 소견에서 모두 관찰할 수 있었다. 결론적으로 볼근과 귀밑샘관에 닿는 볼근섬유는 귀밑샘 분비과정에서 조임계통 (sphincter system)의 역할을 할 수 있을 것이다.