Maxillary sinus septa in Korean
: Prevalence, Location, Morphology
-a Reformatted CT scan analysis

Min-Jung Kim

The Graduate School
Yonsei University
Department of Dental Science

Maxillary sinus septa in Korean
: Prevalence, Location, Morphology
-a Reformatted CT scan analysis

A Dissertation Thesis
Submitted to the Department of Dental Science
and the Graduate School of Yonsei University
in partial fulfillment of the
requirements for the degree of
Master of Dental Science

Min-Jung Kim

December 2004

This certifies that the dissertation thesis
of Min-Jung Kim is approved.

Thesis Supervisor : Kyoo-Sung Cho

Kee-Deog Kim

Chang-Sung Kim

The Graduate School
Yonsei University
December 2004

감사의글

이 작은 결실을 맺을 수 있도록 부족한 저를 항상 따뜻한 관심과 지도로 격려해 주시고 이끌어 주신 조규성 교수님께 깊은 감사를 드립니다. 그리고, 많은 조언과 격려를 해주신 김종관 교수님, 채중규 교수님, 최성호 교수님, 김창성 교수님께 진심으로 감사드립니다. 또한, 본 연구에 많은 관심과 도움을 주신 김기덕 교수님께도 감사의 마음을 전합니다.

본 연구 내내 많은 도움을 아끼지 않은 윤정호 선생님, 정의원 선생님과 치주과 의국원 여러분께 고마움을 전합니다.

마지막으로, 항상 곁에서 든든하게 후원해주시고, 언제나 끝이 없는 사랑으로 저를 감싸주시는 부모님, 형님, 누님께 감사드립니다.

2004년 12월

저자 씀

Table of Contents

List of Figures

List of Tables

Abstract

Maxillary sinus septa in Korean
: Prevalence, Location, Morphology
- a Reformatted CT scan analysis

The placement of osseointegrated dental implants constitutes a widely used method of replacing lost or missing teeth. However, in order to provide adequate bone for implant fixation, resorption of the alveolar ridge of the edentulous posterior maxilla may necessitate augmentation prior to osseointegration. The technique of sinus lift may be difficult to perform when an aberrant sinus anatomy is encountered during surgical exposure, such as in those cases where a septum is present on the sinus floor.

The objective of this study was to determine the prevalence, size, location, and morphology of maxillary sinus septa in the atrophic/edentulous maxillary segments and non-atrophic/dentate maxillary segments. Reformatted computerized tomograms from 200 sinuses were analyzed utilizing ImagePro software. The sample population consisted of 100 patients (41 women and 59 men, with ages ranging between 19 and 87 years and a mean age of 50 years), for whom treatment was being planned in order for them to receive implant-supported restorations. The prevalence of one or more septa per sinus was found to be 26.5% (53/200), 31.76% (27

of 85), and 22.61% (26 of 115) in the overall study population, the atrophic/edentulous maxillary segments, the non-atrophic/dentate maxillary segments, respectively. In the analysis of the anatomic location of the septa within the sinus, it was revealed that 15 (25.4%) septa were located in the anterior region, 30 (50.8%) in the middle region, and 14 (23.7%) in the posterior region. The measured height of the septa varied among the different areas. The mean height of the speta was 1.63 ± 2.44 mm, 3.55 ± 2.58 mm, 5.46 ± 3.09 mm in the lateral area, the middle area, and the medial area, respectively.

In conclusion, it can be inferred that there is a wide anatomical variation in the prevalence, size, location, and morphology of maxillary sinus septa, irrespective of the degree of atrophy. Therefore, in order to prevent the likelihood of complications arising during sinus augmentation procedures, a thorough and extensive understanding of the anatomic structures inherent to the maxillary sinus is indispensable.

Key words : antral septa, computed tomography, dental implant, maxillary sinus.

Maxillary sinus septa in Korean
: Prevalence, Location, Morphology
- a Reformatted CT scan analysis

Min-Jung Kim, D.D.S.
Department of Dental Science, Graduate School,
Yonsei University
(Directed by Prof. Kyoo-Sung Cho, D.D.S., M.S.D., PhD.)

I. Introduction

Osseointegrated implants are increasingly being used to restore functional dentition. However, the placement of endosseous implants in the posterior maxilla is complicated by the existence of the maxillary sinus above the surgical site and into which implants may project. As the maxillary sinus develops, pneumatization of the alveolus occurs. Following the loss of tooth roots in the floor of the adult maxillary sinus, the ensuing increased osteoclastic activity and bone resorption causes further inferior expansion of the sinus. As a result, the edentulous posterior maxillary alveolus consists of low-density trabecular bone with minimal cortex and stress bearing capabilities, and is often inadequate for the anchorage of implants (Smiler DG et al. 1992). In extreme cases, only a paper-thin

lamella of bone separates the maxillary sinus from the oral cavity after long-term edentulousness (Van den Bergh JPA et al. 2000). Therefore, bone augmentation may be necessary before the placement of endosseous implants (Boyne et al. 1980).

The presence of anatomic variations within the maxillary sinus, such as septa, has been reported to increase the risk of sinus membrane perforation during the sinus elevation procedure (Tatum 1986; Chanavaz 1990; Betts et al. 1994; Jensen et al. 1998; Krennmair et al. 1999; Van den Bergh JPA et al. 2000). These anatomic variations were first described by Underwood in 1910 (Underwood 1910) and are therefore sometimes referred to as Underwood's septa. The etiology of antral septa has been the subject of several hypotheses by different authors. Neivert proposed that the septa were derived from the fingerlike projections produced by the embryologic out-pouching of the ethmoid infundibulum in which the contiguous walls did not resorb (Neivert H 1930). Krennmair and coworkers further classified the septa into primary septa and secondary septa, with primary septa arising from the development of the maxilla, while secondary septa were said to arise from the irregular pneumatization of the sinus floor following tooth loss (Krennmair et al. 1999).

The incidence of antral septa varies between 16% and 58% according to the literature (Underwood 1910; Betts et al. 1994; Ulm et al. 1995; Krennmair et al. 1997; Velasquez-Plata et al. 2002). They divide the caudal part of the sinus into multiple compartments known as recesses and, in certain cases, may even be complete, dividing the sinus into smaller accessory sinuses (Miles 1973). These septa act as a masticatory force

carrying struts during the dentate phase of life, and seem to disappear slowly when the teeth have been lost (Van den Bergh JPA et al. 2000).

The purpose of this study was to determine the prevalence, size, location, and morphology of maxillary sinus septa in the Korean population by means of a reformatted CT scan analysis.

II. Materials and Methods

Reformatted computerized tomograms from 200 sinuses were analyzed utilizing an automated image analysis system‡. The sample population consisted of 100 patients (41 women and 59 men, with ages ranging between 19 and 87 years and a mean age of 50 years) for whom treatment was being planned in order for them to receive implant-supported restorations. Twenty-two patients (22%) were completely edentulous, while the remainder of the patients (78%) were partially edentulous. Eighty-five sinuses (42.5%) were classified as atrophic/edentulous maxillary segments (partially edentulous, edentulous, and atrophic edentulous maxillae), while the remaining sinuses (57.5%) were classified as non-atrophic/dentate maxillary segments (partially or completely dentate maxillae). In the last 3 months, recently extracted sites were considered as non-atrophic/dentate maxillary segments.

The CT images were examined for the presence of antral septa using the axial planes of each section. Panoramic reformatted images were used to measure the height of the septa. The height of the septa was measured at 3 regions selected along its course across the sinus floor: the lateral, the middle and the medial aspects. Each aspect was at intervals of 4mm (Fig. 1). Vertical measurements were accomplished with an automated image measuring tool (Fig. 2). Those septa measuring more than 2.5 mm in

‡ Image-Pro Plus®, Media Cybernetics, Silver Spring, MD, U.S.A

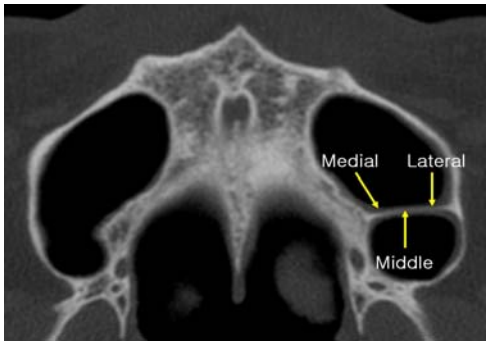

Figure 1. Points of septal height measurement.

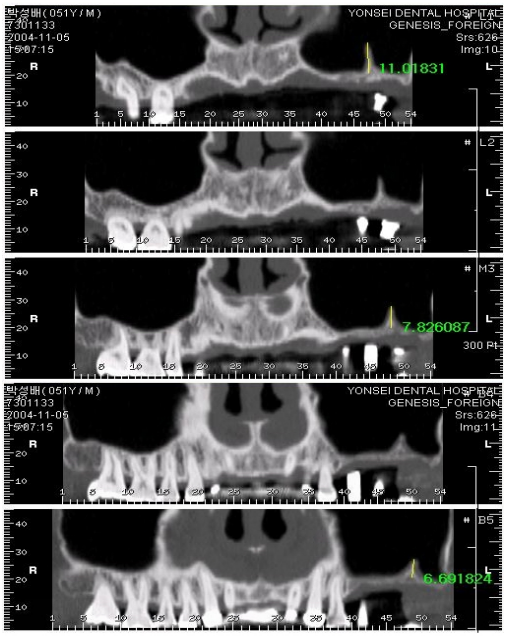

Figure 2. (Right) Measurement of vertical dimension of antral septa at 3 positions. L1 = medial; M3 = middle; B5 = lateral.

height at 1 or more of the above 3 positions were included in the analysis. Not all septa demonstrated a measurable component at each aspect. A value of zero was recorded for such regions. Each antral cavity exhibiting a septum was divided into 3 portions: anterior (mesial to distal aspect of second premolar), middle (from distal aspect of second premolar to distal aspect of second molar), and posterior (distal aspect of second molar region).

The statistical analysis was performed using the student-t test and the x^2 (Chi-square) test to determine whether there was a significant difference between the size and location of the septa identified in the atrophic and non-atrophic maxillary segments. P-values of $P<0.05$ were considered statistically significant.

III. Results

The prevalence of maxillary segment with one or more septa was found to be 53/200 (26.5%) in the overall study population, and 38/118 (32.2%) in the male patients, and 15/82 (18.29%) in the female patients. A total of 59 septa were found in the 200 maxillary segments (29.5%), which corresponded to 38% of the patients (38 of 100). The prevalence of septa was 31.76% (27 of 85) in the atrophic/edentulous maxillary segments and 22.61% (26 of 115) in the non-atrophic/dentate maxillary segments. Twenty-eight antral septa (47.46%) were identified on the right side, while 31 septa (52.54%) were found on the left side. Five patients (5%) presented with multiple septa in 5 maxillary segments (2.5%). Forty-eight maxillary segments harbored 1 septum, 4 maxillary segments presented with 2 septa, and 1 maxillary segment had 3 septa (Table. 1, Fig. 3).

Table 1. Summary of Septa Prevalence Data

	Number of septa				
	0	1	2	3	Total
Atrophic/edentulous maxillary segments	58	26	1	0	85
Non-atrophic/dentate maxillary segments	89	22	3	1	115
Total	147	48	4	1	200

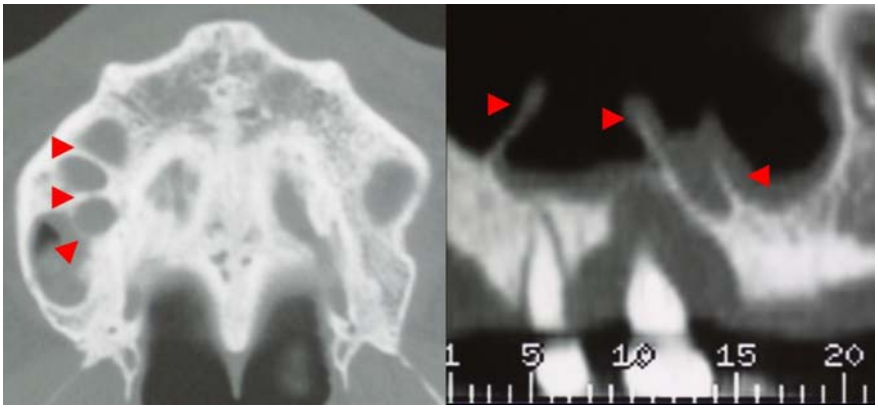

Figure 3. A 41-year-old female patient presented with 3 septa (arrow head) in the non-atrophic maxillary segment.

In the analysis of the anatomic location of the septa within the sinus, it was revealed that 15 (25.4%) septa were located in the anterior region, 30 (50.8%) in the middle region, and 14 (23.7%) in the posterior region. The distribution varied when the atrophic and non-atrophic maxillary segments were compared, but no significant differences were observed between these two populations. A closer examination of the non-atrophic maxillary segment population revealed a 80.65% prevalence of septa located superior to a maxillary tooth (primary septa) and a 19.35% prevalence of septa located superior to an edentulous ridge (primary septa, secondary septa, or a combination of both) (Table 2).

Table 2. Summary of Septa Location Data

	Location prevalence			No. of septa
	Anterior	Middle	Posterior	
Atrophic/edentulous Maxillary Segments	5 (17.9%)	14 (50%)	9 (32.1)	28
Non-atrophic/dentate Maxillary Segments	10 (32.3%)	16 (51.6%)	5 (16.1%)	31
Primary Septa	9 (36%)	14 (56%)	2 (8%)	25
Other Septa	1 (16.7%)	2 (33.3%)	3 (50%)	6
Total	15 (25.4%)	30 (50.8%)	14 (23.7%)	59

Primary septa = septa located apical to maxillary root; Other septa = septa located apical to edentulous maxillary ridge.

The measured height of each individual septum varied among the different regions. In the lateral area, the height ranged from 0 to 15.42 mm (with a mean of 1.63 ± 2.44 mm), in the middle area, the height ranged from 0 to 17.09 mm (with a mean of 3.55 ± 2.58 mm), and in the medial area, the height ranged from 0 to 20.18 mm (with a mean of 5.46 ± 3.09 mm). When the mean values for the septa identified in the atrophic/edentulous maxillary segments were compared with those in the non-atrophic/dentate maxillary segments, those septa found in the non-atrophic/dentate maxillary segments demonstrated statistically significantly higher values at all points of measurement. When the septa

found in the non-atrophic/dentate maxillary segments were classified into those located apically to remaining teeth (primary septa) and those in the proximity of edentulous areas (other septa), the primary septa were found to be significantly higher at all measured points (Table 3). There were no septa completely dividing the sinus into 2 or more compartments.

Table 3. Summary of Septa Height Measurements

	Height (mm ± SD)*					No. of septa
	Lat	Mid	Med	Avg	Max	
Atrophic/edentulous Maxillary Segments	1.45 (±1.72)	2.61 (±1.68)	4.45 (±2.41)	2.84 (±1.47)	4.87 (±1.99)	28
Non-atrophic/dentate Maxillary Segments	1.81 (±2.97)	4.41 (±2.96)	6.37 (±3.39)	4.19 (±2.88)	6.42 (±3.36)	31
Primary Septa	1.90 (±3.23)	4.75 (±3.11)	6.72 (±3.60)	4.46 (±3.07)	6.79 (±3.57)	25
Other Septa	1.41 (±1.60)	2.99 (±1.76)	4.89 (±1.85)	3.10 (±1.59)	4.89 (±1.85)	6
Total	1.63 (±2.44)	3.55 (±2.58)	5.46 (±3.09)	3.55 (±2.40)	5.68 (±2.88)	59

*All differences were statistically significant ($P<0.05$).

Primary septa = septa located apical to maxillary root; Other septa = septa located apical to edentulous maxillary ridge; SD = standard deviation; Lat = height of lateral aspect; Mid = height of middle aspect; Med = height of medial aspect; Avg = average height of 3 regions; Max = height of the highest aspect among 3 regions.

IV. Discussion

The present study analyzed maxillary sinus septa by maens of reformatted computerized tomograms. Krennmair et al. reported that panoramic radiography can lead to a false diagnosis regarding the positive or negative identification of antral septa in 21.3% of the cases (Krennmair et al. 1999). Several authors have suggested that CT images can be useful to the clinician in both diagnosis and treatment planning by enhancing the accuracy of the diagnostic decisions and facilitating the formulation of adequate treatment plans (Schwarz et al. 1987; Alder et al. 1995).

Etiologically, antral septa constitute partly congenital and partly acquired malformations. Congenital septa, also referred to as 'primary septa', can develop in all maxillary sinus regions and evolve during the growth of the middle part of the face (Chanavaz 1990). In contrast, Vinter et al. observed that atrophy of the maxillary alveolar process proceeds irregularly in different regions and leaves bony 'crests' on the maxillary sinus floor, which are also known as 'secondary septa' and can be considered to be the result of tooth loss and atrophy (Vinter et al. 1993). During progressive edentulism, both primary and secondary septa undergo resorption. Although it is impossible to accurately predict the presence and height of the primary septa without imaging, it is reasonable to predict that the more recently a tooth has been extracted, the more likely one is to encounter surgically significant secondary septa (Stover JD 1999). It is impossible to label a septum located apical to an edentulous ridge as primary or

secondary without a radiographic history of the sinus in question. Thus, it can be concluded that septa located apical to dentate regions are primary (developmental), while those located apical to an edentulous region can be either primary or secondary.

The prevalence of septa in the maxillary sinus found in this study shows a significantly higher incidence in the atrophic/edentulous maxillary segments (31.76%) than in the non-atrophic/dentate maxillary segments (22.61%). This is because the atrophic/edentulous maxillary segments generally contain secondary septa. Other authors have also reported on the prevalence of septa. Underwood found 30 septa in 45 skulls (90 maxillary sinuses), demonstrating a 33% prevalence (Underwood 1910). In a similarly designed study, Ulm and coworkers reported 13 septa in 41 maxillary sinuses, a 31.7% prevalence (Ulm et al. 1995). Krennmair and associates counted 32 antral septa in 200 maxillary sinuses (16% of the sinuses) utilizing CT imaging (Krennmair et al. 1997). Krennmair and associates later reported 51 antral septa in 194 maxillary sinuses (26.29%) evaluated using anatomic and radiographic examinations (Krennmair et al. 1999). Velasquez-Plata et al. found 69 septa in 312 maxillary sinuses (22%) (Velasquez-Plata et al. 2002). Both Krennmair et al. and Velasquez-Plata et al. also reported that the atrophic maxillary segments showed secondary septa, whereas the dentate maxilla without any visible alveolar process resorption showed a significantly lower incidence of maxilla with antral septa (Krennmair et al. 1997; Krennmair et al. 1999; Velasquez-Plata et al. 2002).

Morphologically, the septa showed a medial-lateral or largely medial-lateral orientation, that is, they were oriented in the buccopalatal

plane. Their anatomic shape can be compared to an inverted gothic arch whose height is greater than its width. The average height of the medial insertion was generally greater than the height of the lateral insertion, in other words, the septal height increased in the direction of the lateral to the medial insertion (Table 3). The primary septa in the non-atrophic /dentate maxillary segments were significantly higher than the other septa in the atrophic/edentulous maxillary segments as a result of their growth and because they were not affected by the resorption of the maxillary alveolar process. In this study population, no complete septa dividing the sinus into 2 or more compartments were found. Krennmair et al. found only one complete septum in 200 maxillary sinuses (0.5%), which was arch-shaped and showed a sagittal orientation, subdividing the sinus into two separate compartments (Krennmair et al. 1997). Complete septa seem to be few and far between, to say the least.

The septa observed in the overall study population demonstrated a greater prevalence in the middle region (first and second molar) (50.8%), followed by the anterior region (25.4%), and the posterior region (23.7%). When the atrophic maxillary segment group and non-atrophic maxillary segment group were compared, no significant differences were observed (Table 2). This is corresponds to a study by Velasquez-Plata and coworkers, but contrasts with a study by Krennmair and associates. The study by Velasquez-Plata et al. demonstrated a greater prevalence in the middle region (41.0%), followed by the posterior region (35%), and the anterior region (24.0%). The locations of the septa in the partially edentulous patients and completely edentulous patients showed a relatively

similar distribution (Velasquez-Plata et al. 2002). However, Krennmair et al. reported a greater prevalence of septa in the anterior region (72.7%) in the atrophic posterior maxillary regions (partially edentulous, edentulous, and atrophic edentulous maxillae). They also examined a group of non-atrophic posterior maxillary regions (partially or completely dentate maxillae) and observed a decreased prevalence in the anterior segment (57%). Of the 51 septa identified in their study, only 14 (27.5%) were found in the first molar region, while 1 (2%) was found in the second molar region. This information was used to make conclusions regarding the etiology of the septa, namely, that the increased prevalence of septa in the anterior region of the edentulous maxilla was the result of earlier tooth loss and pneumatization of the posterior maxillary ridge, which resulted in an increased prevalence of septa at the junction between the premolar and molar segments (Krennmair et al. 1999). Stover criticized these conclusions, however, stating that a greater prevalence of septa in the posterior segments resulting from remnant interradicular bone between adjacent maxillary molars, in other words, secondary septa, would be more likely (Stover JD 1999). Underwood actually noted in his study that the majority of the septa identified were located in the posterior segment. He hypothesized that septa (primary) formed as a result of the different timing of tooth eruptions. Thus, since primary posterior septa are the last to develop, they would tend to remain for a longer period of time, because of their decreased exposure to resorptive mechanisms proper to the antral cavity (Underwood 1910). The differences between the results obtained from different studies may be a reflection of variations in the methods of measurement, the tools utilized

to gather the data, and the populations studied.

The Clinical significance of primary or secondary antral septa depends both on their location and height, on the one hand, and on the type of surgery performed, on the other hand. For example, when maxillary sinus endoscopy is performed, a pronounced primary septum on the sinus floor can render the removal of displaced foreign bodies, residual roots, or a pathologically changed sinus mucosa more difficult (Wigand et al. 1978; Kennedy et al. 1985; Mafee et al. 1993). In contrast, septa that rest on the sinus floor, and therefore can be of either primary or secondary origin, gain clinical significance when implants are placed in combination with sinus augmentation (Boyne et al. 1980; Misch 1987; Tidwell et al. 1992). During augmentation surgery, the sinus membrane is elevated, and the floor is augmented with graft materials following the infracturing of the facial antral wall (Wood et al; 1988; Tidwell et al. 1992). If septa are present on the sinus floor, they can complicate both the inversion of the bone plate and the elevation of the sinus membrane. If septa are encountered on the antral floor, Boyne et al. recommend cutting them with a narrow chisel and removing them with a hemostat so that the bone graft can be placed over the entire antral floor without interruption (Boyne et al. 1980). Tidwell et al. subdivided the facial bony wall into an anterior and a posterior part and inverted both trap doors. A septa left in situ can be removed after such preparation (Tidwell et al. 1992). Indeed, it is preferable to remove them, because septa left in situ may constitute a risk factor by causing the Schneiderian membrane to become torn during elevation. Among the possible complications of perforation of the sinus membrane is the

development of maxillary sinusitis (Quiney et al. 1990; Ueda et al. 1992; Zimbler et al. 1988). Therefore, a modification of the conventional surgical technique is required when septa are present (Betts NJ et al. 1994).

The present study only analyzed maxillary sinus septa with reformatted computerized tomograms, there was no clinical verification of these results. Therefore, further studies for clinical verification are needed.

V. Conclusion

The objective of this study was to determine the prevalence, size, location, and morphology of maxillary sinus septa in the atrophic/edentulous maxillary segments and non-atrophic/dentate maxillary segments.

Reformatted computerized tomograms from 200 sinuses were analyzed utilizing ImagePro software. The sample population consisted of 100 patients (41 women and 59 men, with ages ranging between 19 and 87 years and a mean age of 50 years), for whom treatment was being planned in order for them to receive implant-supported restorations. The results were as follows.

1. The prevalence of one or more septa per sinus was found to be 26.5% (53/200), 31.76% (27 of 85), and 22.61% (26 of 115) in the overall study population, the atrophic/edentulous maxillary segments, the non-atrophic/ dentate maxillary segments, respectively.

2. In the analysis of the anatomic location of the septa within the sinus, it was revealed that 15 (25.4%) septa were located in the anterior region, 30 (50.8%) in the middle region, and 14 (23.7%) in the posterior region.

3. The measured height of the septa varied among the different areas. The mean height of the speta was 1.63 ± 2.44 mm, 3.55 ± 2.58 mm,

5.46 ± 3.09 mm in the lateral area, the middle area, and the medial area, respectively.

From the above results, it can be inferred that there is a wide anatomical variation in the prevalence, size, location, and morphology of maxillary sinus septa, irrespective of the degree of atrophy. Therefore, in order to prevent the likelihood of complications arising during sinus augmentation procedures, a thorough and extensive understanding of the anatomic structures inherent to the maxillary sinus is indispensable.

VI. References

Alder ME, Deahl ST, Matteson SR. Clinical usefulness of two dimensional reformatted and three dimensionally rendered computerized tomographic images: Literature review and a survey of surgeons' opinions. *J Oral Maxillofac Surg* 53:375-386, 1995.

Betts NJ, Miloro M. Modification of the sinus lift procedure for septa in the maxillary antrum. *Oral Maxillofac Surg* 52(3):332-333, 1994.

Boyne P, RA James. Grafting of the maxillary sinus floor with autogenous marrow and bone. *J Oral Maxliiofac Surg* 38:113-116, 1980.

Chanavaz M. Maxillary sinus: anatomy, physiology, surgery, and bone grafting related to implantology-eleven years of surgical experience (1979-1990). *J Oral Implantol* 16:199-209, 1990.

Jensen OT, Shulman LB, Block MS, Iacono VJ. Report of the Sinus Consensus Conference of 1996. *Int J Oral Maxillofac Implants* 13(suppl):11-12, 1998.

Kennedy DW, Zinreich SJ, Rosenbaum AE, Johns ME. Functional endoscopic sinus surgery. Theory and diagnostic evaluation. *Arch Otolaryngol* 111(9):576-582, 1985.

Krennmair G, Ulm C, Lugmayr H. Maxillary sinus septa: incidence, morphology and clinical implications. *J Cranio-Maxillofac Surg* 25: 261-265, 1997.

Krennmair G, Ulm GW, Lugmayr H, Solar P. The incidence, location, and height of maxillary sinus septa in the edentulous and dentate maxilla. *J Oral Maxillofac Surg* 57:667-671, 1999.

Mafee MF, Chow JM, Meyers R. Functional endoscopic sinus surgery: anatomy, CT screening, indications, and complications. *Am J Roentgenol* 160(4):735-744, 1993.

Miles AEW. The maxillary antrum. *Br Dent J* 134:61-63, 1973.

Misch CE. Maxillary sinus augmentation for endosteal implants: Organized alternative treatment plans. *Int J Oral Implantol* 4:49-58, 1987.

Neivert H. Surgical anatomy of the maxillary sinus. *Laryngoscope* 40:1-4, 1930.

Quiney RE, Brimble E, Hodge M. Maxillary sinusitis from dental osseointegrated implants. *J Laryngol Otol* 104:333-334, 1990.

Schwarz MS, Rothman SLG, Rhodes ML, Chafetz N. Computed tomography: Part II. Preoperative assessment of the maxilla for endosseous implant surgery. *Int J Oral Maxillofac Implants* 2:143-148, 1987.

Smiler DG, Johnson PW, Lozada JL. Sinus lift grafts and endosseous implants. *Dent Clin North Am* 36:151-186, 1992.

Stover JD. Discussion: The incidence, location, and height of maxillary sinus septa in the edentulous and dentate maxilla. *J Oral Maxillofac Surg* 57:671-672, 1999.

Tatum H. Maxillary and sinus implant reconstruction. *Dent Clin North Am* 30:207-229, 1986.

Tidwell JK, Blijdorp PA, Stoelinga PJ, Brouns JB, Hinderks F. Composite grafting of the maxillary sinus for placement of endosteal implants. A preliminary report of 48 patients. *Int J Oral Maxillofac Surg* 21(4): 04-209, 1992.

Ueda M, Kaneda T. Maxillary sinusitis caused by dental implants: Repot of two cases. *J Oral Maxillofac Surg* 50:285-287, 1992.

Ulm CW, Solar P, Krennmair G, Matejka M, Watzek G. Incidence and suggested surgical management of septa in sinus-lift procedures. *Int J Oral Maxillofac Implants* 10:462-465, 1995.

Underwood AS. An inquiry into the anatomy and pathology of the maxillary sinus. *J Anat Physiol* 44:354-369, 1910.

Van den Bergh JPA, ten Bruggenkate CM, Disch FJM, Tuinzing DB. Anatomical aspects of sinus floor elevations. *Clin Oral Impl Res* 11:256-265, 2000.

Velasquez-Plata D, Hovey LR, Peach CC, Alder ME. Maxillary sinus septa: a 3-dimensional computerized tomographic scan analysis. *Int J Oral Maxillofac Implants* 17:854-860, 2002.

Vinter I, Krmpotic-Nemanic J, Hat J, Jalsovec D. Does the alveolar process of the maxilla always disappear after tooth loss? *Laryngorhinootologie* 72(12):605-607, 1993.

Wigand ME, Steiner W, Jaumann MP. Endonasal sinus surgery with endoscopical control: from radical operation to rehabilitation of the mucosa. *Endoscopy* 10(4):255-260, 1978.

Wood RM, Moore DL. Grafting of the maxillary sinus with intraorally harvested autogenous bone prior to implant placement. *Int J Oral Maxillofac Implants* 3(3):209-214, 1988.

Zimbler MS, Lebowitz RA, Glickman R, Brecht LE, Jacobs JB. Antral augmentation, osseointegration, and sinusitis: the otolaryngologist's perspective. *Am J Rhinol* 12(5):311-316, 1998.

국문 요약

3차원 전산화단층촬영을 이용한 한국인에서의 상악동 중격 분석: 빈도, 위치, 형태, 임상적 의의

연세대학교 대학원 치의학과

(지도 **조 규 성** 교수)

김 민 중

선천적 결손이나 상실된 치아를 수복하기 위해 골유착성 치과 임프란트가 폭넓게 사용되고 있다. 위축된 상악 구치부에 임프란트를 식립할 경우에는, 초기 고정을 위한 적절한 골량을 형성하기 위해 골이식이 필요하다. 그러나, 상악동 중격과 같은 상악동 내의 해부학적 변이가 있는 경우에 상악동 거상술시에 상악동막의 천공, 출혈, 비구강개통, 상악동염 등의 합병증이 일어날 수 있다.

본 연구에서는 3차원 전산화단층촬영을 이용해서 한국인 성인에서 위축된 상악골 (위축이 일어난 무치악/무분무치악 상악골) 과 위축되지 않은 상악골 (위축이 일어나지 않은 유치악/부분유치악 상악골) 의 상악동 중격을 분석하고, 빈도, 크기, 위치, 형태학적 특징을 조사하였다. 100명의 환자 (남성: 59명, 여성: 41명, 연령: 19-87세, 평균연령: 50세) 의 재구성화된 전산화단층사진에서 얻은 200개의 상악동 자료를 ImagePro software로 분석하였다.

200개의 상악동에서 총 59개의 상악동 중격이 발견되었다. 하나 이상의 상악동 중격을 포함하는 상악동의 빈도는 26.5% (53/200) 로 나타났으며, 100명의 환자중 38명 (38%) 에서 상악동 중격이 발견되었다. 위축된 상악골에서는 31.76%, 위축되지 않은 상악골에서는 22.61%의 하나 이상의 상악동 중격을 포함하는 상악동의 빈도가 나타났다. 상악동 내에서의 중격의 위치에 대한 분석 결과, 59개의 상악동 중격 중 15개 (25.4%) 는 전방 부위에 위치하였고, 30개 (50.8%) 는 중간 부위, 14개 (23.7%) 는 후방 부위에 위치하였다. 상악동 중격의 높이는 측정 위치에 따라 다양하게 나타났다. 외측 부위는 0에서 15.42 mm (평균 1.63 ± 2.44 mm), 중앙 부위는 0 에서 17.09 mm (평균 3.55 ± 2.58 mm), 내측 부위는 0 에서 20.18 mm (평균 5.46 ± 3.09 mm) 의 길이 분포를 보였다.

이상의 결과에서 볼 때, 상악동 중격은 상악골의 위축 정도에 관계없이 빈도, 크기, 위치, 형태에서의 많은 해부학적 변이를 보인다. 따라서, 상악동 거상술시에 합병증을 예방하기 위해서는 상악동내의 해부학적 구조물들에 대한 철저하고 해박한 이해가 필수적이다.

핵심되는말 : 상악동 중격, 전산화단층촬영, 치과 임프란트, 상악동