

# Homonymous Hemianopia after Embolization of an Aneurysm-associated AVM Supplied by the Anterior Choroidal Artery

Dong Joon Kim, Dong Ik Kim, Seung-Koo Lee, and Si Yeon Kim

Department of Diagnostic Radiology, Yonsei University College of Medicine, Seoul, Korea.

The primary objective for the treatment of arteriovenous malformations (AVM) of the brain is to reduce the risk of hemorrhage. The risk of hemorrhage is known to increase with the presence of an aneurysm associated with AVM. The purpose of this report is to describe the development of visual complications after the embolization of a hemorrhagic anterior choroidal artery feeding AVM with an associated aneurysm and to describe the possible causes.

**Key Words:** Intracranial arteriovenous malformations, embolization, therapeutic, cerebral infarction

## INTRODUCTION

The primary objective for treating arteriovenous malformations (AVM) of the brain is to prevent future hemorrhage, or to at least decrease its frequency.<sup>1</sup> Many factors such as deep venous drainage, prior bleeding, venous stenosis and arterial aneurysms are known to cause a greater incidence of hemorrhage, and these factors must be considered in conjunction with the potential risks and benefits of treatment.<sup>1-3</sup>

The purpose of this report is to describe the development of visual complications after the embolization of a hemorrhagic anterior choroidal artery feeding AVM with an associated aneurysm and to describe the possible causes.

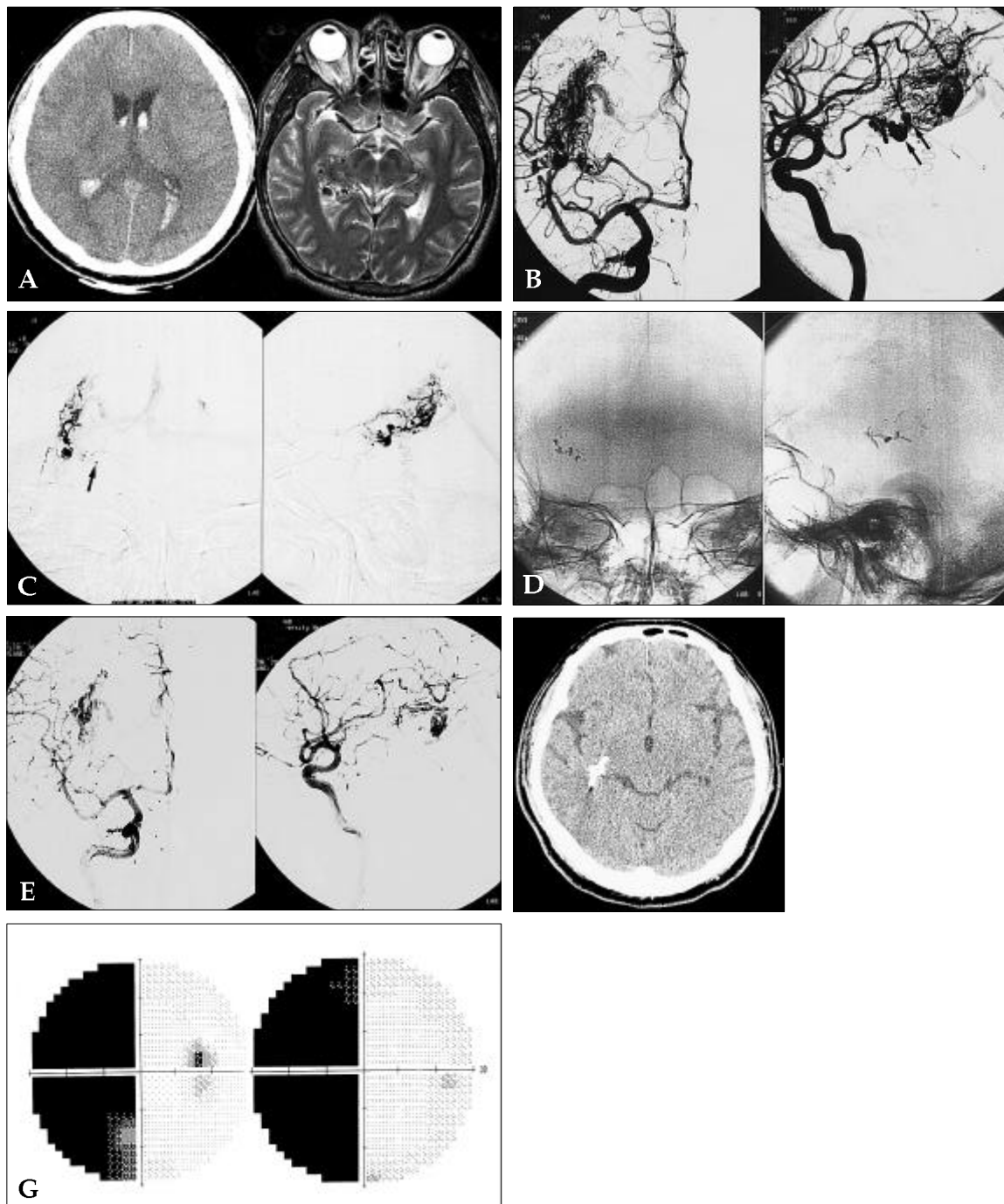
## CASE REPORT

A 43 year old man presented with symptoms of acute headache, nausea and vomiting. Intraventricular hemorrhage was noted on initial CT and a subsequent MR revealed multiple signal void vascular structures in the lateral ventricle with enlarged aneurysmal structures (Fig. 1A). Right ICA angiogram showed an AVM with nidus measuring  $2.9 \times 3.2 \times 1.6$  cm with feeders from the right anterior choroidal artery and the lenticulostriate arteries. Drainage was into the straight sinus via the basal vein of Rosenthal. There were two flow-related aneurysms distal to the plexal point of the right anterior choroidal artery (Fig. 1B). Because the patient had intraventricular hemorrhage, probably associated with the aneurysms, the benefits of preradiosurgical embolization of the aneurysms and the nidus was considered to outweigh the potential risks of the embolization procedure and the hemorrhagic risk of the aneurysm. After superselection of the plexal segment of the anterior choroidal artery, proximal to the flow related aneurysms with the Elite 1.5 microcatheter (Boston Scientific, Fremont, CA), 50 mg of sodium amytal was injected intra-arterially (Fig. 1C). No newly developed neurologic signs including hemiplegia, hemianesthesia and hemianopia were noted after the injection of sodium amytal. Twenty-five percent NBCA was injected at this site and occlusion of the aneurysms and the anterior choroidal feeder beyond the plexal point was noted with residual nidus filling from the lenticulostriate feeders (Fig. 1D and E). However, on neurologic examination, immediately after the

Received April 11, 2003

Accepted July 18, 2003

Reprint address: requests to Dr. Dong Ik Kim, Department of Diagnostic Radiology, Yonsei University College of Medicine, 134 Shinchon-dong, Seodaemun-gu, Seoul 120-752, Korea. Tel: 82-2-361-6277, Fax: 82-2-393-3035, E-mail: dikim@yuunc.yonsei.ac.kr



**Fig. 1.** A 43-year-old man presented with symptoms of acute headache, nausea and vomiting. (A) Initial CT (left) revealed intraventricular hemorrhage. MR (right) revealed multiple signal void structures in the lateral ventricle. Enlarged aneurysmal vascular structures were also noted in the right lateral ventricle. (B) Right ICA angiogram AP (left) and lateral (right) views showed an AVM nidus with feeders from the enlarged right anterior choroidal artery and the lenticulostriate arteries. Drainage was into the straight sinus via the basal vein of Rosenthal. There were flow-related aneurysms distal to the plexal point of the right anterior choroidal artery (arrows). (C) Sodium amytal test after superselection distal to the plexal point (arrow) of the anterior choroidal artery and proximal to the flow related aneurysms. (D) 25% NBCA was injected. (E) Occlusion of the aneurysms and the anterior choroidal feeder beyond the plexal point with residual feeders from lenticulostriate arteries was noted. (F) Post-embolization CT reveals embolic materials in the anterior choroidal artery and the previous site of flow-related aneurysms. (G) A visual field test of the patient two months after the embolization still shows left homonymous hemianopia.

embolization, the patient developed left homonymous hemianopia. No pupillary abnormality was noted. The patient did not show any signs of hemiplegia or hemianesthesia. A visual field test performed two months after the embolization showed homonymous hemianopia correlating with the neurologic exams (Fig. 1G). Gamma knife surgery was performed on the residual lesion after embolization.

## DISCUSSION

Embolization of an AVM with arterial supply from the AchA is an effective adjunct to surgery or radiation therapy, but is potentially hazardous as the AchA supplies crucial structures including the internal capsule, basal ganglia, medial temporal lobe, optic pathways, cerebral peduncle and choroids plexus of the lateral ventricle.<sup>4</sup>

The AchA is a small vessel that originates from the internal carotid artery 2 to 4 mm distal to the origin of the posterior communicating artery. It may originate from the proximal middle cerebral artery or the posterior communicating artery.<sup>5,6</sup>

Anatomical dissections of the AchA consistently separate this artery into its phylogenetically old (inferior cerebral artery) parenchymal ramification, the cisternal segment, and its newly acquired choroidal ramification, the plexal segment. The cisternal segment supplies the optic tract, cerebral peduncle, uncus, lateral geniculate body, anterior perforating substance (globus pallidus and posterior limb of the internal capsule), tip of the temporal lobe, hippocampus, dentate gyrus, fornix and pulvinar. The plexal segment in most cases originates as a single branch, then passes through the choroidal fissure to supply the choroids plexus.<sup>7</sup>

There are profuse anastomotic communications along the choroid plexus with the PCA and a somewhat lesser number of communications with the pial branches of the PCA in the region of the lateral geniculate body. Perforating branches passing through the anterior perforating substance to the globus pallidus and posterior limb of the internal capsule do not receive any significant collateral supply.<sup>7</sup>

Most authors emphasize the absence of branches

to the cerebral tissue after the AchA's ventricular penetration. This allows for the safe endovascular intervention distal to this entry.<sup>8</sup> However, there have been reports of some branches from the plexal segment supplying the distal part of the optic tract and the thalamus.<sup>9</sup>

Anterior choroidal artery syndrome, caused by an infarct in the territory of AchA, was first described by Foix, et al. in 1925. When complete, the syndrome includes hemiplegia, hemihypoesthesia and a homonymous hemianopia.<sup>10</sup>

Hemiplegia has been the most consistently observed deficit by the involvement of the posterior two thirds of the posterior limb of the internal capsule.<sup>5</sup> Infarction of the optic tract, lateral geniculate body, and midbrain is less common, possibly because of the plethora of rich collateral vessels.<sup>5</sup>

Pure homonymous hemianopia from anterior choroidal artery lesions without motor and sensory symptoms - as in our case - has rarely been reported.<sup>11</sup>

Hemianopia is the most variable feature of AchA syndrome, possibly because of the collateral vessels. Although the AchA supplies the visual system at three separate loci - the optic tract, the lateral geniculate body, and the origin of the geniculocalcarine tract in the retrolentiform portion of the internal capsule - involvement of the geniculocalcarine tract is usually believed to be responsible for the visual abnormality.<sup>10</sup>

Various types of visual field defects are related to the AchA infarctions including upper quadrant anopia, sectoranopia by lesions in the lateral geniculate body or homonymous hemianopia by lesions in the posterior optic tract or geniculocalcarine tract.<sup>11</sup>

Ischemia of the geniculocalcarine tract could cause a congruent homonymous hemianopia, possibly sparing the macula with a normal pupillary response. This visual field defect is the most common visual abnormality found in patients with AchA territory infarction, but is often transient because of the rich collateral supply from the PCA branches.<sup>5</sup>

The reason for development of homonymous hemianopia after superselective embolization beyond the plexal point in our case can be explained as follows: First, even though embolization be-

yond the plexal point is generally accepted as safe, the vascular anatomy of the anterior choroidal artery is diverse with profuse anastomotic communications, and there are reports of branches feeding the distal optic tract and thalamus from the plexal segment.<sup>5,9</sup> Embolization of these unusual branches may explain the complication noted in our case. Second, inadvertent injection or migration of embolic material into the proximal cisternal segment may have occurred even though the glue was injected distal to the plexal point. This seems to be a less likely explanation since the postembolization angiogram shows the intact cisternal segment and the embolic material in the intended site of previous aneurysms. Still micro-embolization of the embolic material into the proximal branches cannot be definitively ruled out. Third, the cerebral parenchymal branches are known to originate from the cisternal segment, but this anatomic description is derived from nonpathologic cases. In cases of associated vascular malformations - as in our case - the vascular anatomy may have become distorted due to the abnormally high flow burden. Thus, despite the procedural precautions, complications may occur, as in our patient.

The coexistence of an aneurysm with an AVM was shown to correlate significantly with intracranial hemorrhage at presentation, and when the aneurysm was believed to be responsible for the hemorrhage, early treatment of the aneurysm was shown to have protective effects against hemorrhage or the recurrence of hemorrhage.<sup>2,12</sup>

In our case, the flow-related aneurysm associated with the AVM was regarded as responsible for the hemorrhage; thus, early eradication of the aneurysm from the cerebral circulation and subsequent radiotherapy was considered the optimal treatment choice. The benefits of the embolization procedure were considered to outweigh the risks of the interventional procedures performed on the potentially hazardous anterior choroidal artery or the risk of rehemorrhage of an unembolized aneurysm.

Though the authors were aware of the limitations of the provocative test with sodium amytal, it was still performed with the microcatheter tip at the site of anticipated embolization. A positive result from this test may have re-

directed the treatment plan, but the negative result we obtained in our case provided little information in predicting the aftermath of the procedure. The streaming character of the flow in the high-flow AVM feeder may have been the cause of a false negative result.<sup>13</sup>

In conclusion, embolization of AVMs with anterior choroidal feeder is a risky procedure with inherent dangers of complications despite precautionary measures. The presence of an aneurysm associated with the AVM, as we had in our patient, may further complicate treatment planning. The pros and cons from embolization of an aneurysm associated AVM should be carefully weighed before initiating therapy.

## REFERENCES

1. Byrne JV. *Interventional neuroradiology: theory and practice*. Oxford: Oxford University Press 2002;2002.
2. Piotin M, Ross IB, Weill A, Kothimbakam R, Moret J. Intracranial arterial aneurysms associated with arteriovenous malformations: endovascular treatment. *Radiology* 2001;220:506-13.
3. Stapf C, Mohr JP, Pile-Spellman J, Sciacca RR, Hartmann A, Schumacher HC, et al. Concurrent arterial aneurysms in brain arteriovenous malformations with haemorrhagic presentation. *J Neurol Neurosurg Psychiatry* 2002;73:294-8.
4. Hodes JE, Aymard A, Casasco A, Rufenacht D, Reizine D, Merland JJ. Embolization of arteriovenous malformations of the temporal lobe via the anterior choroidal artery. *AJNR Am J Neuroradiol* 1991;12:775-80.
5. Helgason C, Caplan LR, Goodwin J, Hedges T, 3rd. Anterior choroidal artery-territory infarction. Report of cases and review. *Arch Neurol* 1986;43:681-6.
6. Vaughan D, Asbury T, Tabbara KF. *General ophthalmology*. 12th ed. Norwalk, Conn.: Appleton & Lange; 1989.
7. Friedman JA, Pichelmann MA, Piepgras DG, Atkinson JL, Maher CO, Meyer FB, et al. Ischemic complications of surgery for anterior choroidal artery aneurysms. *J Neurosurg* 2001;94:565-72.
8. Lasjaunias PL, Berenstein A, ter Brugge KG. *Surgical neuroangiography*. 2nd ed. Berlin; New York: Springer; 2001.
9. Morandi X, Brassier G, Darnault P, Mercier P, Scarabin JM, Duval JM. Microsurgical anatomy of the anterior choroidal artery. *Surg Radiol Anat* 1996;18:275-80.
10. Takahashi S, Ishii K, Matsumoto K, Higano S, Ishibashi T, Suzuki M, et al. The anterior choroidal artery syndrome. II. CT and/or MR in angiographically verified cases. *Neuroradiology* 1994;36:340-5.

11. Han SW, Sohn YH, Lee PH, Suh BC, Choi IS. Pure homonymous hemianopia due to anterior choroidal artery territory infarction. *Eur Neurol* 2000;43:35-8.
12. Brown RD, Jr., Wiebers DO, Forbes GS. Unruptured intracranial aneurysms and arteriovenous malformations: frequency of intracranial hemorrhage and relationship of lesions. *J Neurosurg* 1990;73:859-63.
13. Connors JJ, Wojak JC. *Interventional neuroradiology: strategies and practical techniques*. Philadelphia: Saunders; 1999.